

# 3D FIESTA MRI for trigeminal neuralgia diagnostic tools : A case report

H. Fatmawati<sup>1\*</sup>, N.K. Adj<sup>2</sup>, C. Bumi<sup>3</sup>

<sup>1</sup>Department of Radiology, Faculty of Medicine, University of Jember, Indonesia

<sup>2</sup>Department of Neurosurgery, Faculty of Medicine, Univeof Jember, Indonesiarsity

<sup>3</sup>Department of Epidemiology, Faculty of Public Health, University of Jember, Indonesia

## ► Case report

### \*Corresponding author:

Heni Fatmawati, M.D.,

E-mail:

fatmawatiheni@unej.ac.id

Received: February 2024

Final revised: August 2024

Accepted: October 2024

Int. J. Radiat. Res., January 2025;  
23(1): 255-258

DOI: 10.61186/ijrr.23.1.255

**Keywords:** 3D FIESTA Magnetic Resonance Imaging, neuropathic pain, trigeminal neuralgia.

## ABSTRACT

**Background:** Trigeminal neuralgia (TN) is a severe condition presented with abrupt pain in the area innervated by one or more branches of the fifth cranial nerve. The pain is usually described as sudden, unilateral, severe, brief, stabbing, and recurrent sensation. **Case Description:** A 60-year-old female with a left-sided facial has had pain for two years. She was referred by a neurosurgeon diagnosed as having left stabbing pain that radiated down the distribution of the third-division trigeminal nerve. An MRI 1.5T with conventional and high-resolution protocols used the sequences three-dimensional magnetic resonance imaging (3D MRI) study included fast imaging employing steady-state acquisition. According to the ability of 3D-FIESTA MRI, it is used to demonstrate the anatomy of the trigeminal complex. The 3D FIESTA sequence has the ability to demonstrate the compression and displacement of the nerve. **Conclusion:** 3D FIESTA MRI is a useful tool to assess the trigeminal system and may describe the recent understanding pathology of TN.

## INTRODUCTION

Trigeminal neuralgia (TN) is a disorder with painful symptoms that are sudden, recurrent, and usually unilateral, severe, short, and cut in an area innervated by one or more branches of the fifth cranial nerve <sup>(1, 2)</sup>. TN is also known as tic gout. The trigeminal nerve, known as the fifth cranial nerve, originates from the pons and is ramified into three branches, the ophthalmic nerve (V1) supplies the eyes, upper eyelids, and forehead, and the maxillary nerve (V2) supplies the lower eyelids, cheeks, nostrils, and upper lip. Gingiva, mandible (V3), innervates the lower lip, lower gingiva, mandible, and muscles of mastication. Clinical findings to date fail to distinguish idiopathic trigeminal neuralgia from symptomatic trigeminal neuralgia. The etiology and mechanism of TN are not fully understood. According to the etiology, TN is categorized into idiopathic TN, classic TN, and secondary TN. The most common etiological theory for TN is the compression of the trigeminal nerve by blood vessels at the nerve root entry zone (REZ) <sup>(2, 3)</sup>.

The main risk factors for TN are direct trauma, nerve compression, or other systemic disorders that cause nerve damage. The incidence of trigeminal neuralgia can reach 4 to 13 per 100,000 people per year. This disease is more prevalent in women rather

than in men. The prevalence ranges from 1 to 1.5 to 1 to 1.7 for males and females. The most commonly affected age group is those over the age of 50 <sup>(3)</sup>.

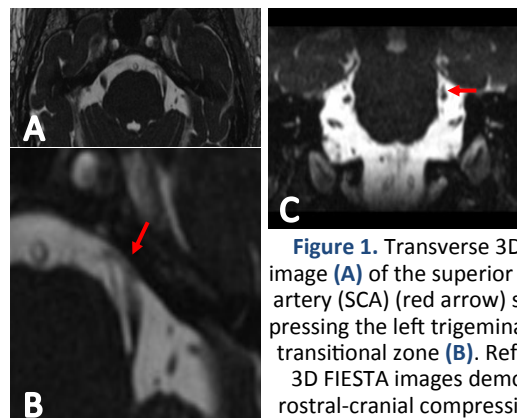
In some cases, drugs and surgery lead to the treatment of patients with TN which treatment a person receives depends on age, medical history, severity of disease, and underlying conditions. Medical treatment can be given by giving carbamazepine, oxcarbazepine, baclofen, and several other drugs such as phenytoin, gabapentin, clonazepam, lamotrigine, and valproic acid. Additionally, it can be done with botulinum toxin injections and surgical treatments (microvascular decompression, peripheral neurectomy, and nerve blocks). Ablation procedures include thermal coagulation rhizotomy, chemical injection or mechanical balloon compression, and radiosurgery) <sup>(4, 5)</sup>.

Magnetic resonance imaging (MRI) provides detailed visualization of trigeminovascular connectivity patterns and detects subtle pathological features in virtually all trigeminal pathways <sup>(4)</sup>. Current studies state that MRI sensitivity for detecting trigeminal nerve vascular compression is estimated between 94-97%. The asymptomatic trigeminal nerve vascular contact is quite prevalent. Therefore, corroboration of clinical and radiologic findings may strengthen diagnosis <sup>(3)</sup>. MRI may be the

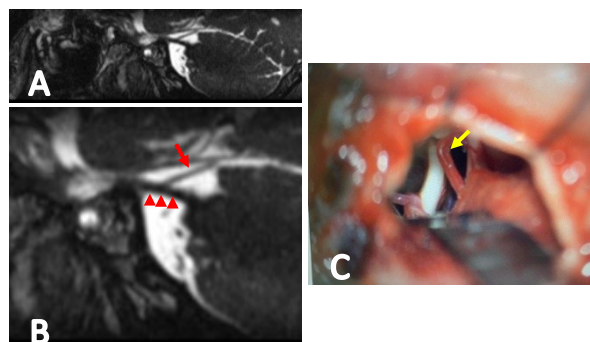
option considering the high sensitivity. However, the MRI is not constantly attainable, predominantly in the rural region. MRI use in developing countries is rather limited compared to the developed world due to expensive purchase expenditures, a shortage in infrastructure, a nonstop power supply, and the proficiency required to sustain and utilize the systems. The deficiency of experts in MRI may also contribute to the procurement of MRI in developing countries <sup>(6)</sup>. We describe a case of trigeminal neuralgia and discuss the importance of MRI, particularly three-dimensional fast imaging employing steady-state acquisition (3D FIESTA), as an important diagnostic tool for TN. Although 3D FIESTA is not considered a novelty, this modality is far from being accessible in all countries. Despite its superiority in evaluating the neuroanatomy, 3D FIESTA is still considered an expensive examination. In Indonesia, the use of 3D FIESTA is yet infrequent and is not covered by national health insurance. This study is considered as a few novel study to discuss the use of 3D FIESTA at diagnosing cranial nerve impairment, especially trigeminal neuralgia, in rural regions within Indonesia. Therefore, this study wishes to emphasize the usefulness of 3D FIESTA in diagnosing trigeminal neuralgia to empower the procurement of this modality widely in developing countries.

### Case presentation

A 60-year-old woman complains of pain in the left side of her face for two years. He was referred by a neurosurgeon who was diagnosed with stabbing pain radiating to the distribution of the third trigeminal nerve. We requested a workstation using GE AW volume share 7 type advanced post-processing workstation. We used MRI 1,5 T (Discovery MR 750; GE Healthcare, Milwaukee, WI). MRI studies of GE1.5-T using three-dimensional magnetic resonance imaging (3D-MRI) sequences with conventional T1W, T2W, and high-resolution protocols, including rapid imaging using steady-state acquisition (FIESTA) were done (figure 1). 3D FIESTA was used for accurate assessment of the anatomy of the various parts of the trigeminal nerve (figure 2).

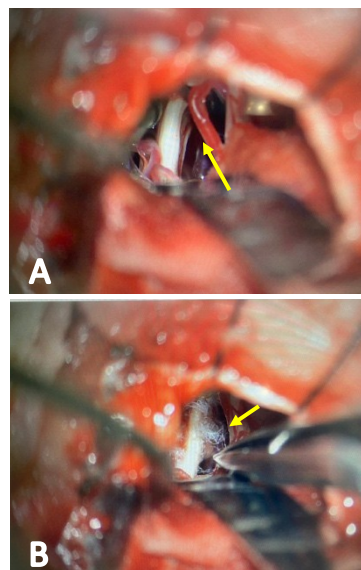


**Figure 1.** Transverse 3D FIESTA image (A) of the superior cerebellar artery (SCA) (red arrow) seen compressing the left trigeminal nerve at transitional zone (B). Reformatted 3D FIESTA images demonstrate rostral-cranial compression of the TN by the SCA loop (C).



**Figure 2.** A. Sagittal 3D FIESTA image at the level of pons. B. A superior cerebellar artery (red arrow) is seen intending and compressing the rostral transitional zone of the cisternal segment (red arrowheads) of the left trigeminal nerve. C. Intraoperative views, the trigeminal nerve was compressed and deformed by the SCA (yellow arrow).

We diagnosed left TN due to neurovascular contact of the SCA loop compressing the trigeminal nerve root on the 3D FIESTA MRI sequences. The vascular microdecompression was done in this patient, in which an SCA loop was compressing the trigeminal nerve root was observed. The patient was discharged with pain-free and light hypoaesthesia on the left side of her face after surgery. On the one-year evaluation, the patient complains of no symptoms after the procedure (figure 3).



**Figure 3.** The intraoperative view (A) of the SCA loop is mobilized away from the nerve, showing the trigeminal nerve has been deformed by the SCA (yellow arrow) into the curved shape seen at the time of surgery. The trigeminal nerve was released from the SCA, and several Teflon (B) implants were placed on the nerve.

### DISCUSSION

The most common etiological theory for TN is vascular compression of the trigeminal nerve. TN is usually due to the compression of the trigeminal nerve caused by an abnormally elongated SCA. Cranial compression of the trigeminal nerve causes subfacial TN (V3), medial or lateral reduction causes V2 pain, and caudal compression causes V1 trigeminal neuralgia <sup>(3, 4)</sup>. In these patients, the SCA may have an abnormally elongated loop, causing

compression of the trigeminal nerve (TN). Clinicopathologic relevance of vascular compression in TN: rostral reduction of the medulla in TN leads to inferior facial trigeminal neuralgia (V3).

Trigeminal neuralgia is diagnosed based on clinical signs and symptoms. This requires the absence of clinically apparent neurological deficits, such as hypoalgesia or dysesthesia in the trigeminal region. Despite typical clinical manifestations, misdiagnosis, or late diagnosis still occurs in clinical practice. In the literature, there are still some reports of errors in the diagnosis and management of trigeminal neuralgia <sup>(1)</sup>. Trigeminal neuralgia can be misdiagnosed as glossopharyngeal neuralgia. Due to the patient's presentation of experiencing singular pain in the middle third of the left side of their tongue without any other accompanying symptoms, they were incorrectly diagnosed with glossopharyngeal neuralgia instead of trigeminal neuralgia <sup>(7)</sup>.

Particular imaging, such as MRI, may be useful to rule out underlying causes of trigeminal neuralgia, such as tumors and multiple sclerosis. MRI should be performed as part of the diagnosis. Brain MR is the gold standard examination to rule out secondary causes of TN. Detailed trigeminal MR brain scan sequences are critical to detect the presence of trigeminal vascular conflict, and the nature and degree of compression of the vasculature. Neuroimaging is also important to further classify typical symptoms and idiopathic TN, thereby influencing the treatment to be applied. Absence of neurovascular conflict may present, 4% of TN patients were reporting no neurovascular contact during microdissection. Therefore, MRI is crucial to identify the presence of neurovascular contact before surgery <sup>(8-10)</sup>. Proper visualization of neurovascular contact through imaging before surgery may help in planning surgical approaches and predicting outcomes in TN patients. If MR is contraindicated, neurophysiological recordings of CT cerebral angiography, head CT scan, MR angiographic, trigeminal evoked potentials, and trigeminal reflexes should be used <sup>(3, 9, 11-16)</sup>.

Three-dimensional fast imaging using steady-state acquisition images (3D-FIESTA) is introduced. 3D FIESTA provides better resolution and a more accurate representation of minor structures such as cranial nerves. 3D FIESTA with contrast creates high-resolution images between fluids, blood vessels, and cranial nerves. Soft tissue can be well described, especially in the cistern space. A high signal-to-noise ratio also makes small structures stand out <sup>(4, 16-19)</sup>. The 3D anatomical model achieved is also compatible with the intraoperative anatomical position findings. Therefore the 3D method is advantageous to formulate the operative approach <sup>(20)</sup>.

Visualization of nerves and blood vessels was demonstrated with MRI rather than CT scan imaging. CT imaging facilitates visualization of the

intraosseous segments of cranial nerves. T2-weighted images from MR angiography with contrast-enhanced imaging are excellent for visualizing blood vessels and nerves, especially in the cranial region. However, in MR angiography the distinct resolution between CSF and nerve may appear ambiguous. MR angiography may also fail to portray a vein due to its slow blood flow compared to 3D FIESTA. Vascular and nerves were described as low signal intensity structures, and CSF was shown as high signal intensity structures on 3D FIESTA images. Low signal intensity is visualized by dark structures and CSF with high signal intensity is visualized by light structures <sup>(1, 11, 19)</sup>.

The capabilities of 3D FIESTA MRI were recently used to demonstrate the anatomy of the trigeminal complex. The aim of the demonstration is radiosurgery planning and management of trigeminal neuralgia. The 3D FIESTA sequence can demonstrate compression and displacement of nerves. Studies have used 3D FIESTA sequences to detect, localize, and grade trigeminal neurovascular disease. There are several ways to assess cranial nerve pain. CT scans are helpful in finding segments within the bone and provide a direct view of the nerves. The nerves are not clearly visible, despite the increased contrast of the CT scan. Therefore, a 3D MRI is required to visualize nerves and blood vessels. According to a study prepared by Vedaraju (2021) <sup>(21)</sup>, all trigeminal neurovascular cases could be better identified and ranked accordingly on 3D FIESTA images. This is useful for delineating the neuroanatomy before planning microvascular decompression. Compression grading in trigeminal neuralgia helps surgeons classify patients and treatment according to each patient's condition. A study by Zhou *et al.* (2012) also showed the superiority of 3D FIESTA in capturing neurovascular contact in TN patients <sup>(10)</sup>.

In diagnosing trigeminal neuralgia, the results of MRI imaging of neurovascular problems must be correlated with clinical symptoms and doctors can eliminate the etiology of cranial nerve neuralgia to help them use MR imaging.

## CONCLUSION

This review highlights that 3D FIESTA is a valuable tool for assessing the trigeminal system in TN and can describe our recent pathology understanding of TN. The 3D FIESTA can be used to examine the connections between the trigeminal nerve and blood vessels in great detail and can detect even the slightest abnormalities in all trigeminal pathways.

**Funding:** There is no associate funding for this study.

**Ethical Consideration:** This study has gained ethical approval from the ethical committee of the medical



research Faculty of Dentistry, University of Jember, registration number 2207/UN25.8/KEPK/DL/2023.

**Conflict of Interest:** There are no conflicts of interest to disclose in this work.

**Author Contribution:** H.F., contributes to initiating the concepts or ideas, also in the definition of intellectual content and manuscript preparation. N.K.A., contributes to design, literature search, data analysis, and data acquisition. C.B., contributes to data analysis and manuscript editing.

## REFERENCES

- Antonaci F, Arceri S, Rakusa M, Mitsikostas DD, Milanov I, Todorov V, Ramusino MC, Costa A (2020) Pitfalls in recognition and management of trigeminal neuralgia. *J Headache Pain*, **21**(1): 82.
- Geneidi EAS, Ali HI, Abdel Ghany WA, Nada MA (2016) Trigeminal pain: Potential role of MRI. *The Egyptian Journal of Radiology and Nuclear Medicine*, **47**: 1549-1555
- Hughes MA, Frederickson AM, Branstetter BF, Zhu X, Sekula RF (2016) MRI of the Trigeminal Nerve in Patients With Trigeminal Neuralgia Secondary to Vascular Compression. *Am J Roentgenol*, **206**: 595-600.
- Prieto R, Pascual JM, Yus M, Jorquera M (2012) Trigeminal neuralgia: Assessment of neurovascular decompression by 3D fast imaging employing steady-state acquisition and 3D time of flight multiple overlapping thin slab acquisition magnetic resonance imaging. *Surg Neurol Int*, **3**: 50.
- Kabatas S, Karasu A, Civelek E, Sabanci AP, Hepgul KT, Teng YD (2009) Microvascular decompression as a surgical management for trigeminal neuralgia: Long-term follow-up and review of the literature. *Neurosurg Rev*, **32**: 87-94
- Hilabi BS, Alghamdi SA, Almanaa M (2023) Impact of magnetic resonance imaging on healthcare in low- and middle-income countries. *Cureus*, **15**(4): e37698.
- Wu L, Xiong J, Huang Y, Han K, Cai K, Fu X (2023) Case report: Trigeminal neuralgia misdiagnosed as glossopharyngeal neuralgia. *Front Neurol*, **14**: 1079914.
- Satoh T, Onoda K, Date I (2007) Preoperative simulation for microvascular decompression in patients with idiopathic trigeminal neuralgia: Visualization with three-dimensional magnetic resonance cisternogram and angiogram fusion imaging. *Neurosurgery*, **60**: 104-113.
- Anderson VC, Berryhill PC, Sandquist MA, Ciaverella DP, Nesbit GM, Burchiel KJ (2006) High-resolution three-dimensional magnetic resonance angiography and three-dimensional spoiled gradient-recalled imaging in the evaluation of neurovascular compression in patients with trigeminal neuralgia: A double-blind pilot study. *Neurosurgery*, **58**: 666-671.
- Zhou Q, Liu ZL, Qu CC, Ni SL, Xue F, Zeng QS (2012) Preoperative demonstration of neurovascular relationship in trigeminal neuralgia by using 3D FIESTA sequence. *Magn Reson Imaging*, **30**: 666-671
- Srivastava R, Jyoti B, Shukla A, Priyadarshi P (2015) Diagnostic criteria and management of trigeminal neuralgia: A review. *Asian Pacific Journal of Health Sciences*, **2**: 108-118
- Miller J, Acar F, Hamilton B, Burchiel K (2008) Preoperative visualization of neurovascular anatomy in trigeminal neuralgia. *J Neurosurg*, **108**: 477-482.
- Ni S, Su W, Li X, Zeng Q, Liu Y, Zhu S, Wu C (2009) Enhanced three-dimensional fast spoiled gradient recalled MRI combined with magnetic resonance angiography for preoperative assessment of patients with trigeminal neuralgia. *Journal of Clinical Neuroscience*, **16**: 1555-1559
- Liang C, Yang L, Reichardt W, Zhang B, Li R (2023) Different MRI-based methods for the diagnosis of neurovascular compression in trigeminal neuralgia or hemifacial spasm: A network meta-analysis. *Journal of Clinical Neuroscience*, **108**: 19-24
- Shi H, Li Y, Wang Y, Guo W, Zhang K, Du Y, Shi H, Qian T (2022) The preoperative evaluation value of 3D-slicer program before microsurgical vascular decompression in patients with hemifacial spasm. *Clin Neurol Neurosurg*, **217**: 107241.
- Benes L, Shiratori K, Gurschi M, Sure U, Tirakotai W, Krischek B, Bertalanffy H (2005) Is preoperative high-resolution magnetic resonance imaging accurate in predicting neurovascular compression in patients with trigeminal neuralgia? A single-blind study. *Neurosurg Rev*, **28**: 131-136.
- Vörös E, Palkó A, Horváth K, Barzó P, Kardos L, Kuncz A (2001) Three-dimensional time-of-flight MR angiography in trigeminal neuralgia on a 0.5-T system. *Eur Radiol*, **11**: 642-647.
- Ni S, Su W, Li X, Zeng Q, Liu Y, Zhu S, Wu C (2009) Enhanced three-dimensional fast spoiled gradient recalled MRI combined with magnetic resonance angiography for preoperative assessment of patients with trigeminal neuralgia. *Journal of Clinical Neuroscience*, **16**: 1555-1559.
- Yoshino N, Akimoto H, Yamada I, Nagaoka T, Tetsumura A, Kurabayashi T, Honda E, Nakamura S, Sasaki T (2003) Trigeminal neuralgia: evaluation of neuralgic manifestation and site of neurovascular compression with 3D CISS MR imaging and MR angiography. *Radiology*, **228**: 539-545.
- Shi Z, Chen S, Fan C, Gao X, Tan G, Wang Z (2021) Role of multimodal image-based 3D reconstruction for primary trigeminal neuralgia. *Interdiscip Neurosurg*, **25**: 101163.
- Veradaju K, Madhusudana Y, Eada SVS (2021) Assessment of trigeminal neurovascular conflicts using 3D FIESTA-C sequence on a 3T MRI. *Asian J Med Radiol Res*, **9**: 7.