

Relationship between MRI imaging characteristics and serum markers CEA, CA199, CA125 levels in ovarian cancer patients

X. Lu, S. Xie*, D. Mou, M. Peng

Department of Gynecology, The First People's Hospital of Zunyi, Zunyi, China

ABSTRACT

► Original article

***Corresponding author:**

Shengyan Xie, M.D.,

E-mail:

xsy419848977@163.com

Received: November 2023

Final revised: August 2024

Accepted: September 2024

Int. J. Radiat. Res., July 2025;
23(3): 513-519

DOI: 10.61186/ijrr.23.3.1

Keywords: Ovarian cancer; magnetic resonance imaging; serum tumor markers; lymph node metastasis.

Background: To investigate the correlation between magnetic resonance imaging (MRI) imaging characteristics and serum markers carcinoembryonic antigen (CEA), carbohydrate antigen 199 (CA199), and carbohydrate antigen 125 (CA125) levels in ovarian cancer patients. **Materials and Methods:** A retrospective analysis of 85 patients with ovarian cancer diagnosed by postoperative pathological results in our hospital was carried out. MRI imaging data and hematological indexes of patients were collected to analyze the relationship between imaging characteristics of ovarian cancer patients and serum CEA, CA199, CA125 levels. **Results:** The main morphology of ovarian cancer was irregular, with solid lesions and visible septal changes and wall nodules. After enhancement, the septal or parietal nodules also significantly enhanced, accompanied by abdominal effusion, peritoneal metastasis, and lymph node metastasis. Serum CEA (66.33±6.54) g/ml, CA199 (185.03±20.71) U/ml, CA125 (224.62±23.82) U/ml. The results of univariate analysis showed that patients with ovarian cancer wall nodules, peritoneal metastasis, and lymph node metastasis had statistically significant differences in serum CEA, CA199, and CA125 concentrations ($P<0.05$). Pearson's results showed that wall nodules, peritoneal metastasis, and lymph node metastasis were positively correlated with serum CEA, CA199, and CA125 levels, respectively ($P<0.05$). **Conclusion:** Ovarian cancer MRI has certain characteristics related to CEA, CA199, CA125 concentrations, which can be used to diagnose the prognosis of ovarian cancer.

INTRODUCTION

Ovarian cancer is one of the three major gynecological malignancies, with the incidence second only to cervical cancer and uterine body cancer, and the mortality ranking first among gynecological malignancies⁽¹⁾. Ovarian cancer patients have a concealed early onset, no obvious specific symptoms, and lack of early diagnosis methods, resulting in more than 65% of patients being diagnosed as advanced⁽²⁾. Only 25% of patients were diagnosed at stage I, and their 5-year survival rate was 95%, while the 5-year survival rate of patients with stage III and IV ovarian cancer was only 20% - 25%⁽³⁾. Surgery combined with chemoradiotherapy is the main treatment of ovarian cancer, but the effective rate of treatment for patients with advanced ovarian cancer combined with lymph node metastasis, peritoneal metastasis and other patients is not significant, which can only reduce the pain of patients and prolong the survival time, and its prognosis effect is poor, and the long-term survival rate is reduced⁽⁴⁾. At present, serum tumor markers can assist the diagnosis and prognosis monitoring of ovarian cancer, and can identify the pathological types of tumors to a certain extent⁽⁵⁾.

Carcinoembryonic Antigen (CEA) is a widely used

tumor marker in tumor diagnosis, and its elevated levels are often associated with various malignant tumors^(6,7). CEA is a polysaccharide protein complex originally discovered in colon cancer and fetal intestinal tissue⁽⁸⁾. During the fetal period, CEA levels are higher, but they significantly decrease with postnatal serum levels⁽⁹⁾. However, in many malignant tumors, the level of CEA increases. The continuous increase in CEA levels indicates the presence of potential metastasis and residual tumors in patients⁽¹⁰⁾. CEA has good stability and can be used for tumor screening and disease prognosis evaluation. Carbohydrate antigen 199 (CA199) is a tumor marker, which is mainly used for the diagnosis and monitoring of pancreatic cancer, colorectal cancer, gallbladder cancer, bile duct cancer and other diseases⁽¹¹⁾. In ovarian cancer, the positive rate of CA199 is about 80% or more, but other gynecological tumors, digestive tract tumors, lung cancer, etc. also have a certain positive rate, which can be comprehensively judged by combining other examination results and clinical manifestations⁽¹²⁻¹³⁾. There is a certain correlation between changes in CA199 levels and the development and prognosis of the disease, which can to some extent indicate the staging, pathological type, and differential diagnosis of benign and malignant ovarian cancer^(14, 15). The

carbohydrate antigen 125 (CA125) antigen is located on a high molecular weight glycoprotein (200-1000KD) and is present in cell culture media and serum⁽¹⁶⁾. The structure of CA125 antigen-determined cluster proteins depends on the glycosylation of side chains. The detection rate of CA125 is higher in the serum of patients with non mucin ovarian tumors originating from epithelial cells⁽¹⁷⁾. On the contrary, CA125 serum expression levels are lower in epithelial cells of normal ovaries (adults and fetuses). According to the Diagnosis and Treatment Guidelines for Ovarian Cancer (2022 Edition)⁽¹⁸⁾, serum CA125 is a tumor marker with high application value in ovarian epithelial cancer, which can be used for auxiliary diagnosis, efficacy monitoring, and recurrence monitoring of ovarian cancer⁽¹⁹⁾. CA125 has a high positivity rate, especially in serous cancer, and has become the preferred tumor marker for serous cancer. The positive rate of CA125 is closely related to tumor staging and histological type⁽²⁰⁾. The positive rate of early ovarian cancer is about 43.5% to 65.7%, while the positive rate of late ovarian cancer is as high as 84.1%, making CA125 an important monitoring indicator for ovarian cancer diagnosis^(21, 22). In summary, CA125, as a tumor marker, has important value in the diagnosis, treatment, and monitoring of ovarian cancer^(23, 24). However, there is also an increase in CA125 in patients with other types of cancer, so in clinical application, it is necessary to make a comprehensive judgment based on the results of other tests^(25, 26).

Magnetic resonance imaging (MRI) is an effective imaging method for tumor staging to understand the tumor location, tumor diameter, morphology and whether there is surrounding metastasis of ovarian cancer^(27, 28). Crombé *et al.*⁽²⁹⁾ showed that MRI examination can clearly show the imaging characteristics of ovarian cancer and accurately judge the tumor stage. Zhu *et al.*⁽³⁰⁾ showed that MRI combined with serum human epididymal protein 4 (HE4), cytoplasmic thymidine kinase (TK1), carbohydrate antigen 199 (CA199) detection can improve the diagnostic efficiency of ovarian cancer, so MRI imaging features may be related to the level of serum tumor markers. Therefore, this paper studies the relationship between MRI characteristics and CEA, CA199, CA125. The report is as follows.

MATERIALS AND METHODS

General information

A retrospective analysis was made on 85 patients with ovarian cancer diagnosed by postoperative pathological results in our hospital from January 2022 to October 2023. The average age of the patients was (52.36±6.54) years. Inclusion criteria: ① Meet the relevant diagnostic criteria in the guidelines

for the diagnosis and treatment of ovarian malignant tumors (2021 version) prepared by the gynecological tumor Professional Committee of the China anticancer association; ② The diagnosis was confirmed by MRI imaging, surgical pathological results, laboratory serum tumor markers and other means; ③ Initial diagnosis. Exclusion criteria: ① With contraindications to MRI examination; ② Without birth control ring; ③ With other gynecological diseases, such as infection; ④ Had previous ovarian surgery; ⑤ With systemic malignant tumor; ⑥ With heart, liver, kidney and other important organ dysfunction; ⑦ Complicated with endocrine system diseases; ⑧ With mental diseases; ⑨ With immune system diseases; ⑩ Patients whose surgical pathological results cannot be confirmed or whose image quality does not meet the diagnostic criteria.

Detection of serum tumor markers

After all patients were admitted to the hospital, 5ml of fasting venous blood was collected, left to stand for 30min without anticoagulant, centrifuged for 5min, and the supernatant was stored in a -80 °C refrigerator. The Architect i2000sr fully automatic immunoassay analyzer produced by Abbott Laboratories in the United States was used to detect CEA, CA199, and CA125 levels using chemiluminescence immunoassay. All reagent kits were purchased with original imported reagents, and the operating procedures were strictly in accordance with the instructions of the reagent kit⁽³¹⁾.

MRI examination method

The patient should be prepared for the intestinal tract before the examination, take the supine position during the examination, and accept MRI scan after calm breathing. MRI scanning: the scanning range is above the bilateral iliac bones, bilateral groins, and the body phased array coil of MRI imaging system (manufacturer: GE company model: discovery 3.0T MRI). After plain scanning, intravenous injection of Gd DTPA 0.1 mmol/kg contrast agent (produced by MEDTRON company) was performed, and axial thin layer scanning was performed on the fat suppression sequence⁽³²⁾.

Image analysis

Two imaging diagnosticians analyzed MRI images, including the location of epithelial ovarian cancer (left, right, bilateral), boundary (clear / unclear), density / signal, morphology [(round / quasi round / oval) / lobulated / irregular morphology], lesion composition (pure cystic / cystic solid / solid), enhancement degree (obvious enhancement / mild moderate enhancement), mural nodules (yes / no), septation (yes / no), peritoneal effusion (yes / no), peritoneal metastasis (yes / no), lymph node metastasis (yes / no) (figure 1).

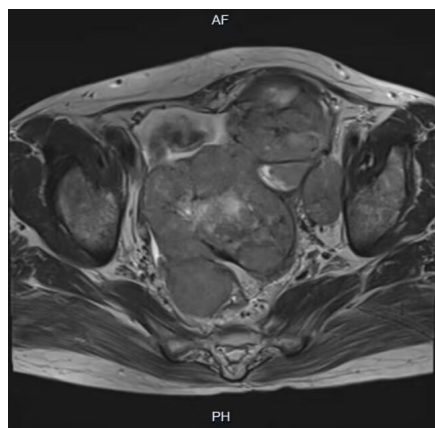


Figure 1. MRI features of ovarian cancer.

Statistical methods

EpiData software was applied to establish the database, and the accuracy of data input was ensured by parallel input of two people. The collected data were statistically analyzed by SPSS 26.0 software, and the measurement data were analyzed by $\bar{x} \pm s$ and t test; The count data were expressed by frequency or percentage and χ^2 test. Pearson correlation coefficient was used to test the correlation between MRI, CT impact characteristics and serum tumor marker levels, with $P < 0.05$ indicating statistical difference.

RESULTS

MRI characteristics and CEA, CA199, CA125 levels

In 85 patients with ovarian cancer, the location: left side in 26 cases, right side in 28 cases, bilateral in 31 cases; Density / signal: 43 cases had mixed density / signal, 42 cases had basically the same density / signal; Boundary: clear in 43 cases, unclear in 42 cases; Morphology: round / quasi round / oval in 29 cases, lobulated in 24 cases, irregular in 32 cases; The lesion components were pure cystic in 24 cases, cystic solid in 29 cases, and solid in 32 cases; The degree of enhancement: 40 cases were significantly enhanced, 45 cases were mild to moderate enhanced; There were 61 mural nodules and 24 mural nodules; 46 cases were separated and 39 cases were not separated; There were 52 cases with ascites and 33 cases without ascites; There were 16 cases with peritoneal metastasis and 59 cases without peritoneal metastasis; There were 17 cases with lymph node metastasis and 68 cases without lymph node metastasis. Among them, serum CEA (66.33 ± 6.54) g / ml, CA199 (185.03 ± 20.71) U / ml, CA125 (224.62 ± 23.82) U / ml.

Relationship between MRI features and serum CEA, CA199, CA125 concentrations

The results showed that CEA, CA199 and CA125 levels were different, as shown in table 1. Variable assigned for correlation between MRI imaging characteristics of ovarian cancer and serum CEA, CA199, CA125 concentrations is shown in table 2.

Correlation between MRI features and serum CEA, CA199, CA125 concentrations

The correlation coefficient results in table 3 showed positive correlations between mural nodules, peritoneal metastasis and lymph node metastasis with CEA, CA199 and CA125, while other indicators were not significantly correlated (table 3). Scatter plot of correlation between wall nodules, peritoneal metastasis, lymph node metastasis and serum CEA, CA199, and CA125 levels is shown in figure 2.

DISCUSSION

Ovarian cancer is a common gynecological malignant tumor, which is one of the malignant tumors threatening the life safety of women⁽³³⁾. Ovarian cancer is mostly treated by surgery, but due to the high-grade ovarian cancer with strong clarity, rapid progress and rapid diffusion, postoperative radiotherapy or chemotherapy is required. Therefore, early diagnosis of serum tumor markers combined with imaging technology before and after treatment is particularly important to understand tumor stage and prognosis MRI technology can clearly show the differences between normal anatomical characteristics and lesion areas in the ovary through multi angle and multi plane imaging, and has unique advantages for the qualitative and localization of ovarian cancer. MRI technology tissue has high resolution, can clearly show the location and signal changes of the lesions, and can obtain the information of whether the mass, tissue and surrounding organs have adhesions through it, which can provide important value for tumor treatment⁽³⁴⁾. Tumor markers can identify the biological and chemical substances in tumors. Serum tumor markers may not exist in normal adult tissues, but only in embryonic tissues, but the content level in tumor tissues is much higher than that in normal tissues. The presence and level changes of serum tumor markers can suggest the nature of tumor, and then preliminarily understand the cell differentiation and cell function of tumor tissue⁽³⁵⁾.

At present, the serum tumor markers associated with tumors are mainly CEA, CA199, CA125, etc. CEA has a complex structure and is a soluble glycoprotein. It mainly exists in the pancreas, liver and gastrointestinal tract of the fetus during the embryonic period, but the CEA level is significantly reduced after birth. CA199 was proposed by Delvillano in 1983. CA199 can be expressed in normal pancreatic ductal epithelium, and its significance in the diagnosis of pancreatic cancer is described. When the ductal epithelium has cancerous lesions, it activates and regulates the expression of mucin genes, and the serum concentration of CA199 increases. Tumor cells block the CA199 secretion pathway, such as small pancreatic duct, pancreatic duct, etc., and a large number of CA199 factors enter

the matrix around the cancerous lesion, enter the blood circulation, and then lead to the increase of CA199 content in the blood, so CA199 is used as the preferred serological indicator for pancreatic cancer detection (36). CA125 is a high molecular glycoprotein. Previous research results showed that 85% of serous ovarian cancer patients had elevated serum CA125 concentration, 36% of undifferentiated ovarian cancer and 12% of mucinous ovarian cancer patients had high expression of CA125 (37). At present, CA125 is the most widely used tumor marker for epithelial

ovarian cancer in clinic, which is used for monitoring treatment effect evaluation and prognosis judgment, and its practicability has been confirmed by a large number of studies. For patients with ovarian cancer, after surgical resection and chemoradiotherapy, the CA125 level is significantly reduced, but the continuous increase of CA125 level predicts the residual, recurrence and deterioration of tumor tissue after surgery. However, due to its low specificity, CA125 detection alone cannot identify the nature of ovarian lesions.

Table 1. Relationship between MRI characteristics and CEA, CA199, CA125 levels (X±s).

Pathological features	n=85	CEA (ng/ml)	t/F	P	CA199 (u/ml)	t/F	P	CA125 (u/ml)	t/F	P
Age of years			1.367	0.175		0.286	0.776		0.365	0.716
<60	49	63.21 ± 6.14			183.98 ± 19.86			219.62 ± 21.26		
>61	36	61.29 ± 6.74			185.21 ± 19.25			221.29 ± 20.19		
Tumor staging			0.441	0.661		0.108	0.915		0.211	0.833
Stage I-II	45	64.59±5.49			182.86±17.59			221.9±20.2		
Stage III-IV	40	65.11±5.36			183.24±14.59			222.8±21.3		
position			0.837	0.437			0.872	0.422	0.785	0.460
left side	26	65.41 ± 6.28			181.68±19.86			221.0±22.69		
Right side	28	65.87 ± 5.83			184.01±18.58			223.5±22.38		
bilateral	31	67.52 ± 7.34			188.75±23.2			228.7±25.85		
Density / signal			0.007	0.994			0.029	0.977	0.060	0.953
Mixed density / signal	43	66.34 ± 6.74			185.09±22.24			224.79±24.7		
The density / signal is basically the same	42	66.33 ± 6.41			184.96±19.28			224.46±23.24		
boundary			1.109	0.271			0.961	0.339	1.300	0.197
clear	43	65.56 ± 7.40			182.89±24.50			221.3±27.55		
Unclear	42	67.13 ± 5.49			187.21±15.93			228.0±19.03		
form			0.801	0.452			0.608	0.547	0.821	0.444
Circle / quasi circle / ellipse	29	65.30 ± 7.60			181.82±22.52			220.8±27.63		
Lobulated	24	67.59 ± 5.31			188.05±15.61			229.2±17.27		
Irregular shape	32	66.32 ± 6.37			185.56±22.49			224.7±24.43		
Lesion composition			2.773	0.068			0.319	0.728	0.252	0.778
Pure cystic	24	66.28 ± 7.29			183.45±21.61			223.4±25.36		
Cystic solid	29	66.02 ± 5.71			183.77±16.53			223.0±20.58		
Substantiality	32	62.66 ± 6.83			187.35±23.65			227.0±25.85		
Strengthening degree			1.128	0.263			1.014	0.314	1.246	0.216
Significantly enhanced	40	67.18 ± 6.27			187.44±21.71			228.0±22.87		
Mild moderate enhancement	45	65.58 ± 6.75			182.88±19.77			221.6±24.49		
Mural nodule			7.086	0.000			6.646	0.000	7.156	0.000
yes	61	68.89 ± 5.23			192.85±17.07			234.2±18.10		
no	24	59.84 ± 4.84			165.13±15.16			200.2±18.77		
separate			0.616	0.540			0.431	0.668	0.395	0.694
yes	46	66.74 ± 6.96			185.92±20.10			225.6±24.96		
no	39	65.86 ± 6.06			183.97±21.62			223.5±22.68		
Ascites			0.649	0.518			0.812	0.419	0.718	0.475
yes	52	66.68 ± 5.43			186.48±18.79			226.1±20.3		
no	33	65.79 ± 8.05			182.73±23.53			222.3±28.65		
peritoneal carcinomatosis			8.060	0.000			7.369	0.000	6.844	0.000
yes	16	75.28±4.22			211.91±17.77			254.2±17.19		
no	69	64.26 ± 5.07			178.79±15.83			217.8±19.57		
Lymph node metastasis			4.596				3.954	0.000	4.088	0.002
yes	17	72.19 ± 5.54			201.42±16.20			244.0±17.80		
no	68	64.87 ± 5.95			180.93±19.74			219.8±22.73		

Note: CEA: Serum carcinoembryonic antigen; CA199: Carbohydrate antigen 199; CA125: Carbohydrate Antigen 125.

Table 2. Variable assignment table.

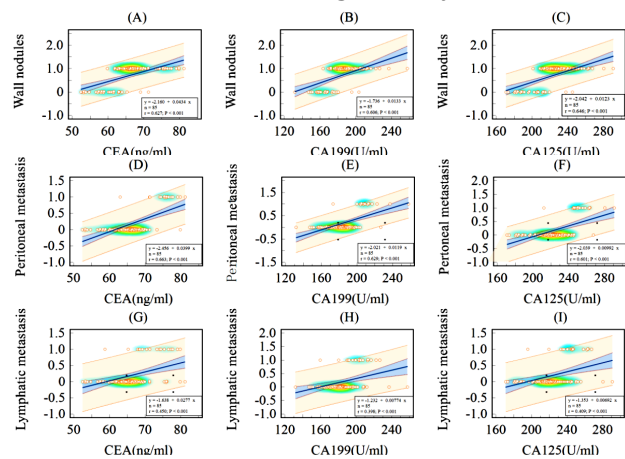
Factor	Variable assignment
Position	Left=0; Right side=1; Bilateral=2
Density / Signal	Mixed density / Signal=0; Density / Signal basically consistent=1
Boundary	Clarity=0; Unclear=1
Form	Circle / Quasi circle / Ellipse=0; Lobulated=1; Irregular shape=2
Lesion composition	Reality=0; Pure cystic 1; Cystic solid=2
Strengthening degree	Significantly enhanced=0; Mild moderate enhancement =1
Mural nodule	Yes=1, no=0
Separate	Yes=1, no=0
Ascites	Yes=1, no=0
peritoneal carcinomatosis	Yes=1, no=0
Lymph node metastasis	Yes=1, no=0
CEA	Raw data input
CA199	Raw data substitution
CA125	Raw data input

Table 3. Correlation between MRI imaging characteristics of ovarian cancer and serum CEA, CA199, CA125 concentrations.

Project	CEA		CA199		CA125	
	R	P	R	P	R	P
Position	0.134	0.221	0.142	0.196	0.133	0.225
Density / Signal	0.000	0.997	-0.033	0.977	-0.007	0.952
Boundary	0.120	0.272	0.105	0.339	0.141	0.197
Form	0.063	0.565	0.077	0.486	0.066	0.547
Strengthening Degree	-0.123	0.263	-0.111	0.314	-0.136	0.216
Mural nodule	0.627	0.000	0.606	0.000	0.646	0.000
Separate	0.068	0.539	0.047	0.667	0.043	0.694
Ascites	0.067	0.542	0.089	0.419	0.078	0.475
Peritoneal carcinomatosis	0.663	0.000	0.629	0.000	0.601	0.000
Lymph node metastasis	0.450	0.000	0.398	0.000	0.409	0.000

In this study, the main morphology of ovarian cancer is mainly irregular, and the lesions are mostly solid. It is presumed that the ovarian cancer patients included in this study have a high degree of differentiation. At the same time, septal changes and mural nodules can be seen, accompanied by peritoneal effusion, peritoneal metastasis and lymph node metastasis, which is similar to the Research Report of Takami *et al.* (38). In Moro *et al.* (39), MRI imaging showed that the greater the degree of signal enhancement, the more obvious the lesion enhancement, and the closer the tumor stage was to the advanced stage. In this study, MRI showed that after enhancement, septal or mural nodules showed an enhancement trend, suggesting that ovarian cancer staging can be identified by the degree of image enhancement. Mural nodules are the imaging characteristics of ovarian cancer. The occurrence of mural nodules predicts that the lesion is more likely to be malignant, and the higher the degree of deterioration. In addition, this study also found that patients with advanced ovarian cancer were often accompanied by peritoneal effusion, lymph node and peritoneal metastasis, which also reflected the

deterioration of ovarian cancer. The results showed that serum CEA (66.33±6.54) g/ml, CA199 (185.03±20.71) U/ml, CA125 (224.62±23.82) U/ml. It is suggested that different imaging features have a certain correlation with the level of serum tumor markers, and the joint detection has a certain value. According to the results of Sanna *et al.* (40), the combined detection of serum tumor markers can effectively improve the early diagnosis rate of ovarian cancer. The results of Li *et al.* (41) showed that MRI combined with serum tumor markers detection improved the diagnostic efficiency of malignant ovarian cancer and reduced the rate of missed diagnosis and misdiagnosis. This study found positive correlations between mural nodules, peritoneal metastasis and lymph node metastasis with CEA, CA199 and CA125, while other indicators were not significantly correlated, indicating that MRI examination of cancer showed mural nodules, peritoneal metastasis, lymph node metastasis and other imaging signs, and their serum CEA, CA199 CA125 levels will increase significantly.

**Figure 2.** (A-I) Scatter plot of correlation between wall nodules, peritoneal metastasis, lymph node metastasis and serum CEA, CA199, and CA125 levels.

Note: (A-C) indicates a positive correlation between wall nodules and levels of CEA, CA199, and CA125; (D-F) shows a positive correlation between peritoneal metastasis and levels of CEA, CA199, and CA125; (G-I) indicates a positive correlation between lymph node metastasis and CEA, CA199, and CA125 levels.

CONCLUSION

Based on the comprehensive research results, MRI imaging features and serum biomarkers had potential clinical application value in the diagnosis and prognosis evaluation of ovarian cancer. However, it should be noted that this study has some limitations, such as retrospective study design and relatively small sample size. Future research can further expand the sample size and adopt more rigorous research designs to validate the findings of this study and explore deeper correlations. Overall, this study provides valuable information for the clinical diagnosis and treatment of ovarian cancer, as

well as valuable insights for further research.

Funding: None.

Conflict of interests: The authors declare no conflict of interests.

Ethical consideration: All methods were carried out in all institutions under the ethical principles of Good Clinical Practice and in accordance with the Declaration of Helsinki. Patient participation in the database received approval by the institutional review board of all institutions of The First People's Hospital of Zunyi (No: FPHZY202109). All subjects provided informed consent for participation in the database.

Authors Contribution: X.L., research experiment: correlation between magnetic resonance imaging (MRI) imaging characteristics and serum markers carcinoembryonic antigen (CEA), carbohydrate antigen 199 (CA199), and carbohydrate antigen 125 (CA125) levels in ovarian cancer patients. S.X., analyzed the data and D.M. and M.P. helped with the constructive discussion. X.L., S.X., D.M. and M.P. made great contributions to manuscript preparation.

REFERENCES

- Sadowski EA, Thomassin-Naggara I, Rockall A, Maturen KE, Forstner R, Jha P, et al. (2022) O-RADS MRI risk stratification system: Guide for assessing Adnexal lesions from the ACR O-RADS committee. *Radiology*, **303**(1): 35-47.
- Tang T, Lai H, Huang X, Gu L, Shi H (2021) Application of serum markers in diagnosis and staging of ovarian endometriosis. *J Obstet Gynaecol Res*, **47**(4): 1441-50.
- Cheng X and Fang Q (2022) Thigh muscle MRI Edema Features of dermatomyositis patients with ovarian cancer: A report of three cases. *Cureus*, **14**(4): e24337.
- Fang M, Huang S, Dong J, Yan H, Fang X, Zhang P, et al. (2022) A preliminary exploration using imaging methods to predict the possibility of the recurrence of serous ovarian cancer in Patients undergoing total resection. *Front Oncol*, **12**: 754067.
- Fu M, Solovey K, Salzman O, Alterovitz R (2023) Toward certifiable optimal motion planning for medical steerable needles. *Int J Rob Res*, **42**(10): 798-826.
- Kelleher M, Singh R, O'Driscoll CM, Melgar S (2019) Carcinoembryonic antigen (CEACAM) family members and inflammatory bowel disease. *Cytokine Growth Factor Rev*, **47**: 21-31.
- Götz L, Rueckschloss U, Balk G, Pfeiffer V, Ergün S, Kleefeldt F (2023) The role of carcinoembryonic antigen-related cell adhesion molecule 1 in cancer. *Front Immunol*, **14**: 1295232.
- Li L, Guo C, Wan JL, Fan QS, Xu XL, Fu YF (2022) The use of carcinoembryonic antigen levels to predict lung nodule malignancy: a meta-analysis. *Acta Clin Belg*, **77**(1): 227-32.
- Liu Y, Du Z, Ji J, Li J, Bi D, Tang F (2020) Bidirectional association between serum carcinoembryonic antigen and metabolic syndrome among the Chinese male population: two cohort studies. *Lipids Health Dis*, **19**(1): 233.
- Hall C, Clarke L, Pal A, Buchwald P, Eglinton T, Wakeman C, et al. (2019) A review of the role of carcinoembryonic antigen in clinical practice. *Ann Coloproctol*, **35**(6): 294-305.
- Shibata C, Nakano T, Yasumoto A, Mitamura A, Sawada K, Ogawa H, et al. (2022) Comparison of CEA and CA19-9 as a predictive factor for recurrence after curative gastrectomy in gastric cancer. *BMC Surg*, **22**(1): 213.
- Silveira MJ, Martins C, Cruz T, Castro F, Amorim-Costa Â, Chester K, et al. (2023) scFv biofunctionalized nanoparticles to effective and safe targeting of CEA-expressing colorectal cancer cells. *J Nanobiotechnology*, **21**(1): 357.
- Pian G, Shin JS, Yoon S, Oh SY (2021) Prognostic reappraisal of postoperative carcinoembryonic antigen in T1-2N0 colorectal cancer. *Anticancer Res*, **41**(2): 1101-10.
- Luo G, Jin K, Deng S, Cheng H, Fan Z, Gong Y, et al. (2021) Roles of CA19-9 in pancreatic cancer: Biomarker, predictor and promoter. *Biochim Biophys Acta Rev Cancer*, **1875**(2): 188409.
- Qing X, Liu L, Mao X (2022) A clinical diagnostic value analysis of serum CA125, CA199, and HE4 in women with early ovarian cancer: Systematic review and meta-analysis. *Comput Math Methods Med*, **2022**: 9339325.
- Lu Y, Yu H, Qin S, Chen M, Chen H, Hu Z, et al. (2020) Single and combined use of preoperative inflammatory biomarkers and CA199 in Diagnosing pancreatic cancer. *Clin Lab*, **66**(11): 2197-2204.
- Jiang Q, Qian H, Mei L, Sun Q, Cheng X, Huang W, et al. (2022) Effect of bevacizumab plus paclitaxel and carboplatin regimen on prognostic survival of ovarian cancer patients. *Am J Transl Res*, **14**(12): 8761-7.
- Jiao X, Peng T, Liang Z, Hu Y, Meng B, Zhao Y, et al. (2022) Lateral flow immunoassay based on time-resolved fluorescence microspheres for rapid and quantitative screening CA199 in human serum. *Int J Mol Sci*, **23**(17): 9991.
- Huang D, Lin Q, Song J, Xu B (2021) Prognostic value of pretreatment serum CA199 in patients with locally advanced rectal cancer treated with CRT followed by TME with normal pretreatment carcinoembryonic antigen levels. *Dig Surg*, **38**(1): 24-9.
- Shuang T, Wang Y, Zhao L, Zhang K, Yin P, Guo L, et al. (2022) Extremely high serum CA19-9 level along with elevated D-dimer in assisting detection of ruptured ovarian endometriosis. *Ann Med*, **54**(1): 1444-51.
- Guo B, Lian W, Liu S, Cao Y, Liu J (2019) Comparison of diagnostic values between CA125 combined with CA199 and ultrasound combined with CT in ovarian cancer. *Oncol Lett*, **17**(6): 5523-8.
- Chen J, Fan L, Yang Z, Yang D (2024) Comparison of results and age-related changes in establishing reference intervals for CEA, AFP, CA125, and CA199 using four indirect methods. *Pract Lab Med*, **38**: e00353.
- Zhou D, Fan X, Xie S, Lu M, Gao L, Zhang R, et al. (2024) Clinical application of serum CST4 combined with tumor markers in the diagnosis of digestive system malignant tumors. *Oncol Lett*, **28**(2): 384.
- Sachan A, Saluja SS, Nekarakanti PK, Nimisha, Mahajan B, Nag HH, et al. (2020) Raised CA19-9 and CEA have prognostic relevance in gallbladder carcinoma. *BMC Cancer*, **20**(1): 826.
- Mie T, Ozaka M, Okamoto T, Takeda T, Ushida Y, Mori C, et al. (2022) CA19-9 reduction after 4 months of treatment is a prognostic factor for locally advanced pancreatic cancer. *In Vivo*, **36**(6): 2844-51.
- Hou S, Jing J, Wang Y, Du L, Tian B, Xu X, et al. (2023) Evaluation of clinical diagnostic and prognostic value of preoperative serum carcinoembryonic antigen, CA19-9, and CA24-2 for colorectal cancer. *Altern Ther Health Med*, **29**(6): 192-7.
- Rosiek V, Wójcik-Giertuga M, Kos-Kudła B (2022) Serum tumor markers for detection of bone metastases in patients with lung neuroendocrine neoplasms. *Cancer Treat Res Commun*, **31**: 100533.
- Pedrazzoli P, Rosti G, Soresini E, Ciani S, Secondino S (2021) Serum tumor markers in germ cell tumours: From diagnosis to cure. *Crit Rev Oncol Hematol*, **159**: 103224.
- Crombè A, Gauquelin L, Nougaret S, Chicart M, Pulido M, Floquet A, et al. (2021) Diffusion-weighted MRI and PET/CT reproducibility in epithelial ovarian cancers during neoadjuvant chemotherapy. *Diagn Interv Imaging*, **102**(10): 629-39.
- Zhu C, Zhang N, Zhong A, Xiao K, Lu R, Guo L (2022) A combined strategy of TK1, HE4 and CA125 shows better diagnostic performance than risk of ovarian malignancy algorithm (ROMA) in ovarian carcinoma. *Clin Chim Acta*, **524**: 43-50.
- Lee JH (2019) The feasibility of serum multiple tumor markers test between patients with primary pancreatic cancer and those with benign pancreatic cystic disease. *Clin Lab*, **65**(10): 1859-1866.
- Touska P and Connor S (2021) New and Advanced magnetic resonance imaging diagnostic imaging techniques in the evaluation of cranial nerves and the skull base. *Neuroimaging Clin N Am*, **31**(4): 665-84.
- Caredda G, Bassareo PP, Cau R, Mannelli L, Suri JS, Saba L (2022) Emerging role of cardiac magnetic resonance imaging in diagnosing myocarditis: A blunder or the way to get the problem sorted. *J Thorac Imaging*, **37**(2): W12-12W27.
- Jamilian M, Mansury S, Bahmani F, Heidar Z, Amirani E, Asemi Z (2018) The effects of probiotic and selenium co-supplementation on parameters of mental health, hormonal profiles, and bi-

- omarkers of inflammation and oxidative stress in women with polycystic ovary syndrome. *J Ovarian Res*, **11**(1): 80.
35. Desai S and Guddati AK (2023) Carcinoembryonic antigen, carbohydrate antigen 19-9, cancer antigen 125, prostate-specific antigen and other cancer markers: a primer on commonly used cancer markers. *World J Oncol*, **14**(1): 4-14.
 36. Yoshida R (2021) Hereditary breast and ovarian cancer (HBOC): review of its molecular characteristics, screening, treatment, and prognosis. *Breast Cancer*, **28**(6): 1167-80.
 37. Bezerra R, Recchimuzzi DZ, Dos Santos Mota MM, Garcia M, de Menezes MR, Mazo PE, et al. (2019) Whole-body magnetic resonance imaging in the oncology setting: an overview and update on recent advances. *J Comput Assist Tomogr*, **43**(1): 66-75.
 38. Takami H, Graffeo CS, Perry A, Giannini C, Nakazato Y, Saito N, et al. (2023) Impact of tumor markers on diagnosis, treatment and prognosis in CNS germ cell tumors: correlations with clinical practice and histopathology. *Brain Tumor Pathol*, **40**(2): 124-32.
 39. Moro F, Bertoldo V, Avesani G, Moruzzi MC, Mascilini F, Bolomini G, et al. (2021) Fusion imaging in preoperative assessment of extent of disease in patients with advanced ovarian cancer: feasibility and agreement with laparoscopic findings. *Ultrasound Obstet Gynecol*, **58**(6): 916-25.
 40. Sanna E, Tanca L, Cherchi C, Gramignano G, Oppi S, Chiai MG, et al. (2021) Decrease in Neutrophil-to-lymphocyte ratio during neoadjuvant chemotherapy as a predictive and prognostic marker in advanced ovarian cancer. *Diagnostics*, **11**(7): 1298.
 41. Sussman D and Tannenbaum E (2023) Diffusion-weighted magnetic resonance imaging and morphological characteristics evaluation for outcome prediction of primary debulking surgery for advanced high-grade serous ovarian carcinoma. *J Magn Reson Imaging*, **57**(5): 1350-1.

