

Using ultrasound-guided fine needle aspiration cytology with ultrasound to diagnose benign and malignant thyroid nodules

J.F. Liu, J. Qian, J. Ma, H.X. Tang, J.X. Ding, Y.Y. Tong*

Ultrasound Department, Tongling Municipal Hospital, Tongling, Anhui Province, China

ABSTRACT

► Original article

*Corresponding author:

Yanyan Tong, M.D.,

E-mail:

13965238978@163.com

Received: February 2024

Final revised: August 2024

Accepted: October 2024

Int. J. Radiat. Res., July 2025;
23(3): 607-612

DOI: 10.61186/ijrr.23.3.14

Keywords: Thyroid nodules, ultrasound-guided FNAC, benign and malignant, diagnostic accuracy, ROC curve analysis.

Background: Thyroid nodules are common and can be benign or malignant. Ultrasound-guided fine needle aspiration cytology (USG-guided FNAC) is a new method for differentiating these nodules, but previous studies have yet to provide consistent conclusions. The aim of the study was to explore the effectiveness of USG-guided FNAC combined with ultrasonography in diagnosing benign and malignant thyroid nodules. **Materials and Methods:** The study involved 87 patients who underwent thyroid ultrasound and USG-guided FNAC. The results were compared with surgical and pathological findings, and the diagnostic efficiency was analyzed using ROC curves. **Results:** Among the 87 thyroid nodules, 22 were malignant, and 53 were benign. USG-guided FNAC alone diagnosed 34 malignant and 58 benign cases, while the combined method diagnosed 25 malignant and 63 benign cases. The ROC curve analysis showed that the combined method had a higher area under the curve (AUC) compared to ultrasound or FNAC alone, indicating better diagnostic accuracy. **Conclusion:** Combining USG-guided FNAC with ultrasound improves the sensitivity of preoperative differential diagnosis of benign and malignant thyroid nodules.

INTRODUCTION

Thyroid nodules have been the most common thyroid disease in clinics in recent years. TN is primarily benign, such as thyroid tumors and thyroid nodules, but it can also lead to some malignant diseases, such as thyroid cancer and lymphoma⁽¹⁻³⁾. According to pathological classification, thyroid carcinoma can be divided into Papillary carcinoma (PTC), Follicular carcinoma (FTC), medullary carcinoma (MTC) and Undifferentiated carcinoma (ATC)^(4,5). PTC is the most common clinical subtype, but its prognosis is good⁽⁶⁾. With the rapid development of ultrasound imaging, the incidence of thyroid cancer has risen significantly, by 200% to 300% in China, and is the highest of all types of cancer. This is mainly because there are no obvious clinical symptoms and signs in the early stage of thyroid cancer, and it is easy to miss diagnosis^(7,8), which makes the treatment of thyroid cancer a controversial issue. The diagnosis and treatment of TN are essential.

The incidence of thyroid nodules is 4-8%, of which the incidence of malignant lesions is less than 1%. However, the diagnosis of thyroid nodules is not satisfactory⁽⁹⁾. The statistical results show that the diagnosis rate of thyroid nodules before clinical operation is less than 50%, and most of the patients

are in the middle and late stage of the disease after diagnosis, which brings great difficulties to the treatment and prognosis of patients⁽¹⁰⁾. At present, with the enhancement of people's awareness of self-protection and safety, many people have regular physical check-ups every year, and thyroid examinations have been paid more and more attention^(11,12). There are many methods for the diagnosis of thyroid nodules, including palpation, ultrasound imaging, fine needle puncture (FNA) and surgical thyroidectomy⁽¹³⁾. The advantages and disadvantages of palpation are apparent, and palpation is convenient and straightforward, but the diagnosis only depends on the subjective opinion of clinicians. Palpation is only an auxiliary physical examination in clinical work. FNA has a small scope of trauma, high specificity, and sensitivity. It is used to differentiate benign and malignant thyroid nodules before the operation. However, the failure rate of FNA puncture is high, with tiny thyroid nodules and multiple thyroid nodules, making it difficult to obtain biopsy tissue, thus affecting the diagnosis and later treatment of clinicians^(14,15). In addition to the high risk of thyroidectomy, the postoperative damage to physical function can be accompanied by a variety of complications that can seriously affect the patient's quality of life and prognosis^(16,17).

Thyroid ultrasound (US) has been used as the

primary diagnostic technique to evaluate thyroid nodules. A Thyroid nodule is very common, and most of them are benign. A few are malignant, so we need a rapid and straightforward method to distinguish and evaluate benign and malignant thyroid nodules, which is necessary to improve the utilization of resources^(18, 19). Because of its excellent spatial and temporal resolution, the US has become the first tool for thyroid imaging examination, especially for asymptomatic and palpable thyroid cancer^(20, 21). In fact, it is now recommended that all patients with suspected thyroid nodules (with local symptoms, thyroid palpation abnormalities, thyroid dysfunction, etc.) be examined by ultrasound^(22, 23). The US is the primary tool for initial cancer risk stratification of thyroid nodules, which is used to determine the characteristics of thyroid nodules further, provide a malignant tumour risk assessment, and then decide whether to arrange fine needle aspiration biopsy based on the ultrasound results⁽²⁴⁾.

Fine needle aspiration biopsy cytology of the thyroid gland was first proposed and applied by Hayes Martin and Edward Ellis in the 1930s. They used needle 18 for the first time to perform a biopsy and cytological evaluation of thyroid lesions⁽¹⁶⁾. Until the 1950s, thyroid ultrasound-guided fine needle aspiration cytology was not proposed and applied in China and Japan, but it was widely used in clinics in the 1970s and 1980s. Thyroid fine needle aspiration cytology has been recognized as a real-time, portable, safe, cost-effective and effective diagnostic method that is widely used in clinical diagnosis and treatment, avoiding many unnecessary procedures for benign thyroid nodules^(25, 26). Ultrasound-guided fine needle puncture can observe the needle path and needle position in real time, ensure the accuracy of sampling, and avoid damage to the surrounding important tissue structures, such as the carotid artery, jugular vein, trachea and so on. Although many studies on the value of USG-guided FNAC in the diagnosis of benign and malignant thyroid nodules have been carried out in the past, there are significant differences in experimental design, sample selection criteria and observation indexes so that convincing and consistent conclusions cannot be obtained^(27, 28). Further studies are necessary to fully demonstrate the diagnostic value of USG-guided FNAC in benign and malignant thyroid nodules. Based on this, the purpose of this study is to explore the clinical value of ultrasonography combined with fine needle aspiration cytology in the diagnosis of benign and malignant thyroid nodules^(29, 30).

The novelty of this article lies in its exploration of the combined use of USG-guided FNAC and ultrasonography for diagnosing thyroid nodules. Unlike previous studies, this research provides a comprehensive analysis of the diagnostic efficiency of the combined method using ROC curves. The study demonstrates that the combined approach

significantly improves diagnostic accuracy compared to using ultrasound or FNAC alone, offering a more reliable preoperative differential diagnosis of benign and malignant thyroid nodules. This finding could lead to better clinical outcomes and more effective resource utilization in thyroid nodule management.

MATERIALS AND METHODS

Eighty-seven patients who underwent thyroid ultrasound and ultrasound-guided fine needle aspiration cytology in our hospital from September 2020 to April 2023 were selected as the study subjects. The results of the operation and pathology were taken as the gold standard for the diagnosis of the nature of thyroid nodules. There were 27 males and 60 females. The age ranged from 18 to 65 years (mean=36.32± 3.58) years. The maximum diameter of nodules was from 0.3 to 5cm (mean=2.31±1.83). The body mass index (BMI) ranged from 17.20 to 28.22kg/m²(mean=23.33 ±2.47) kg/m². All nodules were suspected to be malignant by ultrasound, and a puncture biopsy was performed, which was confirmed by operation and pathology. The indications of USG-guided FNAC refer to the white paper on classified diagnosis of thyroid nodules published by the American Society of Radiology (ACR) in 2017. This study obtained the consent of the hospital ethics committee, and all the patients signed the informed consent form for the trial.

Inclusion criteria: Thyroid nodules were pathologically examined and diagnosed. Routine ultrasound and USG-guided FNAC examination were performed before the operation. Newly treated patients.

Exclusion criteria: Patients with thyroid diseases such as hyperthyroidism or hypothyroidism. Patients with incomplete clinical data. Patients during lactation or pregnancy. Patients with unsatisfactory USG-guided FNAC or USG-guided FNAC results of unknown cellular atypical lesions or follicular lesions of unknown meaning. Patients with mental diseases and cognitive impairment. Patients participated in other clinical research at the same time.

The formula for calculating the sample size was based on equation (1):

$$n_1 = \frac{[Z_{\alpha/2}\sqrt{p(1-p)(1+c)/c} + Z_{\beta}\sqrt{p_1(1-p_1) + p_2(1-p_2)/c}]^2}{(p_1 - p_2)^2} \quad (1)$$

Bilateral α is 0.05, and β is 0.20. Moreover, the accuracy of FNAB combined with ultrasound in the diagnosis of benign and malignant thyroid nodules is taken as the effect index, and relevant literature and previous studies are consulted^(31, 32), P1=0.96, and P2=0.77. After calculation, the sample size of each group is 104 cases, and the shedding rate is 10%, with a total of 115 patients.

All patients underwent routine ultrasound

examinations using a Philips EPIQ7 with an L12-5 probe. Patients were positioned supine with their necks fully exposed. The ultrasound assessed and recorded the size, edge, shape, location, blood supply, aspect ratio, internal echo, calcification, invasion of the thyroid capsule, and the status of central and bilateral cervical lymph nodes. Images were stored dynamically in real-time once the thyroid nodule imaging was stable and the quality control indicator was steady green.

Following the ultrasound examination, all patients received ultrasound-guided fine-needle aspiration cytology (FNAC). The thyroid nodules were located via ultrasound, and samples were obtained using seven disposable syringe needles, with three punctures performed for each nodule. During the procedure, the patient's body was pierced at a 30°-60° angle along the scanning plane of the probe. Once the needle reached the target position, it was quickly inserted several times and then swiftly removed. The samples were smeared and sent to the pathology department for cytological examination.

Based on conventional ultrasound results, nodules were classified as benign or malignant using a semi-quantitative scoring method and a grade 5 method (33). Nodules graded 0 - II were defined as benign, while those graded III - IV were considered malignant. The FNAC results were classified according to the NCCN thyroid USG-guided FNAC cytological classification Bethesda System: Bethesda I indicated unsatisfactory samples, Bethesda II indicated benign lesions, Bethesda III indicated atypical cytopathies, Bethesda IV indicated follicular or suspected follicular cell tumours, Bethesda V indicated suspected malignant lesions and Bethesda VI indicated malignant lesions (34). The ultrasound image for the sample of malignant and benign nodules can be seen in figures 1 and 2.

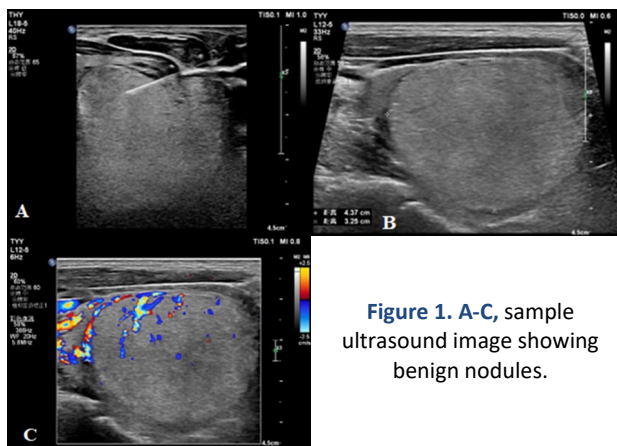


Figure 1. A-C, sample ultrasound image showing benign nodules.

Statistical analysis

The data were analyzed using SPSS22.0 statistical software, with group comparisons expressed as [n (%)]. The χ^2 test was employed to generate the receiver operating curve (ROC) to assess the diagnostic value of ultrasound, USG-guided FNAC

alone, and their combined detection for benign and malignant thyroid nodules. A P-value of <0.05 was considered statistically significant.

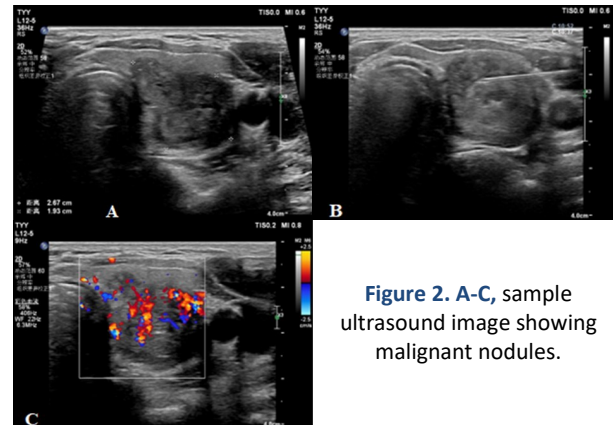


Figure 2. A-C, sample ultrasound image showing malignant nodules.

RESULTS

Postoperative pathological examination of 87 patients revealed 87 thyroid nodules, comprising 22 malignant and 53 benign cases. Among the malignant cases, there were 17 papillary thyroid adenocarcinomas, 3 follicular carcinomas, 1 medullary carcinoma, and 1 diffuse large B-cell lymphoma. The benign nodules included 44 thyroid nodules, 5 cases of Hashimoto's thyroiditis, and 4 adenomas. Thyroid ultrasound results indicated that out of the 87 nodules, 53 were malignant and 22 were benign (table 1).

Table 1. Comparison of ultrasonic diagnosis and pathological diagnosis.

Ultrasonic diagnosis	N	Pathological diagnosis		Total	χ^2	P
		Malignant	Benign			
Benign	34	22	0	22	3.792	0.052
Malignant	53	0	65	65		
Total	87	22	65	87		

The ultrasonographic diagnosis of thyroid nodules revealed that most malignant nodules exhibited hypoechoic characteristics, silent halos, solid lesions, calcifications, and irregular edges. Detailed results are presented in table 2.

The USG-guided FNAC results indicated that out of 87 patients with thyroid nodules, 58 (66.66%) were diagnosed as benign, while 34 (33.34%) were identified as malignant. Detailed results are presented in table 3.

The combined results of USG-guided FNAC and ultrasound for 87 patients with thyroid nodules indicated that 63 (72.41%) were diagnosed as benign, while 25 (28.74%) were identified as malignant. Detailed results are presented in table 4.

The ROC curve analysis revealed that the AUC values for ultrasound, USG-guided FNAC alone, and combined detection were 0.7447 (95% CI: 0.6379-0.8515), 0.8136 (95% CI: 0.7237-0.9035), and 0.8867 (95% CI: 0.8134-0.9599), respectively. The AUC for

combined diagnosis was significantly higher than for each method alone, with a statistically significant difference ($P < 0.05$, table 5). The predictive value ranking was combined detection > FNAB > ultrasound examination (figure 3).

Table 2. Ultrasonic diagnosis of thyroid nodules (n/%).

Ultrasonic manifestation	Malignant (n=22)		Benign (n=65)		χ^2	P
	N	Proportion(%)	N	Proportion(%)		
Echo					15.374	<0.01
High echo	8	36.36	6	9.23		
Low echo	16	72.73	36	55.39		
Mixed echo	-	-	23	35.38		
Sound halo					8.789	<0.01
Yes	-	-	20	30.71		
None	22	100.00	45	69.23		
calcification					21.911	<0.01
Microcalcification	6	27.28	-	-		
Coarse calcification	8	36.36	17	26.15		
None	8	36.36	48	73.84		
Composition					9.369	<0.01
Reality	22	100.00	44	67.69		
Cystic solidity	-	-	21	32.31		
Edge					17.412	<0.01
smooth	4	18.18	45	69.23		
Irregularity	18	81.82	20	30.71		

Table 3. Comparison between USG-guided FNAC and pathological diagnosis.

USG-guided FNAC	N	Pathological diagnosis		Total	χ^2	P
		Benign	Malignant			
Benign	58	65	0	65	1.359	0.244
Malignant	29	0	22	22		
Total	87	65	22	87		

Table 4. comparison of FNAB+ ultrasonography and pathological diagnosis.

FNAB	N	Pathological diagnosis		Total	χ^2	P
		Benign	Malignant			
Benign	63	65	0	65	0.220	0.639
Malignant	25	0	22	22		
Total	87	65	22	87		

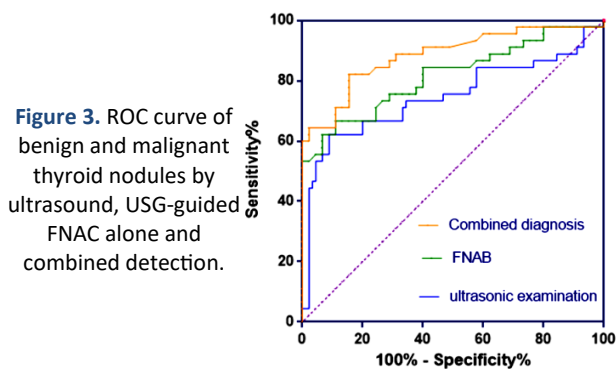


Figure 3. ROC curve of benign and malignant thyroid nodules by ultrasound, USG-guided FNAC alone and combined detection.

Table 5. The diagnostic efficacy of ultrasonography, USG-guided FNAC alone and combined detection in benign and malignant thyroid nodules.

Variable	AUC	Sensitivity (%)	Specificity degree (%)	95%CI
Ultrasonic examination	0.7447	67.32	59.49	0.6379-0.8515
FNAB	0.8136	76.83	79.02	0.7237-0.9035
FNAB+ Ultrasonic examination	0.8867	84.72	86.51	0.8134-0.9599

DISCUSSION

Thyroid disease is a common endocrine disorder, with thyroid cancer rapidly increasing, especially among women (34). Early screening and improved detection have contributed to this rise (35, 36). The primary goal in clinical diagnosis is to distinguish between benign and malignant thyroid nodules, which guides treatment plans to enhance patient outcomes and reduce unnecessary surgeries.

Thyroid carcinoma often presents subtly, with overlapping imaging and cytological features between benign and malignant nodules (37, 38). Current preoperative evaluation methods, including ultrasound, CT, MRI, radionuclide scanning, and fine needle aspiration cytology (FNAC), have a specific misdiagnosis rate (39, 40). Ultrasound is the preferred diagnostic tool due to its non-invasive nature, cost-effectiveness, and high detection rate (41). The TI-RADS system standardizes diagnosis, with higher classifications indicating increased malignancy risk. Malignant nodules account for only 5% of clinical thyroid nodules (42). For nodules larger than 5mm, USG-guided FNAC is recommended to determine malignancy (43).

Thyroid cancer is the most common endocrine malignancy, accounting for about 1% of clinical malignancies and 0.5% of all cancer deaths. Ultrasound features of thyroid nodules suspected to be malignant include a diameter larger than 5mm. USG-guided FNAC is recommended for these nodules (44). In a study of 87 patients, 22 nodules were malignant, and 53 were benign. Most malignant nodules showed hypoechoic, silent halo, solid lesions, and irregular edges. USG-guided FNAC diagnosed 66.66% of nodules as benign and 33.34% as malignant. Combined ultrasound and FNAC results showed 72.41% benign and 28.74% malignant nodules (45). ROC curve analysis indicated that combined diagnosis had a higher predictive value than individual methods. Both methods had missed and misdiagnosed cases, likely due to their limitations (17).

Malignant thyroid nodules often blend with normal thyroid tissues, making their ultrasound features atypical and challenging to identify due to the aggressive nature of tumor cells (46). Signs like microcalcification, abnormal blood flow, aspect ratio ≥ 1 , or irregular boundaries can lead to misdiagnosis, especially in cases of Hashimoto's thyroiditis. Incomplete or fused nodules result in unclear and lumpy ultrasound images. USG-guided FNAC may miss diagnoses due to small sample sizes, high lymphocyte and blood content, or failure to puncture the lesion accurately (47). Fibrosis and calcification in nodules, along with enlarged and heteromorphic cells in Hashimoto's thyroiditis, can mimic malignant features, leading to misdiagnosis. Local adenomatous and papillary hyperplasia can also show similar cytological features, further complicating accurate

diagnosis.

The value of ultrasonography and USG-guided FNAC in diagnosing thyroid nodules was analyzed using ROC curves. The AUC values were 0.7447 for ultrasound, 0.8136 for USG-guided FNAC, and 0.8867 for combined detection. The combined diagnosis had a significantly higher AUC, indicating better predictive value than either method alone. Using both methods together can reduce missed diagnoses and improve accuracy by leveraging the strengths of each technique.

In conclusion, colour Doppler ultrasound is a susceptible and accurate method for detecting thyroid nodules. Ultrasonic features can predict the nature of the nodules. For those with high malignancy suspicion or uncertain characteristics, combining ultrasound-guided fine needle aspiration biopsy is recommended when appropriate.

Funding: None.

conflicts of interests: The authors declare no conflict of interest.

Ethical consideration: Ethical batch number: Shi Yi Lun Zi No.2019-No.24.

author contribution: J.F. Liu: Conceptualization, Methodology, Software, Formal analysis, Investigation, Writing – original draft, Visualization. J. Qian: Validation, Investigation, Resources, Data curation. J. Ma: Validation, Investigation, Resources. H.X. Tang: Methodology, Software, Writing – review & editing. J.X. Ding: Supervision, Project administration, Funding acquisition. Y.Y. Tong: Conceptualization, Resources, Writing – review & editing, Supervision, Project administration.

REFERENCES

- Wong R, Farrell SG, Grossmann M (2018) Thyroid Nodules: Diagnosis & Management. *Med J Aust*, **209**(2): 92-98.
- Cosme I, Nobre E, Bugalho MJ (2023) Factors For second non-diagnostic ultrasound-guided fine-needle aspiration cytology in thyroid nodules. *Ann Endocrinol*, **84**(6): 734-738.
- Gharib H. Fine-Needle Aspiration Biopsy Of Thyroid Nodules: Advantages, Limitations. *Mayo Clin Proc*.1994;69(1):44-9.
- Grani G, Sponziello M, Pecce V, Ramundo V, Durante C (2020) Contemporary thyroid nodule evaluation and management. *J Clin Endocr Metab*, **105**(9): 2869-2883.
- Alexander EK and Cibas ES (2022) Diagnosis of thyroid nodules. *Lancet Diabetes Endo*, **10**(7): 533-539.
- Lee JY, Baek JH, Ha EJ, Sung JY, Shin JH, Kim JH, et al. (2021) Imaging guidelines for thyroid nodules and differentiated thyroid cancer-2020: Korean Society of Thyroid Radiology. *Korean J Radiol*, **22**(5): 840-860.
- Verma P, Sharma R, Sharma N, Gulati A, Parashar A, Kaundal A (2021) Fine-needle aspiration cytology versus core-needle biopsy for breast lesions: a dilemma of superiority between the two. *Acta Cytol*, **65**(5): 411-416.
- Kant R, Davis A, Verma V (2020) Thyroid nodules: advances in evaluation and management. *Am Fam Physician*, **102**(5): 298-304.
- Navin PJ, Thompson SM, Kurup AN, Lee RA, Callstrom MR, Castro MR, et al. (2022) Radiofrequency ablation of benign and malignant thyroid nodules. *Radiographics*, **42**(6): 1812-1828.
- Demiral SS and Erdoğan YE (2021) Does insulin resistance trigger thyroid nodule? *Intern Emerg Med*, **16**(8): 2105-2108.
- Cooper DS, Doherty GM, Haugen BR, Kloos RT, Lee SL, Mandel SJ, et al. (2009) Revised American Thyroid Association management guidelines for patients with thyroid nodules and differentiated thyroid cancer: the American Thyroid Association (ATA) guidelines taskforce on thyroid nodules and differentiated thyroid cancer. *Thyroid*, **19**(11): 1167-214.
- Zhong LC, Lu F, Ma F, Sun LP, et al. (2015) Ultrasound-guided fine-needle aspiration of thyroid nodules: does the size limit its efficiency? *Int J Clin Exp Pathol*, **8**(3): 3155-9.
- Alexander EK, Doherty GM, Barletta JA (2022) Management of thyroid nodules. *Lancet Diabetes Endo*, **10**(7): 540-548.
- Cibas ES and Ali SZ (2017) The 2017 Bethesda system for reporting thyroid cytopathology. *Thyroid*, **27**(11): 1341-6.
- Moudgil P, Vellody R, Heider A, et al. (2016) Ultrasound-guided fine-needle aspiration biopsy of pediatric thyroid nodules. *Pediatr Radiol*, **46**(3): 365-71.
- Holt EH (2021) Current evaluation of thyroid nodules. *Med Clin N Am*, **105**(6): 1017-1031.
- Cimbek EA, Polat R, Sönmez B, Beyhun NE, Dinç H, Saruhan H, Karagüzel G (2021) Clinical, sonographical, and pathological findings of pediatric thyroid nodules. *Eur J Pediatr*, **180**(9): 2823-2829.
- Grant EG, Tessler FN, Hoang JK, Langer JE, Beland MD, Berland LL, et al. (2015) Thyroid ultrasound reporting lexicon: white paper of the ACR thyroid imaging, reporting and data system (TIRADS) committee. *J Am col Radiol*, **12**(12): 1272-9.
- Saberi R, Mirazi N, Amirahmadi S, Darbandi ZK, Vafae F, Rajabian A, Hosseini M (2023) Ameliorative effects of thiamin on learning behavior and memory dysfunction in a rat model of hypothyroidism: implication of oxidative stress and acetylcholinesterase. *Metabolic Brain Disease*, **38**(8): 2603-13.
- Comité Nacional de Endocrinología de la Sociedad Argentina de Pediatría (2021) Alteraciones tiroideas en la infancia y en la adolescencia. Parte 1: hipertiroidismo Thyroid disorders in childhood and adolescence. Part 1: Hyperthyroidism. *Arch Argent Pediatr*, **119**(1): 1-7.
- Subbiah V, Hu MI, Wirth LJ, Schuler M, Mansfield AS, Curigliano G, et al. (2021) Pralsetinib for patients with advanced or metastatic RET-altered thyroid cancer (ARROW): a multi-cohort, open-label, registration, phase 1/2 study. *Lancet Diabetes Endo*, **9**(8): 491-501.
- De D, Dutta S, Tarafdar S, Kar SS, Das U, Basu K, et al. (2020) Comparison between sonographic features and fine needle aspiration cytology with histopathology in the diagnosis of solitary thyroid nodule. *Ind J Endo Meta*, **24**(4): 349-54.
- Varshney R, Forest VI, Zawawi F, et al. (2014) Ultrasound-guided fine-needle aspiration of thyroid nodules: Does size matter? *Am J Otolaryngol*, **35**(3): 373-6.
- Gallant JN, Chen SC, Ortega CA, Rohde SL, Belcher RH, Nettville JL, et al. (2022) Evaluation of the molecular landscape of pediatric thyroid nodules and use of a multigene genomic classifier in children. *JAMA Oncol*, **8**(9): 1323-1327.
- Gupta M, Acharya K, Jha A, Tripathi P, Gyawali BR, Bhat N, Pandey AK (2022) Diagnostic efficacy of ultrasonography-guided fine needle aspiration cytology on thyroid swellings. *The Egyptian Journal of Otolaryngology*, **38**(1): 118.
- Manning AM, Yang H, Falciglia M, et al. (2017) Thyroid ultrasound-guided fine-needle aspiration cytology results: observed increase in indeterminate rate over the past decade. *Otolaryngol Head Neck Surg*, **156**(4): 611-615.
- Rivera M, Ricarte-Filho J, Tuttle RM, Ganly I, Shaha A, Knauf J, et al. (2010) Molecular, morphologic, and outcome analysis of thyroid carcinomas according to degree of extrathyroid extension. *Thyroid*, **20**(10): 1085-93.
- Saleem A, Kalsoom U, Yasin S, et al. (2022) Diagnostic accuracy of strain ultrasound elastography in thyroid lesions compared to fine-needle aspiration cytology. *Cureus*, **14**(7): E27185.
- Gupta M, Acharya K, Jha A, Tripathi P, Gyawali BR, Bhat N, Pandey AK (2022) Diagnostic efficacy of ultrasonography-guided fine needle aspiration cytology on thyroid swellings. *The Egyptian Journal of Otolaryngology*, **38**(1): 118.
- McKenzie DR, Kliassov EG, Dash RC, et al. (2022) Pathologist-performed ultrasound-guided fine-needle aspirations of the thyroid: A single institution observational study. *Cancer Cytopathol*, **130**(9): 735-739.
- Pemayun TG (2016) Current diagnosis and management of thyroid nodules. *Acta Med Indones*, **48**(3): 247-257.
- Baloch ZW, Tam D, Langer J, Mandel S, LiVolsi VA, Gupta PK (2000) Ultrasound-guided fine-needle aspiration biopsy of the thyroid: role of on-site assessment and multiple cytologic preparations. *Diagn Cytopathol*, **23**(6): 425-429.
- Hawkins SP, Jamieson SG, Coomarasamy CN, Low IC (2021) The

- global epidemic of thyroid cancer overdiagnosis illustrated using 18 months of consecutive nodule biopsy correlating clinical priority, ACR-TIRADS and Bethesda scoring. *J Med Imag Radiat On*, **65**(3): 309-316.
34. Whittle C, García M, Horvath E, Slater J, Carrasco C (2019) Thyroid microcalcifications in the absence of identifiable nodules and their association with thyroid cancer. *J Ultras Med*, **38**(1): 97-102.
35. Jasim S, Patel KN, Randolph G, Adams S, Cesareo R, Condon E, *et al.* (2022) American Association of Clinical Endocrinology Disease State Clinical Review: The clinical utility of minimally invasive interventional procedures in the management of benign and malignant thyroid lesions. *Endocr Pract*, **28**(4): 433-448.
36. Kassi GN, Evangelopoulou CC, Papapostolou KD, Karga HJ. Benign and malignant thyroid nodules with autoimmune thyroiditis. *Arch Endocrin Metab*. 2022;**66**(4):446-451.
37. Ostrowska L, Gier D, Zyśk B (2021) The influence of reducing diets on changes in thyroid parameters in women suffering from obesity and Hashimoto's disease. *Nutrients*, **13**(3): 862.
38. Kohlenberg J, Gu J, Parvinian A, Webb J, Kawkgi OE, Larson NB, *et al.* (2022) Added value of mass characteristic frequency to 2-D shear wave elastography for differentiation of benign and malignant thyroid nodules. *Ultrasound Med Biol*, **48**(8): 1663-1671.
39. Senashova O and Samuels M (2022) Diagnosis and management of nodular thyroid disease. *Tech Vasc Interv Rad*, **25**(2): 100816.
40. Grünwald F, Baumgarten J, Happel C, Sabet A, Gröner D (2022) Radiofrequency ablation of benign thyroid nodules. *Laryngorhinootologie*, **101**(7): 569-573.
41. Biswas S, Sureka B, Kaushal D, Elhence P, Goyal A, Yadav T, Goel A, Khara PS (2022) American college of radiology thyroid imaging reporting and data system score has high diagnostic value in the diagnosis of malignant thyroid nodules: A prospective single-center cross-sectional study. *Ann Afr Med*, **21**(4): 377-382.
42. Cordes M, Götz TI, Horstrup K, Kuwert T, Schmidkonz C (2019) Growth rates of malignant and benign thyroid nodules in an ultrasound follow-up study: a retrospective cohort study. *BMC Cancer*, **19**(1): 1139.
43. Malhi HS and Grant EG (2021) Ultrasound of thyroid nodules and the thyroid imaging reporting and data system. *Neuroimag Clin N Am*, **31**(3): 285-300.
44. Hernandez-Prera JC, Valderrabano P, Creed JH, de la Iglesia JV, Slebos RJC, Centeno BA, *et al.* (2021) Molecular determinants of thyroid nodules with indeterminate cytology and RAS mutations. *Thyroid*, **31**(1): 36-49.
45. Goldfarb M and Dinauer C (2022) Differences in the management of thyroid nodules in children and adolescents as compared to adults. *Curr Opin Endocrinol*, **29**(5): 466-473.
46. Ahn SH (2021) Usage and diagnostic yield of fine-needle aspiration cytology and core needle biopsy in thyroid nodules: a systematic review and meta-analysis of literature published by Korean authors. *Clin Exp Otorhinolar*, **14**(1): 116-130.
47. Elmaoğulları S, Özalkak Ş, Çetinkaya S, Karaman İ, Üner Ç, Arda N, Savaş-Erdeve Ş, Ayca Z (2021) Evaluation of children and adolescents with thyroid nodules: a single center experience. *J Clin Res Pediatr E*, **13**(3): 276-284.