

Volumetric changes in meningioma after six-month follow-up of single session gamma knife radiosurgery: A single-centre study

R.S. Ahmed^{1*}, Y.M. Hassen², F.H. Hameed¹, S.A. Abd El-Azeem^{3,4}, M.Y.A. Mostafa^{5*}

¹Department of Physiology and Medical Physics, College of Medicine, Al-Nahrain University, Baghdad, Iraq

²Department of Surgery, College of Medicine, Al-Nahrain University, Baghdad, Iraq

³Physics Department, College of Sciences and Humanities, Prince Sattam Bin Abdulaziz University, Al-Kharj, Saudi Arabia

⁴Physics Department, Faculty of Women for Arts, Science and Education, Ain Shams University, Cairo, Egypt

⁵Physics Department, Faculty of Science, Minia University, El-Minia, Egypt

► Original article

ABSTRACT

*Corresponding authors:

Rasha S. Ahmed, Ph.D.,

Mostafa Y. A. Mostafa, Ph.D.,

E-mail:

rasha.sabeeh.ahmed@colmed-alnahrain.edu.iq

Mostafa.youness@mu.edu.eg

Received: July 2024

Final revised: January 2025

Accepted: April 2025

Int. J. Radiat. Res., October 2025;
23(4): 1009-1015

DOI: 10.61186/ijrr.23.4.25

Keywords: Meningioma, gamma knife, radiosurgery, Iraq, tumor.

Background: Gamma Knife Radiosurgery is a type of radiation therapy that uses a very intense beam of gamma rays that is used in destroying brain tumors like meningiomas without the need to make a surgical interface. The current study aims to assess the impact of Gamma Knife Radiosurgery in meningioma treatment by estimating the changes in meningioma volumes after six months of follow-up. **Materials and Methods:** 43 participants' data was collected at the Saad Al-Watari Gamma Knife Center in Baghdad, Iraq. The data was gathered from June 2022 to December 2022, and each patient followed after 6 months after the gamma knife surgery. **Results:** The outcomes show a decrease in meningioma volumes of 83.7% of patients. Only 2.3% of the patients recorded no change in meningioma size. Also, 9.3% of the patients recorded an increase in meningioma size. And finally, the tumor completely disappeared in 4.7% of the patients. **Conclusion:** Gamma knife treatment is a beneficial option for reducing the meningioma volume. The study demonstrated a significant decrease in tumor size for most patients. Furthermore, a small percentage of patients reported no change or an increase in tumor size, indicating that gamma knife treatment may not be equally effective for all individuals. However, it is essential to mention that two patients reported the complete disappearance of their tumors, suggesting a potential for successful tumor eradication with this treatment.

INTRODUCTION

Meningioma is a benign tumor that grows slowly and arises from meninges, which can present with different symptoms, including anxiety, mood symptoms, psychosis, personality changes, and memory disturbances. Meningiomas' infiltrative nature can cause structural peri-operative damage to be involved in cranial nerves, sinuses, and vessels, increasing the potential morbidity in cases of aggressive tumor resection. Meningiomas are divided into nine types by the World Health Organization (WHO) (1-3), ranging from benign to malignant. The complete surgical resection of meningiomas is virtually impossible, as its anatomical locations can be related to mortality risk (4-6). Many studies regarding the management of meningiomas have focused on tumor volume reduction as well as assessing various treatment approaches to achieve the best tumor control rates.

Gamma Knife (GK) radiosurgery has been used broadly to irradiate small brain tumors as a safe and

effective treatment method with long-term survival rates and reliable tumor control (7-9). In general, the aims of radiosurgery for brain tumors are twofold: to maintain neurological function and to avoid further tumor growth. Gamma Knife radiosurgery has altered the medicinal spectrum for meningioma and played an essential role in lowering the risk of tumor recurrence while not significantly increasing management risk (10-12). In smaller tumor volumes, GK radiosurgery seems to be more effective. The Gamma Knife became the initially available technology for stereotactic radiosurgery (13, 14), with unrivaled 3-dimension high accuracy for radiation delivery. In the literature, many studies focus on examining the effect of gamma knife treatment on different tumor types. Mori *et al.* conducted a comparison of dose strategy over three separate stereotactic radiotherapy (SRT) methods: Novalis (NV), Gamma Knife (GK), and TomoTherapy (TT). The study assessed these methods regarding target coverage and sparing of organs at risk (OARs) for treating benign skull base tumors. They aimed to determine which method

provides the best conformity, thereby offering benefits in treating benign tumors. Their results show that gamma knife radiosurgery is the more effective and safer treatment for skull base benign tumors⁽¹⁵⁾. Rasha *et al.* assess the impact of different treatment strategies for meningioma utilizing GK radiosurgery. This comprised assessing multisession, hypo fractionation, and single-session GK radiosurgery approaches and comparing the outcomes of these three methods concerning tumor volume reduction and patient response. Their results reveal that multisession GK is the best treatment option that is well tolerated for meningioma⁽¹⁶⁾. Peter *et al.* developed a method for utilizing the inverse planning module's functions to automatically fill a target volume with shots and improve the planning process in Gamma Plan for treating metastases. This method showed potential for reducing the treatment and planning times, making the technique more efficient, specifically for less experienced planners⁽¹⁷⁾.

The gamma knife device is considered one of the most recently used devices in Iraq, where the first was introduced in 2016. Therefore, studies related to the condition of the meningioma tumor and its size change before and after GK treatment are limited compared to the globally published research.

Clinically, post-radiosurgery follow-up for meningioma comprises periodic outpatient attends and sequential imaging evaluation. Frequently, clinicians may report the imaging observations as regressed, enlarged, or unchanged using simple assessments of tumor diameter. The possibility of distant recurrence of meningiomas or delayed malignant progression and its heterogeneous nature make the measurement and analysis of volume response guide clinicians in patient risk measurements and long-term clinical decision-making. Only a limited number of studies have attempted to assess the early meningioma volume response after GK radiosurgery, and most have concentrated on long-term changes in volumes⁽¹⁸⁻²⁰⁾.

This cohort (prospective) design study aims to evaluate the early response of meningioma tumor size after 6-month follow-up for patients treated by GK radiosurgery with prescribed doses varying from 10 to 15 Gy. This study focuses on the limited research in Iraq on Gamma Knife radiosurgery, which was introduced to the country in 2016. It presents significant insights into its application and effectiveness in a recently introduced clinical setting.

MATERIALS AND METHODS

Study population and ethics

This study is a prospective cohort and was performed to indicate the effect of the prescribed dose of gamma knife on meningiomas volume after

short-term follow-up (6 months). This work was performed at the Saad Al-Watari Gamma Knife Center in Baghdad, Iraq. The Icon and Perfexion gamma knife machines were used for radiosurgery. Data was collected from a total of 43 patients (5 males and 38 females) who were admitted to the center. The median age of patients was 53.63 ± 0.717 years, ranging from 45 to 65 years. The researchers obtained permission from the Gamma Knife Center at the neurology hospital to collect data. Patients were supplied with informed consent before gamma knife radiosurgery, and the data, including age, MRI reports, and whether the patient underwent a surgical intervention, were collected. All patient information collected during the study was kept confidential. This study was conducted following the principles of the Declaration of Helsinki. Approval was provided by the Institutional Review Board (IRB) of the College of Medicine, Al-Nahrain University, Baghdad, Iraq (6 Feb 2022/No. 202112118).

Pre-gamma knife imaging and planning

After the patients were diagnosed and referred for gamma knife therapy, the tumor size was measured Pre-Gamma Knife surgery using three-dimensional anatomical Magnetic Resonance Imaging (Philips 3 Tesla MRI). The solid structures and head's bone were then imaged using the Perfexion model Computed Tomography (CT) scan or the Cone-Beam Computed Tomography (CBCT) attached to the Leksell gamma knife LGK device (ICON model). CT and MRI scans provide geometric information to assess the spatial placement and anatomy of the target and critical structures, and they are used in image-guided surgery to minimize injury to nearby healthy tissues. Both procedures offer highly precise radiation delivery in the range of millimeters to destroy the tumor, attaining permanent accuracy of the delivered radiation. These procedures help assess the patient's treatment plan by ensuring the radiation can cover the tumor from different directions and angles. The MRI sequences are imported onto the GK computer through data storage media or a computer network. The images are then shown as two-dimensional slices across the coronal, axial, and sagittal planes. Patients' information, such as their name, age, disease, radiosurgery date, patient code, gender, and skull dimensions, is entered to illustrate a 3-D shape of the patient's skull. Co-registration is then performed between CT and MRI, with the tumor's location matched and fitted between the two images using Gamma Knife Linux software.

Patient preparation for gamma knife

In the beginning, a stereotactic neurosurgical frame is affixed to the patient's head to confirm an exact beam center at the tumor location and to immobilize the head. After placing the frame, the patient experiences a tomography scan minutes

before the operation. The recommended dose for Benign meningioma grade (I) is between 10 and 15 Gy, while the recommended dose for malignant meningioma grade (II, III) tumors is between 14 and 18 Gy. These doses are entered into the GK planning software system that covers the entire tumor area while minimizing the risk of radiation exposure to vital areas. The neurosurgeon specifies the target and the at-risk organ by adding the required treatment dose into the Linux software's plan. After the treatment plan was printed and approved, and the data was exported to the LGK treatment control panel, the patient was positioned on a couch to receive the radiation treatment. The patient was adjusted to a comfortable position on the couch, and the frame was attached to his head. The bed was placed at a standard angle of 90, 70, or 110 degrees, with 90 degrees being the most common. Finally, the patient is delivered the required therapeutic dose.

Patient follow-up

Six months after the radiation therapy, the impact of the treatment on the tumor was assessed. The follow-up assessment consisted of an MRI tomography for each patient, conducted at the MRI research facility in Saad Al-Watari hospital, utilizing a Philips MRI device model of 3 Tesla. Image evaluation after GK radiosurgery for meningiomas assesses tumor size changes, and treatment efficiency, and helps find peritumor edema for early treatment.

Statistical analysis

The data analysis was performed using SPSS-27, a statistical package for social sciences with available features. The results were presented in basic statistical measures, including frequency, percentage, mean, standard deviation, and range of values (minimum-maximum).

RESULTS

GK radiosurgery is significantly effective and safe for the management of meningiomas. Therapeutic response to treatment is clinically described as stable, enlarged, or regressed, which outlines the nature of the tumor response. One needs to assess that response accurately to interpret the tumor response to GK radiosurgery. Understanding the early treatment response profile may help predict the long-term results and offer hints to help enhance the overall results. In the presented study, 70 patients who experienced GKRS between June 2022 and December 2022 were identified. For this cohort, 43 patients (62%) were involved. The remaining patients were excluded for insufficient imaging for volumetric analysis, patients with repeat GK radiosurgery, and those with previous meningioma treatment with surgery. The median age at the time of radiosurgery was 53.63 ± 0.717 years, ranging from

45 to 65 years; 86% were female, and 14% were male. As reported elsewhere, Meningiomas are more common in females than in males (21-23) and the risk factors for meningioma in females include radiation exposure, mutations in the NF2 gene, and the SNP rs4968451, which codes for breast cancer gene 1-interacting protein 1 (24-26).

Two Algorithms of Gamma Knife Treatment planning were used; the first was convolution planning by manually adding and/or eliminating shots as needed, adjusting tumor location until the Planning Target Volume (PTV) and Organ at Risk (OAR) attain the appropriate dose. The second was the inverse-planning algorithm, at which the clinical planner describes the dose limitations, and the computer assesses the required beam intensities, allowing for a fast treatment planning process with more effective results. To ensure safety, the plugging blocks technique was utilized, where the plugging of the GK device's sector channels prevented radiation from reaching essential structures. The shot weight was either decreased or increased to provide additional protection for organs. The neurosurgeon generates the dose distribution by outlining one or more isocenters or shots at different locations within the tumor volume so that the prescription surface consistently matches the target (figure 1). Each isocenter identifies an area to which the GK must position the patient to place the isocenter in the radiation direction. Many isocenters allow the surgeon to establish dose coverage with irregular shapes. In Figure 1, each subfigure represents a 3D view of the tumor with different z-axis and slice position (SP).

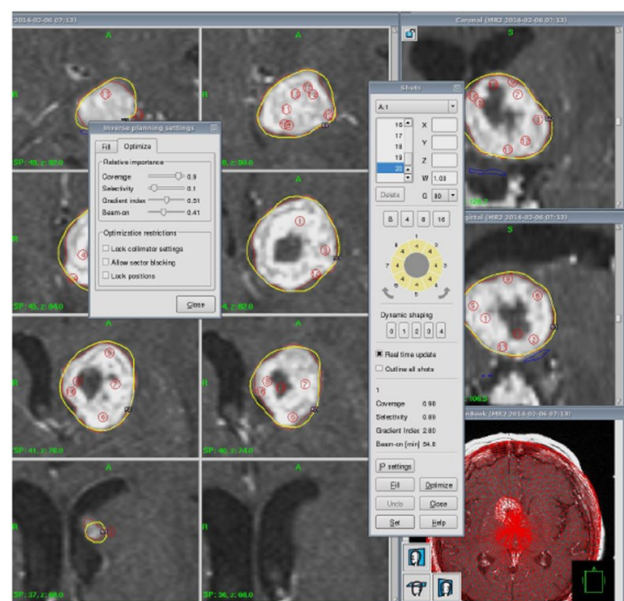


Figure 1. The plugging blocks and GK weight are used to decrease the radiation effects on healthy tissues and concentrate the radiation in the required area. The yellow line represents the dose distribution, and the red circle represents an individual shot.

Patients treated with a single-session gamma knife at Saad Al-Watari Hospital, Iraq were included. The mean value of tumor volume at the time of radiosurgery ranged from 0.64 to 40.6 cm³ with mean ± SD, 10.8±10.4 cm³. The prescribed dose ranged from 10 to 15 Gy. Out of 43 patients, 36 (83.7%) confirmed a reduction in the size of their tumors. Meanwhile, 4 patients (9.3%) reported tumor regrowth, 2 patients (4.7%) reported tumor disappearance, and only one patient (2.3%) reported no change in tumor size as seen in figure 2.

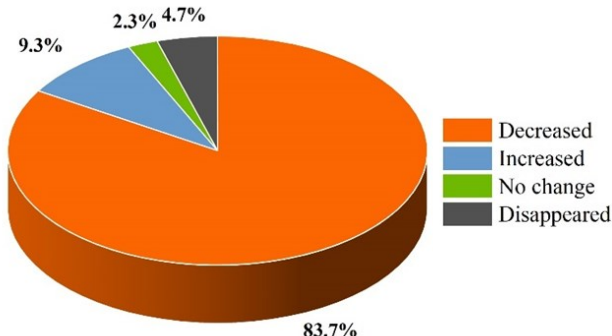


Figure 2. The percentage of tumor volume changes after gamma knife radiosurgery.

Table 1 shows information about patients who experienced a reduction in their tumor size. Accordingly, the tumor volumes ranged between 0.64 cc to 40.57 cc with an average value of 11.72 cc before GK radiosurgery. After GK radiosurgery the tumor volumes ranged between 0.08 cc to 32.71 cc with an average value of 8.26 cc (figure 3). Additionally, two cases (patients 37 and 38) record the total disappearance of the tumors. The maximum reduction percent in tumor volume was found to be (95%) in patient number (24) while the minimum reduction percent in tumor volume was found to be (8%) in patient number (8).

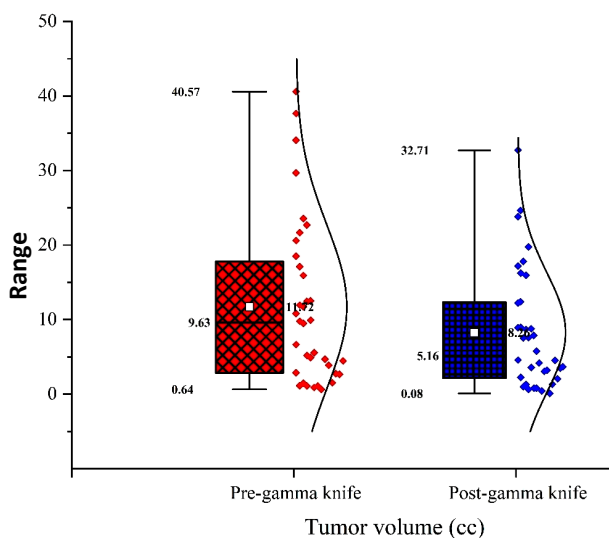


Figure 3. The tumour size pre and post GK radiosurgery. The Whiskers represent the minimum and maximum values, the white squares represent the mean, the solid horizontal lines represent the median, and the dots represent the tumour volume.

Table 1. Age, gender, dose, and tumor size pre and post-GKR for patients with a reduced tumor size.

No.	Age	Gender	Dose	Pre-gamma tumor size (cc)	Post-gamma tumor size (cc)
1	56	male	10	37.66	32.71
2	50	female	10	20.61	17.17
3	50	female	10	10.81	8.89
4	52	female	12	6.63	4.57
5	54	female	12	2.87	2.25
6	53	female	12	1.12	0.99
7	61	female	12	1.46	1.30
8	57	female	12	1.11	0.64
9	50	female	12	21.68	16.23
10	48	female	12	4.90	3.56
11	49	female	12	0.89	0.80
12	53	female	12	1.07	0.78
13	51	female	12	11.94	4.18
14	57	female	12	0.64	0.40
15	53	female	12	23.57	17.79
16	53	female	12	11.72	8.94
17	48	female	14	12.44	7.52
18	53	male	14	12.51	8.69
19	52	female	14	4.68	3.06
20	51	female	14	9.78	7.55
21	60	female	14	9.48	8.76
22	49	female	14	3.88	3.17
23	51	male	14	18.49	12.24
24	56	female	14	1.53	0.08
25	52	female	14	2.75	1.31
26	48	female	14	17.11	7.88
27	51	female	14	40.57	23.81
28	54	female	14	5.17	4.54
29	50	male	14	22.68	15.96
30	56	female	14	2.67	2.05
31	62	female	14	4.45	3.48
32	65	female	14	9.92	5.75
33	45	female	14	29.68	19.74
34	47	male	14	15.91	12.40
35	63	female	14	34.06	24.64
36	55	female	15	5.57	3.69
37	54	female	14	5.87	0.00
38	60	female	14	5.40	0.00

Figure 4 represents the volumetric changes in meningioma tumors before and after GK radiosurgery as a function of radiation doses. The solid lines connect the mean values of tumor size for each radiation dose. The figure illustrates clearly the effectiveness of gamma knife radiosurgery in tumor size reduction. In cases treated with a 10 Gy dose (3 patients), 12 Gy dose (16 patients), and 14 Gy dose (19 patients) the reduction in the mean value of tumor size was found to be 15%, 29%, and 30%, respectively. It should be mentioned that one patient who was treated with a 15 Gy dose (patient number 38) experienced a reduction in tumor size, this case is not included in the figure due to the inability to illustrate the case as a box plot. Additionally, two cases treated with a 14 Gy dose encountered a complete disappearance in the tumors not included in figure 4. Table 2 represents the last five cases: four with increased tumor size (↑), and one with unchanged tumor size (↔) after GK radiosurgery.

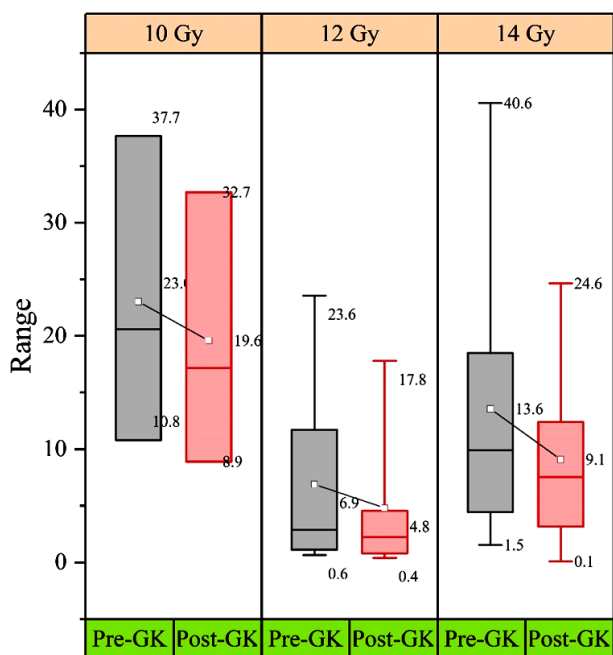


Figure 4. The tumour size before and after GK radiosurgery as a function of radiation doses.

Table 2. The age, gender, dose, tumour volume pre- and post-GKR, and volumetric case of each tumour are shown. The upward arrow represents an increase in tumour size, and the bidirectional arrow represents no change in tumour volume.

No.	Age	Gender	Dose	Pre-gamma tumor size (cc)	Post-gamma tumor size (cc)	Case [†]
1	55	female	12	7.51	30.51	↑
2	49	female	12	2.73	5.10	↑
3	63	female	12	13.84	17.97	↑
4	56	female	12	2.80	3.51	↑
5	54	female	12	2.49	2.49	↔

† No change in tumor size. An increase in tumor size

DISCUSSION

The current study recorded a high percentage reduction in tumor volume or disappearance after gamma knife radiosurgery. This reduction is a positive outcome that indicates the treatment has successfully destroyed tumor cells, making it suitable for meningioma. It should be mentioned that the obtained results were based on short-term follow-ups, and the effectiveness of the results may improve with longer-term patient follow-ups as the biological effects of radiation unfold and the tumor microenvironment responds to treatment.

In some cases, tumor size may increase following GK radiosurgery due to various factors, i.e. Radiation-induced edema due to transient swelling or edema around the treated area as part of the normal tissue response to radiation. This edema may cause an increase in tumor size in imaging studies, although it is often temporary and resolves over time. Close clinical correlation and follow-up imaging are necessary to accurately assess treatment response and guide further management decisions.

Previous studies with long-term follow-up have shown that Gamma Knife radiosurgery achieves high tumor control rates for meningiomas, which agrees with our findings. Ajay *et al.* (27) studied the effect of GK radiosurgery on meningiomas in an average follow-up period of 81 months. They found that the 1 - and 5-year local tumor control rates were 100% and 90.5%, respectively, indicating efficient initial control. This suggests that GK radiosurgery can provide essential benefits shortly after treatment. Yeong-Jin *et al.* study (28) targeted on long-term results of GK for growing meningiomas, with a minimal follow-up of 12 months. At a median follow-up (41 months), tumor volume decreased by 69.5%, did not change in 27.1% of patients, and increased by 3.4%. The findings suggest GK effectively controls tumor growth with minimum neurological deterioration with time. Goktug *et al.* (29) evaluated 37 meningioma patients who underwent GK radiosurgery between 2007 and 2019. The outcomes show that 97.3% of patients accomplished tumor control, with only 2.7% of tumors increasing in size, 62.2% remaining stable, and 35.1% decreasing in size. Robert *et al.* (30) study concluded that after an average follow-up of 6.5 years, tumor volume continued unchanged in 49% of patients, decreased in 35%, and increased in 16%. The survival rates at 3, 5, and 10 years were 90.3%, 88.6%, and 77.2%, respectively, showing a reasonable tumor control rate for large meningiomas treated with GK radiosurgery. Seong-Hyun (31) found that after GK radiosurgery for tentorial meningiomas, 57% of patients underwent a reduction in tumor volume, while 33% had stable tumors and 10% revealed an increase in tumor size. The progression-free survival rates were 97% at 1 year and 92% at 5 years, suggesting success long-term tumor control.

The outcomes of the Wilcoxon Signed-Rank Test demonstrate a statistically significant difference between pre- and post-GK treatment tumor volumes ($p < 0.001$). This shows the effectiveness of GK radiosurgery in reducing tumor size over a six-month follow-up duration. Our findings are consistent with previous studies presenting tumor volume reduction following GK treatment, whereas most available literature concentrates on more extended follow-up periods. While most patients experienced a decrease in tumor size, a small number exhibited stable or increased tumor volumes, requiring further investigation into patient-specific factors that may affect treatment response.

While our six-month follow-up does not capture the long-term tumor response, it provides an early indication of tumor size changes, which may serve as a predictor of later outcomes. Our results align with the findings of delayed shrinkage described in these studies, although further follow-up is necessary to confirm long-term effects.

CONCLUSION

This prospective cohort study provides a six-month follow-up of radio-surgical treated meningiomas. The presented study shows that the most significant percentage of patients (83.7%) undergoing gamma knife radiosurgery experienced a reduction in meningioma tumor size, suggesting that the treatment was effective and a viable option for treating meningiomas. In some cases, there is a regrowth in tumor size after treatment, indicating that the effectiveness of radiosurgery treatment may vary among individuals depending on the size and location of the tumor, as well as the individual patient's response to treatment. As a result, regular monitoring is important to ensure that the tumor does not grow back. Further research is needed to determine the effectiveness of long-term and potential side effects of this treatment approach. Gamma knife can be considered a satisfying alternative to re-surgery for meningioma tumors.

Limitations: Our study includes a small number of patients. This limitation is due to the rarity of the number of patients admitted to the centre who can be treated with radiosurgery. On the other hand, the study cohort belongs to single-centre data, and the handling and performance of GK radiosurgery were homogeneous.

Funding: This study was supported by no funding.

Conflicts of interests: All authors unanimously declare that there is no conflict of interest in this study.

Ethical consideration: This work was approved by the Institutional Review Board (IRB) of the College of Medicine, Al-Nahrain University, Baghdad, Iraq (6 Feb 2022/No. 202112118).

Author contribution: All authors contributed equally to this work.

REFERENCES

- Wechsler W and Reifenberger G (1996) Histopathological classification of brain tumors according to the revised WHO classification: Current State and perspectives BT - brain tumor. In: Nagai M (ed). Springer Japan, Tokyo, pp 3-20.
- Zulch MDKJ (1957) Brain tumors, their biology and pathology. Springer; First Edition (January 1, 1957).
- Mennel H-D (1991) Grading of intracranial tumors following the WHO classification. *Neurosurgical Review*, **14**: 249-260. <https://doi.org/10.1007/BF00383256>
- Couldwell WT, Fukushima T, Giannotta SL, Weiss MH (1996) Petroclival meningiomas: surgical experience in 109 cases. *Journal of Neurosurgery* **84**: 20-28. <https://doi.org/10.3171/jns.1996.84.1.0020>
- Zhu W, Mao Y, Zhou L-F, et al. (2007) Combined subtemporal and retrosigmoid keyhole approach for extensive petroclival meningioma surgery: report of experience with 7 cases. *Minimally Invasive Neurosurgery: MIN*, **50**: 106-110. <https://doi.org/10.1055/s-2007-984384>
- Nadeem A, Khan A, Habib A, et al. (2024) Intracranial intricacies: Comprehensive analysis of rare skull base meningiomas-A single-center case series. *Clinical Case Reports*, **12**: e8376.
- Sheikhbahaei S, Sadaghiani MS, Rowe SP, Solnes LB (2021) Neuroendocrine tumor theranostics: An update and emerging applications in clinical practice. *American Journal of Roentgenology*, **217**: 495-506. <https://doi.org/10.2214/AJR.20.23349>
- Richter S, Steenblock C, Fischer A, et al. (2024) Improving susceptibility of neuroendocrine tumors to radionuclide therapies: personalized approaches towards complementary treatments. *Theranostics*, **14**: 17-32. <https://doi.org/10.7150/thno.87345>
- Mishra S, Kumar AG, Garg K, et al. (2023) Role of stereotactic radiosurgery for cavernous sinus hemangiomas - an individual patient data-based meta-analysis. *Neurology India*, **71**: S21-S30. <https://doi.org/10.4103/0028-3886.373654>
- Speckter H, Bido J, Hernandez G, et al. (2016) SU-F-J-92: Predictive value of diffusion tensor imaging parameters for gamma knife radiosurgery in meningiomas. *Medical Physics*, **43**: 3427-3428. <https://doi.org/https://doi.org/10.1118/1.4956000>
- Lee JA, Kim SR, Yoon SH, et al. (2022) Evaluation and analysis of radiation exposure to normal tissues during gamma knife radiosurgery for vestibular schwannoma. *Int J Radiat Res*, **20**: 571-578. <https://doi.org/10.52547/ijrr.20.3.8>
- Sarihan S, Tunc SG, Irem ZK, Kahraman A (2024) Stereotactic radiotherapy for brain metastases in patients with non-small cell lung cancer: CyberKnife-M6 experience. *Int J Radiat Res*, **22**: 117-124. <https://doi.org/10.61186/ijrr.22.1.117>
- Lippitz BE, Bartek JJ, Mathiesen T, Förander P (2020) Ten-year follow-up after Gamma Knife radiosurgery of meningioma and review of the literature. *Acta Neurochirurgica*, **162**: 2183-2196. <https://doi.org/10.1007/s00701-020-04350-5>
- Ganz JC (2014) Stockholm radiosurgery developing 1968-1982. *Progress in Brain Research*, **215**: 85-94. <https://doi.org/10.1016/B978-0-444-63520-4.00009-0>
- Mori Y, Nakazawa H, Hashizume C, et al. (2019) Dosimetric comparison of hypofractionated stereotactic radiotherapy by three different modalities for benign skull base tumors adjacent to functioning optic pathways. *Int J Radiat Res*, **17**: 519-530
- Ibrahim RT, Ahmed RS, Hassan YM (2023) The evaluation of tumor volume and radiological features in patients with meningioma treated by multi-session, single session and hypo fractionation gamma knife radiosurgery. *Onkologia i Radioterapia*, **17**: 231-234.
- Fallows P, Wright G, Bownes P (2019) A standardised method for use of the Leksell GammaPlan Inverse Planning module for metastases. *Journal of radiosurgery and SBRT*, **6**: 227-233.
- Schmutzer M, Skrap B, Thorsteinsdottir J, et al. (2023) Meningioma involving the superior sagittal sinus: long-term outcome after robotic radiosurgery in primary and recurrent situation. *Frontiers in Oncology*, **13**: 1206059. <https://doi.org/10.3389/fonc.2023.1206059>
- Zada G, Pagnini PG, Yu C, et al. (2010) Long-term outcomes and patterns of tumor progression after gamma knife radiosurgery for benign meningiomas. *Neurosurgery*, **67**: 322-329. <https://doi.org/10.1227/01.NEU.0000371974.88873.15>
- Maksoud Z, Schmidt MA, Huang Y, et al. (2022) Transient enlargement in meningiomas treated with stereotactic radiotherapy. *Cancers*, **14**: 1547. <https://doi.org/10.3390/cancers14061547>
- Ogasawara C, Philbrick BD, Adamson DC (2021) Meningioma: A review of epidemiology, pathology, diagnosis, treatment, and future directions. *Biomedicines*, **9**(3): 319. <https://doi.org/10.3390/biomedicines9030319>
- Samanic CM, Teer JK, Thompson ZI, et al. (2021) Mitochondrial DNA sequence variation and risk of meningioma. *Journal of Neuro-oncology*, **155**: 319-324. <https://doi.org/10.1007/s11060-021-03878-5>
- Ullah MS, Khan MA, Masood A, et al. (2024) Brain tumor classification from MRI scans: a framework of hybrid deep learning model with Bayesian optimization and quantum theory-based marine predator algorithm. *Frontiers in Oncology*, **14**: 1335740. <https://doi.org/10.3389/fonc.2024.1335740>
- Hosseini-Siyaniaki MR, Hasanpour Segherlou Z, Liu S, et al. (2023) Recurrent meningioma: When to intervene. *BOHR International Journal of Neurology and Neuroscience*, **1**: 50-58. <https://doi.org/10.54646/bijn.2023.08>
- Maiuri F, Corvino S, Corazzelli G, et al. (2024) Time to recurrence of intracranial meningiomas from a monoinstitutional surgical series. *World Neurosurgery*, **185**: e612-e619. <https://doi.org/10.1016/j.wneu.2024.02.087>
- Bethke L, Murray A, Webb E, et al. (2008) Comprehensive analysis of DNA repair gene variants and risk of meningioma. *Journal of the National Cancer Institute*, **100**: 270-276. <https://doi.org/10.1093/>

- jnci/djn004.
27. Niranjan A, Wei Z, Taori S, et al. (2024) 199 Gamma knife radiosurgery to treat neurofibromatosis type 2-associated meningiomas: A 35 year experience and paradigm for future treatment. *Neurosurgery*, **70**(Suppl 1): 51-52.
 28. Kim YJ, Moon K-S, Park SJ, et al. (2024) Gamma knife radiosurgery as primary management for intracranial meningioma identified as growing on serial imaging. *Medicine*, **103**: e37082. <https://doi.org/10.1097/MD.00000000000037082>
 29. Akyoldaş G, Samancı Y, Yılmaz M, et al. (2021) Long-term results of gamma knife radiosurgery for foramen magnum meningiomas. *Neurosurgical review*, **44**: 2667-2673. <https://doi.org/10.1007/s10143-020-01446-5>
 30. Starke RM, Przybylowski CJ, Sugoto M, et al. (2015) Gamma knife radiosurgery of large skull base meningiomas. *Journal of Neurosurgery*, **122**: 363-372. <https://doi.org/10.3171/2014.10.JNS14198>
 31. Park S-H, Kano H, Niranjan A, et al. (2015) Gamma knife radiosurgery for meningiomas arising from the tentorium: a 22-year experience. *Journal of Neuro-oncology*, **121**: 129-134. <https://doi.org/10.1007/s11060-014-1605-0>.

