

# Diagnostic value of <sup>18</sup>F-fluorodeoxyglucose positron emission tomography/computed tomography in malignant biliary obstruction

Z.P. Koç<sup>1\*</sup>, P.P. Özcan<sup>1</sup>, E. Reyhan<sup>2</sup>, M. Yıldız<sup>3</sup>, E. Üçbilek<sup>4</sup>

<sup>1</sup>Nuclear Medicine Department, Mersin University, Mersin, Turkey

<sup>2</sup>Surgical Oncology Department, Mersin University, Mersin, Turkey

<sup>3</sup>Pathology Department, Mersin University, Mersin, Turkey

<sup>4</sup>Gastroenterology Department, Mersin University, Mersin, Turkey

## ABSTRACT

### ► Short report

#### \*Corresponding author:

Zehra Pınar Koç, M.D.,

#### E-mail:

[zehrapinarkoc@gmail.com](mailto:zehrapinarkoc@gmail.com)

Received: January 2024

Final revised: July 2024

Accepted: January 2025

*Int. J. Radiat. Res.*, October 2025;  
23(4): 1125-1129

DOI: 10.61186/ijrr.23.4.41

**Keywords:** Biliary stasis, <sup>18</sup>F-FDG, positron emission tomography.

**Background:** Our investigation employed a retrospective methodological approach, examining a sample of 45 participants (55.6% male, 44.4% female). The average age was 64 years. All participants presented clinical manifestations suggestive of malignant biliary obstruction. Initial diagnoses were established through advanced imaging techniques, specifically endoscopic retrograde cholangiopancreatography (ERCP) and magnetic resonance cholangiopancreatography (MRCP). The study design involved a retrospective analysis of data obtained from the entire cohort to ascertain the diagnostic precision of FDG-PET imaging protocol in this specific clinical context. We also conducted a comparative analysis between the imaging results and the definitive findings from surgical interventions and pathological examinations. To quantitatively assess the diagnostic efficacy of FDG-PET scans, we employed ROC curve analysis as our primary statistical instrument. **Results:** Imaging studies through FDG-PET scans yielded a sensitivity value at 86.1% with a relatively lower specificity level standing at around 66.7%. These diagnostic parameters underscore the FDG-PET modality's particular strength in precise lesion localization. The imaging technique exhibited marked efficacy in delineating areas of concern, proving especially valuable in guiding targeted diagnostic sampling procedures. **Conclusion:** Despite exhibiting only moderate specificity, integrating FDG-PET imaging into surgical planning protocols afforded significant alterations in patient treatment plans. The modality's value manifests in two critical domains: detection and localization of malignant biliary obstructions and informing the subsequent management approach. It represents a valuable diagnostic and prognostic tool in the clinical context.

## INTRODUCTION

Accurately diagnosing neoplastic biliary occlusions, namely malignant biliary obstructions (MBO), presents a formidable challenge, and thus it often results in unwarranted invasive surgical interventions such as the Whipple procedure <sup>(1)</sup>. The primary tumors associated with MBOs tend to be small, which complicates their visualization through conventional imaging techniques <sup>(2)</sup>. Functional imaging modalities, including positron emission tomography with CT-integrated fluorodeoxyglucose scans (<sup>18</sup>F-FDG PET/CT), offer a broad range of advantages thanks to their high contrast and visibility between the lesion and background tissue, which is rather crucial for detecting subtle lesions. Prior research in the relevant literature notes that, in diagnostic differentiation of benign and malignant etiologies, this modality has detected a statistically marked disparity in their SUVmax values. The reported high diagnostic sensitivity, specificity, and

accuracy translates into robust diagnostic metrics in the identification of biliary tract malignancies <sup>(3)</sup>. However, conflicting results in the literature necessitate further investigation into the potential benefits of this method for diagnosing MBOs.

FDG-PET CT scans offer secondary advantages beyond diagnosis, including the ability to stage tumors and determine malignancy at a single session. On top of that, they also show promising capacity to inform and refine patient management strategies for a wide range of tumor types. Nevertheless, some studies have reported false-negative results for certain tumor pathologies <sup>(4)</sup>, while others have noted false-positive results owing to inflammation or infectious processes <sup>(5)</sup>. The relatively limited number of previous studies, coupled with their variable outcomes, underscores the need for further research in this area.

Therefore, the primary objective of this investigation was to undertake a comprehensive assessment of the diagnostic success achieved

through computed FDG-PET scans within the specific clinical context of malignant biliary obstruction. This research endeavor was an attempt to elucidate and refine our understanding of this advanced imaging modality's role in the detection and management of this challenging condition.

## MATERIALS AND METHODS

### Patients and ethical considerations

This study investigated a cohort of 45 individuals (25 men and 20 women). The average age of participants was 64. Prior to the commencement of any diagnostic assessments or interventions, a written informed consent was obtained from each patient in order to adhere to established ethical standards. Research protocol received formal ethical approval from the local Ethics Committee on May 27, 2022 (reference no. 2022-360).

### Inclusion criteria

Patients were eligible for inclusion if they exhibited signs of biliary obstruction, supported by laboratory results and imaging findings (CT, MRCP, and/or ERCP) that suggested the presence of a malignant process.

### F-18 FDG PET/CT imaging

In order to diagnose malignancy and pinpoint the primary tumor's location, FDG-PET CT scans were performed on each patient. We instructed patients to continue fasting for at least 4 hours and to limit physical activity for the 24 hours preceding the examination. Following quality control procedures, an average dose of 10 mCi (370 MBq) of MON.FDG (18F), manufactured at the Eczacıbaşı Monrol facility in Adana, was administered through intravenous route. Following approximately 60 minutes for the uptake of the substance, imaging was conducted on a Siemens Biograph mCT 20 PET system (Tennessee, USA), which was installed on January 30, 2018 (software version: VG62B). The imaging protocol included the following parameters: a standard energy level of 511 keV, a field of view of 780 mm, a 200 matrix, TrueX and Time of Flight (UltraHD-PET) reconstruction methods, 21 subsets, and 2 iterations. For attenuation correction, a low-dose CT scan was acquired with a slice thickness of 3 mm, 13-416 mAs, and 120 kVp.

### Image interpretation

An experienced nuclear medicine physician reviewed the images from the FDG-PET scans retrospectively. Lesions identified on CT scans coinciding with SUVmax values exceeding 2.5 were flagged as potentially malignant. PET/CT results were documented for all patients, along with any available pathology results. The final diagnoses were established by integrating the PET/CT findings,

pathology results (when available), laboratory data, and clinical follow-up observations.

### Statistical analysis

In this study, descriptive statistics were employed to further characterize the research data. Categorical variables were reported in the form of percentages and frequencies. On the other hand, continuous variables were summarized in the form of mean or average values as well as standard deviations (SD). ROC curve plots were employed to assess the diagnostic efficacy of FDG-PET scans. This method facilitated determination of optimal SUVmax values considered a threshold for discriminating between malignant and benign obstructions of the bile duct, thus enabling the calculation of the test's sensitivity and specificity. All statistical analyses were conducted on the demo version of MedCalc software package.

## RESULTS

The primary tumor lesions in this study measured an average of 29.8 mm in size and displayed a mean SUVmax of 13.7. Additionally, 31 patients were found to have metastatic sites, with a mean SUVmax value of 11.0. Pathological diagnoses were obtained in 31 patients (8 underwent Whipple procedures, the rest biopsies), with 29 confirmed as malignant (table 1). Five patients died during the course of the disease.

ROC curve analysis suggested an SUVmax cutoff value of 7.5 for malignancy, although it was not considered to be at significant levels ( $p=0.2636$ ) (figure 1). The sensitivity and specificity achieved using this cutoff were 81.6% and 66.7%, respectively. Importantly, FDG PET/CT enabled accurate diagnostic sampling and staging in 64.4% of patients (29 out of 45), ultimately influencing their management (figure 2) as demonstrated in the patient with true positive results.

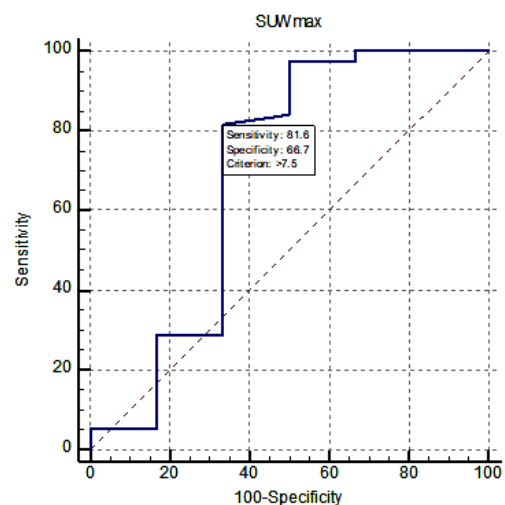
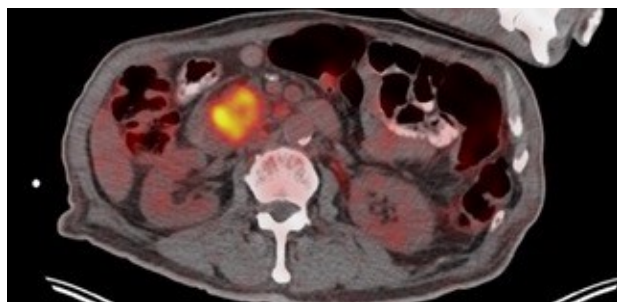


Figure 1. The results of the ROC analysis.

**Table 1.** The FDG PET/CT and pathology results of the patients.

Patient No	PET/CT	Pathology
1	Colon, liver, mesentery	Tubulovillous adenoma
2	Pancreas, lymph node	Adenocarcinoma
3	Liver, lymph node	Adenocarcinoma
4	Liver, lymph node	Cholangiocarcinoma
5	Liver, lymph node	Cholecystitis
6	Pancreas, lymph node	Adenocarcinoma
7	Pancreas	Adenocarcinoma
8	Liver	Adenocarcinoma
9	Liver	Squamous cell carcinoma
10	Liver, lymph node	Adenocarcinoma
11	Pancreas	Adenocarcinoma
12	Pancreas	Adenocarcinoma
13	Pancreas, lymph node	Adenocarcinoma
14	Pancreas, liver, colon	Adenocarcinoma
15	Lung, liver, lymph node, colon	Tubular adenoma
16	Supraclavicular lymph node	Gastritis
17	Pancreas, lymph node	Cholangiocarcinoma
18	Pancreas	Adenocarcinoma
19	Liver, lymph node	Adenocarcinoma
20	Pancreas, lymph node, liver	Adenocarcinoma
21	Liver, lymph node	Adenosquamous carcinoma
22	Pancreas	Adenocarcinoma
23	Pancreas, lymph node	Adenocarcinoma
24	Biliary, lymph node	Adenocarcinoma
25	Pancreas, lymph node	Malignant cytology
26	Pancreas, lymph node	Adenocarcinoma
27	Pancreas, lymph node	Adenocarcinoma
28	Liver, lymph node	Cholangiocarcinoma
29	Pancreas	Adenocarcinoma
30	Liver, lymph node	Cholangiocarcinoma
31	Pancreas	Neuroendocrine tumor
32	Mesentery	Adenocarcinoma
33	Pancreas	Nonmalignant

PET/CT: Positron emission tomography/Computed tomography.



**Figure 2.** Transaxial (A), sagittal (B) and horizontal (C) fusion images of the F-18 FDG PET/CT for a 72-year-old male patient who presented with icterus. The pathology results confirm a final diagnosis of adenocarcinoma of the duodenum. The primary lesion is located at the pancreatobiliary junction, measures 38 mm in size, and exhibits an SUVmax of 17.3. Additionally, there are adjacent small lymph nodes with an SUVmax of 6.5, suggesting possible regional spread.

## DISCUSSION

The assessment of biliary obstruction, a complex medical condition often requiring surgical

intervention, typically necessitates the use of a multitude of imaging and endoscopic procedures. Despite the comprehensive nature of these diagnostic approaches, some lesions remain stubbornly undetectable, posing a significant challenge for clinicians. Our study underscores the exceptional diagnostic accuracy achieved through 18F-FDG PET scans for precisely localizing optimal biopsy sites for tumors not otherwise visible through longstanding imaging modalities. FDG-PET scans offer a capacity to unveil these hidden lesions, a capacity well-established in research on pancreatic cancer, proves indispensable for accurate staging, the identification of recurrent disease, and the ongoing monitoring of treatment effectiveness (6). A comparative analysis of diagnostic modalities for pancreatic cancer revealed detection rates of 93% for endoscopic ultrasound (EUS), 87% for PET/CT, and a considerably lower 53% for computed tomography (CT), highlighting the superior sensitivity of the former two techniques (7).

On top of that, perhaps the most impactful contribution of FDG-PET scans is its unparalleled potential to allow visualization of occult metastatic lesions and metastases in distant sites, which can have significant implications for patient prognosis and treatment planning (8). A previous study involving patients with pancreatic carcinoma demonstrated that PET/CT findings directly influenced therapeutic decisions in a substantial 50% of cases (9).

In our current investigation focused on biliary obstruction, the impact of PET/CT was even more pronounced, with 64.4% of patients experiencing modifications to their management plans as a direct result of PET/CT findings. This technology proved instrumental in guiding clinical decision-making for almost every patient in our study cohort, enabling more accurate diagnoses and facilitating the development of tailored treatment strategies. These findings reinforce the value of 18F-FDG PET/CT as a powerful diagnostic instrument in the complex landscape of biliary obstruction management, offering the potential to improve patient outcomes and optimize treatment pathways.

A significant body of case reports have showcased the true potential of FDG-PET scans in detecting cholangiocarcinomas, yielding true positive results with elevated FDG uptake (10). However, false positive outcomes have also been observed, often linked to inflammatory processes, such as those surrounding biliary stents (11). Further, the literature has established that both direct tumoral invasion of the biliary system and obstruction caused by metastatic lymph node involvement can contribute to biliary obstruction (12, 13). Despite such compelling evidence, there is a scarcity of large-scale studies particularly investigating the diagnostic value of 18F-FDG PET/CT in patients with malignant biliary obstruction (13).

Both Wakabayashi *et al.* and Wang *et al.* report

that FDG-PET imaging modality can produce reliable results in the diagnosis of malignant biliary obstruction<sup>(14,15)</sup>. Wang *et al.*, in particular, reported a diagnostic accuracy of 75.8%, largely attributed to the modality's high specificity<sup>(15)</sup>. This remarkable level of accuracy can be attributed, in part, to their careful exclusion of patients who had recently undergone interventional procedures, such as percutaneous transhepatic cholangiography. Such invasive procedures can induce inflammatory or infectious responses in the biliary system, which in turn may lead to false-positive results on imaging studies through FDG-PET. By excluding such patients, Wang *et al.* minimized the risk of misinterpreting inflammation or infection as malignancy, thus enhancing the accuracy of their findings<sup>(15)</sup>. Therefore, including patients with recent interventions could indeed compromise the diagnostic precision of the imaging protocol as it may increase the ratio at which false-positive readings occur, making it more difficult to discriminate malignant conditions from benign ones.

Cholangiocarcinoma and pancreatic neoplasms represent significant primary etiologies in cases of biliary obstruction. FDG-PET imaging modality has demonstrated notable efficacy in detecting cholangiocarcinoma, even when presenting as small lesions<sup>(15)</sup>. Besides, this imaging modality has recently gained preference in assessing treatment response to neoadjuvant chemotherapy regimens<sup>(16)</sup>. A recent innovation in molecular imaging, Ga-68 fibroblast-activation protein inhibitor (FAPI) PET/CT, has shown much higher sensitivity than those achieved by FDG-PET scans within certain contexts. A prospective comparative study involving 16 patients with biliary tumors has yielded compelling evidence suggesting that FAPI PET/CT offers enhanced accuracy in tumor staging and facilitates more informed clinical decision-making<sup>(17)</sup>. The outperformance of FAPI PET/CT in this context highlights the dynamic advancement of molecular imaging in oncology. It offers a promising avenue for improving diagnostic and staging accuracy in biliary tract malignancies for better tailored and effective treatment strategies.

## CONCLUSION

Our investigation elucidates the potential utility of positron emission tomography with CT-integrated fluorodeoxyglucose scans as a precise visualization method in the clinical management of suspected malignant biliary obstruction. While the specificity was moderate, the imaging modality exhibited superior sensitivity in detecting malignant lesions and directing diagnostic sampling procedures, ultimately influencing patient management strategies. The study's findings, although constrained by its retrospective design and limited cohort size,

yield promising results that merit further exploration through larger, prospective clinical trials. The integration of FDG-PET scans into clinical examinations may enhance diagnostic accuracy, potentially leading to improved patient outcomes. While these findings appear to be promising, we must acknowledge that our study has certain limitations. Prospective research with larger samples is warranted to validate our findings and to establish standardized protocols for the integration of this novel imaging method into the diagnostic algorithm for suspected malignant biliary obstruction.

**Acknowledgement:** The abstract of this article was presented as a poster presentation in the EANM Congress at September 9-13, 2023 in Vienna /Austria

**Ethical considerations:** Adhering to the highest ethical standards, this study was conducted under the auspices of the Institutional Review Board of Mersin University (reference number: 2022/360). The research protocol was designed and executed in accordance with the principles enshrined in the revised Declaration of Helsinki (2013) and its subsequent amendments, ensuring the ethical treatment of all human participants. Prior to their involvement in the study, all participants provided written informed consent. In specific circumstances, and with the explicit approval of the Institutional Review Board, the requirement for written consent was waived. Such waivers were granted only when aligned with established institutional protocols and ethical guidelines.

**Availability of data and material:** Available in case of reasonable request.

**Competing interests:** All authors have nothing to disclose.

**Funding:** None.

**Authors' contributions:** All authors contributed equally for the data collection, analysis and interpretation of the results, manuscript drafting - writing and approval of final version of the manuscript. The statistical analysis of this study was performed by Prof Dr Gulhan Temel from Biostatistics Department of Mersin University.

## REFERENCES

1. Khan SA, Davidson BR, Goldin RD, *et al.* (2012) Guidelines for the diagnosis and treatment of cholangiocarcinoma: an update. *Gut*, **61**(12): 1657-1669.
2. Schulick RD (2008) Primary sclerosing cholangitis: detection of cancer in strictures. *J Gastrointest Surg*, **12**(3): 420-2.
3. Wang SB, Wu HB, Wang QS, *et al.* (2015) 18F-FDG PET/CT in differentiating malignant from benign origins of obstructive jaundice. *Hepatobiliary Pancreat Dis Int*, **14**(5): 516-22.
4. De Gaetano AM, Rufini V, Castaldi P, *et al.* (2012) Clinical applications of (18)F-FDG PET in the management of hepatobiliary and pancreatic tumors. *Abdom Imaging*, **37**(6): 983-1003.
5. Martins PN, Sheiner P, Facciuto M (2012) Xanthogranulomatous cholecystitis mimicking gallbladder cancer and causing obstructive cholestasis. *Hepatobiliary Pancreat Dis Int*, **11**(5): 549-52.
6. Delbeke D and Pinson CW (2004) Pancreatic tumors: role of

- imaging in the diagnosis, staging, and treatment. *J Hepatobiliary Pancreat Surg*, **11(1)**: 4-10.
7. Mertz HR, Sechopoulos P, Delbeke D (2000) EUS, PET, and CT scanning for evaluation of pancreatic adenocarcinoma. *Gastrointest Endosc*, **52(3)**: 367-71.
  8. Delbeke D, Chapman WC, Pinson CW, Martin WH, Beauchamp DR, Leach S (1999) F-18 fluorodeoxyglucose imaging with positron emission tomography (FDG PET) has a significant impact on diagnosis and management of pancreatic ductal adenocarcinoma. *J Nucl Med*, **40**:1784-92.
  9. Franke C, Klapdor R, Meyerhoff K, Schauman M (1999) 18-F Positron emission tomography of the pancreas: diagnostic benefit in the follow-up of pancreatic carcinoma. *Anticancer Res*, **19(4A)**: 2437- 42.
  10. Rajekar H (2017) Synchronous gall bladder and bile duct cancer: A short series of seven cases and a brief review of literature. *J Clin Exp Hepatol*, **7(2)**: 115-20.
  11. Nagasaki Y, Yamane H, Ochi N, Honda Y, Takigawa N (2016) High uptake of FDG along a biliary stent. *Clin Nucl Med*, **41(11)**: 890-1.
  12. Patel D and Lu Y (2015) FDG-PET/CT manifestation of tumor seeding along percutaneous biliary drainage catheter tract. *Clin Nucl Med*, **40(10)**: 830-1.
  13. O'Neill RS, Duong T, Dionela W, Rogge C, Brungs D (2020) Pancreatitis and biliary obstruction secondary to duodenal metastasis from rapidly progressing lung adenocarcinoma treated with common bile duct stenting. *Case Rep Oncol*, **13(2)**: 962-7.
  14. Wakabayashi H, Akamoto S, Yachida S, et al. (2005) Significance of fluorodeoxyglucose PET imaging in the diagnosis of malignancies in patients with biliary stricture. *Eur J Surg Oncol*, **31(10)**: 1175-9.
  15. Dubaniewicz A and Dubaniewicz A (2003) Cholangiocarcinoma--bile ducts cancer. *Wiad Lek*, **56(1-2)**: 57-60.
  16. Fujiwara Y, Ioka T, Matsui H, et al. (2021) A case of intrahepatic cholangiocarcinoma in the elderly patient with curative resection after neoadjuvant chemotherapy. *Gan To Kagaku Ryoho*, **48(13)**: 2085-7.
  17. Lan L, Zhang S, Xu T, et al. (2022) Prospective comparison of <sup>68</sup>Ga-FAPI versus <sup>18</sup>F-FDG PET/CT for tumor staging in biliary tract cancers. *Radiology*, **304(3)**: 648-57.

