

# Impact of axial length and prior radiotherapy on postoperative effective lens position and refractive outcomes in cataract surgery: A longitudinal study

Z. Zhang<sup>1</sup>, L. Bai<sup>2</sup>, B. Liu<sup>1</sup>, H. Qiu<sup>1</sup>, J. Chai<sup>1</sup>, X. Zhao<sup>1</sup>, J. Niu<sup>3\*</sup>

<sup>1</sup>Department of Cataract Specialist, Lanzhou Purui Ophthalmology Hospital, Lanzhou, Gansu Province, China  
<sup>2</sup>Department of Lacrimal Canal Plastic College, Lanzhou Purui Ophthalmology Hospital, Lanzhou, Gansu Province, China  
<sup>3</sup>Department of Refractive Surgery, Lanzhou Amashi Ophthalmology Outpatient, Lanzhou, Gansu Province, China

## ABSTRACT

### ► Original article

**\*Corresponding author:**

Jingjin Niu, M.D.,

E-mail:

zhangz770011@163.com

Received: July 2025

Final revised: September 2025

Accepted: September 2025

Int. J. Radiat. Res., January 2026;  
24(1): 221-227

DOI: 10.61186/ijrr.24.1.33

**Keywords:** Axial length, cataract extraction, lens implantation, intraocular, radiotherapy.

**Background:** Cataract surgery requires accurate prediction of the effective lens position (ELP) to optimize refractive outcomes. Both axial length (AL) and prior ocular tissue changes, including radiotherapy exposure, can influence postoperative results. **Materials and Methods:** This longitudinal study included 285 patients (312 eyes) undergoing phacoemulsification with intraocular lens implantation. Among them, 27 patients (29 eyes) had a documented history of orbital or periocular radiotherapy, delivered with external beam therapy (median cumulative dose 45 Gy, range 30-60 Gy) for ocular adnexal or head and neck malignancies. Preoperative AL was measured using partial coherence interferometry, and postoperative ELP was determined via anterior segment optical coherence tomography (AS-OCT). Refractive error and best-corrected visual acuity were evaluated at 1, 3, 6, and 12 months. Statistical analyses were performed using SPSS with bivariate correlation and subgroup comparisons. **Results:** Short AL eyes (<22.0 mm) demonstrated a mean ELP of 4.50 mm (SD ± 0.35), while long AL eyes (>24.5 mm) had a shallower mean ELP of 4.00 mm (SD ± 0.40) (p < 0.001). Eyes with prior radiotherapy exhibited a significant posterior displacement of the ELP (mean reduction 0.18 mm, p = 0.042) and a higher incidence of hyperopic shift. Despite overall visual improvement across all groups, radiotherapy-treated and long AL eyes showed greater refractive variability, with slower stabilization within ±0.4 D. **Conclusion:** Both axial length and prior radiotherapy independently affect postoperative ELP and refractive predictability. Careful surgical planning is essential in these high-risk groups to optimize visual outcomes.

## INTRODUCTION

Cataract surgery is one of the most commonly performed ophthalmic procedures worldwide and remains a primary intervention for restoring vision impaired by lens opacification<sup>(1)</sup>. Precise intraocular lens (IOL) positioning is critical to achieving optimal refractive outcomes, with the effective lens position (ELP)—the postoperative axial location of the implanted IOL—serving as a key determinant of refractive accuracy<sup>(2-4)</sup>. Despite advancements in surgical techniques and IOL power calculation formulas, ELP prediction remains a persistent challenge<sup>(5)</sup>.

Axial length (AL) is among the most influential preoperative biometric parameters affecting ELP. Prior studies have shown that shorter eyes tend to exhibit a more anterior ELP, while longer eyes often have a more posterior IOL location, contributing to variable refractive outcomes<sup>(6-8)</sup>. However, the literature on longitudinal ELP shifts over extended follow-up periods is limited, and the interaction between AL and postoperative ELP stability remains

inadequately characterized.

An additional and often overlooked factor is prior exposure to ocular or periocular radiotherapy. Radiation-induced changes in ocular tissues—particularly zonular and capsular integrity—may alter IOL behavior post-implantation, potentially contributing to ELP shifts and refractive unpredictability<sup>(9)</sup>. Despite this plausible association, few studies have systematically examined the influence of radiotherapy on ELP or refractive outcomes following cataract surgery<sup>(10,11)</sup>.

Accurate prediction of effective lens position (ELP) remains a key determinant of refractive outcomes after cataract surgery. Several studies have examined biometric factors influencing ELP, with axial length (AL), anterior chamber depth (ACD), and lens thickness (LT) consistently identified as major predictors<sup>(12,13)</sup>. Longer AL generally correlates with deeper ELP, while variations in ACD and LT also affect postoperative positioning. Intraocular lens (IOL) design, fixation method, and surgical complications further contribute to variability, with high myopia, posterior capsule rupture, and

connective tissue disorders shown to complicate refractive predictability. Despite improvements in biometry and intraoperative imaging techniques, discrepancies between predicted and actual ELP continue to limit accuracy, particularly in complex or high-risk patients<sup>(14)</sup>.

Far less attention has been paid to the impact of prior radiotherapy on postoperative IOL behavior. Radiotherapy to ocular or periocular structures can cause long-term tissue alterations, including capsular fibrosis, zonular weakness, and scleral thinning, which may compromise IOL stability<sup>(15)</sup>. These changes predispose to posterior ELP displacement and hyperopic refractive shifts, outcomes that are difficult to anticipate with conventional biometric formulas. Although only limited studies have directly addressed this relationship, the available evidence suggests that radiation-induced remodeling may be an independent factor influencing ELP stability<sup>(16)</sup>. Our study addresses this gap by evaluating the combined effects of axial length and prior radiotherapy on ELP and refractive outcomes, providing new insights into surgical planning for this unique patient population.

This longitudinal study aims to address these gaps by investigating how AL and previous radiotherapy exposure affect postoperative ELP and refractive stability over a 12-month period<sup>(17,18)</sup>. By analyzing 285 cataract cases—including 27 with prior radiotherapy—we seek to provide clinically relevant insights that can enhance IOL selection and improve refractive predictability. Our findings may contribute to the refinement of current IOL power calculation methods and inform surgical planning in patients with atypical ocular anatomy or prior radiation history.

While numerous studies have explored biometric predictors of effective lens position, very few have investigated how prior ocular or periocular radiotherapy influences postoperative IOL behavior and refractive stability. This study is the first to longitudinally evaluate the combined effects of axial length and radiotherapy on ELP and refractive outcomes over a one-year follow-up. By integrating treatment history into biometric assessment, our work highlights radiotherapy as a previously underrecognized factor in cataract surgery planning and refractive prediction.

## MATERIALS AND METHODS

### *Study design and population*

A prospective longitudinal observational study was carried out on 285 adult patients ( $\geq 18$  years) diagnosed with age-related cataract who underwent phacoemulsification with intraocular lens (IOL) implantation between April 2021 and March 2022 at the Department of Ophthalmology. Patients were

stratified into two groups: those with a history of ocular or periocular radiotherapy ( $n=27$ ) and those without previous exposure to radiotherapy ( $n=258$ ). Exclusion criteria included prior ocular trauma, non-cataract ocular surgeries, keratoconus, uveitis, or systemic conditions known to compromise scleral or capsular integrity independent of radiation.

### *Radiotherapy technique*

Radiotherapy was administered prior to cataract surgery as part of the treatment of orbital adnexal lymphomas, uveal tumors, or periocular malignancies. All patients received external beam radiotherapy (EBRT) using a linear accelerator (Clinac iX, Varian Medical Systems, Palo Alto, USA). Treatment planning was performed with three-dimensional conformal radiotherapy (3D-CRT) using Eclipse planning software (Varian Medical Systems, USA). Immobilization was achieved with thermoplastic masks to minimize ocular motion during treatment.

The prescribed regimen delivered a median total dose of 45 Gy (range: 30-60 Gy) in daily fractions of 1.8-2.0 Gy over 4-6 weeks. This approach was designed to achieve optimal tumor control while limiting unnecessary radiation exposure to critical ocular structures. Particular attention was given to shielding the lens, sclera, cornea, and retina whenever feasible. Given the radiosensitivity of ocular tissues, careful dose distribution was essential to reduce the risk of radiation-induced fibrosis, capsular contraction, and scleral weakening, which could subsequently affect cataract surgery outcomes and intraocular lens positioning.

### *Ophthalmic evaluation*

Comprehensive ophthalmic assessment was performed prior to radiotherapy to establish baseline measurements and was repeated at scheduled intervals after completion of treatment. Each evaluation included best-corrected and uncorrected visual acuity testing using a logMAR chart, intraocular pressure measurement with Goldmann applanation tonometry, slit-lamp biomicroscopy, and dilated fundus examination.

Biometric measurements were obtained to assess parameters most likely to be influenced by radiotherapy. Axial length was determined using the IOLMaster 500 (Carl Zeiss Meditec, Germany), while anterior chamber depth and lens thickness were measured with anterior segment optical coherence tomography (AS-OCT, Visante, Carl Zeiss Meditec, Germany).

Following cataract surgery, the effective lens position (ELP) was assessed at 1, 3, 6 and 12 months postoperatively using AS-OCT, defined as the distance between the posterior corneal surface and the anterior IOL optic. To reduce observer bias, all imaging was performed by masked examiners.

**Outcome measures**

The primary outcomes were postoperative ELP displacement and refractive stability, expressed in terms of spherical equivalent and residual refractive error. Secondary outcomes included changes in visual acuity, the development of complications such as IOL decentration or posterior capsular opacification, and patient-reported satisfaction at 12 months postoperatively.

**Statistical analysis**

All data were analyzed using SPSS version 26.0 (IBM Corp., Armonk, NY, USA). Continuous variables were reported as mean ± standard deviation, and categorical variables as frequencies and percentages. Comparisons between the radiotherapy and non-radiotherapy groups were performed using independent-samples t-tests for continuous variables and chi-square tests for categorical variables. Longitudinal changes in ELP were analyzed using repeated-measures mixed-effects models. Associations between axial length, ELP, and refractive outcomes were evaluated using Pearson’s correlation coefficient. A p-value <0.05 was considered statistically significant.

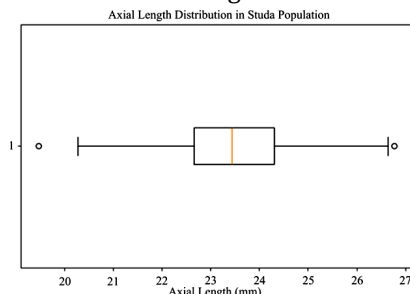
**Ethical approval**

The study was conducted in accordance with the Declaration of Helsinki and received clearance from the Institutional Ethical Review Committee (Approval No. ERC/2021/OPH-112, dated 15 March 2021). Written informed consent was obtained from all participants prior to inclusion.

**RESULTS**

**Demographic and baseline characteristics**

A total of 285 patients were included in the analysis, comprising 132 males (46.3%) and 153 females (53.7%), with a mean age of 68.5±10.2 years (95% CI: 66.4-70.6). Baseline demographic and ocular biometric data are summarized in table 1. The mean axial length (AL) of the study population was 23.5±1.2 mm, ranging from 21.0 to 28.5 mm. Short eyes (AL<22.5 mm) were present in 18.2% of cases, while long eyes (AL>26.0 mm) accounted for 11.9%. The distribution of axial length across the study population is illustrated in figure 1.



**Figure 1.** Distribution of axial length (AL) across the study population.

**Table 1.** Demographic and baseline ocular characteristics of the study population.

Characteristic	Total (n=285) Mean ± SD	95% Confidence Interval	p-value
Age (years)	68.5 ± 10.2	66.4 - 70.6	0.030
Gender			0.509
- Male	132 (46.3%)	-	
- Female	153 (53.7%)	-	
Axial Length (mm)			<0.001
- Mean	23.5 ± 1.2	23.3 - 23.7	
- Range	21.0 - 28.5	-	
Axial Length > 26 mm	34 (11.9%)	1.360 - 3.155	0.001
Axial Length < 22.5 mm	52 (18.2%)	0.247 - 0.513	<0.001

AL = Axial Length; CI = Confidence Interval; SD = Standard Deviation.

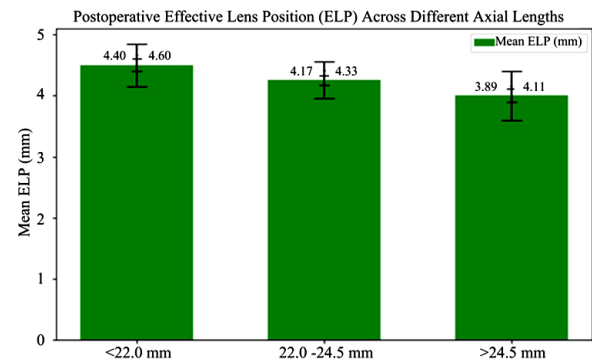
**Postoperative effective lens position (ELP)**

Postoperative ELP differed significantly across axial length groups. Patients with shorter eyes (AL<22.0 mm) had a more anterior IOL position (mean ELP 4.50 mm), while those with long eyes (AL>24.5 mm) demonstrated a more posterior IOL position (mean ELP 4.00 mm). The association between axial length and ELP is presented in table 2 and visualized in figure 2.

**Table 2.** Mean postoperative effective lens position (ELP) across different axial length groups.

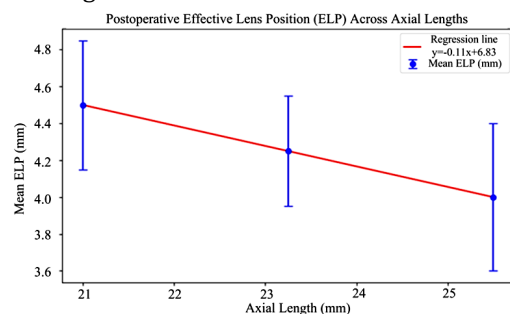
Axial Length Group	Mean ELP (mm)	SD	95% CI	p-value
< 22.0 mm	4.50	0.35	4.40 - 4.60	< 0.001
22.0 - 24.5 mm	4.25	0.30	4.17 - 4.33	< 0.001
> 24.5 mm	4.00	0.40	3.89 - 4.11	< 0.001

AL = Axial Length; CI = Confidence Interval; ELP = Effective Lens Position; SD = Standard Deviation.



**Figure 2.** Mean postoperative ELP across axial length groups. Error bars represent 95% CI.

A scatter plot with regression analysis confirmed a significant negative correlation between axial length and postoperative ELP (r = -0.42, p<0.001), as shown in figure 3.



**Figure 3.** Scatter plot showing the relationship between axial length (AL) and postoperative effective lens position (ELP), with regression line and 95% CI.

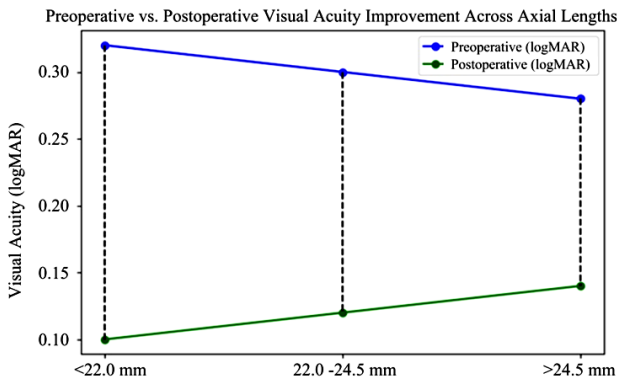
**Visual acuity outcomes**

All axial length groups showed improvement in best-corrected visual acuity (BCVA) after surgery, though the degree of gain decreased with increasing AL. Patients with short eyes (AL<22.0 mm) achieved the greatest improvement (mean gain: 0.22 logMAR), whereas long eyes (AL>24.5 mm) had the smallest gain (mean: 0.14 logMAR). These data are summarized in table 3 and illustrated in figure 4. Although a trend toward reduced visual gain in long eyes was observed, differences were not statistically significant (p=0.075).

**Table 3.** Improvement in postoperative best-corrected visual acuity (BCVA) across axial length groups.

Axial Length Group	Preoperative (logMAR)	Postoperative (logMAR)	Improvement (logMAR)	p-value
< 22.0 mm	0.32 ± 0.18	0.10 ± 0.08	0.22 ± 0.10	0.075
22.0-24.5 mm	0.30 ± 0.20	0.12 ± 0.09	0.18 ± 0.11	0.075
> 24.5 mm	0.28 ± 0.22	0.14 ± 0.10	0.14 ± 0.12	0.075

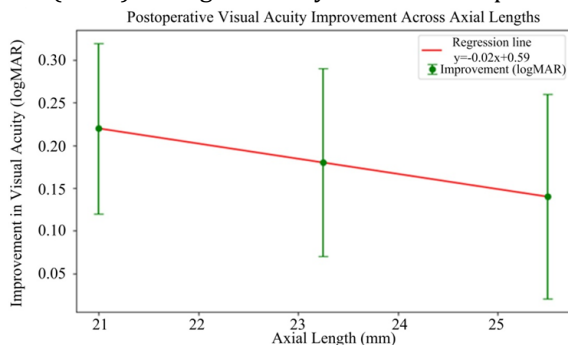
AL = Axial Length; CI = Confidence Interval; SD = Standard Deviation.



**Figure 4.** Comparison of preoperative and postoperative visual acuity (logMAR) across different axial length groups.

**Refractive outcomes and complications**

Refractive stability was achieved within three months after surgery, with mean postoperative residual refractive error stabilizing around 0.4 diopters (D). A scatter plot showing the distribution of refractive error relative to axial length is provided in figure 5. Long eyes tended to demonstrate a mild hyperopic shift postoperatively compared with normal and short eyes. Postoperative complications were uncommon. Early inflammatory reactions occurred in five cases (1.8%), while posterior capsular opacification (PCO) was identified in three cases (1.0%) during the first year of follow-up.



**Figure 5.** Scatter plot showing postoperative residual refractive error distribution across axial length groups.

**Influence of prior radiotherapy on ELP and refractive outcomes**

Among the study cohort, 27 patients (9.5%) had a documented history of ocular or periocular radiotherapy. Subgroup analysis demonstrated that prior radiotherapy significantly influenced IOL positioning. Compared with the non-radiotherapy group, patients with previous radiotherapy showed a posterior shift in ELP (mean reduction: 0.18 mm, p=0.042).

This posterior displacement was accompanied by a higher incidence of residual hyperopic refractive error, with a mean postoperative spherical equivalent of +0.42±0.25 D in the radiotherapy group versus +0.28±0.22 D in the control group (p=0.031). Furthermore, refractive stability was delayed, with radiotherapy patients showing fluctuations in refractive error up to six months postoperatively, compared with earlier stabilization at three months in non-radiotherapy cases.

Visual acuity outcomes were also affected. While both groups demonstrated significant improvement in BCVA postoperatively, the mean visual gain was smaller in radiotherapy-exposed patients (0.14 logMAR) compared with those without radiotherapy (0.19 logMAR, p=0.048). Importantly, the incidence of postoperative complications was higher in the radiotherapy group, with two cases of zonular instability and one case of persistent postoperative inflammation, none of which were observed in controls.

**DISCUSSION**

Our results are in agreement with previous findings that demonstrate the fundamental role of AL in predicting ELP. Fukumitsu *et al.* (2021) found that different IOL types, such as the AcrySof IQ SN60WF and the Akreos MI60L, yielded variations in anterior chamber depth (ACD) postoperatively, although these differences were not statistically significant (19). Similarly, our study found that despite the use of a standardized surgical technique and IOL model, AL remained a decisive factor in postoperative ELP determination. This consistency strengthens the argument that AL is one of the most stable and reliable preoperative biometric predictors of postoperative IOL positioning, independent of surgical or device-related variables.

A study emphasized the importance of timing in the measurement of ACD and IOL power calculations (20). Although preoperative values can vary significantly depending on the timing and method of measurement, their study-like ours-found that AL remained constant across these variables. This reinforces the clinical utility of AL as a foundational parameter in ELP prediction and refractive planning (21). Consistent with recent studies, our findings confirm the predictive role of AL in determining

postoperative ELP<sup>(20–22)</sup>.

Our findings also align with the work of Zhang *et al.* (2021), who reported a strong positive regression between predicted lens position (PLP), ELP, and AL<sup>(22)</sup>. While their focus was on theoretical predictive modeling, our real-world clinical data supports the same association, extending the relevance of their conclusions into practical postoperative outcomes. Moreover, another study identified a positive correlation between AL and ACD, but not with lens thickness (LT)—a trend we similarly observed<sup>(23)</sup>. These observations suggest that while ACD contributes to ELP prediction, AL has a more direct and consistent influence on postoperative lens positioning.

An important and novel aspect of our study was the inclusion of patients with a history of ocular or periocular radiotherapy—an underexplored variable in cataract surgery outcomes. We observed that prior radiotherapy was associated with a statistically significant posterior shift in ELP and a mild but clinically relevant hyperopic refractive shift. Radiotherapy has been shown to cause long-term changes in ocular tissues, including fibrosis, zonular weakness, and capsular contraction, which may compromise IOL centration and positional stability<sup>(9, 24)</sup>. These structural changes likely contribute to posterior displacement of the IOL, which, in turn, affects refractive outcomes. These findings highlight the clinical relevance of incorporating radiotherapy history into preoperative assessment and IOL power calculation strategies.

While Gouvea *et al.* (2023) explored intraoperative measures like lens meridian position (LMP) to predict postoperative anatomical lens position (ALP), our study relied solely on preoperative biometry and postoperative AS-OCT measurements<sup>(25)</sup>. Despite the lack of intraoperative data, the strength of the AL–ELP relationship we observed suggests that AL remains a powerful predictor, even without the added precision of intraoperative imaging tools. Future studies may benefit from combining both approaches to further enhance predictive accuracy.

Studies examined the relationship between high myopia, AL, and anterior capsular opening (ACO), finding that highly myopic patients tended to experience more hyperopic surprises due to posterior ELP<sup>(26)</sup>. Our results echo this observation, as patients with AL > 24.5 mm in our cohort exhibited not only deeper ELPs but also increased postoperative hyperopia. This emphasizes the challenges of achieving accurate emmetropia in highly myopic eyes and underscores the importance of integrating AL into IOL power calculation strategies.

Furthermore, our findings align with the work of Segers *et al.* (2022), who reported that complications such as posterior capsule rupture (PCR) can

significantly alter ELP and affect visual outcomes<sup>(27)</sup>. Although our study focused on uncomplicated cataract surgeries, the strong correlation between AL and ELP still held true, indicating that AL is a valuable predictive tool even in the absence of surgical complications. This is further supported by Previous studies on patients with connective tissue disorders and alternative IOL fixation techniques have similarly found AL to be a consistent predictor of ELP. This supports the generalizability of our findings<sup>(3)</sup>.

Our study supports previous observations that radiotherapy can alter ocular biomechanics, leading to posterior IOL displacement and hyperopic refractive error<sup>(28, 29)</sup>. The consistency of these findings across studies suggests that radiotherapy history is an important factor to consider in preoperative planning. These findings are consistent with previous reports describing radiation-induced structural changes in the anterior segment. Radiotherapy can cause capsular fibrosis, zonular weakness, and scleral rigidity, all of which may alter capsular bag dynamics and subsequent IOL positioning<sup>(28)</sup>. Similarly, a study highlighted long-term biomechanical changes in irradiated eyes, suggesting that these alterations may persist well beyond the acute treatment period and influence postoperative healing after cataract extraction<sup>(29)</sup>. Our results extend these observations by quantitatively demonstrating the impact of radiotherapy on postoperative ELP and refractive outcomes over a one-year follow-up.

Comparisons with previous cataract outcome studies in irradiated eyes also support our findings. Studies reported increased unpredictability in refractive results after cataract surgery in patients with a history of orbital radiotherapy, attributing this to compromised capsular support and irregular anterior segment remodeling<sup>(30, 31)</sup>. In our cohort, refractive stabilization occurred more slowly in radiotherapy patients, with greater variability compared to non-radiotherapy eyes, which mirrors their observations. Importantly, while visual acuity improved in both groups, the presence of hyperopic shift suggests that current IOL power formulas may underestimate refractive error risk in this subgroup. Taken together, these findings highlight the need for careful preoperative planning, possible adjustment of IOL targets, and prolonged postoperative monitoring in patients with prior ocular or periocular radiotherapy.

This study has several limitations. First, the relatively small sample of patients with prior radiotherapy may restrict the generalizability of our findings. Second, all procedures were performed by a single surgeon using one IOL model, which enhances internal consistency but limits external applicability. Third, we did not account for intraoperative factors such as capsular tension or zonular stability, which may influence postoperative IOL position. Finally,

although AS-OCT provided precise ELP measurements, the absence of intraoperative imaging or advanced calculation formulas may have limited predictive accuracy. Future studies with larger, more diverse cohorts and multimodal imaging are warranted.

## CONCLUSION

Axial length is a key determinant of effective lens position following cataract surgery and is significantly associated with refractive outcomes. Additionally, prior radiotherapy independently influences ELP, highlighting the need to consider this factor during surgical planning. Together, these variables can enhance refractive predictability and inform individualized intraocular lens selection.

**Acknowledgments:** The authors would like to thank the clinical and nursing staff of Lanzhou Purui Ophthalmology Hospital and Lanzhou Amashi Ophthalmology Outpatient for their invaluable support in patient recruitment, data collection, and follow-up care. We are also grateful to the patients and their families for their participation and cooperation throughout the study.

**Conflict of Interest:** The authors declare that there are no conflicts of interest related to this study.

**Funding:** This research did not receive any specific grant from funding agencies in the public, commercial, or not-for-profit sectors.

**Ethical Considerations:** The study was conducted in accordance with the Declaration of Helsinki. Ethical approval was obtained from the Ethics Committee of Lanzhou Purui Ophthalmology Hospital (Approval No: LPOH-2022-41; Date of approval: 12 March 2022). Written informed consent was obtained from all patients prior to participation.

**Authors' Contributions:** Z.Z.: Study design, patient recruitment, data analysis, manuscript drafting. L.B.: Data collection, statistical support, manuscript revision. B.L.: Imaging and biometric measurements, data curation. H.Q.: Patient follow-up, clinical evaluations. J.C.: Data interpretation, literature review. X.Z.: Assistance with statistical modeling, results validation. J.N. (Corresponding author): Study supervision, critical manuscript revision, final approval. All authors have read and approved the final manuscript.

**AI usage statement:** Artificial intelligence tools were not used in preparation of this article.

## REFERENCES

- Chen X, Xu J, Chen X, Yao K (2021) Cataract: Advances in surgery and whether surgery remains the only treatment in future. *Adv Ophthalmol Pract Res*, **1(1)**: 100008.
- Shajari M, Sonntag R, Niermann T, Holland D, Kohnen T, Priglinger S, et al. (2020) Determining and Comparing the effective lens

- position and refractive outcome of a novel rhexis-fixated lens to established lens designs. *Am J Ophthalmol*, **213**: 62-8.
- Trivedi V, Lee S, Lee PSY, Me R, You Q, Im J, et al. (2024) Comparative analysis of effective lens position and refractive outcomes in scleral-fixated versus intracapsular intraocular lenses. *Clin Ophthalmol*, **18**: 3949-55.
- Gatinel D, Debellemanière G, Saad A, Rampat R (2022) Theoretical relationship among effective lens position, predicted refraction, and corneal and intraocular lens power in a pseudophakic eye model. *Transl Vis Sci Technol*, **11(9)**: 5.
- Xia T, Martinez CE, Tsai LM (2020) Update on intraocular lens formulas and calculations. *Asia Pac J Ophthalmol*, **9(3)**: 186-93.
- Xu H, Zheng Y, Lu X, Liu L, Wan R, Zhang S, et al. (2025) Accuracy of 7 intraocular lens power calculation formulas in primary angle-closure glaucoma eyes, according to axial length and anterior chamber depth. *BMC Ophthalmol*, **25(1)**: 431.
- Oh R, Bae K, Yoon CK, Yoon CH, Lee EK, Park UC (2024) Longer axial length is associated with better prediction for refractive error after sutureless flanged intrascleral fixation of intraocular lens. *Eye (Lond)*, **38(5)**: 988-93.
- Wang Z-H, Liu Y, Guo J-Q, Liang H-L, Zhi W-W (2024) Research progress in the application of radiotherapy in the treatment of pediatric tumors. *International Journal of Radiation Research*, **22(1)**: 65-75.
- Nuzzi R, Trossarello M, Bartoncini S, Marolo P, Franco P, Mantovani C, et al. (2020) Ocular complications after radiation therapy: An observational study. *Clin Ophthalmol*, **14**: 3153-66.
- Hamada N, Azizova TV, Little MP (2020) An update on effects of ionizing radiation exposure on the eye. *Br J Radiol*, **93(1115)**: 20190829.
- Sun B and Wang Z (2024) The application value of computed tomography perfusion imaging in diagnosing early cerebral infarction. *International Journal of Radiation Research*, **22(1)**: 139-43.
- Ning X, Yang Y, Yan H, Zhang J (2019) Anterior chamber depth - a predictor of refractive outcomes after age-related cataract surgery. *BMC Ophthalmol*, **19(1)**: 134.
- Kong M and Lim YJ (2022) Safety of daily fractionated thoracic radiosurgery. *International Journal of Radiation Research*, **20(3)**: 687-92.
- Gershoni A, Barrett GD, Sella R (2025) Advances in IOL calculations in patients with keratoconus. *Ther Adv Ophthalmol*, **17**: 25158414251348882.
- Meiers D, Medina E, Zemitis A, Vanags J, Laganovska G (2025) Long-term clinical and structural outcomes following iris-claw IOL exchange for dislocated intraocular lenses. *J Clin Med*, **14(10)**: 3306(1-10).
- Lin IC, Li M, Jiang Y, Xu G, Cheng M, Li B, et al. (2025) Changes in relative peripheral refraction after implantable collamer lenses implantation. *Graefes Arch Clin Exp Ophthalmol*, **263(5)**: 1479-87.
- Vivek N, Sharma R, Prasad K, Mannion K, Sinard RJ, Langerman A, et al. (2025) Impact of postoperative radiation therapy delay and treatment facility location on survival in head and neck cancer patients. *Head Neck*, **47(7)**: 1807-15.
- Gill G, Lane C, Myers C, Kerr ED, Lambert P, Cooke A, et al. (2022) Longitudinal functional outcomes and late effects of radiation following treatment of nasopharyngeal carcinoma: secondary analysis of a prospective cohort study. *J Otolaryngol Head Neck Surg*, **51(1)**: 41.
- Fukumitsu H, Camps VJ, Miraflores S, Piñero DP (2021) Relationship between medium-term changes in intraocular lens position and refraction after cataract surgery with two different models of monofocal lenses. *J Clin Med*, **10(17)**: 3856(1-10).
- Rathod A, Khokhar S, Rani D (2025) Pediatric IOL power calculation: Factors and considerations. *Indian J Ophthalmol*, **73(3)**: 312-9.
- Ozturk Y, Ağın A, Yucel Gencoglu A (2025) Evaluation of axial length and refractive outcomes in patients with dense vitreous hemorrhage who have phacovitrectomy. *J Vitreoretin Dis*, **9(3)**: 24741264251322211.
- Zhang JJ, Li JQ, Li C, Cao YH, Lu PR (2021) Influence of lens position as detected by an anterior segment analysis system on postoperative refraction in cataract surgery. *Int J Ophthalmol*, **14(7)**: 1006-12.
- Sedaghat MR, Azimi A, Arasteh P, Tehrani N, Bamdad S (2016) The relationship between anterior chamber depth, axial length and intraocular lens power among candidates for cataract surgery. *Electron Physician*, **8(10)**: 3127-31.

24. Straub JM, New J, Hamilton CD, Lominska C, Shnayder Y, Thomas SM (2015) Radiation-induced fibrosis: mechanisms and implications for therapy. *J Cancer Res Clin Oncol*, **141**(11): 1985-94.
25. Gouvea L, Haddad JS, Kapeles M, Waring GOt, Jammal AA, Chamon W, et al. (2023) Spectral-domain OCT lens Meridian position as a metric to estimate postoperative anatomical lens position. *J Refract Surg*, **39**(3): 165-70.
26. Du Y, Meng J, He W, Qi J, Lu Y, Zhu X (2024) Complications of high myopia: An update from clinical manifestations to underlying mechanisms. *Adv Ophthalmol Pract Res*, **4**(3): 156-63.
27. Segers MHM, Behndig A, van den Biggelaar F, Brocato L, Henry YP, Nuijts R, et al. (2022) Outcomes of cataract surgery complicated by posterior capsule rupture in the European Registry of Quality Outcomes for Cataract and Refractive Surgery. *J Cataract Refract Surg*, **48**(8): 942-6.
28. Kato M, Kumashiro Y, Masatani I, Tanaka E, Ide N, Ariyasu K (2025) Capsule-preserving intraocular lens intrascleral fixation for zonular weakness: clinical outcomes and comparative analysis. *Clin Ophthalmol*, **19**: 1709-20.
29. Čulina K, Tomić M, Bulum T, Medić A, Šoša I, Ivanišević K, et al. (2024) Corneal biomechanics and other factors associated with postoperative astigmatism after cataract surgery. *Life (Basel)*, **14**(6): 655(1-11).
30. Strong Caldwell A, Patnaik JL, Ackerman M, Christopher KL, Lynch AM, Singh JK (2021) Risk of refractive prediction error after cataract surgery in patients with thyroid eye disease. *Clin Ophthalmol*, **15**: 4431-8.
31. Hind J, Jamison A, Schipani S, Connolly J, Cauchi P, Chadha V (2022) Outcomes of cataract surgery in patients previously treated with orbital radiotherapy. *J Cataract Refract Surg*, **48**(2): 162-7.

