

## Ultrasonic characteristics of cutaneous Rosai-Dorfman disease: A case study

Y. Qin<sup>1,2#</sup>, S-r. Liu<sup>1#</sup>, G-l. Wu<sup>2</sup>, L. Jiang<sup>1</sup>, S. Tan<sup>1\*</sup>

<sup>1</sup>Department of Ultrasound, Peking University Third Hospital, Beijing, China  
<sup>2</sup>Department of Ultrasound, People's Hospital of Rongcheng, Rongcheng, China

### ► Case report

#### \*Corresponding author:

Shi Tan, M.D.,

E-mail: [tanshi@hsc.pku.edu.cn](mailto:tanshi@hsc.pku.edu.cn)

Received: February 2025

Final revised: July 2025

Accepted: July 2025

*Int. J. Radiat. Res.*, January 2026;  
24(1): 293-295

DOI: 10.61186/ijrr.24.1.44

**Keywords:** Ultrasound, cutaneous Rosai-Dorfman disease, color Doppler.

### ABSTRACT

**Background:** Cutaneous Rosai-Dorfman disease (CRDD) is an uncommon histiocytic proliferative disorder localized to the skin, representing merely 3% of all reported cases of Rosai-Dorfman disease (RDD). Despite numerous investigations into the clinical and pathological attributes of CRDD, there are few works on its ultrasonic manifestations, with the majority of studies being limited to individual case reports.

**Case presentation:** This paper presents the case of a 66-year-old female who exhibited red nodules on the skin of her face, accompanied by pruritus, which persisted for 2 years and notably affected her quality of sleep. Clinical assessment substantiated a diagnosis of CRDD, and subsequent ultrasound imaging revealed a low-echo nodule. The nodule (2.4 cm by 0.4 cm) was identified within the skin of the right eyebrow and exhibited pronounced blood flow. Following multiple sessions of targeted treatment, there was a notable improvement in the lesion, and no recurrence was detected during subsequent follow-up evaluations. **Conclusion:** This case exemplifies the typical ultrasound features associated with CRDD and underscores the limitations inherent in ultrasound diagnostics, thereby highlighting the vital importance of histopathological assessment.

### INTRODUCTION

Rosai-Dorfman disease (RDD) is an infrequent disorder characterized by the proliferation of histiocytes, primarily affecting lymphatic tissues<sup>(1)</sup>. A specific variant termed cutaneous Rosai-Dorfman disease (CRDD) manifests exclusively as skin lesions, devoid of any lymphatic or systemic involvement, and this particular form is even rarer, accounting for approximately 3% of all RDD cases<sup>(2)</sup>. Recently, RDD has been reclassified as an R group histiocytosis<sup>(3)</sup> based on its molecular and genetic attributes while CRDD is categorized as a C group histiocytosis. Of the relatively few case reports of CRDD, most have focused on its clinical and pathological characteristics<sup>(4-7)</sup>, as well as dermatoscopic findings<sup>(8-10)</sup>. Few have addressed the imaging features of CRDD, particularly in relation to ultrasound characteristics<sup>(11-13)</sup>. Here, we report a case involving a 66-year-old female patient who presented with palpable masses on the skin of her right eyebrow, accompanied by erythematous papules. During the ultrasound examination, a coupling pad was employed to enhance the visualization of both the internal and peripheral structures of the lesions. The ultrasound features were distinct from those of previously reported CRDD cases that mimicked inflammatory skin lesions, thus providing new insights into the ultrasound presentation of this rare condition.

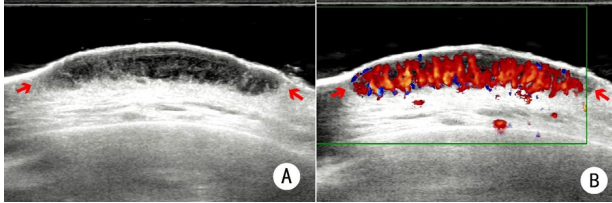
### CASE REPORT

A 66-year-old female patient presented to our

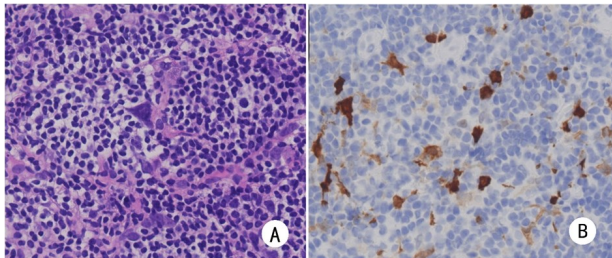
clinic with erythematous nodules on her face that had been pruritic for 2 years, resulting in disturbances in her sleep patterns. The facial nodules showed significant regression following corticosteroid treatment for a cold; however, they quickly recurred after she stopped taking the medication. Over the previous year, the nodule had experienced substantial growth and assumed a hemispherical shape. The symptoms exhibited a spectrum ranging from moderate to severe. The patient had been diagnosed with diabetes 1 year prior, which was managed with an oral dose of metformin (Metamide, China) at a rate of 0.5 tablets twice daily. Her hypertension had been managed for 15 years with oral antihypertensive therapy (specific medication unclear). Dermatological evaluation revealed a red hemispheric nodule approximately 2 cm in diameter located on the inner side of the right eyebrow arch. The surface texture of the affected skin was smooth yet irregular, and palpation caused discomfort. Additional red papules were noted on the forehead, cheeks, and near the ears.

Ultrasound examination using a Samsung RS85 device (18 MHz probe, sound guide pad; Chaoji, China) identified a hypoechoic nodule within the dermis of the right eyebrow arch, measuring approximately 2.4 × 0.4 cm. The lesion had a raised surface, intact epidermis, regular contours, a flat and well-defined base, and heterogeneous internal echotexture. In color Doppler imaging, an excessive blood flow signal was recorded within the nodule (figure 1). Histopathological examination was

performed. The epidermis appeared normal; however, the dermis, extending from its full thickness to the resection margin, exhibited lymphohistiocytic infiltration. Immunohistochemical analysis revealed widespread S-100 staining (figure 2). The clinical diagnosis established was CRDD.



**Figure 1.** Ultrasonographic features of a nodule on the right eyebrow. **A:** Grayscale ultrasound. A hypoechoic nodule is seen in the dermal layer (arrow), showing an elevated surface, a continuous epidermal layer, regular morphology, clear and flat base, and uneven internal echo (probe frequency = 18 MHz). **B:** Color Doppler ultrasound showing abundant blood flow signals within the nodule (probe frequency = 18 MHz).



**Figure 2.** Pathology of the arch nodule: **A:** A large lymphohistiocytic infiltration is seen (H&E,  $\times 40$ ) **B:** Positive S-100 expression ( $\times 40$ ).

The patient received local occlusive treatment for facial nodules consisting of 7 mg depotaxone (Diprosan, Belgium) and 0.1 g lidocaine hydrochloride (Hualu, China), administered four times at intervals of 2–3 months. Initially, oral thalidomide (50 mg twice daily; Reflection Pavilion, China) was prescribed; however, due to dizziness reported after 2 weeks, the regimen was adjusted to methotrexate (10 mg six times weekly; Maoxiang, China) combined with topical halometasone cream (2 g twice daily; Ausen, Hong Kong, China). After 2 months, the lesions were smaller and less pigmented. After more than eight treatment sessions across a 1-month period, the facial nodules had resolved completely, with only mild residual erythema observed on the eyebrow arch and in front of the ears. At the 1.5-year follow-up, the condition was stable without recurrence.

## DISCUSSION

CRDD is a rare histiocytic proliferative disorder affecting the skin, typically manifesting as gradually enlarging, non-tender nodules, plaques, or papules that may vary in color from yellow to red or brown (14). Kong *et al.* (15), categorized CRDD skin lesions into three distinct types: papular-nodular, confluent

plaque, and tumor. In the case discussed, the patient exhibited multiple dermatological lesions localized to the facial region, with a brow lesion identified as a tumor type, while lesions in other areas were classified as papular-nodular.

At present, most studies on the ultrasound characteristics of CRDD are case reports. For instance, Zhong *et al.* (10) documented a multifocal CRDD case affecting the skin in the axillary, thigh, and abdominal regions, where ultrasound imaging revealed characteristics akin to inflammatory dermal lesions, albeit without local erythema or elevated skin temperature. Wang *et al.* (11) described a CRDD case with a lesion on the left arm, where standard ultrasound findings suggested inflammatory reactive lesions; contrast-enhanced ultrasound exhibited a “trunk-like” progressive enhancement pattern of the lesion, marked by uneven high enhancement and the classic “fast in and fast out” phenomenon.

Contrary to reports suggesting that CRDD shares ultrasound characteristics with inflammatory skin lesions, the imaging findings in our case were consistent with those commonly seen in noninvasive benign dermal masses. Despite the broad surface area of the lesion, its depth was limited to the dermis, with a well-demarcated and flat base. These observations align with the findings of Bruce-Brand *et al.* (3). The evolving understanding of RDD reflects a shift from its traditional classification as a reactive, non-clonal disorder toward recognition of potential neoplastic underpinnings.

Recent studies have identified clonal driver mutations (e.g., KRAS, MAP2K1, NRAS, ARAF, CSF1R), suggesting possible links to tumorigenic mechanisms. Nonetheless, the present case did not display ultrasound features characteristic of CRDD, highlighting the limitations of ultrasonography as a diagnostic tool for this entity. Clinicians should maintain a high index of suspicion for CRDD when assessing cutaneous or subcutaneous lesions, especially those with multifocal presentation, as part of a comprehensive differential diagnosis. Beyond the characteristic features of lesions, a conclusive diagnosis predominantly depends on histopathological examination. The histological characteristics associated with CRDD typically include infiltration of lymphoid cells and, crucially, positive expression of the S100 protein. Common treatment modalities for CRDD include surgical procedures, localized therapies, and systemic treatments (7). In certain instances, the condition may spontaneously resolve, allowing patients to opt for a watchful waiting approach rather than active intervention when they are asymptomatic (15).

Our patient exhibited multifocal skin lesions that were superficial and confined to the dermis; these lesions were managed with a combination of therapeutic strategies rather than surgical excision. Post-treatment assessment showed significant

regression of the facial nodules, leaving only a few residual mild erythema. After a follow-up period of 18 months, the patient's condition had remained stable with no indications of recurrence, thereby reinforcing the efficacy of pharmacological treatment for superficial lesions.

This case offers novel insight into the ultrasound characteristics of CRDD, advancing imaging diagnostics and providing a clinical reference for future applications. Ultrasound, aided by a coupling pad, was used to assess accurately the extent of the lesion. The findings suggest that conservative pharmacologic therapy may offer an effective treatment option and inform future management strategies for similar cases. However, these conclusions require validation through larger-scale studies. The absence of elastography and contrast-enhanced ultrasound in this case also underscores current limitations in imaging modalities. Future research should focus on standardizing ultrasound protocols for CRDD and refining diagnostic techniques. As knowledge of CRDD expands, a more comprehensive understanding of its sonographic features will enhance clinicians' diagnostic precision.

**Acknowledgments:** The authors extend their sincere gratitude to the patient involved in this study.

**Conflicts of interest declaration:** The authors have no conflicts of interest to report.

**Funding:** The authors received no funding.

**Ethical considerations:** This case report received ethical approval from the Institutional Review Board of Peking University Third Hospital (Approval No. IRB00006761-M2024470). To protect the patient's privacy, her identity has been anonymized.

**Authors' contributions:** Y.Q. and S.R.L. conceptualized and designed the study. Y.Q. authored the initial draft. G.L.W. and L.J. performed a thorough literature review and contributed significantly to writing the discussion of the manuscript. S.R.L. and S.T. reviewed and revised the manuscript. All authors read and approved the final manuscript.

**AI usage for manuscript preparation:** Grammarly

was used to enhance the fluency of the language and rectify any grammatical errors. The final content was rigorously reviewed and approved by the authors to ensure its academic integrity.

## REFERENCES

- Liu T and Cao XX (2022) Advances in the diagnosis and treatment of Rosai-Dorfman disease. *Basic & Clinical Medicine*, **42**(11): 1785-1790. Chinese.
- Al-Khateeb TH (2016) Cutaneous Rosai-Dorfman disease of the face: A comprehensive literature review and case report. *J Oral Maxillofac Surg*, **74**(3): 528-540.
- Bruce-Brand C, Schneider JW, Schubert P (2020) Rosai-Dorfman disease: an overview. *J Clin Pathol*, **73**(11): 697-705.
- Ahmed A, Crowson N, Magro CM (2019) A comprehensive assessment of cutaneous Rosai-Dorfman disease. *Ann Diagn Pathol*, **40**: 166-173.
- Kong YY, Kong JC, Shi DR, et al. (2007) Cutaneous Rosai-Dorfman disease: a clinical and histopathologic study of 25 cases in China. *Am J Surg Pathol*, **31**(3): 341-350.
- Zhang DZ, Pu XM, Yu SR, Ding Y, Kang XJ (2018) Clinical manifestations and histopathological characteristics analysis of cutaneous Rosai-Dorfman disease. *Chinese Journal of Dermatology*, **51**(3): 173-176. Chinese.
- Zhang Y, Chen H, Sun JF (2019) Research progress on cutaneous Rosai-Dorfman disease. *Chinese Journal of Dermatology*, **52**(2): 138-141. Chinese.
- Yang Z, Yu WT, Liu ZH, Bian K, Xu FM, Shen H (2021) Dermoscopy and reflectance confocal microscopy for the diagnosis of generalized pure cutaneous Rosai-Dorfman disease. *Skin Res Technol*, **27**(2): 288-290.
- Shen X, Wang WJ, Wang ZY, Cui Y (2020) Dermoscopic and reflectance confocal microscopic findings of cutaneous Rosai-Dorfman disease. *Chin Med J (Engl)*, **134**(1): 112-114.
- Litaïem N, Trimech R, Daoud Y, et al. (2025) Cutaneous involvement in Rosai-Dorfman disease: clinical and dermoscopic features. *Int J Dermatol*, **64**(5): 939-941.
- Zhong L and Qiu L (2016) Ultrasonographic presentation of a case of cutaneous multilocular rhododendrosis. *Chinese Journal of Medical Imaging Technology*, **32** (7): 1147-1148. Chinese.
- Wang J, Liu YJ, Huang K, Li X (2023) Diagnosis of a case of cutaneous Rosai-Dorfman disease by real-time contrast-enhanced ultrasound-guided percutaneous biopsy. *Chinese Journal of Medical Imaging Technology*, **39** (2): 294. Chinese.
- Badlissi F, Pihan GA, Corominas H (2020) Rosai-Dorfman disease: Ultrasonography and histopathology study of a soft tissue mass in the forearm. *Reumatol Clin (Engl Ed)*, **16** (2 Pt 2): 174-176.
- Abla O, Jacobsen E, Picarsic J, et al. (2018) Consensus recommendations for the diagnosis and clinical management of Rosai-Dorfman-Destombes disease. *Blood*, **131**(26): 2877-2890.
- Zhang P, Liu F, Cha Y, Zhang X, Cao M (2021) Self-limited primary cutaneous Rosai-Dorfman disease: A case report and literature review. *Clin Cosmet Investig Dermatol*, **14**: 1879-1884.

