

Unique constellation of multimodal imaging findings in a case of unilateral agenesis of the right internal carotid artery

A. Baskar*, V. Indiran, V. Vignesh, I. Rajkumar

Department of Radiodiagnosis, Sree Balaji Medical College and Hospital, Chromepet, Chennai, India

► Case report

*Corresponding author:

Baskar A., M.D.,

E-mail:

baskarmrd@gmail.com

Received: January 2025

Final revised: July 2025

Accepted: July 2025

Int. J. Radiat. Res., January 2026;
24(1): 297-300

DOI: 10.61186/ijrr.24.1.45

Keywords: Carotid arteries, cerebral arteries, CT scan, MRI, congenital anomalies.

INTRODUCTION

Congenital anomalies of the internal carotid artery (ICA), such as aplasia, agenesis, and hypoplasia, are considerably rare, manifesting in <0.01% of the population^(1, 2). We use the term “absent ICA” for simplification. This condition is usually found incidentally on the computed tomography (CT) or magnetic resonance imaging (MRI) findings of the head and neck performed for some other reason. Most patients do not present any symptoms related to sufficient cerebral circulation being maintained by the communicating arteries of the circle of Willis (CW), intercavernous anastomosis, external carotid artery, and persistent embryologic artery to the carotid artery. However, carotid artery agenesis is linked to subarachnoid hemorrhage and intracranial aneurysms⁽³⁾. Anomalies of the aortic arch and intracranial vessels are best visualized on MR and CT angiography. Right internal carotid agenesis associated with anomalies of the aortic arch and intracranial vessels has not been reported previously.

CASE REPORT

A 58-year-old female patient visited the neurology outpatient clinic with a complaint of numbness in the right upper limb for 6 months along with tremors and lethargy. She had no other known comorbidities.

Doppler ultrasonography of the neck (GE P7 ultrasound system, Boston, USA) using probe

ABSTRACT

Background: Congenital anomalies of the internal carotid artery (ICA), such as agenesis, aplasia, and hypoplasia, are considerably rare, occurring in less than 0.01% of the population. Recognition of these anomalies is critical, as they may alter cerebral hemodynamics and impact clinical management. **Case Presentation:** We report a rare case of unilateral agenesis of the right ICA in an adult, incidentally detected during Magnetic resonance imaging (MRI). This anomaly was associated with several unusual vascular features: hypoplasia of the right common carotid artery, aberrant origin of the right subclavian artery from the aortic arch, and a hypoplastic right vertebral artery. Intracranial findings included basilar artery bifurcation supplying the right middle cerebral artery, fetal origin of the left posterior cerebral artery, and an anomalous origin of the right ophthalmic artery from the cavernous segment of the left ICA. Despite these extensive vascular variations, the patient was asymptomatic. **Conclusion:** Early diagnosis and knowledge of this unusual constellation of findings in patients with ICA agenesis are crucial for the optimization of clinical treatment and planning of possible surgical treatment in the future.

frequency at 5 ~ 12 MHz showed a small-diameter right common carotid artery (CCA), a missing right carotid bifurcation, a nonexistent right ICA, and the CCA continuing as the right external carotid artery. On spectral Doppler, these arteries exhibited high-resistance flow with a narrow systolic peak and a low diastole. Brain CT (Siemens GO 32 slice CT scan, Germany) using thin section (thickness 0.6 mm) bone window (WL: -1043 WW 5890) revealed the missing bony carotid canal on the right side (figure 1a, b).

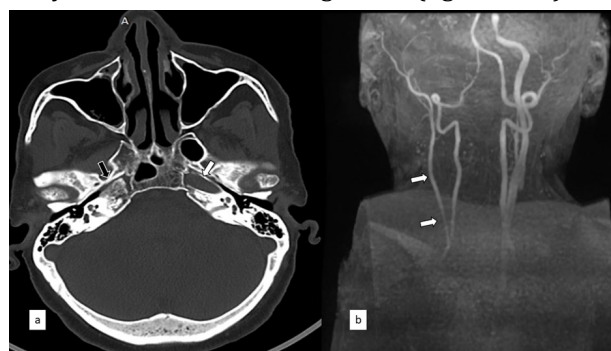


Figure 1. (a) Axial reformatted CT skull base (bone window) shows the absence of the right carotid canal (black arrow) and a normally developed left carotid canal (white arrow). (b) Time of flight (TOF) MRA with coronal maximum intensity projection (MIP) of the neck vessels shows a complete absence of the right ICA with small-caliber right common carotid artery continuing as external carotid artery (white arrows).

MRI T2-weighted axial images (GE 3T MRI System, USA) showed a nonexistent right ICA flow void. The

patient also underwent a three-dimensional time-of-flight MR angiography (3D-TOF-MRA) (TR/TE-23/6.9 ms) for the brain and CW evaluation with MIP reconstructions (figures 2 - 4). No aneurysm or subarachnoid hemorrhage was noted. MR neck angiography exhibited a few aortic arch anomalies, including the completely missing ICA (figure 1a and b), hypoplastic right CCA (figure 1b), and aberrant origin of the right subclavian artery (figure 3b). Furthermore, MR brain angiography showed the basilar artery bifurcating into the right middle cerebral artery (MCA) and right PCA (figure 2 a); the right PCOM was absent (figure 2a). The left PCA had a fetal origin (figure 2b). The right ACA's A1 segment was absent (figure 3a), and it was supplied by the contralateral ACA (figure 3a). The right ophthalmic artery emerged from the left ICA's cavernous segment (figure 4a). The right vertebral artery was hypoplastic (figure 4b).

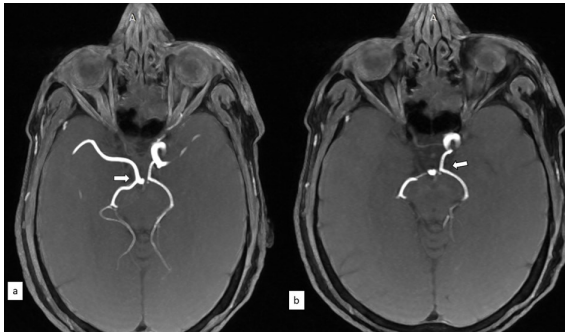


Figure 2. Source image from a 3D time-of-flight MR angiogram shows (a) Basilar artery bifurcation into a right middle cerebral artery (MCA) and right PCA (white arrow). (b) Fetal origin of left PCA (white arrow).

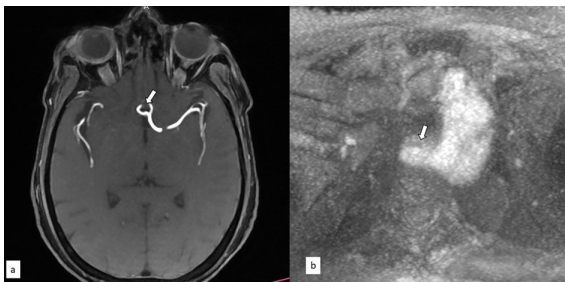

Figure 3. Source image from a 3D time-of-flight MR angiogram shows (a) absent A1 segment of right and the right ACA arising from left ACA (white arrow). (b) Neck angiography shows the aberrant origin of the right subclavian artery (white arrow).

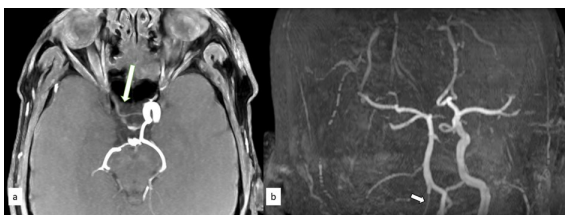


Figure 4. Source image from a 3D time-of-flight MR angiogram shows (a) the Origin of the right ophthalmic artery from a cavernous segment of the left ICA (white arrow). Time of flight (TOF) MRA with maximum intensity projection (MIP) of the intracranial arteries shows (b) a complete absence of the right ICA with the hypoplastic vertebral artery (arrow).

DISCUSSION

In 1787, Tode first reported a case of carotid agenesis, which was identified after postmortem examination. Subsequently, in 1954, Verbiest presented the first ICA agenesis case, and they determined it through cerebral angiography. Unilateral ICA agenesis might be caused by intrauterine hemodynamic or mechanical stress (4,5).

The CW forms during the embryonic development stage when the embryo measures between 7 and 24 mm. In ICA agenesis, the pattern of collateral blood circulation to the distal ICA and its ending intracranial blood vessels relies on the development stage when the disruption occurs. If the disruption occurs post the 24-mm development stage, collateral blood supply via the CW would mainly be responsible for it (4).

In the case of a missing ICA, three collateral routes are identified, namely flow via the CW, through persistent fetal vessels, and from external carotid artery's branches (6). The blood flow routes associated with ICA agenesis are categorized by Lie as types A- F (1, 4, 6). Type A: represents a missing ICA on one side, with collateral blood circulation to the ACA and MCA on the same side through an anterior communicating artery (ACOM) and an enlarged posterior communicating artery (PCOM), respectively. Type B: represents one-sided ICA absence with collateral blood supply to the MCA and ACA on the same side through a functioning ACOM artery. Type C: represents missing ICA on both sides, with blood being supplied anteriorly through carotid-vertebrobasilar connections and an enlarged PCOM. Type D: represents one-sided agenesis of cervical ICA sections, with collateral circulation being maintained by the ICA's cavernous segment on the other side through an intercavernous link. Type E: represents enlarged PCOM supplying blood to the bilateral hypoplastic ICAs, which give rise to the ACA and MCA. In Type F, transcranial connections from the ECA's branches, referred to as the rete mirabile supply to the ICA (3).

According to this classification, our case is type A, which involves a right-sided absent ICA with collateral blood flow from the left ACA to the right ACA and from the basilar system to the right MCA. A study reported a 3:1 left-sided predominance of ICA agenesis, with right-side agenesis being relatively rare (4).

Ultrasonography with Doppler examination of the neck (CDUS) is widely employed in the diagnosis of carotid artery disease due to its simple operation, repeatability, and non-invasive nature (7). It also serves as a crucial screening modality for identifying carotid agenesis, by detecting features such as absence of ipsilateral carotid bifurcation, a hypoplastic and small-caliber common carotid artery (CCA), and reduced blood flow, as observed in the

present case (2, 5). Cross-sectional studies (MRI and CT) are excellent for confirming findings. CT temporal bone study reveals the absent or hypoplastic carotid canal, which is used to differentiate congenital absence from acquired occlusion (3). In recent years, computed tomography angiography (CTA) has been increasingly utilized in clinical practice for head and neck imaging due to its non-invasive nature, ease of operation, and cost-effectiveness (8).

MRI is another noninvasive imaging modality that can be employed to diagnose the nonexistence of the carotid artery and its collateral blood supply. Here we used MR angiography to document the basilar artery's bifurcation into the right PCA and MCA, which has not been yet described. Although the right subclavian artery's aberrant origin has been described in left ICA agenesis once (9), no study has yet reported its link with right ICA agenesis. A fully developed adult-form ophthalmic artery can be identified at the 40-mm embryonic developmental stage. The artery emerges from the ICA distal to the dural ring (10). The unusual origin of the ophthalmic artery from the anterior cerebral artery, middle meningeal artery, accessory meningeal artery, basilar artery, MCA, PCOM, anterior deep temporal artery, and external carotid artery has been well described (11, 12). The aberrant origin of the ophthalmic artery through the cavernous segment of the contralateral ICA observed, in this case, was reported only once before. Detailed knowledge of collateral vascular pathways and variations in ophthalmic artery origin is essential in patients with internal carotid artery agenesis, especially when performing procedures like trans-arterial embolization, carotid endarterectomy, or trans-sphenoidal pituitary surgery (13).

Congenital ICA absence is a benign finding and tends to cause occasional symptoms; however, it is significantly related to cerebral aneurysms. The increased occurrence of aneurysms is often attributed to augmented flow via collateral vessels and alterations in flow dynamics (1, 2). If such aneurysms are detected in time, the patient can be saved from major neurological complications (2, 6). Patients with these conditions may initially present symptoms linked with cerebrovascular insufficiency. Although the projected prevalence of cerebral aneurysms is between 2% and 4% in the general population, its documented prevalence in relation to ICA's absence is between 24% and 34% (5). Therefore, for a patient with ICA agenesis, vigilant screening for aneurysms is crucial; none were found in our patient. Carotid agenesis diagnosis is crucial in conditions such as thromboembolic disease. Patients undergoing carotid endarterectomy in contralateral atherosclerotic CCA may be more prone to major neurological deficits because the complete anterior blood supply may rely on the vertebrobasilar system or on a single carotid artery (4, 6).

Recognizing this variant is also important to

prevent incorrect diagnoses, such as severe carotid stenosis or carotid dissection. A case was described wherein ICA hypoplasia was misinterpreted as the angiographic string sign, which is commonly linked to severe carotid stenosis (4).

CONCLUSION

Knowledge of this unusual constellation of findings in patients with ICA agenesis is crucial for optimization of clinical treatment, planning of possible surgical treatment in the future, careful screening for small intracranial aneurysms and awareness of the large potential for the thromboembolic event.

Acknowledgement: Nil.

Funding: There is no funding.

Conflict of interest: Author declares that they have no conflict of interest.

Ethical approval: All procedures performed in studies involving human participants were in accordance with the ethical standards of the institutional and/or national research committee and with the 1964 Helsinki Declaration and its later amendments or comparable ethical standards.

Informed consent: Informed consent was obtained from individual participants included in the study.

Author contributions: B.A., Data collection, Manuscript writing, Literature review. V.I., Data interpretation, Manuscript editing. V.V., Data collection and interpretation. I.R., Data collection and interpretation. All authors reviewed and approved the final manuscript.

AI usage: No use of AI assistance in this manuscript.

REFERENCES

1. Kumaresh A, Vasanthraj P, Chandrasekharan A (2015) Unilateral agenesis of internal carotid artery with intercavernous anastomosis: A rare case report. *J Clin Imaging Sci*, 5(1): 1-4.
2. Guimarães AC, Pessoa TDB, Moreira RH, de Araujo WJB (2018) Agnesis of the internal carotid artery. *J Vasc Bras*, 17(3): 243-7.
3. Choh NA, Choh SA, Jehangir M (2008) Right internal carotid artery agenesis. *Indian J Pediatr*, 75(12): 1269-71.
4. Given CA, Huang-Hellinger F, Baker MD, Chepuri NB, Pearse Morris P (2001) Congenital absence of the internal carotid artery: Case reports and review of the collateral circulation. *Am J Neuroradiol*, 22(10): 1953-9.
5. Kaya O, Yilmaz C, Gulek B, Soker G, Cikman G, Inan I, et al. (2014) An important clue in the sonographic diagnosis of internal carotid artery agenesis: Ipsilateral common carotid artery hypoplasia. *Case Rep Radiol*. 2014: Article ID 124918. doi:10.1155/2014/124918.
6. Montoya S, Towner J, Bhatt A (2017) Unilateral agenesis of the internal carotid artery with intracavernous carotid-carotid anastomosis. *Appl Radiol*, 46(10): 19-22.
7. Guo L, Guo X, Kong R (2025) Value of color Doppler ultrasonography in diagnosis of carotid atherosclerotic plaque in cerebral infarction patients. *Int J Radiat Res*, 23(1): 245-248. DOI: 10.61186/ijrr.23.1.245.
8. Liu H, Zhao Z, Xu H, Chen W, Lu Q, Chen X (2024) Diagnostic value of head and neck computed tomography angiography in combination with color Doppler ultrasonography in carotid artery stenosis in ischemic stroke patients. *International Journal of*

Radiation Research. **22**(4): 869-73.

9. Naeini RM, De J, Satow T, Benndorf G (2005) Unilateral agenesis of the internal carotid artery with ophthalmic artery arising from the posterior communicating artery. *Am J Roentgenol*, **184**(2): 571-3.
10. Kahraman AS, Kahraman B, Ozdemir ZM, Dogan M, Kaya M, Gormeli CA, et al. (2016) Congenital agenesis of right internal carotid artery: A report of two cases. *Jbr-Btr*, **100**(1) :1-4.
11. Yang SK, Zhang A, Hazany S, Huang J, Hathout GM, et al. (2022) MR angiographic findings of aberrant right subclavian artery with agenesis of the left common carotid artery and anomalous origin of the vertebral arteries. *Clinical Imaging*, **84**: 31-35.
12. Zhou WZ, Zhao LB, Liu S, Shi HB (2015) Teaching neuroImages: Unilateral agenesis of the internal carotid artery with an ophthalmic artery from the opposite side. *Neurology*, **84**(9): e65-6.
13. Kulhari A, Singh A, Fourcand F, Zacharatos H, Mehta S, Kirmani JF (2023) Internal carotid artery agenesis: a rare entity. *Cureus*, **15**(3): e36640. doi:10.7759/cureus.36640