Iran. J. Radiat. Res., 2011; 9(3): 201-205

- *Case report*

A 8-year survivor of unresectable intrapelvic desmoplastic small round cell tumor treated with concurrent chemoradiotherapy

J.I. Saitoh[1*], H. Ishikawa[1], T. Ebara[1], H. Katoh[1], T. Ohno[1], T. Takahashi[1], T. Akimoto[2], T. Nakajima[3], T. Nakano[1]

[1]Department of Radiation Oncology, Gunma University Graduate School of Medicine, 3-39-22, Showa-machi, Maebashi, Gunma 371-8511, Japan
[2]Department of Radiology, Tokyo Women's Medical University 8-1, Kawada-cho, Shinjuku, Tokyo, 162-8666, Japan
[3]Department of Pathology, Shizuoka Cancer Center 1007, Shimonagakubo, Nagaizumi, Shizuoka, 411-8777, Japan

Desmoplastic small round cell tumor is a rare malignant tumor that occurs primarily in young males. Here, a case of small round cell tumor in an adult male successfully treated with a curative concurrent chemoradiotherapy is presented. A 58-year-old man had an intrapelvic tumor. Surgical resection was attempted, but the tumor was unresectable. Needle biopsy was performed and the diagnosis was suggested to be desmoplastic small round cell tumor. Concurrent chemoradiotherapy was performed, and a complete response was obtained. This patient has been alive for 8 years after treatment with no evidence of disease. Concurrent chemoradiotherapy appears to be a useful treatment choice for unresectable desmoplastic small round cell tumor.
Iran. J. Radiat. Res., 2011; 9(3): 201-205

Keywords: *desmoplastic small round cell tumor, concurrent chemoradiotherapy, retroperitoneum.*

INTRODUCTION

Desmoplastic small round cell tumor (DSRCT) is a rare malignant tumor observed primarily in male children and young adults. It is a highly aggressive tumor that commonly develops as a large abdominal mass with widespread peritoneal involvement at the time of diagnosis [(1)]. Treatment outcomes of this disease are generally disappointing, and it leads to death in most cases, despite the performance of surgical resection, radiation therapy, and/or chemotherapy. Furthermore, DSRCT is extremely rare in elderly patients, and no effective therapeutic modalities for the elderly have been identified. In this report, a case of retroperitoneal small round cell tumor in an adult male successfully treated with concurrent chemoradiotherapy (CCRT) is presented.

CASE REPORT

The subject was a 58-year-old man with a history of chronic hepatitis C infection. In May 2001, he visited a local hospital with the chief complaint of pain in the perineal region; an intrapelvic neoplasm was suspected. Pathological examination by needle biopsy was performed, and the tumor was primarily diagnosed as small cell carcinoma. Surgical resection was attempted, but the tumor was determined to be unresectable due to extensive peritoneal invasion and adhesion to the bladder and rectosigmoid colon. As a result, ileal conduit diversion and colostomy were performed. The patient was then admitted to our hospital to receive radiation therapy. He had been smoking 20 cigarettes per day for 40 years (Brinkman's index: 800). Laboratory

Corresponding author:
Dr. Jun-ichi Saitoh,
Department of Radiation Oncology, Gunma University Graduate School of Medicine, 3-39-22, Showa-machi, Maebashi, Gunma 371-8511, Japan.
Fax: *+81 27 220 8397*
E-mail: *junsaito@gunma-u.ac.jp*

[Downloaded from ijrr.com on 2026-11-28]

studies showed elevated levels of lactate dehydrogenase (594 IU/l) and tumor markers such as neuron-specific enolase (18.9 ng/ml) and progastrin-releasing peptide (286.5 pg/ml). Magnetic resonance imaging (MRI) showed a large mass located between the bladder and the rectosigmoid colon with low signal intensity on T1 weighted images and heterogeneous intensity on T2 weighted images (figure 1). Computed tomography (CT) with contrast media demonstrated a heterogeneously enhanced mass lesion with low-density areas (figure 2). The tumor size had increased rapidly within the previous several weeks, but no distant metastasis was observed. Histologically, the lesion was composed of tumor nests of various sizes embedded in abundant fibrous stroma (figure 3). The tumor cells had small round or oval shaped nuclei with hyperchromasia and scanty cytoplasm (figure 4). Immunohistochemical staining revealed that the tumor cells had strong positive immunoreactivity for keratin and mic2 (figure 5). Conversely, the tumor cells were weakly positive for neuron-specific enolase, and negative for chromogranin, synaptophysin, S-100, vimentin, smooth muscle actin, and epithelial membrane antigen. On the basis of these findings, the histological diagnosis was suggested to be DSRCT rather than primitive neuroectodermal tumor.

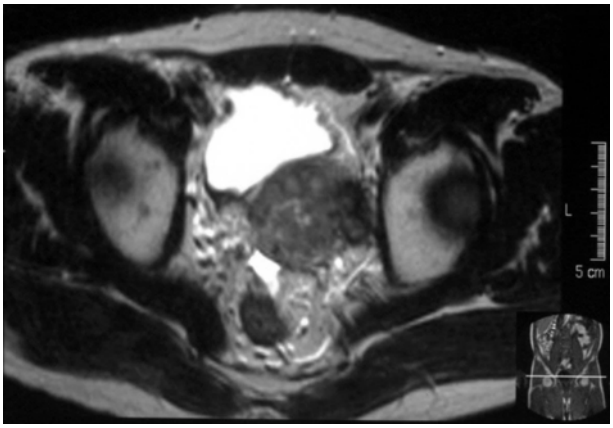

Figure 1. T2 weighted MR image of the pelvis. A large mass was located between the bladder and the rectosigmoid colon. The tumor showed low intensity on T1 weighted images and appeared heterogeneous on T2 weighted images.

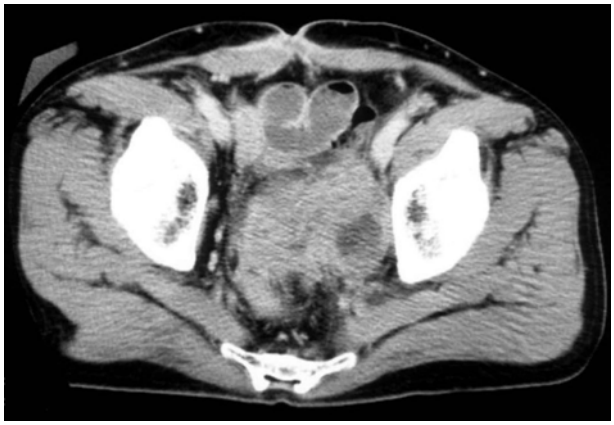

Figure 2. Computed tomography image with contrast media before treatment. The heterogeneously enhanced mass lesion was located in the pelvis, with low density areas within the mass.

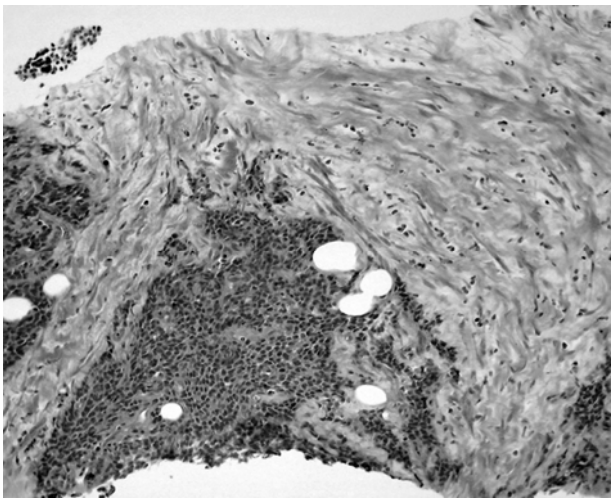

Figure 3. Histological findings of the needle biopsy specimen. Tumor nests were embedded in abundant fibrous stroma.

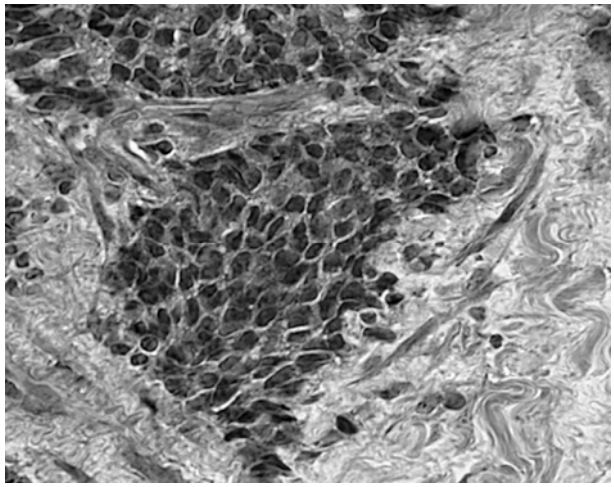

Figure 4. Histological findings, higher magnification. The tumor cells had small round or oval shaped nuclei with hyperchromasia and scanty cytoplasm.

[Downloaded from ijrr.com on 2026-11-28]

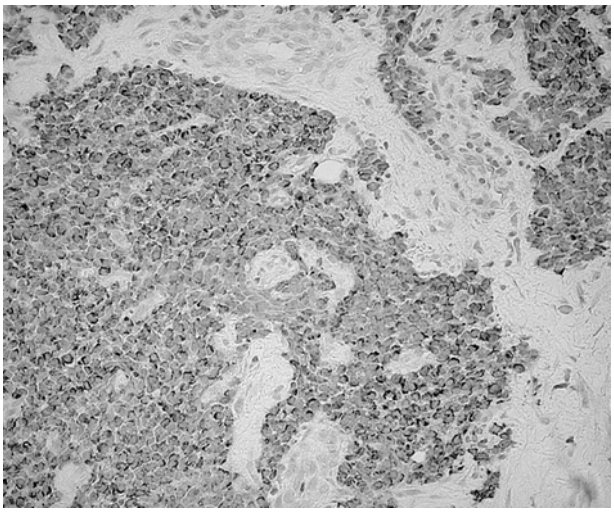

Figure 5. Immunohistochemical staining of keratin. The tumor cells displayed positive immunoreactivity for keratin, mic2, and neuron-specific enolase.

CCRT was planned as a primary treatment. The treatment was initiated with external beam radiation therapy to the whole pelvic region with a daily fractional dose of 2 Gy using antero-posterior parallel opposed beams with 10 MV photons. A total dose of 120 mg of cisplatin with a daily dose of 8 mg (5 mg/m^2) was administered concomitantly with radiation therapy. The therapeutic response was fairly good, and the tumor decreased rapidly. Following the administration of a total dose of 40 Gy, the irradiation field size was decreased, and the additional 20 Gy in 10 fractions was delivered to the gross tumor. The patient's pain, for which opioid analgesia had been required before treatment, rapidly improved after initiation of CCRT. Finally, a complete response was achieved without severe toxic effects, and the patient has remained alive without any evidence of recurrence for over 8 years (figure 6).



Figure 6. A contrast-enhanced computed tomography image after treatment. Complete response was achieved at the end of concurrent chemoradiotherapy, and no evidence of recurrence has been observed for over 8 years.

DISCUSSION

DSRCT is a rare and highly aggressive tumor that was first reported by Gerald and Rosai in 1989 [2]. Clinically, DSRCT usually occurs in male children and young adults, primarily in the abdominal cavity with widespread peritoneal involvement. The present case is very rare with respect to age. This case was a 58-year-old man with a large mass in the pelvic region. Furman et al. reviewed 109 reported cases of DSRCT, finding that 25 involved urogenital organs, and these investigators also reported an additional 2 cases from their own experience [3]. In that report, out of the total 27 patients with urogenital involvement, 25 patients were male and 2 were female, with a median age of 21 years (range, 8-36 years). While the age of this case appears to be relatively high, several other cases of DSRCT aged 50 to >70 years old have also been previously reported [1, 4-6].

Histologically, DSRCT is composed of well-defined nests of small, undifferentiated round or oval hyperchromatic cells embedded in abundant desmoplastic stroma. Furthermore, tumors exhibit a unique immunohistochemical staining profile; co-expression of epithelial (keratin and epithelial membrane antigen), mesenchymal (vimentin), neural (neuron-specific enolase), and myogenic (desmin) markers in the same tumor cells provides evidence of origination from a primitive pluripotent stem cell with multiphenotypic differentiation [7]. In this case, the immunoreactivity was not entirely typical for DSRCT, but the histological pattern using H&E staining was compatible with DSRCT. Some reports have stated that the reciprocal chromosomal

[Downloaded from ijrr.com on 2026-11-28]

translocation t(11;22)(p13;q12) is specific for DSRCT [7]. Cytogenetic analysis could not be performed in this case due to the limited sample volume obtained by needle biopsy. With respect to diagnostic imaging, characteristics of DSRCT on CT images—ie, bulky heterogeneous peritoneal soft tissue masses without an apparent organ-based primary site—were observed in this case [8].

The optimal treatment for DSRCT remains to be determined. Previous reports have stated that the prognosis of DSRCT was generally poor, because patients with the disease had widespread peritoneal involvements at the time of diagnosis. Bertuzzi *et al.* reported the prospective study of high-dose chemotherapy in patients with DSRCT consisting of epirubicin, ifosfamide, vincristine, and etoposide or cyclophosphamide, and concluded that high-dose chemotherapy did not improve the treatment outcomes with a median survival of 14 months [9]. Treatment results for the largest number of patients with DSRCT have been reported from Memorial Sloan-Kettering Cancer Center [6, 10]. For example, Lal *et al.* reported that the 3-year and 5-year overall survival rates after induction chemotherapy with the P6 protocol (seven courses involving cyclophosphamide, doxorubicin, vincristine, ifosfamide, and etoposide), debulking surgery, and/or radiation therapy were 44% and 15%, respectively; these researchers concluded that multimodal therapy resulted in improved survival in patients with DSRCT [6]. The survival rate was far inferior in tumors that were judged to be unresectable: among patients who received a lesser resection, there were no survivors after 3 years, compared to a 3-year survival rate of 58% in patients for whom a >90% tumor resection was achieved [6]. However, the treatment intensity of triple modality therapy consisting of induction chemotherapy, surgical debulking, and radiation therapy was so high that more than half of patients with a median age of 19 years did not complete multimodal therapy [6]. In older DSRCT cases, the therapeutic burden is even higher. The results of previously reported therapeutic courses of DSRCT in elderly patients are summarized in table 1 [1, 4, 5]. To our knowledge, the present case is the only known long-term DSRCT survivor who possibly achieved cure after CCRT among older DSRCT patients.

Very few reports have addressed the radiation therapy techniques and radiation sensitivity of DSRCT. Goodman *et al.* reported the treatment outcome of whole abdominopelvic irradiation (WAPI) for DSRCT after intensive induction chemotherapy and surgical resection [10]. The prescribed total dose of WAPI was 30 Gy with a fractional dose of 1.5 Gy, and an additional boost ranging from 6 to 24 Gy was delivered to areas of gross disease. In that report, the 3-year relapse-free survival rate was 19%, 76% of patients experienced a recurrence within the WAPI field. Furthermore, relatively severe

Table 1. The results of previously reported therapeutic courses in older DSRCT patients.

Reference	Age (years)	Gender	Tumor location	Treatment	Prognosis
Lae *et al.* (2002)	54 53	M M	Abdomen Abdomen	S, CT, RT S	DOD, 24 mo NA
Reich *et al.* (2000)	68	F	Abdomen	S, CT	DOD, 3 mo
Wolf *et al.* (1999)	76	F	Abdomen	S, CT	AWD, 10 mo
Present case (2011)	58	M	Pelvis	CCRT	Alive at >8 years

S, surgery; CT, chemotherapy; RT, radiotherapy; CCRT, concurrent chemoradiotherapy; DOD, dead of disease; AWD, alive with disease; NA, not available

[Downloaded from ijrr.com on 2026-11-28]

hematological and gastrointestinal toxicity, including small bowel obstruction, was observed [10]. In the present case, the tumor was unresectable, but it was localized in the pelvic region. This patient was treated with CCRT that consisted of a total irradiation dose of 60 Gy combined with daily low-dose administration of cisplatin. Consequently, the early tumor response to treatment was fairly good, and the control of tumor has been achieved to date. The successful disease control of this case may be due to the administration of a high radiation dose localized to the lesion along with the concurrent chemotherapy.

In conclusion, we have presented a 8-year survivor of intrapelvic small round cell tumor in an adult male successfully treated with CCRT. CCRT may become a useful option for the treatment of unresectable DSRCT, particularly for cases with no evidence of distant metastasis or expanded dissemination.

REFERENCES

1. Lae ME, Roche PC, Jin L, Lloyd RV, Nascimento AG (2002) Desmoplastic small round cell tumor: A clinicopathologic, immunohistochemical, and molecular study of 32 tumors. *Am J Surg Pathol,* ***26:*** *823–35.*
2. Gerald WL and Rosai J (1989) Case 2: desmoplastic small round cell tumor with divergent differentiation. *Pediatr Pathol,* ***9:*** *177–83.*
3. Furman J, Murphy WM, Wajsman Z, Berry AD (1997) Urogenital involvement by desmoplastic small round-cell tumor. *J Urol,* ***158:*** *1506-9.*
4. Reich O, Justus J, Tamussino KF (2000) Intra-abdominal desmoplastic small round cell tumor in a 68-year-old female. *Eur J Gynaecol Oncol,* ***21:*** *126-7.*
5. Wolf AN, Ladanyi M, Paull G, Blaugrund JE, Westra WH (1999) The expanding clinical spectrum of desmoplastic small round-cell tumor: a report of two cases with molecular confirmation. *Hum Pathol,* ***30:*** *430-5.*
6. Lal DR, Su WT, Wolden SL, Loh KC, Modak S, La Quaglia MP (2005) Results of multimodal treatment for desmoplastic small round cell tumors. *J Pediatr Surg,* ***40:*** *251-5.*
7. Gerald WL, Ladanyi M, de Alava E, Cuatrecasas M, Kushner BH, La Quaglia MP, *et al.* (1998) Clinical, pathologic, and molecular spectrum of tumors associated with t(11;22)(p13;q12): desmoplastic small round-cell tumor and its variants. *J Clin Oncol,* ***16:*** *3028–36.*
8. Pickhardt PJ, Fisher AJ, Balfe DM, Dehner LP, Huettner PC (1999) Desmoplastic small round cell tumor of the abdomen: radiologic-histopathologic correlation. *Radiology,* ***210:*** *633-8.*
9. Bertuzzi A, Castagna L, Quagliuolo V, Ginanni V, Compasso S, Magagnoli M, *et al.* (2003) Prospective study of high-dose chemotherapy and autologous peripheral stem cell transplantation in adult patients with advanced desmoplastic small round-cell tumour. *Br J Cancer,* ***89:*** *1159–61.*
10. Goodman KA, Wolden SL, La Quaglia MP, Kushner BH (2002) Whole abdominopelvic radiotherapy for desmoplastic small round-cell tumor. *Int J Radiat Oncol Biol Phys,* ***54:*** *170-6.*

[Downloaded from ijrr.com on 2026-11-28]

[Downloaded from ijrr.com on 2026-11-28]