

Oral zinc sulphate and prevention of radiation-induced oropharyngeal mucositis in patients with head and neck cancers: A double blind, randomized controlled clinical trial

D. Moslemi¹, N. Babae², M. Damavandi², M. Pourghasem^{3*},
A.A. Moghadamnia⁴

¹Division of Radiation Oncology, School of Medicine, Babol University of Medical Sciences, Babol, Iran

²Department of Oral Medicine, School of Dentistry, Babol University of Medical Sciences, Babol, Iran

³Department of Anatomy, Embryology and Histology, Babol University of Medical Sciences, Babol, Iran

⁴Department of Pharmacology, School of Medicine, Babol University of Medical Sciences, Babol, Iran

ABSTRACT

► Original article

*** Corresponding author:**

Dr. Mohsen Pourghasem,

Fax: +98 111 2234367

E-mail:

mpourghasem@hotmail.com

Received: April 2013

Accepted: July 2013

Int. J. Radiat. Res., July 2014;
12(3): 235-241

Background: This research was conducted to evaluate the potential benefits of zinc sulphate in the prevention of radiation induced mucositis in patients who are being treated for head and neck cancers. **Materials and Methods:** Forty patients with proven cancers of head and neck were randomly divided into 2 equal groups that either received zinc sulphate or placebo (control group). Patients who received curative radiotherapy or chemoradiotherapy were instructed to take zinc sulphate capsules (30 mg) daily at 8 hours interval. They were to begin 10 days before the start of treatment and continued until 2 weeks after completing the schedule. Mucositis was evaluated weekly according to the Oral Mucositis Assessment Scale (OMAS). **Results:** In both groups (zinc and control) mucositis was evident during the first week but its prevalence was 40% and 70.5% in the zinc and placebo groups respectively at the end of this period. This difference was significant ($p < 0.0001$). The mean severity of oropharyngeal mucositis increased after commencement of radiotherapy and reached to maximum intensity in the 4th week. Control group showed higher severity ($p < 0.0001$). In comparison with the placebo group, the mucositis score of OMAS in the zinc group was lower until at 2 weeks after end of the treatment ($p = 0.0001$). **Conclusion:** The present study shows that Zinc sulfate is effective in reducing the severity of radiation induced oropharyngeal mucositis. In addition, it delays the development of mucositis and may be used at a lower dose (30 mg 3 times daily) with the same benefit but fewer side effects.

Keywords: Zinc sulfate, mucositis, radiotherapy, prevention.

INTRODUCTION

Radiotherapy (RT) is an essential treatment for most patients with head and neck cancers (1-3). One of the most commonly troublesome side effects of radiotherapy in head and neck

cancers is mucositis which is the main factor of dose limiting side effect (4-7). Radiotherapy induces mucositis in 70% of patients with hypopharynx and all patients with mouth, nasopharynx or oropharynx cancers (8).

The main factor to determine the incidence of mucositis is based on the cancer treatment

protocol. So the incidence of mucositis in current head and neck radiotherapy protocols, altered fractionated radiation, chemoradiation and conventional radiation are respectively 85-100%, 100%, 89% and 97%⁽⁹⁾. Mucositis might be seen in 100% of patients receiving aggressive myelo-ablative chemotherapy. Prevalence and status of mucositis will be increased in chemo radiation accompany with hyper fractionated program⁽¹⁰⁾. The severity of mucositis is dependent to many factors such as: genetic factors, anti-cancer treatment protocol, sex, age, nutritional status and oral hygiene.

Oral mucositis has different presentation that initially appears as erythema and subsequent ulceration, necrosis and bleeding. Severe pain, odynophagia and dysphagia, with consequential anorexia, disorder in food intake and speech problem are other symptoms of mucositis. Oral mucositis could be a potential way for local and systemic infections. Furthermore, mucositis usually changes the radiotherapy program such as delays in administration or limitation in radiation dosage. It may also increase hospitalization and cost of the treatment. Interruption in treatment and prolongation total radiation time may make deficiency on radiotherapy effects in the head and neck cancers and decrease patient survival. One week after conventional RT schedule (2 Gy/day and 10 Gy/week), inflammatory signs begin to appear. Initially it appears as a white discoloration and develops to maximum situation in dose of 3000 cGy⁽¹¹⁾. Prevention of secondary infection, decrease of pain and correction of nutrition imbalance should be considered as important objectives in treatment of mucositis⁽⁵⁾.

A mass of investigations is growing to find an effective agent to reduce and prevent of mucositis. Many modalities and materials such as antibiotics, anti-inflammatory agents, cytokines (granulocyte colony-stimulating factor, granulocyte macrophage colony-stimulating factor), mouth-coating agents (sucralfate), vitamins (A and E), amino acids (glutamine), prostaglandins (PGE-1, PGE-2), immune regulatory agents (immunoglobulin, pentoxifylline), cytoprotectors (amifostine),

hormones (melatonin) and honey preparations have been administered either prophylactic or after the onset of symptoms. But there were no approved treatment^(12,13).

Zinc is essential element for body to make many enzymes which participate to multiple functions such as cell proliferation, wound healing, free radical protection, infection protection, epithelial organization and immunity^(2, 14). Zinc sulphate is a colorless inorganic compound which might be a promising agent to prevent and reduce severity of mucositis^(15, 16). Regarding to zinc function on the human body, this research was conducted to evaluate potential effects of zinc sulphate to prevent radiation induced mucositis in patients with head and neck cancers.

MATERIALS AND METHODS

The study was approved by ethical committee of Babol University of Medical Sciences. It was a phase III, double blind, placebo controlled, randomized clinical trial that was conducted in the department of Radiotherapy of Babol University of Medical Sciences from February 2009 to May 2011. it was registered in Iranian Registry of Clinical Trials (www.irct.ir) with ID No: IRCT201106116734N3 . Forty patients with proven squamous cancers of head and neck were entered in study (Karnofsky's performance status ≥ 70). All patients were fully informed about the research before entering to the program and a written informed consent form was signed. Patients were randomly divided into 2 equal groups either received zinc sulphate or placebo (control group). Patients received curative radiotherapy or chemoradiotherapy. Planned treatment was at least 6000cGy total radiation dose of external beam radiotherapy to at least one third of the oral cavity. Exclusion criteria were: concurrent disease (diabetes mellitus, hypertension, autoimmunedisorder, chronic inflammation, cardiac disease, etc.) previously administration of cytotoxic chemotherapy or radiotherapy, patients refusal, infection of mouth and systemic infection.

Patients with interruption in the treatment were excluded from study as well. Patients were informed to take zinc sulphate capsules (30 mg) three times daily at 8 hours interval. It has been started 10 days before beginning of treatment and continued to 8 weeks after the end of treatment. During treatment until 2 weeks after treatment, a radiation oncologist and a periodontist evaluated oral and pharyngeal mucositis weekly according to the Oral Mucositis Assessment Scale (OMAS). This scoring system was introduced by Sonis⁽¹³⁾ which is a simple method and easy use to records the parameters of mucositis accuracy. Oral cavity has been divided into 9 regions: hard and soft palate, floor of mouth, upper and lower lips, left and right buccal mucosa, left and right ventral and lateral tongue. All regions of oral cavity had been assessed for erythema and ulcer.

Erythema considered as: 0 point (no erythema), 1 point (mild to moderate erythema) and 2 points (severe erythema). It was for ulcers as follows: 0 point (no ulcer), 1 point (ulcer <1 cm), 2 points (ulcer 1-3 cm) and 3 points (ulcer >3 cm).

Cobalt-60 at 80 cm SSD was used for treatment. Two parallel-opposed lateral fields and an anterior lower neck field were planned daily with a mid-plane radiation dose of 200 cGy to a total of 6000–7000 cGy in 30–35 treatment sessions. A dose less than 4600cGy were restricted for spinal cord. Residual disease at the primary site was irradiated with a boost dose of 1600–2400 cGy. There were shielding blocks for patients who need. Thirty four patients treated concurrent radiotherapy and chemotherapy with receiving cisplatin (100mg/m²) with or without 5-fluorouracil (5-FU) on the first 3 days of first week and interval continued each 3 weeks during of treatment period. General physical examination, renal and liver function tests were done before beginning of radiotherapy or chemotherapy period. Placebo capsules filled with starch and designed same medicine firm, form and color to zinc sulphate. Patients administrated capsules a period of 10 days before beginning of the treatment to last

day. Treatment interruption was considered if patient had break time in radiotherapy for more than 5 days. Patients were asked to drink enough water, brush the teeth with soft brush daily, avoiding drink too hot or cold liquids and do not eat spiced or sour foods. Severity, duration and commencement of radiotherapy induced mucositis have been evaluated by the SPSS 16. To determine the effectiveness of zinc sulphate to prevent or reduce of oral mucositis, The Mann-Whitney, Fisher's exact, Pearson chi-square tests and Friedman variation analysis were performed. $P < 0.05$ was considered as statistically significant difference point between the results of the groups.

RESULTS

In control group, 2 patients in 4th week and 1 patient in 5th week leave out the treatment program due to sever mucositis and interruption of treatment but all patients stayed and finished the treatment in zinc group. All patients tolerated zinc sulphate without any considerable side effect. The mean \pm SD and range of the patients' age in zinc group and control group were 49.5 ± 17.47 (18–78) and 52.82 ± 14.03 (22–71), respectively and in both group male patients were predominant. After nasopharynx, oral cavity was most prevalent primary site (table 1).

Comparison of mucositis development between 2 groups showed that sex, age, histological type, disease, treatment modalities, and chemotherapy regimen didn't make statistically significant differences.

Based on the OMAS criteria, mean of oral and pharyngeal mucositis severities had been increased after commencement of radiotherapy and reached to maximum tendency at 4th week. Meanwhile, control group showed highest severity in mucositis ($p < 0/0001$). The mucositis score of the OMAS in the zinc group was lower at the weekends ($p < 0.0001$) compared to placebo group. For 2 weeks after end of the treatment, difference between results of zinc and placebo groups were statistically significant ($p < 0.05$) (figure 1).

Table1. characters of the patients.

Variable	Zinc sulphate group	Placebo
Gender		
Male	12	9
Female	8	8
Age		
Range	18-78	29-78
Median	49	52
Tumor site		
Nasopharynx	11	10
Oral cavity	6	5
Primary in neck ganglion lymphomas	1	1
Tonsil	2	1
Surgery before radiotherapy		
Yes	8	6
No	12	11
Concurrent chemoradiotherapy		
Yes	17	15
No	3	2
Radiotherapy doses (cGy)		
Range	4000-7000	4000-7000
Median	6600	6600

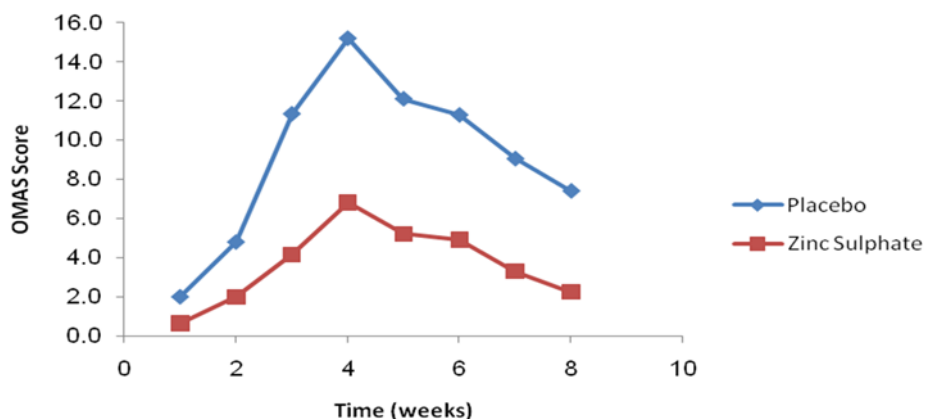


Figure 1. Initiation and severity of mucositis in the placebo and zinc groups by the time.

In both groups of study mucositis has been expressed during the first week but the prevalence of mucositis were 40% and 70.5% in zinc and placebo groups, respectively at the end of this week ($p < 0.0001$).

In weeks 2-7 and 8, the severity of oral and pharyngeal mucositis were lower in the zinc group, ($p < 0.003$) (figure 2).

Severity of oral and pharyngeal mucositis has been compared in male and female of both groups at the end of 3rd week. The severity was more in male however, was no significant (figure 3).

DISCUSSION

A mass of materials has been examined to reduce radiation induced mucositis but the results were controversial and there is no approved agent. Therefore, this study has been conducted to find a way to reduce mucositis which is one of the most common dose-limiting side effects of radiotherapy in patients with head and neck cancers. Mucositis could interrupts treatment protocol in 11% patients and leads a rest of 2-3 weeks during radiotherapy schedule that decreases the chance

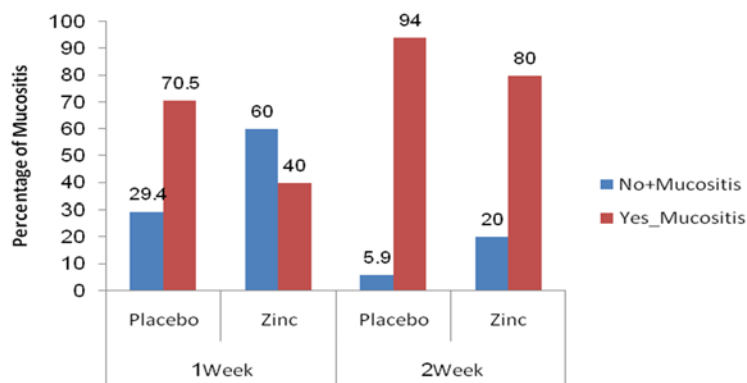


Figure 2. Incidence of mucositis among placebo and zinc groups in the weeks 1 & 2.

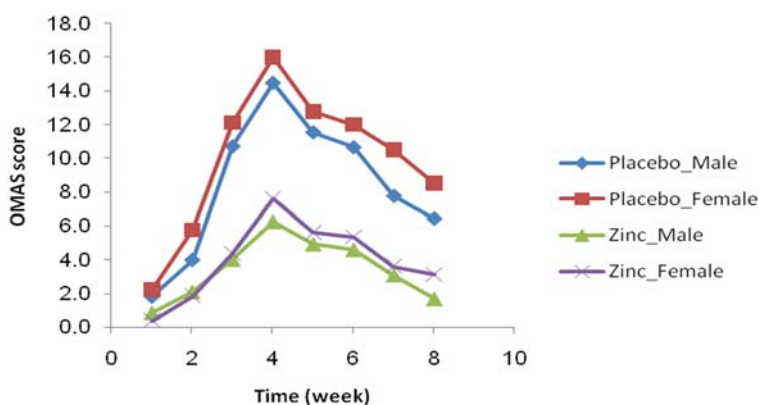


Figure 3. Comparison of initiation and severity of mucositis in male and female in the placebo and zinc groups by the time.

Sucralfate has been evaluated to prophylactic control of mucositis by Carter et al, but using sucralfate mouth wash during RT did not reduce mucositis severity⁽¹⁹⁾. Although the study of Gengiz on sucralfate was hopeful⁽²⁰⁾. Amifostine is an organic thiophosphate agent that is confirmed as a radio and cyto-protective material by the American Society of Clinical Oncology (ASCO) and by Food and Drug Administration⁽¹⁾. Buntzel *et al.* showed that amifostine can decrease the incidence, severity and duration of mucositis⁽¹⁸⁾. In contrast, Brizel et al demonstrated that there was no beneficial management of mucositis in patients who received amifostine during their radiotherapy treatment⁽²¹⁾. Nausea, vomiting and hypotension were reported as side effects of amifostine. But zinc sulphate had no side effect.

Zinc is an antioxidant, stabilizer of DNA, RNA and organelle structure⁽²²⁻²⁴⁾. It acts as an important co-factor for synthesis of DNA and as

a component helps to wound healing. It has anti-inflammatory effect⁽²⁵⁻²⁷⁾ and used as immune system modulator⁽²⁸⁻³⁰⁾. Based on these properties, zinc sulphate could have preventing role in decreasing radiation-induced side effects. Zinc sulphate even corrects taste sensation changes during radiotherapy for head and neck cancer^(31, 32).

Pathophysiology of mucositis can be developed in five phases: initiation, message generation, amplification, ulceration and healing phases. Initiation phase is caused by free radicals resulting chemotherapy or radiotherapy. The free radicals damage DNA and induce releasing of cell transcription factors. These factors increase cytokines such as IL-1 and TNF-alpha which induce inflammation and followed by ulceration. Re epithelialization is final phase that epithelial cells heal the ulcer^(33, 34).

Initiation and message generation phases could be affected by zinc^(14, 35-40). Ertekin *et al.*

showed that zinc delays initiation of ulcer and no patient expressed phase 3 or 4 mucositis (2, 14). Furthermore, there was no interruption in the radiotherapy course using zinc. These results have been previously reported (41). The study showed that zinc can reduce severity of mucositis of oral cavity but is not beneficial for concurrent chemoradiation patients. In another randomized placebo controlled trial result has been showed that zinc reduces the severity of radiation induced oral mucositis (11). The results of our study are in consistent to the previous studies. The present study showed zinc sulphate significantly delayed initiation time of mucositis expression and decreased its severity. Comparing to the previous mentioned studies, in this present investigation lower dose of zinc sulphate was used with the same efficacy without significant side effects such as nausea or vomiting.

CONCLUSION

The present study showed that zinc sulphate can reduce the severity of radiation-induced oropharyngeal mucositis. It delays initiation of mucositis and could be administered in low dose with the same benefit and lower side effects. According to the findings, further evaluation in a larger number of patients is recommended.

Declaration of Competing Interest

No competing interest is declared by authors.

REFERENCES

1. Ngeow WC, Chai WL, Zain RB (2008) Management radiation therapy- induced mucositis in head and neck cancer patients. *Oncol Rev*, **2**: 102-113.
2. Ertekin MV, Tekin SB, Erdogan F, Karslioglu I, Gepdiremen A, Sezen O, Balci E, et al. (2004) The effect of zinc sulphate in the prevention of radiation-induced dermatitis. *J Radiat Res*, **45**: 543-548.
3. Vissink A, Burlage FR, Spijkervet FK, Jansma J, Coppes RP (2003) Prevention and treatment of the consequences of head and neck radiotherapy. *Crit Rev Oral Biol Med*, **14**: 213-225.
4. Al-Mamgani A, van Rooij P, Verduijn GM, Mehilal R, Kerrebijn JD, Levendag PC (2012) The impact of treatment modality and radiation technique on outcomes and toxicity of patients with locally advanced oropharyngeal cancer. *Laryngoscope*, **123**: 386-393.
5. Carl W and Havens J (2000) The cancer patient with severe mucositis. *Curr Rev Pain*, **4**: 197-202.
6. Yavas C, Yavas G, Acar H, Toy H, Yuce D, Akyurek S, Ata O (2012) Amelioration of radiation-induced acute inflammation and mucosal atrophy by beta-hydroxy-beta-methylbutyrate, L-glutamine, and L-arginine: results of an experimental study. *Support Care Cancer*, **21**: 883-888.
7. Wang R, Wu F, Lu H, Wei B, Feng G, Li G, Liu M, et al (2012) Definitive intensity-modulated radiation therapy for nasopharyngeal carcinoma: long-term outcome of a multicenter prospective study. *J Cancer Res Clin Oncol*, **139**:139-145.
8. Eilers J and Million R (2007) Prevention and management of oral mucositis in patients with cancer. *Semin Oncol Nurs*,**23**:201-212.
9. Trotti A, Bellm LA, Epstein JB, Frame D, Fuchs HJ, Gwede CK, Komaroff E, et al. (2003) Mucositis incidence, severity and associated outcomes in patients with head and neck cancer receiving radiotherapy with or without chemotherapy: a systematic literature review. *Radiother Oncol*, **66**: 253-262.
10. Sonis ST, Eilers JP, Epstein JB, LeVeque FG, Liggett WH, Jr., Mulagha MT, Peterson DE, et al. (1999) Validation of a new scoring system for the assessment of clinical trial research of oral mucositis induced by radiation or chemotherapy. Mucositis Study Group. *Cancer*, **85**: 2103-2113.
11. Mosallaei A, Nasrolahi H, Shafizad A, Ahmadloo N, Ansari M, Mosleh-Shirazi MA, et al. (2010) Effect of zinc sulfate in prevention of radiation induced oropharyngeal mucositis during and after radiotherapy in patients with head and neck cancers. *Middle East J Cancer*, **1**: 69-76.
12. Clarkson JE, Worthington HV, Eden OB (2007) Interventions for treating oral mucositis for patients with cancer receiving treatment. *Cochrane Database Syst Rev*: CD001973.
13. Scully C, Sonis S, Dizz PD (2006) Mucosal diseases series: oral mucositis. *Oral dis*, **12**:229-241.
14. Ertekin MV, Koc M, Karslioglu I, Sezen O (2004) Zinc sulfate in the prevention of radiation-induced oropharyngeal mucositis: a prospective, placebo-controlled, randomized study. *Int J Radiat Oncol Biol Phys*, **58**: 167-174.
15. Rostan EF, DeBuys HV, Madey DL, Pinnell SHR (2002) Evidence supporting zinc as an important antioxidant for skin. *Int J Dermatol*, **41**: 606-611.
16. Ripamonti C, Zecca E, Brunelli C, Fulfaro F, Villa S, Balzarini A, Bombardieri E, et al (1998) A randomized, controlled clinical trial to evaluate the effects of zinc sulfate on cancer patients with taste alterations caused by head and neck irradiation. *Cancer*, **82**: 1938-1945.
17. Berk LB (2006) Primer on integrative oncology. *Hematol Oncol Clin North Am*, **20**: 213-231.
18. Buntzel J, Schuth J, Kuttner K, Glatzel M (1998) Radiochemotherapy with amifostine cytoprotection for head and neck cancer. *Support Care Cancer*, **6**:

- 155-160.
19. Carter DL, Hebert ME, Smink K, Leopold KA, Clough RL, Brizel DM (1999) Double blind randomized trial of sucralfate vs placebo during radical radiotherapy for head and neck cancers. *Head Neck*, **21**: 760-766.
 20. Cengiz M, Ozyar E, Ozturk D, Akyol F, Atahan IL, Hayran M (1999) Sucralfate in the prevention of radiation-induced oral mucositis. *J Clin Gastroenterol*, **28**: 40-43.
 21. Brizel DM, Wasserman TH, Henke M, Strnad V, Rudat V, Monnier A, Eschwege F, et al. (2000) Phase III randomized trial of amifostine as a radioprotector in head and neck cancer. *J Clin Oncol*, **18**:3339-3345.
 22. Abarca D, Roldan M, Martin M, Sabater B (2001) Arabidopsis thaliana ecotype Cvi shows an increased tolerance to photo-oxidative stress and contains a new chloroplastic copper/zinc superoxide dismutase isoenzyme. *J Exp Bot*, **52**:1417-1425.
 23. Fraefel C, Zeng J, Choffat Y, Engels M, Schwyzer M, Ackermann M (1994) Identification and zinc dependence of the bovine herpesvirus 1 transactivator protein BICP0. *J Virol*, **68**: 3154-3162.
 24. Nguyen HQ, Hoffman-Liebermann B, Liebermann DA (1993) The zinc finger transcription factor Egr-1 is essential for and restricts differentiation along the macrophage lineage. *Cell*, **72**: 197-209.
 25. Bandyopadhyay B and Bandyopadhyay SK (1997) Protective effect of zinc gluconate on chemically induced gastric ulcer. *Indian J Med Res*, **106**: 27-32.
 26. Barbarino F, Toganel E, Brilinschi C (1992) Protective effect of zinc acexamate on experimental gastric ulcers: a histochemical study. *Methods Find Exp Clin Pharmacol*, **14**: 685-694.
 27. Joseph RM, Varela V, Kanji VK, Subramony C, Mihas AA (1999) Protective effects of zinc in indomethacin induced gastric mucosal injury: evidence for a dual mechanism involving lipid peroxidation and nitric oxide. *Aliment Pharmacol Ther*, **13**: 203-208.
 28. Hodkinson CF, Kelly M, Alexander HD, Bradbury I, Robson PJ, Bonham MP, O'Connor JM, et al. (2007) Effect of zinc supplementation on the immune status of healthy older individuals aged 55-70 years: the ZENITH Study. *J Gerontol A Biol Sci Med Sci*, **62**: 598-608.
 29. Ripa S and Ripa R (1995) Zinc and immune function. *Minerva Med*, **86**: 315-318.
 30. Wintergerst ES, Maggini S, Hornig DH (2006) Immune-enhancing role of vitamin C and zinc and effect on clinical conditions. *Ann Nutr Metab*, **50**: 85-94.
 31. Halyard MY, Jatoi A, Sloan JA, Bearden JD, 3rd, Vora SA, Atherton PJ, Perez EA, et al. (2007) Does zinc sulfate prevent therapy-induced taste alterations in head and neck cancer patients? Results of phase III double-blind, placebo-controlled trial from the North Central Cancer Treatment Group (N01C4). *Int J Radiat Oncol Biol Phys*, **67**:1318-1322.
 32. Silverman JE, Weber CW, Silverman S, Jr., Coulthard SL, Manning MR (1983) Zinc supplementation and taste in head and neck cancer patients undergoing radiation therapy. *J Oral Med*, **38**: 14-16.
 33. Bensadoun RJ, Magne N, Marcy PY, Demard F (2001) Chemotherapy- and radiotherapy-induced mucositis in head and neck cancer patients: new trends in pathophysiology, prevention and treatment. *Eur Arch Otorhinolaryngol*, **258**:481-487.
 34. Duncan M and Grant G (2003) Oral and intestinal mucositis - causes and possible treatments. *Aliment Pharmacol Ther*, **18**:853-874.
 35. Arbabi-kalati F, Deghatipour M, Ansari Moghadam A (2012) Evaluation of the efficacy of zinc sulfate in the prevention of chemotherapy-induced mucositis: a double-blind randomized clinical trial. *Arch Iran Med*, **15**:413-417.
 36. Coyle P and Rofe AM (2009) Implications of high dietary zinc and intestinal metallothionein on the severity of methotrexate-induced mucositis. *Cancer Biol Ther*, **8**: 1668-1670.
 37. Lin YS, Lin LC, Lin SW, Chang CP (2010) Discrepancy of the effects of zinc supplementation on the prevention of radiotherapy-induced mucositis between patients with nasopharyngeal carcinoma and those with oral cancers: subgroup analysis of a double-blind, randomized study. *Nutr Cancer*, **62** :682-691.
 38. Mansouri A, Hadjibabaie M, Irvani M, Shamshiri AR, Hayatshahi A, Javadi MR, Khoee SH, et al. (2011) The effect of zinc sulfate in the prevention of high-dose chemotherapy-induced mucositis: a double-blind, randomized, placebo-controlled study. *Hematol Oncol*, **30**:22-26.
 39. Mehdipour M, Taghavi Zenoz A, Asvadi Kermani I, Hosseinpour A (2011) A comparison between zinc sulfate and chlorhexidine gluconate mouthwashes in the prevention of chemotherapy-induced oral mucositis *Daru*, **19**:71-73.
 40. Tran CD, Sundar S, Howarth GS (2009) Dietary zinc supplementation and methotrexate-induced small intestinal mucositis in metallothionein-knockout and wild-type mice. *Cancer Biol Ther*, **8**:1662-1667.
 41. Lin LC, Que J, Lin LK, Lin FC (2006) Zinc supplementation to improve mucositis and dermatitis in patients after radiotherapy for head-and-neck cancers: a double-blind, randomized study. *Int J Radiat Oncol Biol Phys*, **65**:745-750.

