

Dosimetric comparison of TomoDirect and TomoHelical plans in post-mastectomy chest wall radiation therapy

F. Teke*, M.H. Doğan, M.A. Kaya, M. Gümüş

Dicle University, Medical School, Department of Radiation Oncology, Yenişehir 21280 Diyarbakır, Turkey

ABSTRACT

► Original article

*Corresponding authors:

Dr. Fatma Teke,

Fax: +90 412 248 81 15

E-mail:

doktorfatmateke@gmail.com

Revised: May 2016

Accepted: Aug. 2016

Int. J. Radiat. Res., July 2017;
15(3): 259-266

DOI: 10.18869/acadpub.ijrr.15.3.259

Background: The purpose of this study was to evaluate the characteristics of TomoDirect (TD) plans compared to conventional TomoHelical (TH) plans in chest wall irradiation in patients with breast cancer. **Materials and Methods:** TD and TH plans for only chest wall were retrospectively created for 30 patients previously treated with TH technique in our clinic. The beam angles were arranged to cover PTV chest wall and to minimize doses to OARs, ipsilateral lung and contralateral breast in TD plan. The prescribed dose was 50 Gy in 25 fractions. **Results:** The mean treatment times were similar in TH and TD (310.8 and 309 s, respectively, $p > 0.05$). There was no difference between the values of CI and HI of both plans ($p > 0.05$). The values of Dmean, V5 and V20 of the ipsilateral lung in TD plan was significantly lower than that in TH plan for all 30 patients ($p < 0.001$, $p < 0.001$ and $p = 0.001$, respectively). V25 and V30 values of the heart were significantly lower in TH than those in TD plan in left-sided chest wall irradiation ($p = 0.006$ and $p < 0.001$, respectively). However, V5 values in TH was significantly higher than those in TD ($p < 0.001$). In the right-sided, there was no difference between two plans for V25 and V30 values of heart ($p > 0.05$). **Conclusion:** Both of TH and TD plans produce acceptable target dose coverage in chest wall RT. Considering the risk of low-dose radiation to the critical organs; TD mode improve dose distribution.

Keywords: Breast cancer, TomoDirect, TomoHelical, chest wall irradiation.

INTRODUCTION

Post-mastectomy radiation therapy (PMRT) has been shown to decrease significantly the risk of chest wall recurrence and improve overall survival for patients with node positive and/or high-risk breast cancer (1-3). Comprehensive PMRT is technically difficult due to the complexity of the target volume and neighboring critical structures such as the lung and heart. Traditionally post-mastectomy chest-wall is treated with 3D conformal RT (3D CRT) with tangential beams, often using mixed electron/photon beams (2-4). To improve dose distribution in the chest wall and to reduce the received doses of the organs at risk (OAR), various techniques such as intensity modulated

radiotherapy (IMRT) and hybrid IMRT have been developed (5-9). Helical Tomotherapy (TomoHelical (TH)) is a rotational IMRT (Accuray Inc, Sunnyvale, CA, USA). TomoDirect (TD) is a static delivery mode of Tomotherapy device that allows to create 3D conformal RT (3D CRT) or IMRT plans by using a fixed gantry angle instead of rotational beam delivery. TD mode can reduce treatment time and low dose radiation regions on healthy tissues in breast cancer treatment. There are studies (10-12) about usage of TD for early breast cancer after lumpectomy, but TD-3DCRT for PMRT still deserves investigation. To our best knowledge, the only work on TD for chest wall is that of Jones *et al.* (13), which included a smaller dataset of 10 patients. To evaluate which Tomotherapy

technique is superior in chest wall irradiation, we compared 30 TD to TH plans by focusing on treatment time, The planning target volume (PTV) and OARs dosimetric endpoints.

MATERIALS AND METHODS

Patients

We included 30 patients with primary breast cancer underwent modified radical mastectomy in this planning study. All patients received PMRT with TH technique between November 2014 to July 2015 in the Department of Radiation Oncology at the Faculty of Medicine of Dicle University. This study was approved by Dicle University research ethic board. TD plans were retrospectively created for these patients after obtaining informed consent. While eligibility criteria were histopathologically proven invasive breast cancer and stage I-III disease according to AJCC Cancer Staging System, 7th Edition; exclusion criterias were advanced stage breast cancer and previous thoracic RT. We compared two modes of tomotherapy for only post-mastectomy chest wall irradiation without lymph nodes.

Simulation, contouring, planning and the plan assessment

Patients were simulated using computed tomography (CT) and positioned using a breast board (CIVCO) with their head turned to the contralateral side and the ipsilateral arm raised above their head. CT images with a 3.0 mm thickness were used to generate chest wall irradiation plans using TD and TH technique. PTV of the chest wall and organ at risk (OAR) were defined and contoured by a radiation oncologist according to the recommendations of the breast cancer atlas for radiation therapy planning consensus definitions of RTOG (the Radiation Therapy Oncology Group) (available at: <http://www.rtog.org/CoreLab/ContouringAtlases/BreastCancerAtlas.aspx>). The volume contours and CT images were transferred to the Tomotherapy H system (Accuray Inc., Sunnyvale, CA) to create

treatment plans.

TD plan using tangential beams and TH plan were generated for each patient. The beam angles were arranged to cover PTV and to minimize doses to OARs, ipsilateral lung and contralateral breast for TD plan. The chest wall was included in the irradiation volume. For TD and TH plans, the pitch (fraction of the jaw opening advanced by the treatment couch per evolution), field width and modulation factor were selected. Plans with a field width of 5.048 cm with fixed jaw mode were created with a pitch of 0.5 for TD and 0.287 for TH. The median modulation factor was 3.0 and it ranged from 0.5 to 4.0.

The dose to PTV was prescribed as 50 Gy in 25 fractions of 2.0 Gy daily. As dose constraints for the PTV, 1) D95% was defined as the minimum dose delivered to 95% of the PTV and D95% \geq 95% of the prescribed dose were satisfied. 2) V95% ($V_{47.5\text{ Gy}}$) was defined as the percentage of the PTV receiving at least 95% of the prescribed dose and V95% \geq 95% were satisfied. For PTV, the parameter V107 ($V_{53.5\text{ Gy}}$) was defined as the percentage of the PTV receiving at least 107% of the prescribed dose and was used to assess the maximum doses. The same dose prescription for targets and constraints for OARs were used to compare direct and helical plans.

The Conformity Index (CI) was used to evaluate the target dose conformity in our study. The CI was calculated according to following formula defined in ICRU (International Commission on Radiation Units and Measurements) ⁽¹⁴⁾.

CI= Volume of PTV covered by the reference dose / Volume of PTV

CI= 1.00 is for an ideal case.

The Homogeneity Index (HI) was used to analyze the uniformity of dose distribution in the target volume. HI is the ratio of the dose difference between D2 (the dose to 2% of the target volume) and D98 (the dose to 98% of the target volume) to D50 (the target median dose) ⁽¹⁵⁾. While a higher HI value ranging from 0 to 1 represents worse homogeneity; the lower value shows better conformity.

Effects on target and organ-at-risk (OAR)

doses, and treatment time were assessed for each planning technique by one radiation oncologist.

Statistical analysis

Data were analyzed using SPSS version 16.0 statistical software (SPSS, Chicago, IL, USA). All data were expressed as median and/or mean \pm standard deviation. Statistically significant differences in dosimetric end-points between TD and TH plans were determined using the Wilcoxon signed-rank test. Differences were considered significant for $p < 0.05$.

RESULTS

Thirteen patients had right-sided, and 17 patients had left-sided breast cancers. The median age was 51.5 years old (range: 25–84) and the patients were 29 females and 1 male. Patient characteristics were summarized in table 1.

We investigated whether there was the statistically significant difference in dosimetric value between the two plans. The median volume of PTV chest wall was 477.34 cc (Range, 204.26–1275.71 cc). Table 2 summaries the dose

parameters of PTV in the TD and TH plans. Figure 1 shows dose distributions of TD and TH plans in representative case. In our study, the CI values of TomoDirect and TomoHelical were 0.95 and 0.96, respectively ($p > 0.05$). Similarly the HI values in TomoDirect were not significantly better than those in TomoHelical plan (0.18 vs. 0.15, $p > 0.05$). Both Tomotherapy methods demonstrated clinically acceptable target dose coverage for chest wall RT in our study. However, the values of Dmax were similar for both techniques. We found that there was significant difference in the mean values of V107 (the volume receiving 53.5 Gy) between TD and TH (%6.4 vs %10.3 $p = 0.002$). The mean value of V107 in TD was lower (%10.3 vs %6.4, $p = 0.002$).

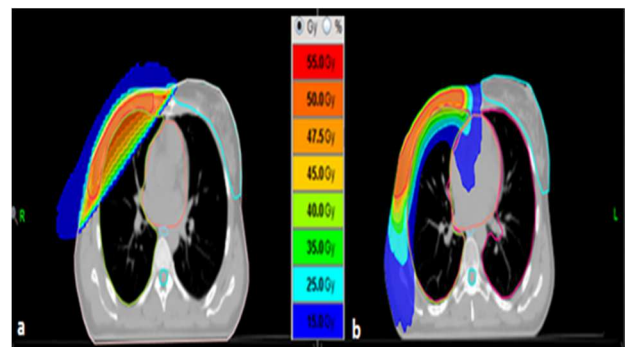


Figure 1. The dose distributions of TomoDirect (a) and TomoHelical (b) plans in representative case.

Table 1. Patient characteristics.

Variable		N	%
Sex			
Female		29	96.7
Male		1	3.3
Age			
Mean \pm SD	13.70 \pm 50.03		
Range	84-25		
Histology			
Invasive ductal carcinoma		29	96.7
Invasive lobular carcinoma		1	3.3
Stage			
IIA		3	10.0
IIB		9	30.0
IIIA		8	26.7
IIIB		3	10.0
IIIC		7	23.3
Tumor side			
Right breast cancer		13	43.3
Left breast cancer		17	56.7

Table 2. Comparison of dosimetric parameters for the PTV between TomoDirect and TomoHelical plans.

Parameter	TomoDirect		TomoHelical		P value
	Median	Range	Median	Range	
Dmean	50.91	53.22-49.51	51.48	54.23-49.55	0.001>
Dmin	22.08	35.15-5.37	34.50	42.48-26.45	0.001>
Dmax	56.68	77.54-53.49	56.77	61.01-53.63	0.46
V95	95.14	99.33-90.37	96.59	99.40-89.30	0.61
V107	1.64	92.74-0.0	8.07	38.34-0.0	0.002
D2	53.49	59.06-51.58	54.53	57.60-52.09	0.002
D50	51.12	52.85-48.30	51.60	54.52-50.20	0.001
D95	47.81	90.03-43.75	48.27	50.17-45.85	0.22
D98	44.44	48.91-38.12	46.58	49.18-43.32	0.003
CI	0.95	0.99-0.90	0.96	0.99-0.89	0.10
HI	0.16	0.34-0.09	0.16	0.24-0.09	0.15

Dmax, maximum dose; Dmean, mean dose; Dmin, Minimal dose received by 99% of target volume; D2, the dose to 2% of the target volume; D50, the dose to 50% of the target volume; D95, the dose to 95% of the target volume; D98, the dose to 98% of the target volume; Vx, volume (%) receiving x dose (Gy) or higher; CI, Conformity Index; HI, Homogeneity Index.

In our study, values of Dmax, Dmean and D2 of the spinal cord and values of Dmean of the esophagus in TD were also significantly lower than those in TH ($p < 0.001$). The value of Dmean of the contralateral breast in TomoDirect was also significantly lower than those in TomoHelical plan ($p < 0.001$). Table 3 shows the dosimetric parameters for the ipsilateral lung, heart, contralateral breast, esophagus and spinal

cord. Figure 2 shows dose volume histograms of the PTV and OARs for TD and TH plans. We compared dosimetric parameters direct and helical plans of right and left chest wall. Table 4 shows dosimetric comparisons of TD and TH plans of the 13 right-sided and 17 left-sided chest wall. The most important differences were found in dosimetric parameters of heart.

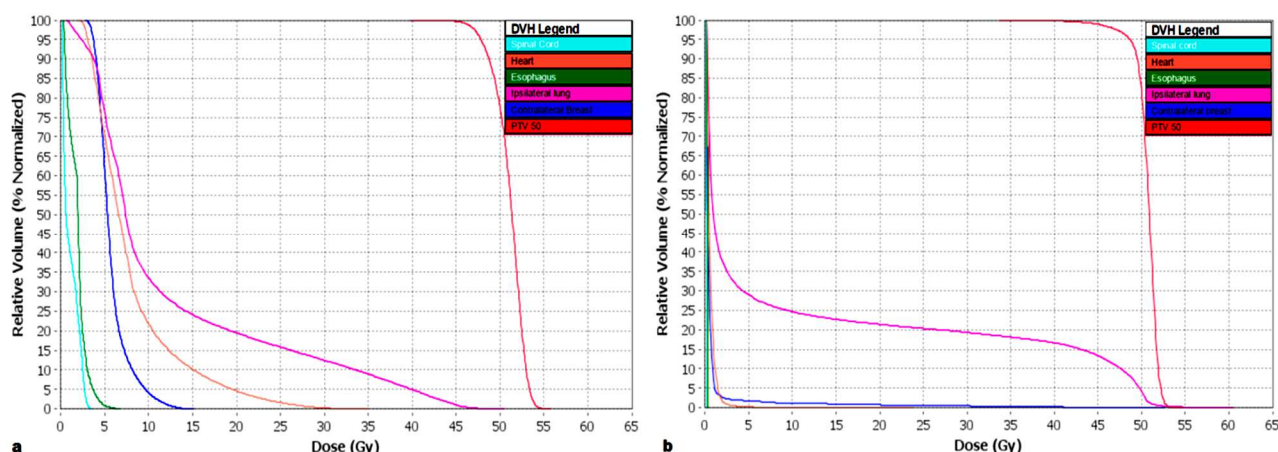


Figure 2. The dose volume histograms of the PTV and OARs for Tomohelical (a) and TomoDirect (b) plans.

Table 3. Comparison of dosimetric parameters for the OARs TomoDirect and TomoHelical plans for 30 patients.

Parameter	TomoDirect		TomoHelical		P value
	Median	Range	Median	Range	
Ipsilateral lung					
Dmean	8.51	14.70-4.59	14.26	22.80-10.63	0.001>
V5	24.31	41.00-0.00	87.09	100.00-44.3	0.001>
V20	16.17	28.20-0.00	21.83	43.44-14.05	0.001>
Heart					
Dmean	3.82	13.25-0.46	10.01	16.87-5.45	0.001>
V5	11.41	50.68-0.00	94.75	100.00-44.79	0.001>
V30	4.01	13.71-0.00	1.56	7.87-0.00	0.001>
Spinal cord					
Dmax	0.38	3.78-0.22	13.99	38.00-0.36	0.001>
Dmean	0.22	0.91-0.12	3.77	9.05-0.55	0.001>
D2	0.34	2.67-0.10	12.97	34.30-0.45	0.001>
Contralateral breast					
Dmean	0.44	3.94-0.11	5.98	9.42-3.63	0.001>
Esophagus					
Dmean	0.45	8.32-0.25	9.04	16.55-1.48	0.001>

Vx, volume (%) receiving x dose (Gy) or higher; Dmax, maximum dose; Dmean, mean dose; D2, the dose to 2% of the spinal cord.

Table 4. Comparison of dosimetric parameters of TomoDirect and TomoHelical plans of the right and left-sided chest wall.

Parameter	Right-sided(n=13)				Left-side(n=17)					
	TomoDirect		TomoHelical		TomoDirect			TomoHelical		P value
	Median	Range	Median	Range	P value	Median	Range	Median	Range	
Treatment time (s)	300	486.00-180	294	.144-198	0.238	300	564-168	324	600-120	0.338
PTV										
Dmin	25.56	35.15-7.33	33.0	40.54-30.13	0.002	21.67	33.71-5.37	34.75	42.48-26.45	0.001>
Dmean	50.88	51.35-49.51	51.41	52.47-49.55	0.005	50.92	53.22-50.37	51.49	54.23-50.70	0.016
Dmax	56.91	77.54-53.49	57.00	59.29-53.33	0.133	56.24	71.73-54.09	56.55	61.01-55.51	0.981
V95	97.42	99.3-91.48	97.30	99.40-89.30	0.382	94.21	98.75-90.37	96.40	99.33-90.80	0.070
V107	1.44	8.13-0.00	4.33	36.06-0.00	0.005	1.84	92.74-0.09	11.54	38.34-1.45	0.049
D2	53.43	57.25-51.58	53.95	56.12-52.09	0.028	53.55	59.06-52.32	54.57	57.60-53.32	0.022
D50	51.08	51.37-49.86	51.49	52.89-50.20	0.002	51.18	52.85-48.30	51.68	54.52-50.89	0.049
D98	46.10	48.91-41.06	47.14	49.18-43.88	0.152	43.32	48.25-38.12	46.35	48.69-43.32	0.007
HI	0.13	0.32-0.09	0.13	0.19-0.10	0.507	0.19	0.34-0.12	0.17	0.24-0.09	0.210
CI	0.97	0.99-0.91	0.97	0.99-0.89	0.753	0.94	0.98-0.90	0.96	0.99-0.91	0.068
Ipsilateral lung										
Dmean	9.07	12.62-5.00	14.26	19.70-10.63	0.001	8.04	14.70-4.59	15.01	22.80-11.65	0.001>
V5	27.29	31.45-20.64	85.25	98.73-66.76	0.002	23.25	41.00-0.00	88.94	100-44.33	0.001>
V20	17.55	23.35-7.85	21.22	35.37-14.05	0.016	15.38	28.20-0.00	22.12	43.44-15.44	0.001
Heart										
Dmean	0.74	7.65-0.46	10.19	14.21-5.45	0.001	6.05	13.25-0.69	9.83	16.87-6.76	0.001
V5	0.15	24.19-0.00	98.90	100.0-44.79	0.001	17.87	50.68-0.64	86.37	100.00-49.53	0.001>
V25	0.00	12.26-0.00	0.73	10.38-0.00	0.260	8.86	21.97-0.00	4.54	12.78-0.24	0.006
V30	0.00	10.28-0.00	0.00	1.99-0.00	0.917	7.71	3.94-0.11	2.79	7.87-0.0	0.001>
Spinal cord										
Dmax	0.38	1.21-0.22	10.55	38.00-3.44	0.001	0.40	3.78-0.23	14.23	27.89-0.36	0.001>
Dmean	0.20	0.71-0.12	3.75	7.93-1.08	0.001	0.24	0.91-0.14	4.47	9.05-0.55	0.001>
D2	0.33	2.11-0.10	8.19	34.30-2.91	0.001	0.36	2.67-0.17	13.08	23.90-0.45	0.001>
Contralateral breast										
Dmean	0.41	1.34-0.19	5.57	9.42-3.63	0.002	0.72	3.94-0.11	6.10	9.14-4.28	0.001
V5	0.86	6.69-0.00	41.77	75.78-14.79	0.003	2.49	19.76-0.00	56.19	93.30-24.18	0.001
Esophagus										
Dmean	0.43	0.71-0.25	10.42	14.21-5.45	0.001	0.45	8.32-0.30	8.22	16.55-4.70	0.001>

PTV, Planning Target Volume; Dmin: Minimal dose; Dmean, mean dose; D2, the dose to 2% of the volume; D50, the dose to 50% of the target volume; Dmax, maximum dose; Vx, volume (%) receiving x dose (Gy) or higher.

DISCUSSION

Treatment-planning comparison studies^(11,16,17) have shown that TomoHelical IMRT plans provide superior target dose homogeneity and better normal tissue sparing in breast cancer radiation therapy. However, the drawbacks of HT in PM and whole breast RT are prolonged treatment time and an increased low dose radiation to healthy tissues. While many studies⁽¹⁰⁻¹²⁾ investigate usage of Tomodirect for early breast cancer after lumpectomy, but, to our best knowledge, the only work on TomoDirect for chest wall is that of Jones *et al.*⁽¹³⁾. But our series were larger than Jones *et al.*⁽¹³⁾. To evaluate which tomotherapy technique is superior in chest wall irradiation, we compared treatment time and dosimetric results of radiotherapy of the chest wall on 30 patients using two delivery modalities available with tomotherapy, fixed fields tomotherapy (TD) or helical tomotherapy (TH).

Jones *et al.*⁽¹³⁾ compared five techniques for 10 post-mastectomy patients with positive nodes, 4 field fixed beam tomotherapy (4FBT) IMRT, 11FBT 3D, 11FBT IMRT, HT 3D, HT IMRT. They found that all tomotherapy and conventional IMRT plans achieved the prescription of V47.5 Gy of PTVs > 95%. However, HT and conventional IMRT resulted in superior target dose homogeneity than 11FBT 3D (1.21) and 11FBT IMRT (1.21) for the chest wall in their study. Reynders *et al.*'s study⁽¹⁸⁾ mixed tumorectomy and mastectomy patients. They reported that conventional plans had worse PTV coverage when compared to TH and TD plans. In their study, the value of V95 in supine TH was higher than that in supine TD two beams in postmastectomy chest wall irradiation (99.87 vs 97.89). We found that the mean value of V95 for TH was higher than that for TD, but this difference was not statistically significant (96.2% vs. 95.1%, $p > 0.05$). There was also no difference between the values of CI and HI of TD and TH plans (CI: 0.95 vs 0.96, $p = 0.10$ and HI: 0.16 vs 0.16, $p = 0.15$, respectively). Hacıislamoglu *et al.*⁽¹¹⁾ showed that the mean value of PTV V107 was $0.2 \% \pm 0.1$ in TH and TH plan had the most conformed and homogeneous

dose distribution in whole breast irradiation. However, they did not compare TH and TD plans in their study. Qi *et al.*⁽¹⁹⁾ reported that volumetric-modulated arc therapy (VMAT) plans were more inhomogeneous than the TH and TD plans. Murai *et al.*⁽²⁰⁾ reported that in the thoracic wall RT plans, the CI in TD plans was worse than that in TH (2.21 vs. 4.63, respectively; $p = 0.004$), although D95% in TomoDirect was better than that in TH ($97 \pm 1\%$ vs. $96 \pm 1\%$, $p = 0.04$).

There is a correlation between increasing irradiated lung volumes and pulmonary complications⁽²¹⁾ and the choice of RT technique is critical. Schubert *et al.*⁽²²⁾ reported that HT resulted in the larger low dose volumes and higher mean dose of the ipsilateral lung compared to TD ($p = 0.02$). Rudat *et al.*⁽⁸⁾ found that the mean dose of ipsilateral lung (MLD) statistically significantly reduced with tangential beam IMRT. Similar to previous studies^(13,20,22); in our study, the values of Dmean, V5 (Volume of lung receiving at least 5 Gy) and V20 (Volume of lung receiving at least 20 Gy) of the ipsilateral lung in TD was significantly lower than that in TH plan for all 30 patients ($p < 0.001$, $p < 0.001$ and $p = 0.001$, respectively). These results can be explained by rotational delivery of a fan beam within a helical geometry of helical tomotherapy. In our study, for 30 patients, the Dmean and V5 values of the heart in TD were significantly lower than those in TH ($p < 0.001$ for both). However, the value of V30 of the heart in TomoDirect was higher than that in TomoHelical ($p < 0.001$, $n = 30$). TD plans reduced doses of the ipsilateral lung and mean dose and volumes receiving low dose irradiation of the heart as well as provided acceptable target dose homogeneity, for only chest wall irradiation in post-mastectomy patients. However, TH is superior when added nodal irradiation. Previous studies^(13,19,20,22) seem to support this view. Qi *et al.*⁽¹⁸⁾ reported that the average mean doses administered to the heart were lower in TH plans than those in TD for the cases with regional node involvement (8.8 Gy vs. 11.8 Gy, respectively). V25 and V30 values of the heart were significantly lower in TH than those in TD plan in left-sided chest wall irradiation ($p = 0.006$

and $p < 0.001$, respectively). However, V5 values in TH was significantly higher than those in TD ($p < 0.001$). In the right-sided chest wall irradiation, there was no difference between two plans for V25 and V30 values of heart ($p = 0.260$ and $p = 0.917$, respectively). However, similar to left-sided chest wall irradiation, V5 values in TH was significantly higher than those in TD ($p = 0.001$).

For 30 patients, we found that the value of Dmean of the contralateral breast in TomoDirect was also significantly lower than those in TomoHelical plan ($p < 0.001$). The higher dose to the contralateral breast with TH technique because of the rotational beam delivery may be a concern for young patients and may result with a risk of radiation-induced cancer in long term. The indications of post-mastectomy RT for breast cancer include lymph node involvement or tumor size equal to or greater than 5cm⁽²³⁾. We compared two modes of tomotherapy for only post-mastectomy chest wall irradiation without lymph nodes and we found that tomotherapy mode better protected healthy tissues.

CONCLUSION

TD and TH IMRT plans have similar conformity and homogeneity for PTV. However, considering larger low-dose radiation regions on the critical organs which lead to increase rate of radiation-induced secondary malignancies, lung and heart disease, TD mode improves dose distribution and provides a better protection for critical organs in post-mastectomy chest wall irradiation.

Conflicts of interest: Declared none.

REFERENCES

1. EBCTCG (Early Breast Cancer Trialists' Collaborative Group), McGale P, Taylor C, Correa C, Cutter D, Duane F, Ewertz M, Gray R, Mannu G, Peto R, et al. (2014) Effect of radiotherapy after mastectomy and axillary surgery on 10-year recurrence and 20-year breast cancer mortality: meta-analysis of individual patient data for 8135 women in 22 randomised trials. *Lancet Lond Engl*, **383**: 2127–35.
2. Overgaard M, Hansen PS, Overgaard J, Rose C, Andersson M, Bach F, Kjaer M, Gadeberg CC, Mouridsen HT, Jensen MB, et al (1997). Postoperative Radiotherapy in High-Risk Premenopausal Women with Breast Cancer Who Receive Adjuvant Chemotherapy. *N Engl J Med*, **337**: 949–55.
3. Ragaz J, Olivetto IA, Spinelli JJ, Phillips N, Jackson SM, Wilson KS, Knowling MA, Coppin CM, Weir L, Gelmon K, et al. (2005) Locoregional radiation therapy in patients with high-risk breast cancer receiving adjuvant chemotherapy: 20-year results of the British Columbia randomized trial. *J Natl Cancer Inst*, **97**: 116–26.
4. Overgaard M, Jensen M-B, Overgaard J, Hansen PS, Rose C, Andersson M, Kamby C, Kjaer M, Gadeberg CC, Rasmussen BB, et al. (1999) Postoperative radiotherapy in high-risk postmenopausal breast-cancer patients given adjuvant tamoxifen: Danish Breast Cancer Cooperative Group DBCG 82c randomised trial. *The Lancet*, **353**: 1641–8.
5. Cavey ML, Bayouth JE, Endres EJ, Pena JM, Colman M, Hatch S (2005) Dosimetric comparison of conventional and forward-planned intensity-modulated techniques for comprehensive locoregional irradiation of post-mastectomy left breast cancers. *Med Dosim Off J Am Assoc Med Dosim*, **30**:107–16.
6. Ma J, Li J, Xie J, Chen J, Zhu C, Cai G, Zhang Z, Guo X, Chen J (2013) Post mastectomy linac IMRT irradiation of chest wall and regional nodes: dosimetry data and acute toxicities. *Radiat Oncol Lond Engl*, **8**:81.
7. Michael Ashenafi RAB (2009) Feasibility of postmastectomy treatment with helical tomotherapy. *Int. J Radiat Oncol Biol Phys*, **77**:836–42.
8. Rudat V, Aziz Alaradi A, Mohamed A, Al-Yahya K, Altuwaijri S (2011) Tangential beam IMRT versus tangential beam 3D-CRT of the chest wall in postmastectomy breast cancer patients: A dosimetric comparison. *Radiat Oncol Lond Engl*, **6**:26.
9. Mayo CS, Urie MM, Fitzgerald TJ (2005) Hybrid IMRT plans—concurrently treating conventional and IMRT beams for improved breast irradiation and reduced planning time. *Int. J Radiat Oncol*, **61**:922–32.
10. Borca VC, Franco P, Catuzzo P, Migliaccio F, Zenone F, Aimonetto S, Peruzzo A, Pasquino M, Russo G, La Porta, et al. (2012) Does TomoDirect 3DCRT represent a suitable option for post-operative whole breast irradiation? A hypothesis-generating pilot study. *Radiat Oncol Lond Engl*, **7**:211.
11. Haciislamoglu E, Colak F, Canyilmaz E, Dirican B, Gurdalli S, Yilmaz AH, Yoney A, Bahat Z (2015) Dosimetric comparison of left-sided whole-breast irradiation with 3DCRT, forward-planned IMRT, inverse-planned IMRT, helical tomotherapy, and volumetric arc therapy. *Phys Medical PM Int J Devoted Appl Phys Med Biol Off J Ital Assoc Biomed Phys AIFB*, **31**:360–7.
12. Kim MJ, Kim JH, Kim HK, Cho KC, Chun BC, Cho JH (2011). Evaluation of tangential fields' technique using tomotherapy after breast partial mastectomy. *Journal of the Korean Society for Radiotherapeutic Tech-*

- nology, **23**: 59-66.
13. Jones R, Yang W, Read P, Sheng K (2011) Radiation therapy of post-mastectomy patients with positive nodes using fixed beam tomotherapy. *Radiother Oncol J Eur Soc Ther Radiol Oncol*, **100**: 247–52.
14. Prescribing, recording, and reporting proton-beam therapy: contents (2007) *J ICRU*, **7(2)**: NP.
15. Hodapp N (2012) [The ICRU Report 83: prescribing, recording and reporting photon-beam intensity-modulated radiation therapy (IMRT)]. *Strahlenther Onkol Organ Dtsch Röntgenges Al*, **188**: 97–9.
16. Goddu SM, Chaudhari S, Mamalui-Hunter M, Pechenaya OL, Pratt D, Mutic S, Zoberi I, Jeswani S, Powell SN, Low DA (2009) Helical tomotherapy planning for left-sided breast cancer patients with positive lymph nodes: comparison to conventional multiport breast technique. *Int J Radiat Oncol Biol Phys*, **73**: 1243–51.
17. Coon AB, Dickler A, Kirk MC, Liao Y, Shah AP, Strauss JB, Chen S, Turian J, Griem KL (2010) Tomotherapy and Multi-field Intensity-Modulated Radiotherapy Planning Reduce Cardiac Doses in Left-Sided Breast Cancer Patients With Unfavorable Cardiac Anatomy. *Int J Radiat Oncol*, **78**: 104–10.
18. Reynders T, Tournel K, De Coninck P, Heymann S, Vinh-Hung V, Van Parijs H, Duchateau M, Linthout N, Gevaert T, Verellen D, et al. (2009) Dosimetric assessment of static and helical TomoTherapy in the clinical implementation of breast cancer treatments. *Radiother Oncol J Eur Soc Ther Radiol Oncol*, **93**: 71–9.
19. Qi XS, Liu TX, Liu AK, Newman F, Rabinovitch R, Kavanagh B, Hu YA (2014) Left-sided breast cancer irradiation using rotational and fixed-field radiotherapy. *Med Dosim Off J Am Assoc Med Dosim*, **39**: 227–34.
20. Murai T, Shibamoto Y, Manabe Y, Murata R, Sugie C, Hayashi A, Ito H, Miyoshi Y (2013) Intensity-modulated radiation therapy using static ports of tomotherapy (TomoDirect): comparison with the TomoHelical mode. *Radiat Oncol*, **8**: 68.
21. Lind PA, Wennberg B, Gagliardi G, Fornander T (2001) Pulmonary complications following different radiotherapy techniques for breast cancer, and the association to irradiated lung volume and dose. *Breast Cancer Res Treat*, **68**: 199–210.
22. Schubert LK, Gondi V, Sengbusch E, Westerly DC, Soisson ET, Paliwal BR, Mackie TR, Mehta MP, Patel RR, Tomé WA, et al. (2011) Dosimetric comparison of left-sided whole breast irradiation with 3DCRT, forward-planned IMRT, inverse-planned IMRT, helical tomotherapy, and tomotherapy. *Radiother Oncol*, **100**: 241–6.
23. Farhan F, Esmati E, Maddah Safaei A, Shahriarian Sh, Mirai Ashtiani MS, Akbari Hamed E (2015) Ultrasound-guided boost irradiation of tumor cavity after lumpectomy in breast cancer. *Int J Radiat Res*, **13**: 325-329.