

# New drug in neoadjuvant chemoradiation for rectal cancer

M. Aghili<sup>1</sup>, M. Babaei<sup>1\*</sup>, M. Ganjalikhani<sup>2</sup>, F. Azmoodeh Ardalan<sup>3</sup>

<sup>1</sup>Department of Radiotherapy Oncology, Cancer Institute, Tehran University of Medical Sciences, Tehran, Iran

<sup>2</sup>Tehran University of Medical Sciences, Tehran, Iran

<sup>3</sup>Department of Central Pathology, Imam Khomeini Hospital, Tehran University of Medical Sciences, Tehran, Iran

## ABSTRACT

### ► Original article

**\* Corresponding author:**

Dr. Mohammad Babaei,

Fax: +98 21 61192584

E-mail:

[m-babaei@sina.tums.ac.ir](mailto:m-babaei@sina.tums.ac.ir)

Submitted: Nov. 2012

Accepted: Aug. 2013

*Int. J. Radiat. Res., January 2014;*  
12(1): 33-38

**Background:** In recent years, neoadjuvant chemoradiation and subsequent surgical resection with total mesorectal excision has been shown to increase local control with decreased toxicity. Neoadjuvant chemoradiotherapy is the standard treatment for locally advanced rectal cancer. In this study we evaluated the efficacy a cox-2 inhibitor on pathologic response, sphincter preservation and acute toxicity during neoadjuvant chemoradiation.

**Materials and Methods:** Thirty-six patients with Adenocarcinoma of rectum (up to 15 cm of anal verge) was enrolled in this phase 2 study. Patients were undergone endorectal ultrasound, abdomino-pelvic and chest CT scan for staging. Then received neoadjuvant concurrent chemo radiation (capecitabine 825 mg/m<sup>2</sup> bid in combination with celecoxib 100 mg qid and Radiotherapy "50-50.4Gy/25-28fraction"). Surgery was done 6-8 weeks after Chemoradiation. Acute complications were scored by common toxicity criteria 3.0 and tumor response was graded by tumor regression grade.

**Results:** Of 36 patients, total mesorectal excision was done in 30 patients. Tumor regression grade was reported as: 8 patients (26.7%) had grade 0 or complete response, 10 patients (33.3%) had grade 1 or moderate response, 9 patients (30%) had grade 2 or minimal response and 3 patients (10%) had grade 3 or poor response. Tumor down staging was 43.3% and Node down staging was 30.8%. No patient had skin reaction or cardio-vascular toxicity.

**Conclusion:** Results indicate celecoxib in combination with neoadjuvant chemoradiation is safe and associated with low toxicity. This combination can promote pathologic complete response, tumor regression grade and T and N down staging in rectal adenocarcinoma.

**Keywords:** Rectal cancer, celecoxib, tumor regression, neoadjuvant chemoradiation.

## INTRODUCTION

Colorectal cancer (CRC) is the third most common malignant neoplasm worldwide <sup>(1)</sup>. According to cancer registry report in 2009, colorectal cancers are the fourth most common cancer in Iran <sup>(2)</sup>. Therefore it is a major public health problem. So developing new colorectal cancer drugs is highly desired. Standard treatment for locally advanced rectal

cancer (stage II & III) is surgery and chemoradiotherapy (before or after surgery) and chemotherapy <sup>(3)</sup>. Neoadjuvant chemoradiation is associated with easier resection, lower risk of small bowel toxicity, better functional result, more patient tolerance and better pathologic response <sup>(4)</sup>.

Cyclooxygenase-2 (COX II) enzyme as an effective enzyme in prostaglandine synthesis has an important role in inflammation and tumor

growths and COX II gene over expression is detected in 40% of colon adenoma and 90% of colorectal adenocarcinoma <sup>(5)</sup>.

Nowadays, preclinical data suggest that COX-2 inhibitors with chemotherapy are an effective treatment for gastrointestinal tumours. Although, the exact mechanism is still unclear. Celecoxib, as a selective COX-2 inhibitor, has a very good application prospect for the prevention and the treatment of colon cancer. Meanwhile, it has received researchers' attention due to its anti-tumour effects <sup>(6-7)</sup>.

In this study, we have evaluated the effect of selective inhibitor of COX-II receptor in combination with standard neoadjuvant chemoradiotherapy in locally advanced rectal cancer on pathologic response, sphincter preservation and the rate of acute treatment's complications. These results can help the progress and applicability of selective COX-2 inhibitors as novel drug for colorectal cancer treatment, and meet the needs of related future research.

## MATERIALS AND METHODS

After ethical approval by university ethic committee, 36 patients with stage II & III adenocarcinoma of rectum (up to 15 cm from anal verge) were enrolled in this study. In our department (Radiotherapy Oncology department of Cancer Institute) between April 2008 and October 2009 and we followed the patients until May 2010.

### Patients

Between April 2008 and October 2009, 36 patients with locally advanced rectal cancer were enrolled in this study. The characteristics of patients are summarized in table 1.

The eligibility criteria for this study were as follows: (a) histologically proven rectal adenocarcinoma; (b) extension of the primary tumor through the bowel wall, or positive lymph nodes without evidence of any distant metastatic disease (T3-4, or N positive and M0) on endorectal ultrasonography (EUS) and

**Table 1.** patient characteristic.

Age(years)	mean	48±14.5
	range	22-79
Sex	female	17
	male	19
Tumor location	Upper third	4 (11%)
	Middle third	15(41%)
	Lower third	9 (25%)
	Upper and middle third	4 (11%)
	Middle and lower third	4 (11%)
Clinical stage	T3N0	19 (52.8%)
	T3N1	14(38.9%)
	T4N0	1(2.8%)
	T4N1	2(5.6%)
CEA*** before treatment( ng/dl)	mean	7.35±0.26
	range	1-35
Type of surgery	APR*	10 (33%)
	LAR**	20 (67%)
	No surgery	6

\* APR= abdomino peritoneal resection \*\* LAR = low anterior resection \*\*\*CEA=Carcino Embryonic Antigen.

computerized tomography (CT) scan; (c) age 18-75 years; (d) ECOG (Eastern Cooperative Oncology Group) performance status of 2 or below; (e) adequate bone marrow reserve (white blood cell count  $\geq 4,000/\text{mm}^3$ , platelet count  $\geq 100,000/\text{mm}^3$ , hemoglobin  $\geq 10 \text{ mg/dl}$ ); (f) adequate renal function (serum creatinine level  $\leq 1.5 \text{ mg/dl}$ , calculated creatinine clearance  $\geq 50 \text{ ml/min}$ ); (g) adequate liver function (liver transaminase levels  $\leq 3$  times the upper normal limit, serum bilirubin  $\leq 1.5 \text{ mg/dl}$ ).

The exclusion criteria included: (a) a tumor type other than an adenocarcinoma; (b) pregnant or lactating women; (c) familial history of colorectal cancer; (d) hypersensitivity to celecoxib, sulfonamide, aspirin or other NSAIDs (non-steroidal anti inflammatory drugs); (e) prior pelvic irradiation; (f) active gastrointestinal ulcers or history of gastric bleeding ;(g) active ischemic heart disease, cerebrovascular disease or congestive heart failure.

Pretreatment evaluations were performed during 4 weeks before the start of the treatment and included complete history, physical

examination, total colonoscopy, endorectal ultrasound (for T&N staging), CT scan of the chest and abdomen and pelvis (for M staging), CEA (carcino embryonic antigen) and complete laboratory tests.

### **Treatment protocol**

The patients received neoadjuvant chemoradiotherapy with Capecitabine (825 mg/m<sup>2</sup> BID) and celecoxib (100 mg QID) and radiotherapy with 18 megavoltage X-ray was done with standard protocol (50 to 50.4 Gy in 25 to 28 fractions with 3 or 4 fields' technique).

During chemoradiation, treatment tolerance was evaluated with weekly visits and examinations (CBC) and the toxicities reported on the basis of Common Toxicity Criteria (CTC 3.0). 6 to 8 weeks after the end of chemoradiation, patients underwent surgery. Depending on the localization of the tumor and the tumor regression, different types of surgical techniques were used (low anterior resection, abdominoperianal resection), though a total mesorectal excision was always performed.

Tumor regression was assessed by examining the pathological resection specimen. Response to treatment was reported as tumor regression grade by a skilled pathologist.

All patients were visited one month, three months and six months after surgery. Each follow up assessment included: physical examination of patients, CEA serum level, probable complications and toxicity, abdominal ultrasonography, and liver function tests. Also total colonoscopy was done one year after surgery.

Sample and statistical analysis were performed by SPSS version 15 software. For the evaluation of pathologic complete response, tumor regression grade, tolerance of treatment mean and SD were used.

## **RESULTS**

For 30 patients, who underwent TME (total mesorectal excision) surgery mean interval between the end of chemoradiation and surgery was 6.2 weeks. Six have not been operated; two of them appeared to have multiple

unresectable liver metastases; three refused surgery and one had severe bleeding during surgery so the surgery procedure was not completed.

### **Toxicity evaluation**

2 of 36 patients had treatment interruptions because of grade 2 thrombocytopenia. Celecoxib and capecitabine were discontinued for one and two weeks in these two cases. The most common toxicities was grades I diarrhea (24 of 36, 66%). Only 2 of 36 (6%) had cystitis (grade 1). No patient had skin reaction. one patient (3%) had gastritis that was improved by omeprazole and celecoxib was not discontinued.

### **Response evaluation**

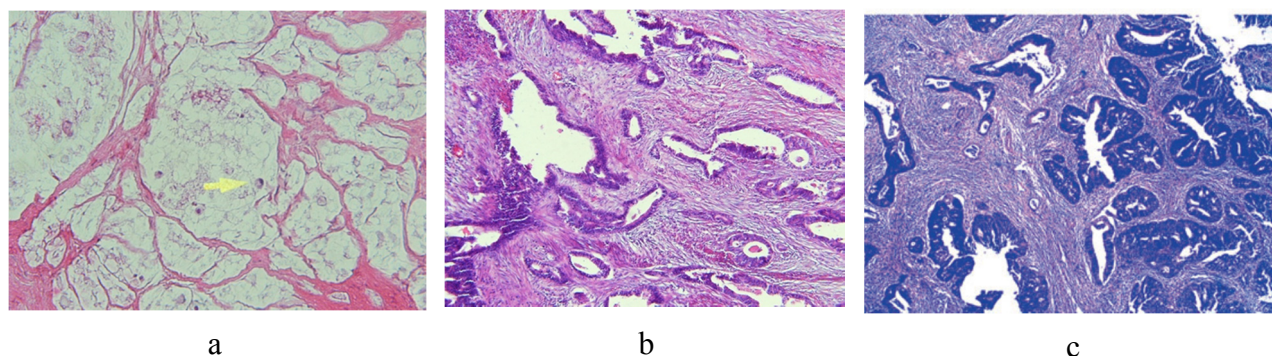
Response was evaluated by pathological examination of the surgical resection specimen after surgery. Tumor regression grade was reported according to the degree of radiation fibrosis and the tumor regressive changes (figure 1). Tumor regression grade is shown in table 2.

8 of 30 patients (26.7%) had pathologic complete response (pCR). All patients who underwent sphincter preservative surgery had fecal continence.

T down staging observed in 13 of 30 patients and N down staging in 4 of them. 3 of 13 patients with tumor located in lower third of rectum who were planned to go under APR by surgeon in the initial evaluation, after neoadjuvant therapy underwent sphincter preserving surgery.

**Table 2 . Tumor Regression Grade (TRG).**

Description	Three-point TRG	No. of patients (%)
No viable cancer cells	0	8 (26.7%)
Single cells or small groups of cancer cells	1	10 (33.3%)
Residual cancer outgrown by fibrosis	2	9 (30%)
Significant fibrosis outgrown by cancer	3	3 (10%)



**Figure 1 .** a, Tumor regression grade 1 of 3; b, Tumor regression grade 2 of 3, c, Tumor regression grade 3 of 3.

### Follow up

The median duration of follow-up of the patients was 16 months (range: 7 months – 23 months) and the mean time of follow-up was 14.4 months. 6 patients didn't undergo surgery and 2 of 30 patients who underwent surgery died because of neutropenic fever during adjuvant chemotherapy and the other because of car accident. 20 were followed to one year after surgery, of whom 95% had normal colonoscopic results. During one year of follow up serum level of CEA increased up in 2 patients, one with liver metastasis and the other with local recurrence.

Three patients refused from surgical resection but none of them recurred until the time of analysis, may 2010.

## DISCUSSION

This is a phase II study for evaluating the efficacy of a COX II inhibitor (celecoxib) in combination with neoadjuvant chemoradiotherapy in patients with locally advanced rectal cancer. Standard treatment for locally advanced rectal cancer is perioperative chemoradiation and adjuvant chemotherapy <sup>(3)</sup>.

NSABP-R03 study which was done to compare chemoradiotherapy before or after surgery in locally advanced rectal cancer showed that neoadjuvant chemoradiotherapy has a significantly higher rate of 5 years disease free survival and better local control and higher sphincter preservation <sup>(8)</sup>.

Thus neoadjuvant chemoradiation has

become the standard treatment for T3 or T4 rectal cancers, clinically node positive, detected by MRI or TRUS, T1 or T2 rectal cancers, distal rectal cancers which are considered for APR (abdominoperianal resection) at initial evaluations, before any treatments, or tumors with invasion to mesorectal fascia on preoperative imaging <sup>(9)</sup>. Our patients received capecitabine. Capecitabine is an orally active fluoropyrimidine pro-drug which is changed to 5-FU within tumor cells. Therefore, capecitabine has this advantage that has convenience of administration, which is attractive to patients, and it is tumor-selective <sup>(11-12)</sup>.

### Response

One of purposes of this study was evaluation of tumor regression grade (TRG). Ryan *et al.* in 2005 reported a study with 60 patients with rectal cancer received chemoradiotherapy (50Gy/25F with infusional 5-FU ), in five point scoring system , 9 patients had TRG-1 (15%), one patient had TRG-2 (1.6%), 17 patients had TRG-3 (28.3%), 20 patients had TRG-4 (33%) and 13 patients had TRG-5 (21.6%). in three point scoring system 10 patients had TRG-1 (16.6%), 19 patients had TRG-2 (31.6%) and 31 patients had TRG-3 (51.6%) [13]. In our study, tumor regression grade (TRG) was better than this study and celecoxib administration can be the reason of this better tumor regression grade.

Debuquoy in 2009 reported a double blind randomized study with radiation (50 Gy/25F) +

Infusional 5-FU +/- celecoxib (400 mg, BID) on 35 patients (seventeen and eighteen patients were randomly allocated to the placebo and the



celecoxib arm) and response was evaluated by pathological examination of the surgical resection specimen after the planned surgery and a better response was seen in the celecoxib arm with 61% of the patients with a good response (Dworak grade 3 and 4) compared to 35% in the placebo group (Dworak grade 3: good regression, Dworak grade 4: complete pathological response). Also the number of patients with T and N downstaging in the celecoxib group (72%) was slightly larger than the placebo group (59%). Also in the celecoxib group 1 patient had stomatitis, 2 patients had skin rash, 5 patients had neutropenia and 2 patients had dizziness <sup>(14)</sup>. In our study, pathological response was evaluated by tumor regression grade (TRG) system and 60 % of patients were in grade 1 (which is equal to no viable cancer cells or Single cells or small groups of cancer cells) the same as Dworak grade 3 and 4. T down staging was 43.3% and N down staging was 30.8% and pathological complete response (pCR) was 26.7%, that, lower dose and shorter duration of celecoxib administration might have caused the difference. Also none of the patients had skin rash, cardiovascular toxicities ,neutropenia and dizziness and our treatment had fewer complications.

The results of this study are in agreement with earlier animal studies. Bandaru S at 2000 reported that celecoxib has chemopreventive effect while administrated at different stages of carcinogenesis <sup>(15)</sup>.

### Toxicity

Jakobson *et al.* in 2007 began the study on patients with local rectal cancer and the patients received chemoradiation with celecoxib (400mg bid ),but the study was stopped because of maculopapular rashes (in 49% of patients). In our study the dose of celecoxib was 100 mg QID, but none of our patients had skin rash <sup>(16)</sup>.

It has been shown that when selective COX-2 inhibitors are used in prevention of colon cancer, they are associated with higher cardiovascular events comparing with placebo <sup>(17-19)</sup>. But our study was not done in preventive setting, although no cerebro vascular events were observed. This might be attributed to the

shorter duration of celecoxib administration (5-6 weeks).

## CONCLUSION

we conclude that celecoxib (400 mg/day) maybe safe and effective but for longer duration of administration have better response rate. Celecoxib in combination with neoadjuvant chemoradiation is safe and can promote pathological complete response (pCR) and T and N downstaging and tumor regression grade (TRG).

## REFERENCES

1. Jemal A, Siegel R, Ward E, Hao Y, Xu J, Murray T (2008) Cancer statistics. *CA Cancer J Clin*, **58**: 71-96.
2. Hagh Azali M and Ramazani R (2008) Cancer Registry Report of Iran. Ministry of Health and Medical Education, Tehran, Iran.
3. O'Neil BH and Tepper JE (2007) Current options for the management of rectal cancer. *Curr Treat Options Oncol*, **8**: 331-8.
4. Onaitis MW, Noone RB, Fields R, Hurwitz H, Morse M, Jowell P (2001) Complete response to neoadjuvant chemoradiation for rectal cancer does not influence survival. *Ann Surg Oncol*, **8**: 801-6.
5. Keller JJ and Giardiello FM (2003) Chemoprevention strategies using NSAIDs and COX-2 inhibitors. *Cancer Biol Ther*, **2**: 144-149.
6. Sade A, Tunçay S, Çimen İ, Severcan F, Banerjee S (2012) Celecoxib reduces fluidity and decreases metastatic potential of colon cancer cell lines irrespective of COX-2 expression. *Biosci Rep*, **32**: 35-44.
7. Moreira L and Castells A (2012) Cyclooxygenase as a target for colorectal cancer chemoprevention. *Curr Drug Targets*, **12**: 1888-1894.
8. Sauer R, Becker H, Hohenberger W, Rödel C, Wittekind C, Fietkau R (2004). Preoperative versus postoperative chemoradiotherapy for rectal cancer. *N Engl J Med*, **351**: 1731-40.
9. Guillem JG, Díaz-González JA, Minsky BD, Valentini V, Jeong SY, Rodriguez-Bigas MA (2008) cT3N0 rectal cancer: potential overtreatment with preoperative chemoradiotherapy is warranted. *J Clin Oncol*, **26**: 368-73.
11. Wong SJ, Sadasivan C, Erickson B, Ota D, Mulkerin D, Thomas J, Holen K, Meadows S (2004) A phase II trial of preoperative capecitabine and concurrent radiation for locally advanced rectal cancer. *Proc ASCO*, **23**: 312.
12. Vanhoefera U, Rougierb P, Bornerc M, Munozd A, Van

- Laetheme JL, Sobrerof A (2004) Irinotecan in combination with new agents. *European Journal of Cancer Supplements*, **2**: 14–20.
13. Ryan R, Gibbons D, Hyland JM, Treanor D, White A, Mulcahy HE, *et al.* (2005) Pathological response following longcourse Neoadjuvant chemoradiotherapy for locally advanced rectal cancer. *Histopathology*, **47**: 141-6.
  14. Debucquoy A, Roels S, Goethals L, Libbrecht L, Van Cutsem E, Geboes K, *et al.* (2009) Double blind randomized phase II study with radiation+5-fluorouracil+/- celecoxib for resectable rectal cancer. *Radiother Oncol*, **93**: 273-8.
  15. Bandaru S, Reddy??, Yoshinobu Hirose, Ronald Lubet, *et al.* (2000) Chemoprevention of Colon Cancer by Specific Cyclooxygenase-2 Inhibitor, Celecoxib, Administered Different Stages of Carcinogenesis. *Cancer Res*, **60**: 293-297.
  16. Jakobsen A, Mortensen JP, Bisgaard C, Lindebjerg J, Rafaelsen SR, Bendtsen VO (2008) A COX-2 inhibitor combined with chemoradiation of locally advanced rectal cancer: a phase II trial. *Int J Colorectal Dis*, **23**: 251-5.
  17. Bresalier RS, Sandler RS, Quan H, Bolognese JA, Oxenius B, Horgan K, *et al.* (2005) Cardiovascular events associated with rofecoxib in a colorectal adenoma chemoprevention trial. *N Engl J Med*, **352**:1092-102.
  18. Mukherjee D, Nissen SE, Topol EJ (2001) Risk of cardiovascular events associated with selective COX-2 inhibitors. *JAMA*, **286**:954-9.
  19. Solomon SD, McMurray JJ, Pfeffer MA, Wittes J, Fowler R, Finn P, *et al.* (2005) Cardiovascular risk associated with celecoxib in a clinical trial for colorectal adenoma prevention. *N Engl J Med*, **352**: 1071-80.