

# A novel case of quartet tumor: meningioma, angiomyolipoma, ependymoma and sarcoma: report of a case and review of the literature

C. Yavas<sup>1</sup>, P. Karabagli<sup>2</sup>, G. Yavas<sup>3</sup>, H.Acar<sup>4\*</sup>, O. Ata<sup>5</sup>

<sup>1</sup>Konya Training and Research Hospital, Department of Radiation Oncology Konya, Turkey

<sup>2</sup>Selcuk University, Department of Pathology Konya, Turkey

<sup>3</sup>Selcuk University, Department of Radiation Oncology Konya, Turkey

<sup>4</sup>Selcuk University, Department of Medical Genetics Konya, Turkey

<sup>5</sup>Selcuk University, Department of Medical Oncology Konya, Turkey

## ► Case report

## ABSTRACT

Multiple primary tumors in a single patient are relatively rare when four or more distinct lesions are considered. Herein, we report a case of woman with four different primary tumors: meningioma, renal angiomyolipoma, spinal ependymoma and high-grade soft tissue sarcoma. There was no family history and hereditary syndrome. The genetic analysis was completely normal. To best of our knowledge, the present patient is the first case in the literature, who presented with these four types of tumors.

**Keywords:** Angiomyolipoma, ependymoma, meningioma, sarcoma.

### \* Corresponding author:

Dr. Song Hilal Acar,

Fax: +90 332 4461608

E-mail: hilalacar@hotmail.com

Revised: April 2014

Accepted: May 2014

Int. J. Radiat. Res., January 2015;  
13(1): 73-78

DOI: 10.7508/ijrr.2015.01.010

## INTRODUCTION

The phenomenon of multiple primary neoplasms in the same individual was described firstly by Warren and Gates <sup>(1)</sup>. Recently, the early detection and the advances in therapy for malignant diseases have contributed to prolonged survival of patients, resulting in an increment of multiple primary tumors. However, the reports of multiple primary tumors are still uncommon. They appear more frequently in the upper digestive tract, respiratory system, head and neck region, or urogenital system. The incidence ranges from 2% to 10% <sup>(2)</sup>. Among those with multiple primary malignancies, double cancers is commonly seen, while triple cancers occur in 0.5% of patients, and quadruple or quintuple cancers occur in only less than 0.1% of the population <sup>(3)</sup>. Autopsy series have estimat-

ed the incidence of a second primary cancer ranges from 3% to 7% with the higher percentage representing the older age groups <sup>(4-5)</sup>. Herein we report a case with four primary tumors, all involving different organ systems.

## CASE REPORT

A 59-year-old woman admitted to the hospital, with a complaint of progressive weakness on her lower extremities over a 6-month history in January 2011. She denied tobacco usage or alcohol consumption. She was a housewife living in a small village. There was no family history.

The patient had a past history of meningioma. The mass located in the right parieto-occipital region 2.5×2×1.5 cm in size, the first of her cancers. It was curatively resected in November

2004. Pathological examination revealed that the tumor characterized was due to the formation of multiple, discrete, concentrically laminated, calcareous bodies (psammoma bodies). It was diagnosed as psammomatous meningioma, grade I (WHO, 2000) (figure 1). In 2010 she admitted to the hospital with left flank pain which was increased progressively within 3 months. The physical examination was unremarkable. Ultrasound demonstrated a hyperechoic mass on the left kidney. The CT revealed a heterogeneous mass in the left kidney measuring 8×5×3 cm. grossly; the tumor was confined within the renal capsule. A radical left nephrectomy was performed. The major histological components of the tumor were characterized by abnormally thick-walled vessels, mature fat cells, and smooth muscle

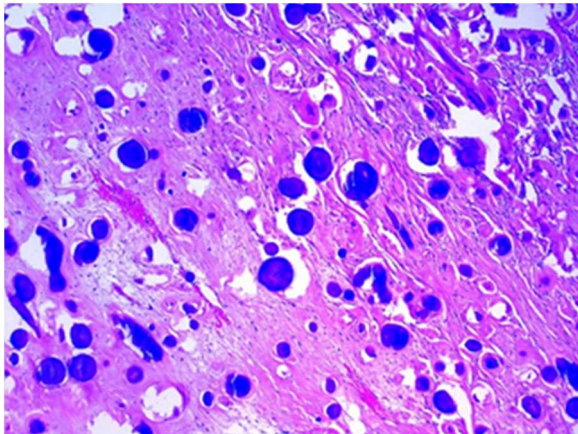


Figure 1. The tumor characterized by the abundance of psammoma bodies (H&E ×40).

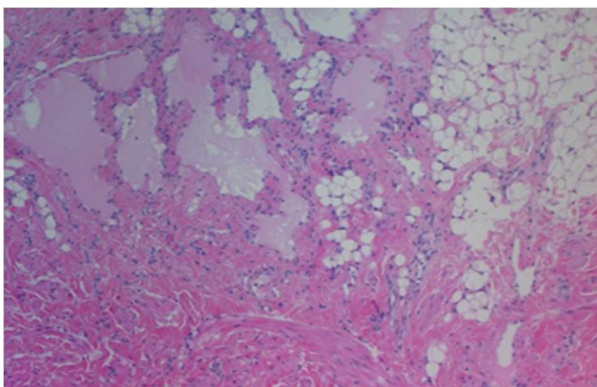


Figure 2. Renal angiomyolipoma showing mature fat cells, blood vessels, and smooth muscle cells (H&E ×100).

bundles. Pathologic examination revealed an angiomyolipoma which was her second tumor. The tumor composed of adipose tissue, smooth muscles and blood vessels (figure 2). After surgery the patient refused any further diagnostic work and treatment so she did not go to her routine follow-up until (a year later) the development progressive weakness on her lower extremities.

Neurological examination revealed a bilateral hemiparesis (3/5). Lumbar magnetic resonance imaging (MRI) revealed an intradural and extramedullary mass located in the level of L2-L3. On T1-weighted images, the mass appeared isointense whereas on T2-weighted images, it was hyperintense relative to the normal cord. A subtotal excision of the mass was then performed, which was followed by transient improvement. Histological findings indicated a diagnosis of tanycytic ependymoma grade II (WHO, 2007). The tumor characterized by markedly elongated spindle shaped cells, which were immunopositive for S-100 protein and glial fibrillary acidic protein (figure 3). Since the tumor subtotally resected, a total dose of 5000 cGy radiotherapy (RT) with 2 Gy/fraction was planned. RT field was defined as the preoperative tumor volume (determined by T1 magnetic resonance imaging (MRI) scan) plus 2

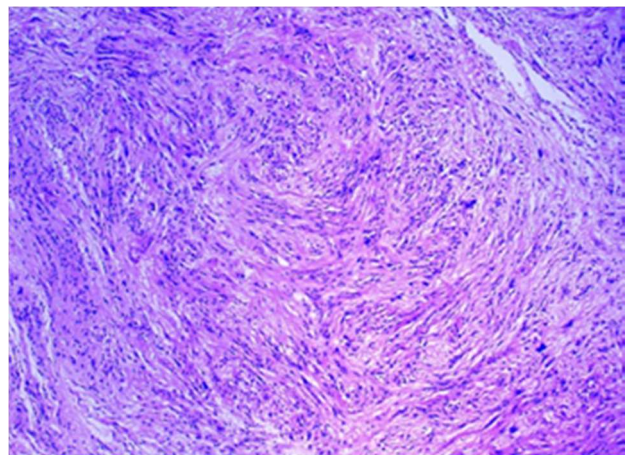
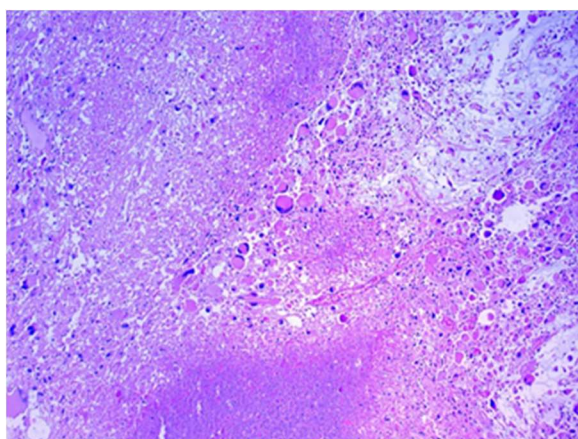


Figure 3. The tumor consistent of elongated cells with highly fibrillary processes, forming a fascicular architecture (H&E ×40). The tumor characterized by markedly elongated spindle shaped cells, which were immunopositive for S-100 protein and glial fibrillary acidic protein.

cm margin a dose of 50Gy was applied.

Three months after the RT, she came to routine follow-up. She had no complaint about her three other tumors although she had a mass on her right gluteal region. Physical examination revealed a 10 cm fixed irregular mass located on her right buttock. We inspected her previous planning tomography for spinal ependymoma however; there was no mass on her right gluteal region. MRI revealed a 15×10 cm mass on the right gluteal region. We performed position emission tomography (PET)-CT, and it demonstrated 10×15 cm heterogenous hypermetabolic mass with a standardized uptake (SUV) value of 43.81. The tumor excised from right gluteal area characterized by an extreme degree of pleomorphism with numerous typical and atypical mitotic figures and a fascicular growth pattern. Hemorrhage and necrosis were extensive in tumor. Immunohistochemically tumor cells were positive for Vimentin, but negative for CD45, AE1/AE3, SMA, S-100, Desmin and Myogenin. Histological and immunohistochemical findings indicated diagnosis of high grade sarcoma (figure 4). During the operation the tumor was disintegrated so the surgical margins could not be determined. We planned a dose of 66-70 Gy RT to the tumor bed, with 5 cm and 2 cm margins in craniocaudal radial directions respectively; however she could not tolerated the doses above 62 Gy.



**Figure 4.** Anaplastic tumor cells are arranged haphazardly in sheets and necrotic areas (H&E ×40). Immunohistochemically tumor cells were positive for Vimentin, but negative for CD45, AE1/AE3, SMA, S-100, Desmin and Myogenin.

We thought that she might have had a genetic syndrome which was associated with multiple primary tumors. Thus conventional cytogenetic analysis and FISH (fluorescence in situ hybridization) with P53 gene were done. Both cytogenetic analysis and FISH analyses showed a normal karyotype and p53 gene.

During follow-up the patient was admitted to the hospital with shortness of breath and severe cough. A contrast enhanced CT revealed multiple nodules in her lungs, which were identified as metastases. The patient was hospitalized. However; her dyspnea was progressively increased and 15 months after the completion of the last RT, the patient died of respiratory failure.

## DISCUSSION

Multiple primary tumors in a patient are extremely low conditions but have increase in frequency in recent decades. This may be due to the medical improvements in both diagnostic and therapeutic strategies, which eventually increase the overall survival time of the patents with multiple malignancies. On the other hand, as the age increased, the risk of developing a tumor increases as well. We report a patient who developed four different tumors: a meningioma, angiomyolipoma, tanycytic ependymoma and high grade sarcoma. To best of our knowledge, the present patient is the first case in the English literature, who presented with these four types of tumors.

In reviews of the literature with respect to the multiple primary malignancies, it is interesting that, the Japanese population seems to have higher likelihood of developing multiple malignancies. This may be due to longer life span, gene susceptibility or advancement in the field of the oncology. Table 1 summarizes the reported cases of four or more primary malignancies in the literature during 1981-2011 (6-27). Although the appearance of four and more primary tumors in one patient is not very common, should not be considered as such a rare event. As it is seen in the table, most of the cases were



reported from Japan. Moreover a case with six metachronous primary malignancies was recently reported by Takada and colleagues from Japan (6). As can be seen from the table 1, the case with four primary tumors same with our case has not been reported previously.

Li Fraumeni syndrome comprises of breast cancer, brain tumors, acute leukemia, soft tissue sarcomas, bone sarcomas, and adrenal cortical carcinoma. It is a rare autosomal dominant

hereditary disorder linked to germline mutations of p53 tumor suppressor gene. Although we analyzed constitution of karyotype beside p53 alterations we could not find any genetic changes in our case.

Multiple primary tumors occur more often in elderly patients, as the incidence of tumors increases with age. A family history of cancer and genetic predisposition to cancer may be associated with a risk of multiple neoplasms (7).

Table 1. The reported cases of four or more primary malignancies in the English literature during 1974-2011.

Malignancies						
Author	1 <sup>st</sup>	2 <sup>nd</sup>	3 <sup>rd</sup>	4 <sup>th</sup>	5 <sup>th</sup>	6 <sup>th</sup>
Kenyon GS <sup>8</sup>	Caecum	Uterus	Renal pelvis	Anus	Bladder	
Kenyon GS <sup>8</sup>	Caecum	Choroid Melanoma	Bowel	Colon	Pancreas	
Bjerium <sup>9</sup>	Rectum	Breast	Uterus	Colon		
Kobayashi T <sup>10</sup>	Uterus	Stomach	Breast	Brain		
Megighian D <sup>11</sup>	Parotid Gland	Tongue	Soft Palate	Larynx	Hypopharynx	
Hori N <sup>12</sup>	Bladder	Penis	Stomach	Lung		
Hori N <sup>12</sup>	Bladder	Lung	Buccal mucosa	Rectum		
Craig DM <sup>13</sup>	Mouth	Lung	Larynx	Tongue		
Oagawara K <sup>14</sup>	Breast	Breast	Lung	Brain	Thyroid	
Kiyo <sup>15</sup>	Stomach	MM	Bladder	Bladder		
Kuriara <sup>16</sup>	Breast	RCC	Thyroid	Colon		
Abe <sup>17</sup>	Stomach	Colon	Ureter	Rectum		
Melkert PW <sup>18</sup>	Skin	Vulva	Vagina	Anus	Cervix	
Brugier L <sup>19</sup>	Soft tissue tumor	Brain	Thyroid	Breast		
Murata <sup>20</sup>	Skin	Stomach	Colon	Larynx		
Bumpers HL <sup>7</sup>	Larynx	Lung	Breast	Colon		
Sakashita <sup>21</sup>	Stomach	Lip	Oral cavity	Oral cavity		
Potzsch <sup>22</sup>	Breast	Lung	RCC	Acute myelomonocytic leukemia		
Keshishian <sup>23</sup>	Oropharynx	Oesophagus	Lung	Oral cavity		
Nakayama <sup>24</sup>	Breast	Breast	Vater's papilla	Bladder		
Mussari case 1 <sup>25</sup>	Anus	Esophagus	Lung	Oral cavity		
Mussari case 2 <sup>25</sup>	Lung	Stomach	Rectum	Lung		
Mussari case 3 <sup>25</sup>	Oral cavity	Oropharynx	Esophagus	Melanoma		
Mussari case 4 <sup>25</sup>	Oral cavity	Larynx	NHL	Esophagus		
Mukai <sup>26</sup>	Stomach	Duodenum	Esophagus	RCC	Colon	
Hu NC <sup>2</sup>	Colon	MALT	Lung	Breast	HCC	
Takada K <sup>6</sup>	Lymphoma	Stomach	Ureter	Lung	Bladder	Lung
Sherriff JM <sup>27</sup>	Ovary	RCC	Melanoma	Breast		
Current study	Brain	Kidney	Spinal Cord	Soft Tissue Sarcoma		

HCC: Hepatocellular Carcinoma, RCC: Renal cell carcinoma, MALT: Mucosa associated lymphoid tissue, MM: Multiple myeloma, NHL: Non-Hodgkin's lymphoma.

The present case was 59 years old and there was no relevant family history. The patients described in the current report never used tobacco or alcohol. Additionally she did not receive any chemotherapy or radiotherapy for her first two tumors. There wasn't any predisposing factor to these four tumors.

Interestingly, her fourth tumor, high grade sarcoma, was developed up to 10 cm within three months of period. When she was receiving RT to her spinal region she was regularly followed-up in every week; however she did not have any mass on the gluteal region. Moreover when she admitted to the hospital three months after her spinal RT, we checked again her planning tomography scans and it was completely normal.

There was no predisposing factor, family history and genetic abnormality in the case we presented. We considered that the multiple primary tumors may not be associated with hereditary syndrome and risk factors including smoking, chemotherapy and radiotherapy. However patients with a diagnosis of either benign or malign tumor should be followed for the development of subsequent cancers.

**Conflict of interest:** Declared none

## REFERENCES

- Warren S and Gates O (1932) Multiple primary malignant tumors: a survey of the literature and statistical study. *American Journal of Cancer*, **16**: 1358–1403.
- Hu NC, Hsieh SC, Chen TJ et al. (2009) Multiple primary malignancies including colon, stomach, lung, breast, and liver cancer: a case report and literature review. *Chinese Medical Journal*, **122(24)**:3091–3093.
- Németh Z, Czigner J, Iván L et al (2002) Quadruple cancer, including triple cancers in the head and neck region. *Neoplasma*, **49**: 412–414.
- Berg JW and Foote FW (1997) The prevalence of latent cancers in cancer patients. *Arch Pathol*, **91**:183-186.
- Hajdu SI and Hajdu ED (1968) Multiple primary malignant tumors. *JAm Geriatr Soc*, **16**:16–26.
- Takada K, Matsumoto S, Kojima E et al. (2011) A case of six metachronous primary malignancies. *Gan To Kagaku Ryoho*, **38(4)**:697-700.
- Bumpers HL, Natesha RK, Barnwell SP et al. (1994) Multiple and distinct primary cancers: a case report. *J Natl Med Assoc*, **86**:387-388.
- Kenyon GS (1981) Multiple primary malignant neoplasms in three members of a family. *Journal of the Royal Society of Medicine*, **4**:601-604.
- Bjerrum OW, Gjedde S, Bendtzen K et al. (1984) Retinoblastoma: a shared chromosomal mechanism revealing multiple malignancy in an adult. *Tumori*, **70**: 575–7.
- Kobayashi T (1985) Diagnosis and treatment of multiple primary neoplasm—brain tumors and cancer of other organs. *Saishin Igaku*, **40** :1613-1620.
- Megighian D and Zorat PL (1985) A rarely observed case of primary multiple carcinomas of the head and neck. *Arch Otorhinolaryngol*, **242**:7-12.
- Hori N, Kinoshita N, Hoshina A et al. (1985) Two cases of triple primary neoplasm and two cases of quadruple primary neoplasm including bladder cancer. *Hinyokika Kyo*, **31(10)**:1807-11.
- Craig DM and Triedman LJ (1986) Four primary malignant neoplasms in a single patient. *J Surg Oncol*, **32**:8-10.
- Ogasawara K, Ogawa A, Shingai J et al. (1986) Synchronous multiple primary malignant tumors accompanied by glioblastoma. *Neurol Med Chir (Tokyo)*, **26**: 908-912.
- Hashimoto K, Oishi K, Ueda M et al. (1987) Quadruple cancers gastric adenocarcinoma, multiple myeloma, transitional cell carcinoma and leiomyosarcoma of the bladder. *Acta Urologica Japonica*, **33(12)**:2122-6.
- Kurihara T, Ishida T, Miyamoto YM et al. (1989) A case of quartet cancer—a carcinoma of the breast followed by three synchronous cancers (kidney, thyroid and colon). *Gan No Rinsho*, **35(8)**:955-62.
- AbeY, Nakada T, Kawamura S et al. (1991) A case of quadruple carcinoma with special reference to ureteral cancer. *Int Urol Nephrol*, **23**: 325–31.
- Melkert PW, Walboomers JM, Jiwa NM et al. (1992) Multiple HPV 16-related squamous cell carcinomas of the vulva, vagina, anus, skin and cervix in a 31-year-old woman. *Eur J Obstet Gynecol Reprod Biol*, **46**: 53-56.
- Brugieres L, Gardes M, Moutou C et al. (1993) Screening for germ line p53 mutations in children with malignant tumors and a family history of cancer. *Cancer Research*, **53**: 452-455.
- Murata K, Iwazawa T, Takayama T et al. (1994) Quadruple cancer including Bowen's disease after arsenic injections 40 years earlier: report of a case. *Surg Today*, **24**: 1115–8.
- Sakashita H, Miyata M et al. (1996) A case of quadruple cancer, including triple cancers in the head and neck region. *J Oral Maxillofac Surg*, **54**: 501–4.
- Potzsch C, Fetscher S, Mertelsmann R et al. (1997) Acute myelomonocytic leukemia secondary to synchronous carcinomas of the breast and lung, and to metachronous renal cell carcinoma. *J Cancer Res Clin Oncol*, **123**: 678-680.
- Keshishian A, Sarkar FH, Kucyj G et al. (1998) Four multiple primary malignant neoplasms of the aerodigestivetract. *Ann Thorac Surg*, **65**: 252–4.
- Nakayama H, Masuda H, Ugajin W et al. (1999) Quadruple cancer including bilateral breasts, Vater's papilla, Banfi A, and urinary bladder: a report of a case. *Surg Today*, **29**: 276–9.

**Yavas et al./ A novel case of quartet tumor**

25. Mussari S, Amichetti M, Tomio L (2000) Quadruple cancer in a single patient: a report of four cases. *Eur J Surg Oncol*, **26**: 614-616.
26. Mukai M, Macuuchi H, Mukohyama S et al. (2001) Quintuple carcinomas with metachronous triple cancer of the esophagus, kidney and colonic conduit following synchronous double cancer of the stomach and duodenum. *Oncol Rep*, **8**:111-114.
27. Sherriff MJ and Walji N (2011) Prolonged survival in a patient with multiple metachronous tumors. *J Clin Oncol*, **29** (7):154-155.