

Accuracy of the dose delivery in prostate cancer patients-using an electronic portal imaging device (EPID)

S.R. Mahdavi¹, E. Jazayeri Gharehbagh^{2*}, B. Mofid³, A.H. Jafari⁴,
A.R. Nikoofar⁵

¹Medical Physics Department of Iran University of Medical Sciences, Tehran, Iran

²Department of Radiology and Radiotherapy Technology, School of Allied Health Sciences, Tehran University of Medical Sciences, Tehran, Iran

³Radiotherapy Department of Shahid Beheshti University of Medical Sciences, Tehran, Iran

⁴Research Center of Biomedical Technology and Robotics, Tehran University of Medical Sciences, Tehran, Iran

⁵Radiotherapy Department of Iran University of medical Sciences, Tehran, Iran

ABSTRACT

Background: To correct patient positioning errors (setup errors) during prostate cancer treatment using EPID and fiducial gold markers, to improve the accuracy of the dose delivery in these patients. **Materials and Methods:** Fifteen patients with localized prostate carcinoma after implantation of fiducial gold markers in their prostate gland underwent the five-field IMRT planning technique. The plan was prepared in accordance with ICRU 50 guidance (PTV to receive 95-107% dose). The software program reconstructed the three-dimensional position of the markers from the different Beams Eye Views (BEV). The discrepancies of the seeds' positions (prostate surrogate) between plan and daily images were calculated three dimensionally. Then, necessary corrections were applied to match the prostate fiducial markers in the portal image with the BEV image in the planned one by moving the couch in the X, Y and Z directions. **Results:** Data from 15 patients and 469 fractions of radiotherapy were analyzed in this study. Two sets of data were available from EPID software before and after 3D set-up corrections. The mean of the population displacement in Left /Right (L/R), Anterior/Posterior (A/P) and Crania/Caudal (C/C) directions were 0.5, -1.0 and 2.4mm before, and -0.1, -0.5 and 0.9mm after corrections, respectively. The systematic and random errors for the measured populations in the three mentioned directions were 2.4, 2.7 and 2mm and 6.4, 5.9 and 6.1mm before corrections, and 1.1, 2.4 and 1.4mm and 3.8, 3.9 and 3.6mm after corrections, correspondingly. **Conclusion:** This study provides further evidence that using gold markers in the prostate improves dose delivery to the prostate. Also, it has been demonstrated that the EPID can be a powerful tool in the reduction of treatment setup errors and the quality assurance and verification of complex treatments.

Keywords: Prostate cancer, EPID, systematic errors, random errors.

INTRODUCTION

Over the last half century, the treatment of cancer by external beams of megavoltage x-ray radiation has benefited from a variety of significant technical advancements. Improvements in 3D treatment planning

software systems, the adoption of novel three-dimensional imaging modalities, and the development of a variety of hardware and software facilitate the delivery of ever more sophisticated treatment plans ⁽¹⁾.

The benefits of advanced treatment technology and 3D conformal radiation therapy

*Corresponding author:

Dr. Elahe Jazayeri Gharehbagh,

Fax: +98 21 88983037

E-mail: ejazayeri@sina.tums.ac.ir

Revised: March 2016

Accepted: April 2016

Int. J. Radiat. Res., January 2017;
15(1): 39-47

DOI: 10.18869/acadpub.ijrr.15.1.39

► Original article

(3D-CRT) can only be appreciated if the target and normal tissues are given the absorbed dose as prescribed in the treatment planning ⁽²⁾. The consequences of missing the target, even partially, are reduction in tumor control and an increase in normal tissue complication probabilities.

The tumor region is normally irradiated through different numbers of directions and gantry angles with a suitable radiation field or port. Verifying that each radiation port is being delivered as intended remains a difficult practical issue due to a number of complicating factors. For example, the size and shape of the tumor can change during the course of treatment. In addition, the position of the tumor in the patient may vary from treatment to treatment, or even during treatment due to breathing, the degree of extension of the bladder and changes in patient positioning. Moreover, errors in the set-up of the patient and/or of the beam collimators are also possible ⁽¹⁾. For these and also other reasons, an effective way to reduce setup error would be to increase the frequency of treatment verification with portal imaging ⁽³⁾.

Portal imaging is commonly used to check the position of the patient relative to the isocentre by using bony landmarks just before radiation therapy. This check is essential and necessary to verify the patient position before radiation therapy ⁽⁴⁾. However, a target volume such as the prostate is more likely to move independently of the bony landmarks, then, additional efforts are required to visualize the target's position ^(5, 6). One of the approaches to verify the prostate position could be implantation of fiducial gold markers into prostate. This method has been in clinical use since 1997⁽⁴⁾. Displacements of these markers can be monitored radiographically during the treatment course and the registered marker shifts act as a surrogate for prostate motion ⁽⁷⁾.

The data ⁽⁸⁾ show that while the prostatic tissue relative to bony pelvis does not move appreciably during treatment, it can move over 1.5 cm relative to the bones between fractions. Other pelvic setup studies show that setup errors exceeding 1 cm were not uncommon, and

that these intertreatment values exceed any intrafractional motion errors for the pelvis⁽⁹⁾.

In radiotherapy use of film cassettes represent many advantages and provide useful image information, but, they suffer from several major weaknesses. There is a gap of several minutes between exposing the film and obtaining information from it. In the case of localization imaging, this introduces a significant delay during which the information content of the film may become invalid (e.g. due to patient movement) ⁽¹⁾. In addition, Significant setup and treatment delivery errors have been reported in film-based portal imaging studies ^(5, 10).

In contrast, the electronic portal imaging device (EPID) provides a more efficient and effective method for determining radiation field placement accuracy. The digital nature of the EPID provides quantitative tools for population-based or individual patient systematic and random error analysis ⁽²⁾.

EPID use for patient setup verification and correction can be separated into two general categories, on-line or intrafractional and off-line or interfractional. On-line correction protocol allows the reduction of total setup errors for each individual patient, but cannot differentiate between systematic and random components ⁽¹¹⁻¹³⁾. The example of off-line correction is the weekly port film, when the image is examined after treatment, and if necessary, a correction is made at the following treatment session ⁽²⁾.

In advanced treatment techniques, such as Intensity Modulated Radiotherapy (IMRT), the delivered dose distribution can often be shaped more closely to the tumor volume compared with conventional radiotherapy especially for concave shaped targets ^(14, 15). For reliable application of this technique, which is often combined with high tumor doses, a patient-specific quality control program is currently being developed in Pars Hospital radiotherapy center. It is mainly based on measurements with Electronic Portal Imaging Devices (EPIDs) for the verification of the patient positioning and the dose delivery before and during the actual patient treatment.

Monitoring studies demonstrate the power of EPID technology to acquire sufficient image data

during treatment to benefit the individual patient. Analysis of these data allows assessment of institutional technique and patient specific errors that cannot be obtained with film ⁽²⁾. Due to the smaller amount of time needed to image with an EPID, EPID is a more accurate reflection of patient setup error than film ⁽¹⁶⁾. EPID imaging allows multiple images on every fraction, with suitable resolution to visualize radio opaque markers in prostate tissue.

In this study, we aimed to correct patient positioning errors (setup errors) during prostate cancer treatment using EPID and fiducial gold markers to improve the accuracy of the dose delivery and the effectiveness of marker-based position verification of the prostate during external-beam radiotherapy in these patients.

This work was performed for the first time by using an electronic portal imaging device (EPID) and implanted gold markers in our country (Iran).

MATERIALS AND METHODS

Fifteen patients with localized prostate carcinoma (T1c-T3bN0M0) provided written informed consent to participate in a prospective

study that was approved by Iran Medical University Research Ethics Committee. Fifteen sets of three gold seeds (diameter = 0.7 mm, length = 3-5 mm) were provided by CIVCo and Alpha-Omega Services Inc. as the fiducial marker for implantation within the prostate gland. The use of gold seeds to act as a surrogate for prostate position during treatment has been widely documented ⁽¹⁷⁾.

The age of the patients ranged from 57 to 80 years (the mean being 69 years), initial prostate-specific antigen was in the range 5.9-16.4 ng/ml (mean 10.6 ng/ml) with Gleason scores of 6 to 8. All patients received neoadjuvant hormonal therapy. Table 1 shows the demographic characteristics of the patients.

A commercially available software system [Theraview classic 5.1, Cablon Medical B.V. (Leusden; Netherland)] was used in combination with implanted fiducial markers within the prostate gland and standard portal imaging equipment. This software system quantifies the differences between the Digitally Reconstructed Radiographs (DRR) (as a reference image) and actual daily positions of the intraprostatic markers reporting the couch translational movements required to re-align the patient in X, Y, Z directions.

Table 1. Demographic characteristics of patients.

Patient	Age	BMI	Gleason scores	PSA (ng/ml)	T staging
1	70	26.2	6	4.64	T1cN0
2	70	26.2	7	5.9	T2bN0
3	57	23.4	6	16.4	T3bN0
4	69	23.4	7-8	12.25	T3bN0
5	75	35.2	6	9.36	T2bN1
6	69	29.4	6	12	T2aN0
7	65	24.5	6	11.03	T2cN0
8	78	23.4	8	11.9	T2bN0
9	80	24.5	6	14	T2cN0
10	62	32	6	7.6	T2aN0
11	66	29.4	7	16.2	T2cN0
12	68	26.2	7	4.6	T1cN0
13	73	30.7	6	10.98	T2bN0
14	68	18.3	6	13	T2aN0
15	72	30.7	6	8.42	T2bN0

The three fiducial gold markers were inserted by the interventional radiologist under local anesthetic and transrectal ultrasound guidance. The aim was to implant two seeds at the base, and one at the apex of the prostate.

Computed Tomography (CT) scanning was carried out for planning 5-7 days after the gold seed insertion to allow any periprostatic edema to settle. The patients were asked to comply with the standard department protocol of having a comfortable full bladder for simulation and before each treatment. For bowel preparation, the protocol was having a light dinner on the night before simulation and also during each treatment, and if possible, to empty the bowel. Patients were positioned supine without any fixation device on the simulation CT couch; skin tattoos over bony landmarks were used as the external reference points for aligning the treatment fields. Axial images were obtained with a 16-slice helical CT scanner [Siemens Company (Berlin; Germany)] with 5mm slice thickness and 2mm reconstruction protocol from the midpoint of the sacroiliac joints to 2cm inferior of the pubic rami. The prostate as CTV, bladder and rectum (ischial tuberosities to the rectosigmoid flexure) were outlined on each axial image using the TIGRT LinaTech Treatment Planning System (TPS) (Sunnyvale; USA).

In our experiment, we used a five-field IMRT inverse planning technique. The plan was prepared in accordance with ICRU 50 guidance (PTV to receive 95-107% dose). The monitor units from the daily pre-treatment localization portal images were included as a component of the delivered dose. DRR of each field was generated. Thirteen patients were treated to with a dose of 80Gy in 40 fractions and two patients received 78Gy in 39 fractions using a two-phase technique with CTV to PTV margins of 10mm on each side except 7mm posteriorly. First phase 28 fractions with 200 cGy per fractions to treat prostate and seminal vesicle and second phase 11-12 fractions for treating prostate only or prostate plus 1cm of seminal vesicle depending to the clinical staging as a subsequent boost⁽⁷⁾.

In our center, an Electronic Portal Imaging

Devices (EPID) consisting of a fluorescent screen, a front-surface mirror, a Peltier-cell Cooled Charged-coupled Device (CCD) camera and a computer with a frame grabber is used. X-rays that are transmitted through an absorber (patient or phantom) and hit the detector screen generate visible light in the fluorescent layer that is viewed by the CCD camera.

In each fraction, portal images at two nearly orthogonal angles (with 5 monitor units each) were acquired. The DRRs of the planned field positions were used to assist identification of the seed positions on the portal images. For each beam direction, these Electronic Portal Images (EPIs) are compared with related DRRs that were derived from the planning CT scan of the patient. The discrepancies of the seeds positions (prostate surrogate) between images were calculated three dimensionally. Then, necessary corrections were applied with the translational couch movements to reposition the isocentre to that planned (the online protocol setup correction strategy). The markers were visualized by means of the Theraview portal imaging software and its marker enhancement option.

Displacement data was automatically recorded within the Theraview software. The action level used for this study was 3mm. Figure 1 shows the DRR and portal images as well as gold markers in the BEV at 15° gantry angle.

The systematic (Σ) and random errors (σ) of each patient and group of patients for set-up and organ motions were calculated as below (equations 1-4 respectively)⁽¹³⁾.

$$m_{\text{individual}} = \frac{\Delta_1 + \Delta_2 + \Delta_3 + \dots + \Delta_n}{n} \quad (1)$$

$$\sigma_{\text{individual}}^2 = \frac{(\Delta_1 - m)^2 + (\Delta_2 - m)^2 + (\Delta_3 - m)^2 + \dots + (\Delta_n - m)^2}{(n - 1)} \quad (2)$$

$$\Sigma_{\text{set-up}}^2 = \frac{(m_1 - M_{\text{pop}})^2 + (m_2 - M_{\text{pop}})^2 + (m_3 - M_{\text{pop}})^2 + \dots + (m_n - M_{\text{pop}})^2}{(p - 1)} \quad (3)$$

$$\sigma_{\text{set-up}} = \frac{\sigma_1 + \sigma_2 + \sigma_3 + \dots + \sigma_p}{p} \quad (4)$$

Descriptive statistics [mean and standard deviation (SD)] and EXCEL office 10 software were used for describing the inter-fractional motion observed in individual patients.

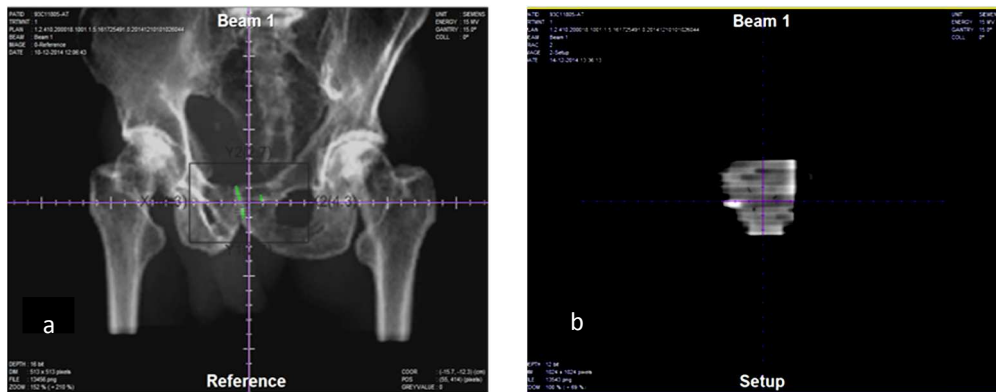


Figure 1. An IMRT field image shows (a) the related DRR and BEV (reference), and (b) the portal image of prostate with implanted gold markers at 15⁰ BEV.

RESULTS

Data from 15 patients and 469 fractions of radiotherapy (average of 32 measurements for each patient) were analyzed in this study. Two sets of data were available from EPID software

before and after 3D set-up corrections.

Figure 2 typically shows variations of setup errors for Left/Right (L/R), Anterior/Posterior (A/P) and Crania/Caudal (C/C) directions for one of the patients in 37 fractions.

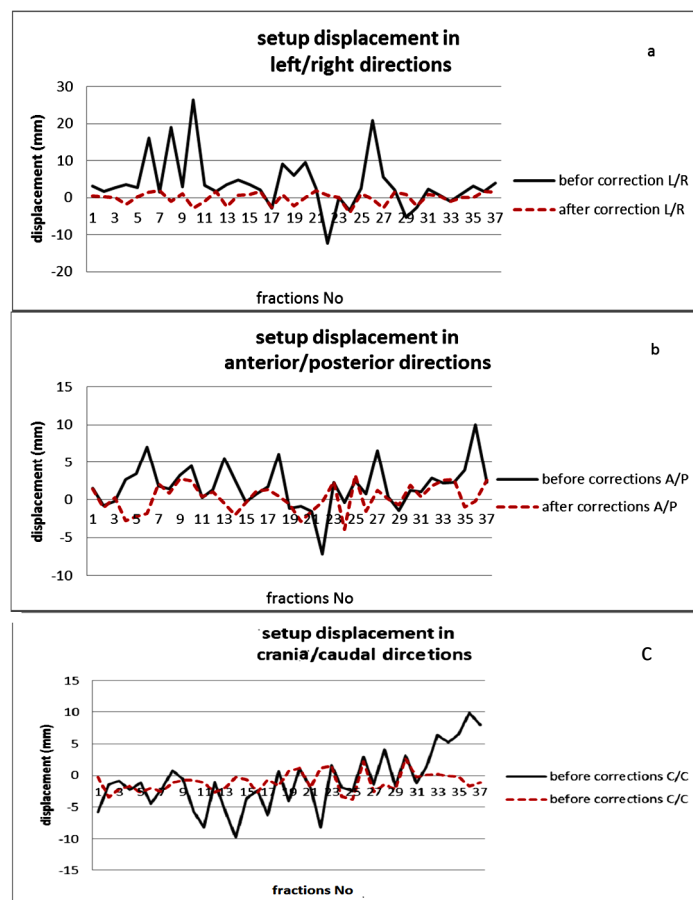


Figure 2. The setup displacement for one of the patients in 37 fractions before and after corrections in a; Left/Right (L/R), b; Anterior/Posterior (A/P), and c; Crania/Caudal (C/C) directions.

Figure 3 shows the mean of the prostate setup displacement in 3 mentioned directions for each one of 15 patients over all fractions; (a) before and (b) after corrections.

The SD of translational displacement in the study population in each of the three axes (left/right, crania/caudal and anterior/posterior) before and after corrections for overall fractions is shown in figure 4.

The population means, systematic and random displacements before and after corrections are shown in table 2.

DISCUSSION

In our study, we observed a translation motion mainly in the anterior-posterior and crania/caudal directions of prostate and seminal vesicles 9.7 and 6.8mm respectively before

setup corrections, which were reduced to 6.7 and 4.2mm respectively after repositioning the patients. This may be related to both of the rectal and bladder fillings which displace the prostate over the course of treatment ⁽⁷⁾. In addition, respiration and peristaltic motion which have a time scale that is shorter than the delivery time of a single fraction ⁽¹⁹⁾ could change the prostate position during the fraction.

Studies have shown that the greatest prostate motion is noted in the anterior-posterior and crania/caudal directions with a range of 3.6-5.9mm \pm 4.1mm ^(8, 20). Furthermore, increasing rectal volume/diameter on the planning CT scan has been significantly correlated with the mobility of the prostate and the seminal vesicles ^(21, 22). Our results are in good agreement with findings of other authors ^(7, 19, 23-25).

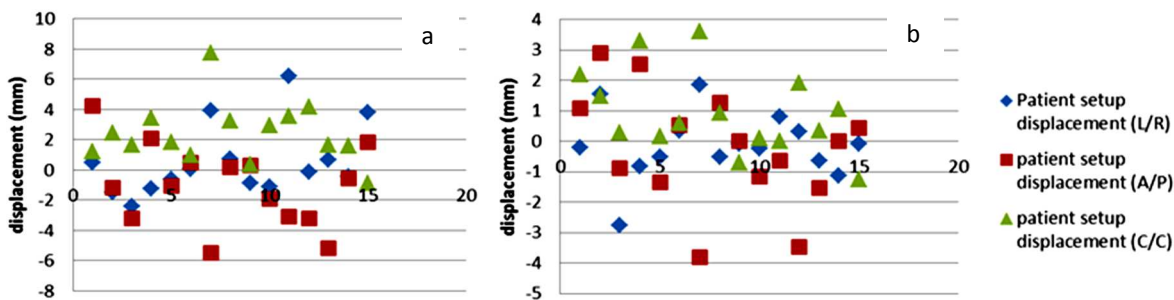


Figure 3. The mean of the prostate setup displacement in 3 directions for each one of 15 patients over all fractions; (a) before and (b) after corrections.

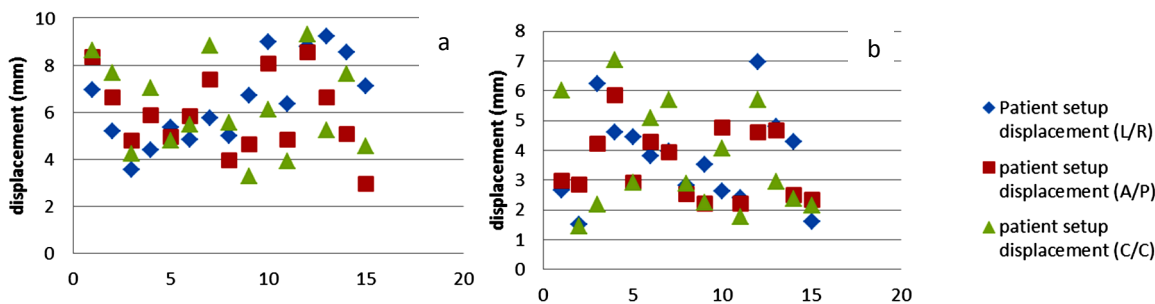


Figure 4. The SD of the study population (15 patients) in Left/Right, Anterior/Posterior and Crania/Caudal directions before and after corrections for overall fractions.

Table 2. The population means, systematic and random displacement before and after corrections in Left/Right, Anterior/Posterior and Crania/Caudal directions/

	mean			systematic			random		
	L/R	A/P	C/C	L/R	A/P	C/C	L/R	A/P	C/C
before correction	0.5	-1.0	2.4	2.4	2.7	2.0	6.4	5.9	6.1
after correction	-0.1	-0.5	0.9	1.1	2.4	1.4	3.8	3.9	3.6

Our finding showed, the overall mean of study population were 0.5,-1.0 and 2.4mm before correction and -0.1,-0.5 and 0.9mm after correction in L/R, A/P and C/C directions respectively. Actually, the mean of the population displacement should be very small. However, the calculation of the mean and SD of the movement of each patient often showed deviation from zero which could be due to inaccuracy in the equipment (lasers), procedure⁽¹⁹⁾ and specially involuntary movement in the elderly patients. Also, displacement after setup corrections could be due to relaxing of the pelvis muscles, so that the bony anatomy as well as the prostate moves in the dorsal direction relative to the skin markers. This would also be shown in a shift of the bony anatomy relative to the skin markers. Indeed, such translations of the bony anatomy were observed in a positioning study of 151 prostate patients^(26, 27).

In this study, the systematic errors calculated from the interfractional translational data are similar to those reported by Litzenberg, et.al (2.8 to 5.0 mm left-right, 1.9 to 3.0 mm anterior-posterior, and 2.6 to 5.3 mm superior- inferior)⁽²⁸⁾, but the random errors were greater⁽²⁶⁾. The latter could be due to the longer time durations that it took to enter the treatment room and correct the couch position. Ideally, the time taken between online verification and treatment should be as short as possible (a minute), in order to reduce the variation that may occur from patient movement during this time.

As seen in this study and other studies^(18, 21, 26) sufficient planning target margin expansion is necessary to reduce the possibility of a geometric miss because of organ motion, such as changes in rectal volume/distension. Investigators have attempted to derive a generic margin of 10 mm from each side except the posterior where the margin is 7mm to provide adequate coverage of CTV by the 95% isodose from the observation of prostate and seminal vesicle motion in a population average⁽²¹⁾. However, a target margin greater than 10 mm was recommended in the anterior/posterior and crania/caudal directions respectively, to ensure adequate coverage of CTV⁽²¹⁾. The margin on the

posterior border of the target has been reduced deliberately to minimize potential rectal morbidity. Nevertheless, limitation of this approach is that a subgroup of patients with large systematic variation due to large rectal volume in the planning CT scan will suffer the potential risk of target geometric miss^(29, 30).

Various investigators have recommended a generic isotropic expansion of at least 5 mm (based on population average), independent of imaging modality^(31, 32).

Despite the fact that CTV expansion can be reduced with image guidance, daily imaging with implanted markers, additional planning consideration may still be required in patients with rectal distension⁽³³⁾.

CONCLUSIONS

It has been demonstrated that the EPID can be a powerful tool in the reduction of treatment setup errors and the dose delivery during a course of radiation treatment, and the quality assurance and verification of complex treatments. EPID-based, on-line adaptive radiotherapy allows for the correction of patient-specific, inter-fractional, prostate position secondary to internal organ motion and deformation. The incorporation of IGRT into prostate cancer treatment appears to reduce the risk of geometric miss and CTV-PTV margin redaction.

We found that the accuracy measured justifies reduced margins for daily prostate treatment, leading to a potential reduction in dose to the rectal wall. We have reduced the prostate margins with gold markers to 5 mm toward rectum⁽⁷⁾.

ACKNOWLEDGEMENTS

We are thankful to Saman Tabesh Co. for providing us with fiducial gold markers and staff of the Radiotherapy Department of Pars Hospital. This study was granted by Iran University of Medical Sciences, Tehran.

Conflict of interest: Declared none.

REFERENCES

- Antonuk LE (2002) Electronic portal imaging devices: a review and historical perspective of contemporary technologies and research. *Physics in Medicine and Biology*, **47** (6): R31.
- Herman MG, Kruse JJ, Hagness CR (2000) Guide to clinical use of electronic portal imaging. *Journal of Applied Clinical Medical Physics*, **1**(2):38-57.
- Marks J, Haus A, Sutton H, Griem M (1976) The value of frequent treatment verification films in reducing localization error in the irradiation of complex fields. *Cancer*, **37** (6):2755-61.
- Pouliot J, Aubin M, Langen KM, Liu Y-M, Pickett B, Shinohara K, et al. (2003) (Non)-migration of radiopaque markers used for on-line localization of the prostate with an electronic portal imaging device. *International Journal of Radiation Oncology* Biology* Physics*, **56**(3):862-6.
- Balter JM, Sandler HM, Lam K, Bree RL, Lichter AS, Ten Haken RK (1995) Measurement of prostate movement over the course of routine radiotherapy using implanted markers. *International Journal of Radiation Oncology* Biology* Physics*, **31**(1): 113-8.
- Langen K and Jones D (2001) Organ motion and its management. *International Journal of Radiation Oncology* Biology* Physics*, **50**(1):265-78.
- Sorcini B and Tilikidis A (2006) Clinical application of image-guided radiotherapy, IGRT (on the Varian OBI platform). *Cancer/Radiothérapie*, **10**(5):252-7.
- Vigneault E, Pouliot J, Laverdière J, Roy J, Dorion M (1997) Electronic portal imaging device detection of radiopaque markers for the evaluation of prostate position during megavoltage irradiation: a clinical study. *International Journal of Radiation Oncology* Biology* Physics*, **37**(1): 205-12.
- Tinger A, Michalski JM, Bosch WR, Valicenti RK, Low DA, Myerson RJ (1996) An analysis of intratreatment and inter-treatment displacements in pelvic radiotherapy using electronic portal imaging. *International Journal of Radiation Oncology* Biology* Physics*, **34**(3): 683-90.
- Huddart RA, Nahum A, Neal A, McLean M, Dearnaley DP, Law M, et al. (1996) Accuracy of pelvic radiotherapy: prospective analysis of 90 patients in a randomised trial of blocked versus standard radiotherapy. *Radiotherapy and oncology*, **39**(1):19-29.
- Herman MG, Abrams RA, Mayer RR (1994) Clinical use of on-line portal imaging for daily patient treatment verification. *International Journal of Radiation Oncology* Biology* Physics*, **28**(4):1017-23.
- Gildersleve J, Dearnaley D, Evans P, Swindell W (1995) Reproducibility of patient positioning during routine radiotherapy, as assessed by an integrated megavoltage imaging system. *Radiotherapy and Oncology*, **35**(2):151-60.
- Hoskin PJ (2008) On target: ensuring geometric accuracy in radiotherapy: Royal College of Radiologists; 2008.
- Portelance L, Chao K, Grigsby PW, Bennet H, Low D (2001) Intensity-modulated radiation therapy (IMRT) reduces small bowel, rectum, and bladder doses in patients with cervical cancer receiving pelvic and para-aortic irradiation. *International Journal of Radiation Oncology* Biology* Physics*, **51**(1):261-6.
- Teh BS, Woo SY, Mai W-y, McGary JE, Carpenter LS, Lu HH, et al. (2002) Clinical experience with intensity-modulated radiation therapy (IMRT) for prostate cancer with the use of rectal balloon for prostate immobilization. *Medical Dosimetry*, **27**(2):105-13.
- Hunt MA, Schultheiss TE, Desobry GE, Hakki M, Hanks GE (1995) An evaluation of setup uncertainties for patients treated to pelvic sites. *International Journal of Radiation Oncology* Biology* Physics*, **32**(1):227-33.
- Rimmer Y, Burnet N, Routsis D, Twyman N, Hoole A, Treeby J, et al. (2008) Practical issues in the implementation of image-guided radiotherapy for the treatment of prostate cancer within a UK department. *Clinical Oncology*, **20** (1):22-30.
- Van Herk M (2004) editor Errors and margins in radiotherapy. Seminars in radiation oncology; 2004: Elsevier.
- Crook J, Raymond Y, Salhani D, Yang H, Esche B (1995) Prostate motion during standard radiotherapy as assessed by fiducial markers. *Radiotherapy and oncology*, **37**(1):35-42.
- Antolak JA, Rosen II, Childress CH, Zagars GK, Pollack A (1998) Prostate target volume variations during a course of radiotherapy. *International Journal of Radiation Oncology* Biology* Physics*, **42**(3): 661-72.
- Beard CJ, Kijewski P, Bussi re M, Gelman R, Gladstone D, Shaffer K, et al. (1996) Analysis of prostate and seminal vesicle motion: implications for treatment planning. *International Journal of Radiation Oncology* Biology* Physics*, **34**(2):451-8.
- van Herk M, Bruce A, Guus Kroes A, Shouman T, Touw A, Lebesque JV (1995) Quantification of organ motion during conformal radiotherapy of the prostate by three dimensional image registration. *International Journal of Radiation Oncology* Biology* Physics*, **33**(5):1311-20.
- Melian E, Mageras GS, Fuks Z, Leibel SA, Niehaus A, Helen L, et al. (1997) Variation in prostate position quantitation and implications for three-dimensional conformal treatment planning. *International Journal of Radiation Oncology* Biology* Physics*, **38**(1): 73-81.
- Stroom JC, Koper P, Korevaar GA, van Os M, Janssen M, de Boer HC, et al. (1999) Internal organ motion in prostate cancer patients treated in prone and supine treatment position. *Radiotherapy and oncology*, **51**(3): 237-48.
- van der Heide UA, Kotte AN, Dehnad H, Hofman P, Lagendijk JJ, van Vulpen M (2007) Analysis of fiducial marker-based position verification in the external beam radiotherapy of patients with prostate cancer. *Radiotherapy and oncology*, **82**(1):38-45.
- Bel A, Vos PH, Rodrigues PT, Creutzberg CL, Visser AG,

- Stroom JC, et al. (1996) High-precision prostate cancer irradiation by clinical application of an offline patient set-up verification procedure, using portal imaging. *International Journal of Radiation Oncology* Biology* Physics*, **35(2)**: 321-32.
27. Litzenberg D, Dawson LA, Sandler H, Sanda MG, McShan DL, Ten Haken RK, et al. (2002) Daily prostate targeting using implanted radiopaque markers. *International Journal of Radiation Oncology* Biology* Physics*, **52(3)**: 699-703.
28. van Herk M, Remeijer P, Rasch C, Lebesque JV (2000) The probability of correct target dosage: dose-population histograms for deriving treatment margins in radiotherapy. *International Journal of Radiation Oncology* Biology* Physics*, **47(4)**:1121-35.
29. de Crevoisier R, Tucker SL, Dong L, Mohan R, Cheung R, Cox JD, et al. (2005) Increased risk of biochemical and local failure in patients with distended rectum on the planning CT for prostate cancer radiotherapy. *International Journal of Radiation Oncology* Biology* Physics*, **62(4)**: 965-73.
30. Park SS, Yan D, McGrath S, Dilworth JT, Liang J, Ye H, et al. (2012) Adaptive image-guided radiotherapy (IGRT) eliminates the risk of biochemical failure caused by the bias of rectal distension in prostate cancer treatment planning: clinical evidence. *International Journal of Radiation Oncology* Biology* Physics*, **83(3)**:947-52.
31. O'Daniel JC, Dong L, Zhang L, de Crevoisier R, Wang H, Lee AK, et al. (2006) Dosimetric comparison of four target alignment methods for prostate cancer radiotherapy. *International Journal of Radiation Oncology* Biology* Physics*, **66(3)**: 883-91.
32. Lattanzi J, McNeeley S, Pinover W, Horwitz E, Das I, Schultheiss TE, et al. (1999) A comparison of daily CT localization to a daily ultrasound-based system in prostate cancer. *International Journal of Radiation Oncology* Biology* Physics*, **43(4)**:719-25.
33. Engels B, Soete G, Verellen D, Storme G (2009) Conformal Arc radiotherapy for prostate cancer: increased biochemical failure in patients with distended rectum on the planning computed tomogram despite image guidance by implanted markers. *International Journal of Radiation Oncology* Biology* Physics*, **74(2)**:388-91.

