

The effects of zinc in the gastrointestinal system as a radioprotective agent

A. Akbulut*, M. Sadic¹, N. Yumusak², F.N. Aydinbelge¹, G. Koca¹,
M. Korkmaz¹

¹Department of Nuclear Medicine, University of Health Sciences, Ankara Training and Research Hospital, Ankara, Turkey

²Department of Pathology, Harran University Faculty of Veterinary Medicine, Sanliurfa, Turkey

ABSTRACT

► Original article

*Corresponding authors:

Dr. A. Akbulut,

Fax: +90 312 595 3611

E-mail:

aylinbaskin@gmail.com

Revised: December 2017

Accepted: January 2018

Int. J. Radiat. Res., July 2018;
16(3): 333-339

DOI: 10.18869/acadpub.ijrr.16.3.333

Background: Radioiodine I131 therapy (RAI) is an efficient method to decrease the functioning of very active thyroid tissues and to ablate the remnant thyroidal tissue after surgery and its metastases in differentiated thyroid carcinomas. Several cytoprotective, anti-oxidant or radioprotective mediators have been used in trials for RAI-induced damage in other organ systems. The hypothesis of this study was that zinc would ameliorate RAI-induced histopathological parameters in the rat gastrointestinal system. **Materials and Methods:** A total of 30 female Wistar albino rats were separated into 3 groups of 10. First group received only 0.003 mCi/g of I131, second group received 0.003 mCi/g of I131 and 0.01 mg/g of zinc and the control group (Sham Group) were given neither I131 nor zinc. Zinc was started via gastric gavage two days before I131 administration and continued for five days after RAI. At 24 hours after the last dosage of zinc, all the animals were sacrificed and the gastrointestinal tissues, including stomach, duodenum, ileum and colon were removed for histopathological examination. **Results:** All the histopathological parameters were diminished in the I131-zinc group compared to the I131 group. The histopathological differences were statistically significant in respect of inflammation and fibrosis between the I131-zinc group and the I131 group in all the evaluated gastrointestinal organs ($p < 0.05$). **Conclusion:** The co-administration of zinc was observed to significantly prevent RAI-induced histopathological alterations in rats.

Keywords: Radioiodine, radioprotective agent, zinc, gastrointestinal system.

INTRODUCTION

Radioiodine I131 therapy (RAI) is a commonly used treatment method for hyperthyroidism, differentiated thyroid carcinoma remnants and their metastases. Absorption of I131 is almost exclusively through thyroid tissue, however the areas of highest radiation exposure between non-thyroidal tissues are the bladder followed by the stomach (1, 2). The intrinsic plasma membrane protein, known as sodium iodide symporter (NIS), mediates the active transport of I131 into the thyroid gland and salivary glands, lactating breast and gastric mucosa (3). The exact

mechanism of RAI-induced cell damage is thought to involve through NIS (4).

The most common acute side effects of RAI are gastrointestinal tract symptoms such as gastralgia, nausea, vomiting, diarrhea, stomatitis and/or ulcers, which can be present in 30.4-67.5% of patients. After high-dose RAI, the side effects usually occur within 48 h but can start as early as 2 h, and last for up to 96 hours (5). In addition, RAI adverse effects in cancers such as secondary solid tumors including those of the stomach and colon have been reported (6, 7, 8).

To decrease the toxicity of RAI, several anti-oxidant agents are under evaluation to

reduce these changes ⁽⁹⁻¹¹⁾. In many studies, various cytoprotective, anti-oxidant or radioprotective agents, such as vitamin E, vitamin C, glutathione, dexmedetomidine, melatonin, and beta-carotene, have been suggested as adjuvant treatments, as these are principally non-enzymatic antioxidants which may delay and prevent ionizing radiation damage ⁽¹²⁻¹⁴⁾.

Zinc is an essential metal for many different physiological functions such as cell membrane integrity. It is crucial for hydrochloric acid production with beneficial effects on the gastrointestinal mucosa and it has cytoprotective effects in gastric ulcer healing ^(15, 16). In addition to cytoprotective effects, the anti-oxidant and anti-inflammatory effects of zinc ⁽¹⁷⁾, and powerful mitochondria-specific radioprotection effects have been demonstrated in a previous experimental animal cell culture study ⁽¹⁸⁾.

Zinc action on gastrointestinal epithelial tight junctions and epithelial barrier function, have figured prominently in its potential therapeutic action in several gastrointestinal diseases ⁽¹⁹⁾ such as in acute and persistent diarrhea in children ⁽²⁰⁾ and in lowering the grade of oropharyngeal mucositis in patients with head and neck cancer ⁽²¹⁾.

Zinc pretreatment before irradiation has been shown to increase metallothionein levels in animal lymphocytes, which acts as a scavenger on radiation-induced peroxides, inducing defensive mechanisms for the induction of the cytogenetic adaptive response to ionizing radiation ⁽²²⁾. Furthermore, the radioprotective effects of zinc on rat red blood cells ⁽²³⁾, salivary glands ⁽²⁴⁾, spermatogonia and tetraploid cells ⁽²⁵⁾, bone marrow cells ⁽²⁶⁾, bone marrow recovery after irradiation ⁽²⁷⁾ and radioprotection against the lethal effects of radiation ⁽²⁸⁾ in mice have been reported in previous research. Similarly, in a study group of patients undergoing pelvic radiotherapy, the results showed a lower incidence of diarrhea, with zinc and a combination of prebiotics, probiotics and vitamins, suggesting that this could be used for the prevention and reduction of radiation-related gastrointestinal disorders

⁽²⁹⁾.

However, to the best of our knowledge, there has been no previous evaluation of the radioprotective value of zinc in the rat gastrointestinal system. On the basis of the promising results, of previous studies, the aim of this study was to assess the early radioprotective effect of zinc after high-dose RAI in the rat gastrointestinal system.

MATERIALS AND METHODS

The study included a total of 30 Wistar female albino rats, aged 3-5 months old, each weighing 200-250g. The animals were housed under standard laboratory conditions, at 21°C ± 2°C room temperature and 65%-70% relative humidity with a 12-hour light-dark cycle. The rats were fed with standard chow and water ad libitum and housed in polypropylene cages using disposable absorbent cloths under sterile paddy husks to avoid contamination from radioactive urine. The rats were randomly assigned into 3 groups, each group containing ten animals. The first group was given only a single dose of 0.003 mCi/g I131 (mon-Iyot 131 Eczacıbaşı-Monrol Kocaeli, Turkey) via gastric gavage. The I131 dose was extrapolated from the human dose for differentiated thyroid carcinoma that could be used for RAI in clinical trials. The second group animals were given a single dose of 0.003 mCi/g I131 plus zinc sulphate monohydrate 0.01 mg/g/day (Zinco®, Berko, Istanbul, Turkey) via gastric gavage. The zinc administration was started two days before the administration of RAI and was continued for five days after RAI. The third group was the Sham-operated control group without any medication. At 24 hours after the final administration of zinc, the animals were sacrificed by anesthesia with 50 mg/kg intraperitoneal propofol (Propofol®, Abbott Laboratory, Istanbul, Turkey). All animal experiments were conducted adhering to the Guide for the Care and Use of Laboratory Animals of the National Institute of Health guidelines and were approved by the Animal Care and Use Committee of the University of Health Sciences, Ankara Training and Research

Hospital.

RESULTS

Histopathological analysis

The stomach, duodenum, ileum and colon were removed and were fixed in 10% neutral buffered formalin (pH 7.2-7.4) and prepared for 4- μ m-thick paraffin sections, stained with Haematoxylin-Eosin. The histopathological examinations were applied using light microscopy (Olympus BX-50, Tokyo, Japan) at 40 to 400-fold magnification by an experienced veterinary pathologist, blinded to the rat groups. The histopathological sections were evaluated for oedema in the lamina propria, ulceration, mucosal erosion, mucosal degeneration, necrosis, inflammation and fibrosis and these evaluations were marked as present or absent.

Data analysis

Data analysis was performed using Statistical Package for Social Sciences for Windows software (SPSS version 20.0, SPSS Inc. Chicago, USA). Differences between the I131 group and the I131-zinc group were analyzed using the Chi square test or Fisher's exact test. A value of $p < 0.05$ was accepted as statistically significant.

In the histopathological examination, no change was observed in the gastrointestinal system of the control group subjects. Taking this into account, the statistical analyses were performed between the I131 administered groups.

In both I131 group and I131-zinc group, similar RAI dose-related histopathological changes were observed in the gastrointestinal tract tissues as marked lamina propria oedema, ulceration, mucosal erosion, mucosal degeneration, necrosis, inflammation and fibrosis. A rat gastrointestinal system from I131 group is presented in figure 1 and another rat from I131- zinc given group is shown in figure 2, showing the acute histopathological abnormalities after RAI.

The histopathological parameters detected in each group of rats are shown in table 1. All the histopathological parameters were less frequently observed at a lower rate in the I131- zinc group compared to the I131 group.

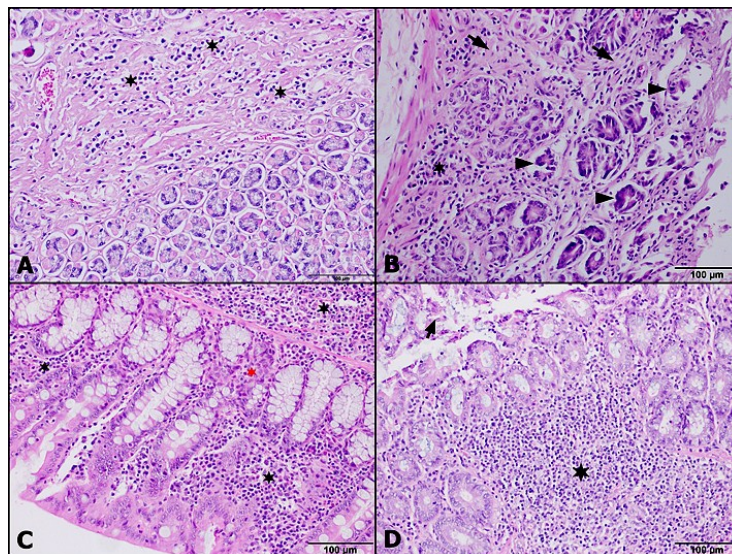


Figure 1. Representative photomicrographs of the gastrointestinal system showing the acute effects of RAI on gastrointestinal tissues in the I131 group are presented with (A) severe inflammation and massive necrosis (black stars) in the stomach; (B) severe inflammation (black stars), diffuse fibrosis (arrows) and necrotic glands (black arrowhead) in the duodenum; (C) severe inflammation (black stars) and massive necrosis (red star) in the ileum; and (D) severe inflammation (black stars) and massive necrosis (arrow) in the colon (Haematoxylin and Eosin, A, B, C and D; x400).

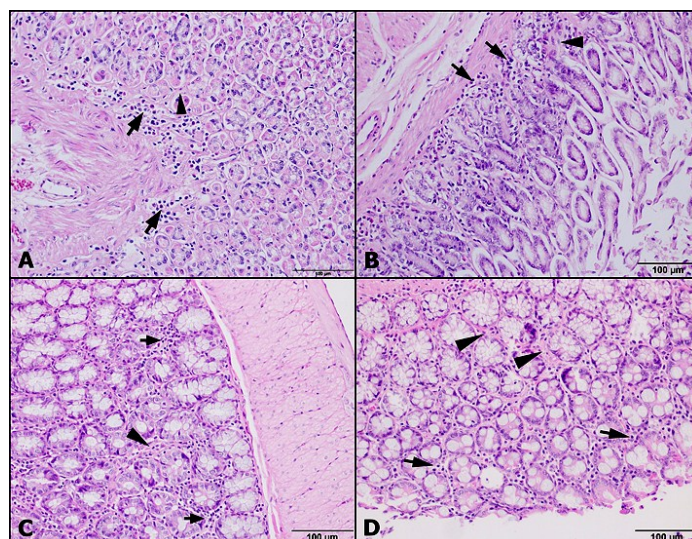


Figure 2. The acute effects of RAI on gastrointestinal tissues in the I131-zinc group are presented with (A) inflammation (arrows) and fibrosis (arrowheads) in the stomach, (B) inflammation (arrows) and fibrosis (black arrowhead) in the duodenum, (C) inflammation and fibrosis (arrowheads) in the ileum and (D) inflammation and fibrosis (arrowheads) in the colon (Haematoxylin and Eosin, A, B, C and D; x400).

Table 1. Histopathological parameters detected in the gastrointestinal tract of the rats. The statistical significance values (p values) between the I131 group and the I131- zinc group are given and marked with * if $p < 0.001$ and ** if $p < 0.05$.

Parameters examined in the groups		Stomach		Duodenum		Ileum		Colon	
		I131 group (n=10)	I131- zinc group (n=10)	I131 group (n=10)	I131- zinc group (n=10)	I131 group n=10	I131- zinc group (n=10)	I131 group (n=10)	I131-zinc group (n=10)
Lamina propia oedema	n	5	2	7	3	9	1	8	4
	%	50	20	70	30	90	10	80	40
	p	0.35		0.074		<0.001*		0.17	
Ulcer	n	3	1	5	1	5	0	4	0
	%	30	10	50	10	50	0	40	0
	p	0,582		0.141		0.033**		0.087	
Mucosal erosion	n	8	2	8	1	6	2	8	0
	%	80	20	80	10	60	20	80	0
	p	0.007**		0.005**		0.17		0.001**	
Mucosal degeneration	n	9	2	6	3	8	1	9	4
	%	90	20	60	30	80	10	90	40
	p	0.005**		0.37		0.005**		0.057	
Necrosis	n	8	0	9	4	10	0	10	4
	%	80	0	90	40	100	0	100	40
	p	0.001**		0.057		<0.001*		0.011**	
Inflammation	n	10	3	9	3	10	4	10	3
	%	100	30	90	30	100	40	100	30
	p	0.003**		0.02**		0.011**		0.003**	
Fibrosis	n	9	3	10	0	10	2	10	1
	%	90	30	100	0	100	20	100	10
	p	0.02**		<0.001*		<0.001*		<0.001*	

The histopathological parameters in stomach, duodenum, ileum and colon were compared between the I131 and I131-zinc groups. In the stomach samples, for the mucosal erosion, mucosal degeneration, necrosis, inflammation and fibrosis parameters, the p values were 0.007, 0.005, 0.001, 0.003, and 0.02 respectively. In the duodenum samples, for the mucosal erosion, inflammation and fibrosis parameters, the p values were 0.005, 0.02, and <0.001, respectively. In the ileum samples, for the lamina propria oedema, ulceration, mucosal degeneration, necrosis, inflammation and fibrosis parameters, the p values were <0.001, 0.033, 0.005, <0.001, 0.011, and 0.001

respectively. In the colon samples, for the mucosal erosion, necrosis, inflammation and fibrosis parameters, the p values were 0.001, 0.011, 0.003, and <0.001 respectively. The bar graphics showing the differences in the number of histopathological parameters in the gastrointestinal system organs in both groups are presented in figure 3.

Within the 2 groups, there was no statistically significant difference between the stomach, duodenum, ileum and colon histopathological parameter differences as most of the observed values were less than 5 due to the limited number of rats.

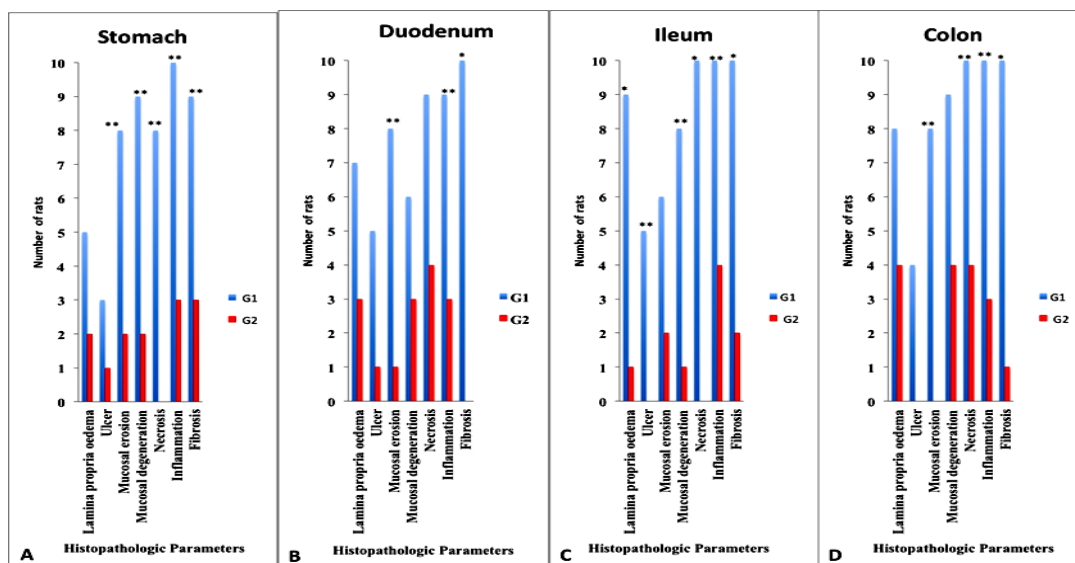


Figure 3. The incidence of histopathological parameters is presented in bar graphics for **A.** stomach, **B.** duodenum, **C.** ileum and **D.** colon in the number of rats; the blue bar represents the I131 group and the red bar represents the I131-zinc group. The significant differences between the groups are marked with * on the top of highest bar if $p < 0.001$ or ** if $p < 0.05$.

DISCUSSION

This study was designed to elucidate the possible radioprotective role of zinc on the histopathological differences following acute RAI exposure. High-dose RAI was observed to cause similar histopathological changes in the RAI administered groups, although all the histopathological changes were less frequently observed in the I131-zinc group compared to the I131 group. In all the evaluated gastrointestinal organs, RAI-induced fibrosis

and inflammation were statistically less frequent in the I131-zinc group compared to the I131 group ($p < 0.05$).

As further evaluation was made for each histopathological parameter, for fibrosis, the p values in the stomach, duodenum, ileum and colon were 0.02, <0.001, 0.001, <0.001 respectively and inflammation in the stomach, duodenum, ileum and colon, the p values were 0.003, 0.02, 0.011, and 0.003 respectively. For necrosis in the stomach, ileum and colon, the p values were 0.001, < 0.001, and 0.011

respectively. For mucosal degeneration in the stomach and ileum, the p values were 0.005 and 0.005 respectively. For mucosal erosion in the stomach, duodenum and colon, the p values were 0.007, 0.005, and 0.001 respectively. Ulceration in the ileum ($p=0.033$), and lamina propria oedema in the ileum were less frequently observed in the I131-zinc given group and the difference was significantly different between the I131 and the I131- zinc groups ($p<0.001$).

In cell cultures, necrosis is detected instantly after RAI⁽³⁰⁾. The cell death, occurring after toxic levels of RAI, causes inflammation, which causes additional tissue damage. RAI-induced damage leading to apoptosis and necrosis of thyroid follicular cells, glandular atrophy, and loss of capacity to function, generates partially reduced oxygen species (ROS), which are then included in the metabolic processes in the cell depending on the cellular antioxidant status. Oxidative stress occurs when the cellular level of ROS exceeds the antioxidant capacity of the cell equipped with protective enzymes such as superoxide dismutase (SOD) and catalase (CAT) or glutathione peroxidase (GSH- Px) and the factors influencing the cellular levels of ROS determine the extent of radiation damage. Zinc is fundamentally essential for sustaining resistance to ionizing radiation as it is a cofactor for the functioning of SOD, CAT, and GSH- Px. Zinc delays and reduces oxidative damage, suggesting that it may have a role in modulating reactive oxygen species and have protective effects on oxidative stress-dependent cytotoxicity⁽³¹⁾.

As far as we know, this is the first study to have evaluated with histopathological parameters the effect of zinc on the gastrointestinal system after high-dose RAI. Through histopathological examination, the results of the current study showed that zinc had radioprotective effects on the rat gastrointestinal tract organs against RAI-induced damage after a high dose of I131.

The main limitation of this study was the limited number of rats in compliance with the “principle of reduction” in animal experiments. In addition the present study discussed the

acute radioprotective effects of zinc, but zinc co-administration may have outcomes on long-term side effects of RAI, which might have been more critical regarding the adverse effects RAI on secondary solid tumors including those of the stomach and colon. From a clinical perspective, for the prevention of impairment of normal tissues, the co-administration of zinc with RAI may be a promising approach. Nevertheless, further studies are needed to elucidate the mechanism underlying the beneficial effect of zinc on RAI-induced damage.

ACKNOWLEDGMENT

The authors have not used any sources of public or private financial support. The authors declare that they have no conflict of interests.

Conflicts of interest: Declared none.

REFERENCES

1. Ziessman HA, O'malley JP, Thrall JH (2013) Nuclear Medicine: The Requisites. Elsevier Health Sciences.
2. Press P (1993) International Commission on Radiological Protection. Addendum 1 to Publication 53—Radiation dose to patients from radiopharmaceuticals. *ICRP Publication 62*, Oxford.
3. Castro MR, Bergert ER, Beito TG *et al.* (1999) Development of monoclonal antibodies against the human sodium iodide symporter: Immunohistochemical characterization of this protein in thyroid cells 1. *The Journal of Clinical Endocrinology & Metabolism*, **84**: 2957-2962.
4. Spitzweg C, Joba W, Schriever K *et al.* (1999) Analysis of human sodium iodide symporter immunoreactivity in human exocrine glands 1. *The Journal of Clinical Endocrinology & Metabolism*, **84**: 4178-4184.
5. Pashnehsaz M, Takavar A, Izadyar S *et al.* (2016) Gastrointestinal side effects of the radioiodine therapy for the patients with differentiated thyroid carcinoma two days after prescription. *World Journal of Nuclear Medicine*, **15**: 173.
6. Alexander C, Bader JB, Schaefer A *et al.* (1998) Intermediate and long-term side effects of high-dose radioiodine therapy for thyroid carcinoma. *The Journal of Nuclear Medicine*, **39**: 1551.
7. Suit H, Goldberg S, Niemierko A *et al.* (2007) Secondary carcinogenesis in patients treated with radiation: a review of data on radiation-induced cancers in human, non-

- human primate, canine and rodent subjects. *Radiat Res*, **167**: 12-42.
8. Metso S, Auvinen A, Huhtala H et al. (2007) Increased cancer incidence after radioiodine treatment for hyperthyroidism. *Cancer*, **109**: 1972-1979.
 9. Koca G, Gültekin SS, Han Ü et al. (2013) The efficacy of montelukast as a protective agent against ¹³¹I-induced salivary gland damage in rats: scintigraphic and histopathological findings. *Nuclear Medicine Communications*, **34**: 507-517.
 10. Acar DE, Acar U, Yumusak N et al. (2014) Reducing the histopathological changes of radioiodine to the lacrimal glands by a popular anti-oxidant: lycopene. *Current Eye Research*, **39**: 659-665.
 11. Acar U, Atilgan HI, Acar DE et al. (2013) The effect of short-term vitamin E against radioiodine-induced early lacrimal gland damage. *Annals of Nuclear Medicine*, **27**: 886-891.
 12. Limon-Pacheco J, Gonshebbatt ME (2009) The role of antioxidants and antioxidant-related enzymes in protective responses to environmentally induced oxidative stress. *Mutation Research*, **674**: 137-147.
 13. Kismet K, Sadic M, Bag YM et al. (2016) Hepatoprotective effect of dexmedetomidine against radioiodine toxicity in rats: Evaluation of oxidative status and histopathologic changes. *International Surgery*, **101**: 176-184.
 14. Barlas A, Bag Y, Pekcici M et al. (2017) Melatonin: a hepatoprotective agent against radioiodine toxicity in rats. *Bratislava Medical Journal-Bratislavske Lekarske Listy*, **118**: 95-100.
 15. Opoka W, Adamek D, Plonka M et al. (2010) Importance of luminal and mucosal zinc in the mechanism of experimental gastric ulcer healing. *Journal of physiology and pharmacology: an official journal of the Polish. Physiological Society*, **61**: 581-591.
 16. Salama SM, Gwaram NS, Alrashdi AS et al. (2016) A Zinc Morpholine Complex Prevents HCl/Ethanol-Induced Gastric Ulcers in a Rat Model. *Scientific Reports* **6**.
 17. Hosseinimehr SJ (2015) The protective effects of trace elements against side effects induced by ionizing radiation. *Radiation Oncology Journal* **33**: 66.
 18. Epperly MW, Gretton JE, Sikora CA et al. (2003) Mitochondrial localization of superoxide dismutase is required for decreasing radiation-induced cellular damage. *Radiation Research*, **160**: 568-578.
 19. Skrovanek S, Diguilio K, Bailey R et al. (2014) Zinc and gastrointestinal disease. *World Journal of Gastrointestinal Pathophysiology*, **5**: 496-513.
 20. Lukacik M, Thomas RL, Aranda JV (2008) A meta-analysis of the effects of oral zinc in the treatment of acute and persistent diarrhea. *Pediatrics*, **121**: 326-336.
 21. Ertekin MV, Koç M, Karslioğlu I et al. (2004) Zinc sulfate in the prevention of radiation-induced oropharyngeal mucositis: a prospective, placebo-controlled, randomized study. *Int J Radiat Oncol Biol Phys*, **58**: 167-174.
 22. Cai L and Cherian MG (1996) Adaptive response to ionizing radiation-induced chromosome aberrations in rabbit lymphocytes: effect of pre-exposure to zinc, and copper salts. *Mutation Research*, **369**: 233-241.
 23. Dani V, Malhotra A, Dhawan D (2007) ¹³¹I induced hematological alterations in rat blood: protection by zinc. *Biological Trace Element Research*, **120**: 219-226.
 24. Sadic M, Atilgan HI, Yumusak N et al. (2017). Zinc; Does it Have Radioprotective Effect on Major Salivary Glands. *Journal of Clinical and Analytical Medicine*, **8**(1): 78-82.
 25. Krishnamurthy H, Jagetia GC, Jyothi P (1998) Radioprotective effect of zinc aspartate on mouse spermatogenesis: a flow cytometric evaluation. *Mutation Research*, **401**: 111-120.
 26. Floersheim GL, Chiodetti N, Bieri A (1988) Differential radioprotection of bone marrow and tumour cells by zinc aspartate. *The British Journal of Radiology*, **61**: 501-508.
 27. Huang MY, Lian SL, Wu HL et al. (2007) Effects of zinc compound on body weight and recovery of bone marrow in mice treated with total body irradiation. *The Kaohsiung Journal of Medical Sciences*, **23**: 453-462.
 28. Floersheim GL and Floersheim P (1986) Protection against ionising radiation and synergism with thiols by zinc aspartate. *The British journal of radiology*, **59**: 597-602.
 29. Scartoni D, Desideri I, Giacomelli I et al. (2015) Nutritional supplement based on zinc, prebiotics, probiotics and vitamins to prevent radiation-related gastrointestinal disorders. *Anticancer Research*, **35**: 5687-5692.
 30. Marx K, Moka D, Schomäcker K et al. (2006) Cell death induced by ¹³¹I in a differentiated thyroid carcinoma cell line in vitro: Necrosis or apoptosis? *Nuclear Medicine Communications*, **27**: 353-358.
 31. Formigari A, Irato P, Santon A (2007) Zinc, antioxidant systems and metallothionein in metal mediated-apoptosis: biochemical and cytochemical aspects. *Comparative Biochemistry and Physiology Part C: Toxicology & Pharmacology*, **146**: 443-459.

