

Protective role of ferulic acid against the damaging effect induced by electromagnetic waves on rat liver and intestine tissues

M.S. Tawfik¹, M. Saif-Elnasr^{1*}, A.A. Elkady¹, M.M. Alkady¹,
A.M. Hawas²

¹Health radiation research department, National Center for Radiation Research and Technology (NCRRT),
Egyptian Atomic Energy Authority (EAEA), P.O. Box 29, Nasr City, Cairo, Egypt

²Drug radiation research department, National Center for Radiation Research and Technology (NCRRT), Egyptian
Atomic Energy Authority (EAEA), P.O. Box 29, Nasr City, Cairo, Egypt

ABSTRACT

Background: the increasing use of mobile phones in daily life causes many concerns about their effects on human health. Therefore, this work was designed to study the effects of exposure to 1800 MHz electromagnetic waves (EMW) on the liver and intestine of male albino rats and the protective role of ferulic acid (FA) against these harmful effects. **Materials and Methods:** twenty-four male albino rats were randomly divided into four groups as follows: 1) control group, 2) treated group given FA, 3) irradiated group exposed to 1800 MHz EMW and 4) treated-irradiated group given FA then exposed to EMW. Biochemical analysis and histopathological examination were performed. **Results:** a significant increase in serum activities of alanine transaminase and aspartate transaminase, and serum levels of interleukin (IL)-6 and tumor necrosis factor- α was shown in the irradiated group, while IL-10 was significantly decreased. There was a significant decrease in lactate dehydrogenase and total antioxidant capacity in the tissues of liver and intestine of this group as well as some histopathological changes. All these serum and tissues parameters and histopathological changes were improved in the group treated with FA before exposure to EMW. **Conclusion:** prolonged exposure to EMW emitted from mobile phones might produce harmful effects in the liver and intestinal tissues of albino rats. These effects can be prevented by FA administration which may be protective against tissue damage induced by EMW through the suppression of oxidative stress.

Keywords: Mobile phones; electromagnetic waves; liver; intestine; ferulic acid.

► Original article

*Corresponding authors:

Dr. Mostafa Saif-Elnasr,

Fax: +2 22749298

E-mail:

mostafa_saif_elnasr@yahoo.com

Revised: November 2017

Accepted: December 2017

Int. J. Radiat. Res., October 2018;
16(4): 421-430

DOI: 10.18869/acadpub.ijrr.16.4.421

INTRODUCTION

Advances in science and technology have introduced many newly developed devices which emit electromagnetic radiation (EMR). These devices include radars, cell phones, radio and television transmitters, microwave ovens and certain devices used in medical and industrial practice ⁽¹⁾. The most frequent sources of EMR are mobile phones and cell towers. Mobile phones and related telephony

technologies transmit information that is encoded into electromagnetic waves (EMW) in the microwave range around 900 MHz and 1800 MHz ⁽²⁾. There is evidence that exposure to the radiofrequency radiation from mobile telephones or their base station could affect people's health, it may be associated with detrimental effects on the human brain, cardiovascular system, gastrointestinal system, cancer development and more specifically male reproduction ⁽³⁻⁵⁾.

The risk level of exposure to radiation depends on the type, frequency of exposure, amount of energy absorbed and duration ⁽⁶⁾. Mechanism of interaction with viable tissues is the conversion of electromagnetic energy to thermal energy which could have a damaging effect on these tissues as a result of cell protein denaturation or destruction ⁽⁷⁾. EMW might disturb reactive oxygen species (ROS) metabolism by increasing its production or by decreasing antioxidant enzymes activities. Chronic exposure to EMW decreases the activity of catalase (CAT), superoxide dismutase (SOD) and glutathione peroxidase (GPx), and thus decreases the total antioxidant capacity (TAC) ⁽⁸⁾.

Ferulic acid (FA) is a phenolic compound commonly found in fruits and vegetables such as tomatoes, sweet corn, and ricebran. It arises from metabolism of phenylalanine and tyrosine by Shikimate pathway in plants. FA exhibits a wide range of pharmacological effects including anti-aging, anti-inflammatory, anticancer, anti-diabetic, anti-apoptotic, and neuroprotective ⁽⁹⁻¹¹⁾. FA possesses antioxidant property by virtue of its phenolic hydroxyl group in its structure. It is an effective scavenger of free radicals ^(12, 13).

We aimed to investigate the damaging effects of EMR emitted by the cell phones on the rat liver and intestinal tissues and assess the protective role of FA against these effects.

MATERIALS AND METHODS

Animals

Twenty-four male albino rats, ten weeks age, weighing 110-140 g, were obtained from the National Center for Radiation Research and Technology (NCRRT), Cairo, Egypt, and used for this study. The rats were allowed an adaptation period of two weeks in a well-ventilated animal house. The rats were fed a standard laboratory chow and allowed free access to water *ad libitum*. Experiments were carried out in accordance with the ethical standards of the NCRRT (serial number of the protocol: 18A/18).

Electromagnetic waves

The whole body of the rats was exposed to

1800 MHz mobile phone-like EMW, using a microwave generating device, at a power 27 dpm, with an average specific absorption rate of 2 w/kg, at the NCRRT. The exposure was for four hours per day, seven days per week, for seven weeks. The microwave generating device was formed of three parts: 1- Hewlett Packard radio-frequency generator 83712B (10 MHz-20 GHz). 2- Hewlett Packard spectrum analyzer 8592L (9 KHz-26.5 GHz). 3- Two horn antennae. The device was placed in a 3 m² room. The animals were placed in stainless steel cages in the room. During exposure to EMW the cages were placed at a distance of 50 cm away from the antennae.

Treatment

FA was purchased from Sigma-Aldrich, USA. It was purchased as a powder that reconstitutes into a crystal-like suspension in distilled water. Half of the rats used in this experiment were given FA as a protective agent at a dose of 20 mg/kg body weight ⁽¹⁴⁾ by oral gavage for two weeks prior to the start of the EMW seven weeks irradiation sessions.

Experimental design

The rats were randomly divided into four groups as follows:

Group 1. Six rats were designated as controls and were neither irradiated by EMW nor given FA throughout the experiment.

Group 2. Six rats were designated as the treated group and were given FA 20 mg/kg body weight once daily by oral gavage, two weeks before the irradiation sessions starting time. However, as they were considered a positive control they were not exposed to any irradiation throughout the experiment.

Group 3. Six rats were designated as the irradiated group and were not given FA beforehand. They were exposed to EMW in the manner described above for seven weeks.

Group 4. Six rats were designated as the treated- irradiated group and were given FA 20 mg/kg body weight once daily by oral gavage, two weeks before the irradiation sessions starting time. Afterwards, they were exposed to EMW as described above for seven weeks

starting 24 h after the final dose of FA.

All rats used were anaesthetized with light ether and sacrificed after a 24 h fasting period after the final dose of EMW. Intracardiac blood samples were collected then serum was obtained by centrifugation and stored at -80°C until analysis. The liver and intestine were dissected and either frozen in -80°C prior to homogenization or fixed in paraffin blocks prior to histopathological examination.

Analysis of the serum parameters

Liver transaminases: aspartate transaminase (AST) and alanine transaminase (ALT) activities were estimated using a colorimetric method with kits purchased from Egy-Chem for lab technology, Egypt.

Tumor necrosis factor-alpha (TNF- α) levels were measured using Quantikine enzyme-linked immunosorbent assay (ELISA) rat TNF- α immunoassay kit (R&D Systems, Inc. USA)

Interleukin (IL)-6 and IL-10 levels were measured using Quantikine ELISA rat IL-6 immunoassay kit (R&D Systems, Inc. USA) and RayBio rat IL-10 ELISA kit (RayBiotech, Inc. USA) respectively.

Analysis of the tissues parameters

A suitable weight of liver or intestinal tissues (0.5 g) was homogenized in 5 ml of ice-cold 0.1 M phosphate buffer saline (pH 7.4), then the homogenate was centrifuged and the supernatant was collected for the estimation of:

Lactate dehydrogenase (LDH) activities using rat LDH ELISA kit (MyBioSource, Inc. USA).

TAC levels using a colorimetric method with kit purchased from Biodiagnostic, Egypt.

Histopathological examination

Liver and intestinal tissues specimens belonging to the four groups were collected and fixed in 10% buffered formalin solution followed by dehydration, clearing and embedding in paraffin. Paraffin sections of 5 μm thickness were sliced and stained routinely with haematoxylin and eosin (H&E), according to Bancroft and Stevens, ⁽¹⁵⁾ and examined with a light microscope.

Statistical analysis

All data was statistically analyzed by one way analysis of variance (ANOVA) followed by a post hoc, least significant difference (LSD) test using the Statistical Package for Social Science (SPSS) program version 15. The results were presented as mean \pm standard error (SE). The values of $p < 0.05$ were considered statistically significant.

RESULTS

Serum ALT and AST

Table 1 shows the difference in the activities of liver enzymes, ALT and AST in the studied groups. The highest mean was observed in the irradiated group compared to control, treated and treated-irradiated groups (in case of ALT, $P \leq 0.0001$, $P \leq 0.0001$ and $P \leq 0.0001$ respectively; in case of AST, $P \leq 0.0001$, $P \leq 0.0001$ and $P \leq 0.0001$ respectively). Treated-irradiated group in turn showed a significant difference when compared to both control and treated groups according to AST ($P \leq 0.01$ and $P \leq 0.01$ respectively). However, in the case of ALT, treated-irradiated group showed a significant difference when compared to the control group ($P < 0.05$) but no significant difference was observed between it and the treated group.

Serum IL-6, IL-10 and TNF- α

Table 1 shows the difference in the levels of IL-6, TNF- α and IL-10 in the studied groups. According to IL-6 and TNF- α , the highest mean was observed in the irradiated group compared to control, treated and treated-irradiated groups (in case of IL-6, $P \leq 0.0001$, $P \leq 0.0001$ and $P \leq 0.0001$ respectively; in case of TNF- α , $P \leq 0.0001$, $P \leq 0.0001$ and $P \leq 0.0001$ respectively). Treated-irradiated group in turn showed a significant difference when compared to both control and treated groups (in case of IL-6, $P \leq 0.0001$ and $P \leq 0.0001$ respectively; in case of TNF- α , $P \leq 0.0001$ and $P \leq 0.0001$ respectively). However, in the case of IL-10, the lowest mean was observed in the irradiated group compared to control, treated and treated-irradiated groups

($P \leq 0.0001$, $P \leq 0.0001$ and $P \leq 0.01$ respectively). Treated-irradiated group in turn showed a significant difference when compared

to both control and treated groups ($P < 0.05$ and $P \leq 0.01$ respectively).

Table 1. Serum activities of liver enzymes, ALT and AST, and levels of IL-6, TNF- α and IL-10 in the studied groups (mean \pm SE).

Parameters	Control group	Treated group	Irradiated group	Treated-Irradiated group
ALT (U/L)	13.50 \pm 1.20	15.00 \pm 1.21	53.50 \pm 7.42 ^{a****b****}	25.33 \pm 2.19 ^{a*c****}
AST (U/L)	15.17 \pm 1.52	14.33 \pm 2.11	66.17 \pm 3.94 ^{a****b****}	29.33 \pm 3.77 ^{a**b**c****}
IL-6 (pg/ml)	31.55 \pm 1.51	33.62 \pm 2.30	111.77 \pm 5.78 ^{a****b****}	74.43 \pm 6.32 ^{a****b****c****}
TNF- α (pg/ml)	31.08 \pm 1.65	38.22 \pm 1.46	138.75 \pm 3.96 ^{a****b****}	87.80 \pm 5.39 ^{a****b****c****}
IL-10 (pg/ml)	163.30 \pm 10.77	168.15 \pm 8.71	96.10 \pm 6.31 ^{a****b****}	133.03 \pm 5.55 ^{a*b**c**}

When P value < 0.05, it is statistically significant.

a : indicates the statistical difference between the compared group and controls

b : indicates the statistical difference between the compared group and treatment group

c : indicates the statistical difference between the compared group and irradiation group

* : means $p < 0.05$; ** : means $p \leq 0.01$; *** : means $p \leq 0.001$; **** : means $p \leq 0.0001$

Liver tissues parameters; LDH and TAC

Table 2 shows the difference in the activities of LDH and the levels of TAC in the studied groups. According to both LDH and TAC, the lowest mean was observed in the irradiated group compared to control, treated and treated-irradiated groups (in case of LDH, $p \leq 0.0001$, $p \leq 0.0001$ and $p \leq 0.0001$ respectively; in case of TAC, $p \leq 0.0001$, $p \leq 0.0001$ and $p \leq 0.05$ respectively). Treated-irradiated group in turn showed a significant difference when compared to both control and treated groups according to TAC ($p \leq 0.01$ and $p \leq 0.01$ respectively). However, in the case of LDH, treated-irradiated group showed a significant difference when compared to the control group ($p \leq 0.05$) but no significant difference was observed between it

and the treated group.

Intestinal tissues parameters; LDH and TAC

Table 2 shows the difference in the activities of LDH and the levels of TAC in the studied groups. According to both LDH and TAC, the lowest mean was observed in the irradiated group compared to control, treated and treated-irradiated groups (in case of LDH, $p \leq 0.0001$, $p \leq 0.0001$ and $p \leq 0.01$ respectively; in case of TAC, $p \leq 0.0001$, $p \leq 0.0001$ and $p \leq 0.01$ respectively). Treated-irradiated group in turn showed a significant difference when compared to both control and treated groups (in case of LDH, $p \leq 0.05$ and $p \leq 0.01$ respectively; in case of TAC, $p \leq 0.0001$ and $p \leq 0.01$ respectively).

Table 2. Liver and intestinal activities of LDH and levels of TAC in the studied groups (mean \pm SE).

Tissues	Parameters	Control group	Treated group	Irradiated group	Treated-Irradiated group
Liver	LDH (U/mg)	236.83 \pm 10.74	227.83 \pm 6.47	125.00 \pm 4.88 ^{a****b****}	207.00 \pm 9.07 ^{a*c****}
	TAC (nmol/mg)	29.07 \pm 2.22	29.28 \pm 1.92	13.78 \pm 1.57 ^{a****b****}	20.07 \pm 1.68 ^{a**b**c*}
Intestine	LDH (U/mg)	207.07 \pm 10.86	213.78 \pm 4.16	116.83 \pm 13.53 ^{a****b****}	170.38 \pm 13.21 ^{a*b**c**}
	TAC (nmol/mg)	39.45 \pm 2.86	36.23 \pm 3.39	12.50 \pm 1.77 ^{a****b****}	23.90 \pm 1.97 ^{a****b**c**}

When P value < 0.05, it is statistically significant.

a : indicates the statistical difference between the compared group and controls

b : indicates the statistical difference between the compared group and treatment group

c : indicates the statistical difference between the compared group and irradiation group

* : means $p < 0.05$; ** : means $p \leq 0.01$; *** : means $p \leq 0.001$; **** : means $p \leq 0.0001$

Histopathological findings

Liver tissues

In the liver of the control group, the hepatic lobule in between the central vein and

peripheral interlobular septum consisted of plates of hepatic cells. These plates branched and anastomosed within the lobule. The portal venules and hepatic arterioles penetrated the

connective tissue to form sinusoids. The hepatic cells were polygonal, varied in size, contained a large, round nucleus and sometimes cells were binucleated. The cells had a granular acidophilic cytoplasm (figure 1A). The liver of irradiated rats (group 3) showed an obvious widespread swelling and ballooning of hepatocytes owing to hydropic degeneration and necrosis processes. Moreover some sinusoids were engorged with blood, and the portal vein was dilated (figure 1 B1,B2). In the treated rats (group 2), the hepatic tissues showed normal structure. On the other hand, in most cases of treated-irradiated rats (group 4) the histological structure of hepatic tissues showed relatively well preserved architecture without necrosis, degenerative changes, dilated blood vessels or apoptosis (figure 1C).

Intestinal tissues

The wall of intestine in the control group consisted of four layers (mucosa, submucosa, muscularisexterna and serosa (visceral peritoneum)). The villi exhibited variable shapes and lengths in the different regions of the small intestine (figure 2A). The intestine of the irradiated rats (group 3) showed desquamation of villus epithelium and catarrhal enteritis represented by dilated blood vessels and leukocytic infiltration with partial necrosis of the tips of villi (figure 2B1,B2). The epithelial of intestinal mucosa had an increased number of goblets cells. Intestinal tissues in the treated rats (group 2) were similar to the control rats. Intestinal tissues in the treated-irradiated rats (group 4) showed a normal wall with or without leukocytic infiltration (figure 2C).

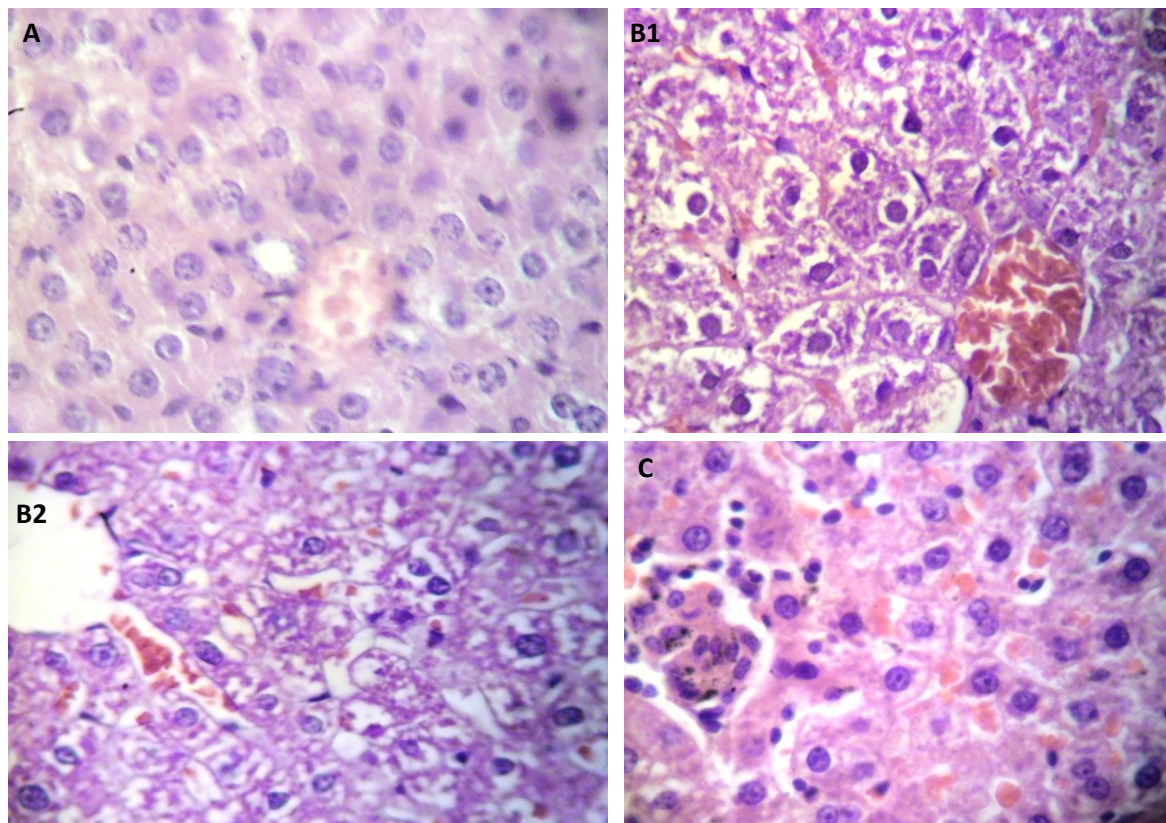


Figure 1. Histopathological findings of liver tissues (H&E \times 400). **(A)** Liver of control rats (group 1) showing a normal structure. **(B1)** Liver of irradiated rats (group 3) showing a dilated portal vein with necrotic changes of hepatocytes. **(B2)** Liver of irradiated rats (group 3) showing a sinusoid slightly engorged with blood with degenerated changes of hepatic tissue. **(C)** Liver of treated-irradiated rats (group 4) showing a normal structure.

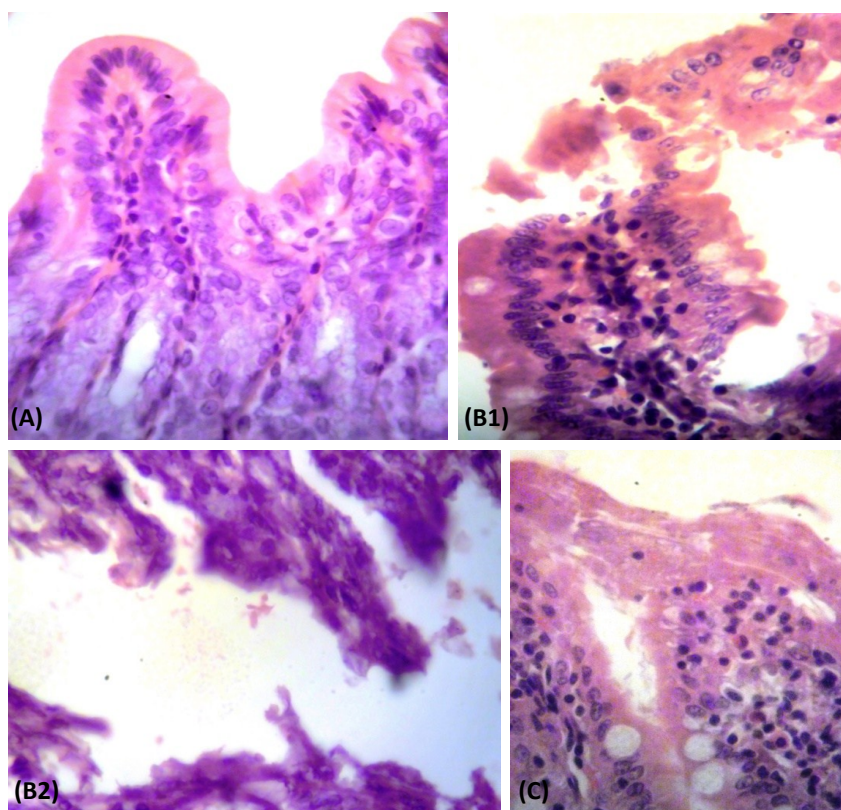


Figure 2. Histopathological findings of intestinal tissues (H&E × 400). **(A)** Intestine of control rats (group 1) showing a normal structure. **(B1)** Intestine of irradiated rats (group 3) showing desquamation of villus epithelium and catarrhal enteritis. **(B2)** Intestine of irradiated rats (group 3) showing partial necrosis of the tips of intestinal villi. **(C)** Intestine of irradiated-treated rats (group 4) showing normal intestinal villi with leukocytic infiltration.

DISCUSSION

In recent years, rapid proliferation of wireless telecommunication industry has resulted in an increase in the number of cell phone users so much so that the radiation emitted from the cell phone has become a cause of concern for public health in general and the cell phone users in particular. However, until now no satisfactory mechanism has been proposed to explain the biological effects of this radiation. Researchers initially were concerned about how microwave radiation affected human biological systems by increasing tissue temperature, in other words, its thermal effects⁽¹⁶⁾. However, Friedman *et al.*⁽¹⁷⁾ have demonstrated that EMW from commercially available cell phones have non-thermal effects. There were controversial reports on the effects

of EMW on mitochondria, apoptosis pathway, heat shock proteins, free radical metabolism, cell differentiation, DNA damage and the plasma membrane⁽¹⁸⁻²⁰⁾.

This study demonstrated a significant effect of exposure to EMR with a frequency of 1800 MHz on rat liver and intestine. Serum activities of AST and ALT changed significantly after the exposure to EMR. Enzyme activities of AST and ALT were significantly increased in the irradiated group compared to the other groups. This data agrees with that reported in previous studies, which reported that EMR caused a significant increase in AST and ALT activities^(2, 21). Ragy⁽²²⁾ reported that ALT, AST, urea, creatinine and corticosterone were significantly increased in male albino rats after exposure to 900 MHz EMR for one hour per day, for sixty days. Liver is an important metabolic tissue and

the main organ of detoxification. It has become clear that non-ionizing radiation from mobile phones has a direct effect at cellular and subcellular levels by destabilizing cell membranes and affecting signal transduction pathways inducing apoptosis, necrosis and cell damages ⁽²³⁾. During cell injury, because of the higher permeability of the hepatocyte membrane, these enzymes penetrate to sinusoids and then enter into the peripheral blood and an increase in the activities of such enzymes (ALT, AST) is observed ⁽²⁴⁾. The great increase in serum AST compared to ALT suggested that the liver was not the only organ leaking the AST or that this enzyme was released to a higher degree than ALT from the liver. The heart, with a relatively high AST content, could provide a significant portion of the serum AST ⁽²⁵⁾.

The present study showed a significant decrease in LDH in the tissues of the liver and intestine after exposure to EMR. The enzyme LDH is considered as a general marker of cellular health, these observations indicate that exposure to the radiofrequency radiation increases cell death and changes the homeostasis of tissues leading to an increase in LDH in serum and a simultaneous decrease in their levels in the liver and intestinal tissues ⁽²⁶⁾.

In the present study, the TAC was significantly decreased in the liver and intestinal tissues of the irradiated group compared to the other groups. These were in agreement with Ragy, ⁽²²⁾ who reported that the TAC decreased after exposure to 900 MHz EMW in the brain, kidney and liver of male rats. Other studies showed that chronic exposure to EMW decreased the activities of CAT, SOD and GPx, and thus decreased the TAC ^(27, 28).

Among the putative mechanisms, by which EMR from mobile phones may affect biological system is by increasing the free radicals life span and the concentration of free radicals or other ROS in the cells ⁽⁸⁾. ROS lead to oxidation damage in major cell macromolecules such as lipid and nucleic acid and have been implicated in tissue injury ⁽²⁹⁾. ROS are scavenged by CAT, SOD and GPx activities. EMR of cellular mobile

phones affect biological systems by increasing free radicals, which appear mainly to enhance lipid peroxidation, and by changing the antioxidant defense systems of human tissues, thus leading to oxidative stress ⁽³⁰⁾.

Exposure to EMR leads to inflammation of the tissues of exposed rats as evidenced by the significantly increased levels of pro-inflammatory cytokines namely IL-6 and TNF- α . Similar results were reported by Wang *et al.* ⁽³¹⁾ where increased serum levels of IL-6 were observed after exposure of rats to microwave radiation and by Megha *et al.* ⁽³²⁾ where TNF- α and IL-6 were increased in brain cells after exposure to this type of radiation. Serum levels of IL-10 were decreased significantly in the irradiated group, and this was in agreement with Wang *et al.* ⁽³¹⁾. The free radicals generated due to microwave radiation exposure stimulate T-helper cells that are important during the beginning of an immune response. Stimulated T-helper cells may secrete pro-inflammatory cytokines like IL-6, TNF- α , IL-2 etc. ⁽³²⁾.

Treatment with FA for two consecutive weeks prior to irradiation ameliorated the activities of serum AST and ALT and the cytokines IL-6, TNF- α and IL-10 and also all the studied tissue parameters of liver and intestine. There was a significant increase of TAC in the tissues of liver and intestine compared to their corresponding values in EMR exposed rats. The deleterious effects of radiation in biological systems are mainly mediated through the generation of ROS which are known to cause oxidative stress in several critical cellular molecules like DNA, proteins and lipid membranes ⁽³³⁾. Currently, there are no previous studies about the protective role of FA against the damaging effects of EMR, but some studies reported its radioprotective role against γ -ionizing radiation. It has been reported that pretreatment with FA to γ -irradiated lymphocytes resulted in decreased lipid peroxidation, and improved antioxidant status preventing the damage to these lymphocytes. This may be due to the antioxidant sparing action of FA since FA prevents the formation of ROS ⁽³⁴⁾. Srinivasan *et al.* ⁽³⁵⁾ evaluated the radioprotective effect of FA, on γ -radiation

induced toxicity in primary cultures of isolated rat hepatocytes. Pretreatment with FA significantly ameliorated lipid peroxidation and DNA damage. In addition, pretreatment with FA significantly increased antioxidant enzymes, reduced glutathione (GSH), vitamins A, E and C, uric acid and ceruloplasmin levels. Thus, pretreatment with FA helps in protecting the hepatocytes against γ -radiation induced cellular damage and can be developed as an effective radioprotector during radiotherapy ⁽³⁵⁾. Also, Salem *et al.*, ⁽³⁶⁾ reported that oral administration of FA resulted in amelioration of γ -radiation-induced hepatic function impairment, dyslipidemia and hepatic histological alterations. In addition it helped in the reduction in lipid peroxidation and elevation of liver CAT, GPx and SOD activities as well as GSH levels.

Another key manifestation of irradiation is oxidative stress mediated inflammation. This is primarily mediated through the activation of the receptor tyrosin kinase (RTK) and redox sensitive kinases in an indirect reversible manner, which in turn phosphorylates I κ B α and releases the sequestered nuclear factor kappa B (NF- κ B) ⁽³⁷⁾. ROS oxidizes the essential cysteine residue with low pKa that exists as a thiolate anion at neutral pH at the active site of protein tyrosine phosphatase enzyme ⁽³⁸⁾. This makes the enzyme inactive and therefore, unable to dephosphorylate the activated RTK. Activated RTK now transmits a signal to the downstream pathway. Eventually, the phosphorylated NF- κ B residue (p⁶⁵) is translocated into the nucleus and augments the expression of cyclooxygenase-2 (COX-2), inducible nitric oxide synthase-2 (iNOS-2), TNF- α and IL-6 inflammatory genes ⁽³⁹⁻⁴²⁾.

FA can accept an extra electron from superoxide radicals therefore, preventing the free radical chain reaction and ROS generation ⁽³⁵⁾. Das *et al.* ⁽⁴³⁾ demonstrated that FA significantly ameliorated γ -radiation induced inflammatory response such as phosphorylation of IKK α / β and I κ B α and consequent nuclear translocation of NF- κ B. FA also prevented the increase of COX-2 protein, iNOS-2 gene expression, lipid peroxidation in liver and the increase of TNF- α and IL-6 in serum. Also, it was

observed that FA treatment prior to irradiation increased the activities of the endogenous antioxidants (SOD, CAT and the pool of GSH content). Thus, pretreatment with FA offers protection against γ -radiation induced inflammation ⁽⁴³⁾. Also FA significantly inhibited down-regulated IL-10 mRNA expressions in trinitrobenzenesulfonic acid induced ulcerative colitis rats ⁽⁴⁴⁾.

The histopathological results of our study indicated that liver tissues of irradiated rats showed an obvious widespread swelling and ballooning of hepatocytes owing to hydropic degeneration and necrosis processes. Moreover, some sinusoids were engorged with blood, and the portal vein was found to be dilated. Also, histopathological examination of the intestine in the irradiated group showed desquamation of villus epithelium and catarrhal enteritis which lead to partial necrosis of the tips of villi. Such results may be due to inflammation of the tissues of rats exposed to EMR as supported by significantly increased levels of pro-inflammatory cytokines (IL-6 and TNF- α) in the present study which agree with the results of Wang *et al.*, ⁽³¹⁾ and El-Bediwi *et al.*, ⁽²¹⁾. Eid and Al-Dossary, ⁽⁴⁵⁾ reported an altered glycogen content, protein content and collagenous fibers in the liver tissue of pregnant rats that were exposed to 50 MHz EMR.

Liver and intestine in treated-irradiated rats showed preserved tissue structures in most cases without necrosis or degenerative changes that may be due to the antioxidant and anti-inflammatory proprieties of FA that appeared clearly in the present study where treatment with FA for two consecutive weeks previous to irradiation improved TAC levels in the liver and intestinal tissues, and serum cytokines IL-6 and TNF- α .

In conclusion, prolonged exposure to EMR emitted from mobile phones might produce some biochemical and histopathological changes and oxidative stress in the liver and intestinal tissues of albino rats. These alterations were corrected by the administration of FA which may be protective against tissue damage induced by EMR through the suppression of oxidative stress.

ACKNOWLEDGMENT

The authors are greatly indebted to Prof. Dr. Karam Sharshar (Radiation Engineering Department, National Center for Radiation Research and Technology (NCRRT), Egyptian Atomic Energy Authority (EAEA)) for his providing of the microwave generating device and his valuable training on the apparatus as well as his continuous support throughout this work.

Conflicts of interest: Declared none.

REFERENCES

- Koca O, Gökçe AM, Öztürk MI, Ercan F, Yurdakul N, Karaman MI (2013) Effects of intensive cell phone (Philips Genic 900) use on the rat kidney tissue. *Urol J*, **10(2)**: 886-891.
- Aberumand M, Mansouri E, Pourmotahari F, Mirlohi M, Abdoli Z (2016) Biochemical and histological effects of mobile phone radiation on enzymes and tissues of mice. *RJPBCS*, **7(5)**: 1962-1971.
- Knave B (2001) Electromagnetic fields and health outcomes. *Ann Acad Med Singapore*, **30(5)**: 489-493.
- Bortkiewicz A (2001) A study on the biological effects of exposure mobile-phone frequency EMF. *Med Pr*, **52(2)**: 101-106.
- Parsanezhad ME, Mortazavi SMJ, Doohandeh T, Namavar Jahromi B, Mozdarani H, Zarei A, Davari M, Amjadi S, Soleimani A, Haghani M (2017) Exposure to radiofrequency radiation emitted from mobile phone jammers adversely affects the quality of human sperm. *Int J Radiat Res*, **15(1)**: 63-70.
- Balmori A (2005) Possible effects of electromagnetic fields from phone masts on a population of white stork (*Ciconia ciconia*). *Electromagn Biol Med*, **24**: 109-119.
- Vanderstraeten J (2009) GSM fields and health: an updated literature review. *Rev Med Brux*, **30(4)**: 416-424.
- Balci M, Devrim E, Durak I (2007) Effects of mobile phones on oxidant/antioxidant balance in cornea and lens of rats. *Curr Eye Res*, **32(1)**: 21-25.
- Kim HK, Jeong TS, Lee MK, Park YB, Choi MS (2003) Lipid lowering efficacy of hesperidin metabolites in high-cholesterol fed rats. *Clin Chim Acta*, **327(1-2)**: 129-137.
- Soobrattee MA, Neergehen VS, Luximon-Ramma A, Aruoma OI, Bahorun T (2005) Phenolics as potential antioxidant therapeutic agents: mechanism and actions. *Mutat Res*, **579(1-2)**: 200-213.
- Gohil KJ, Kshirsagar SB, Sahane RS (2012) Ferulic acid – a comprehensive pharmacology of an important bioflavonoid. *IJPSR*, **3(1)**: 700-710.
- Kikuzaki H, Hisamoto M, Hirose K, Akiyama K, Taniguchi H (2003) Antioxidant properties of ferulic acid and its related compounds. *J Agric Food Chem*, **50**: 2161-2168.
- Mishra K, Ojha H, Kallepalli S, Alok A, Kumar Chaudhury N (2014) Protective effect of ferulic acid on ionizing radiation induced damage in bovine serum albumin. *Int J Radiat Res*, **12(2)**: 113-121.
- Rukkumani R, Aruna K, Suresh Varma P, Padmanabhan Menon V (2004) Hepatoprotective role of ferulic acid: a dose-dependent study. *J Med Food*, **7(4)**: 456-461.
- Bancroft JD and Stevens AE (1996) Theory and Practice of Histological Techniques. 4th ed. Edinburgh, Churchill Livingstone, pp: 766.
- Oftedal G, Wilen J, Sandstrom M, Mild KH (2000) Symptoms experienced in connection with mobile phone use. *Occup Med (Lond)*, **50**: 237-245.
- Friedman J, Kraus S, Hauptman Y, Schiff Y, Seger R (2007) Mechanism of short-term ERK activation by electromagnetic fields at mobile phone frequencies. *Biochem J*, **405**: 559-568.
- McNamee JP, Bellier PV, Gajda GB, Lavallee BF, Marro L, Lemay E, Thansandote A (2003) No evidence for genotoxic effects from 24 h exposure of human leukocytes to 1.9 GHz radiofrequency fields. *Radiat Res*, **159**: 693-697.
- World Health Organization (WHO) (2006) WHO research agenda for radio frequency fields.
- Desai NR, Kesari KK, Agarwal A (2009) Pathophysiology of cell phone radiation: oxidative stress and carcinogenesis with focus on male reproductive system. *Reprod Biol Endocrinol*, **7**: 114.
- El-Bediwi A, El-kott AF, Saad M, Eid E (2011) Effects of electromagnetic radiation produced by mobile phone on some visceral organs of rat. *J Med Sci*, **11(6)**: 256-260.
- Ragy MM (2015) Effect of exposure and withdrawal of 900 -MHz-electromagnetic waves on brain, kidney and liver oxidative stress and some biochemical parameters in male rats. *Electromagn Biol Med*, **34(4)**: 279-284.
- Lahijani MS, Tehrani DM, Sabouri E (2009) Histopathological and ultrastructural studies on the effects of electromagnetic fields on the liver of preincubated white leghorn chicken embryo. *Electromagn Biol Med*, **28(4)**: 391-413.
- Friedel R, Diederichs F, Lindena J (1979) Release and extracellular turn-over of cellular enzyme. In: *Advances in Clinical Enzymology*, (Schmidt EF, Schimidt W, Transchold I and Friedel R, eds.), Karge, Basel, pp: 70-105.
- Mayer FL, Verteeg DJ, McKee MJ, Folmar LC, Gramey RL, McCume DC, Rattner BA (1991) Physiological and non-specific biomarkers. In: *Biomarkers* (Huggett RJ, Kimerle RA, Mehrle Jr PM and Bergman HL, eds.), Boca Raton, FL: Lewis Publishers, pp: 5-85.
- Shivashankara AR (2015) Effect of cell phone use on salivary total protein, enzymes and oxidative stress markers in young adults: a pilot study. *J Clin Diagnostic Res*, **9(2)**: 19-22.
- Ibrahim NK and Gharib OA (2010) The protective effect of antioxidants on oxidative stress in rats exposed to the 950 MHz electromagnetic field. *J Rad Res Appl Sci*, **3(4A)**: 1143-1155.
- El Nabrawy NA and El Desouky MA (2011) Protective

- effect of caffeic acid phenethyl ester (CAPE) on liver and kidney of rats after exposure to 900 MHz electromagnetic field. *J Am Sci*, **7**(12): 937-944.
29. Lee BC, Johng HM, Lim JK, Jeong JH, Baik KY, Nam TJ, Lee JH, Kim J, Sohn UD, Yoon G, Shin S, Soh KS (2004) Effects of extremely low frequency magnetic field on the antioxidant defense system in mouse brain: a chemiluminescence study. *J Photochem Photobiol B*, **73**: 43-48.
 30. Koyu A, Ozguner F, Yilmaz H, Uz E, Cesur G, Ozelik N (2009) The protective effect of caffeic acid phenethyl ester (CAPE) on oxidative stress in rat liver exposed to the 900 MHz electromagnetic field. *Toxicol Ind Health*, **25**(6): 429-434.
 31. Wang YH, Jiang LZ, Li Q, Sun YM, Lü SJ, Zhong XH (2014) Effect of high power microwave radiation on liver injury and serum cytokine in rats. *Acad J Sec Milit Med Univ*, **35**(6): 672-675.
 32. Megha K, Deshmukh PS, Banerjee BD, Tripathi AK, Abegaonkar MP (2012) Microwave radiation induced oxidative stress, cognitive impairment and inflammation in brain of Fischer rats. *Indian J Exp Biol*, **50**(12): 889-896.
 33. Nair CK, Parida DK, Nomura T (2001) Radioprotectors in radiotherapy. *J Radiat Res*, **42**(1): 21-37.
 34. Prasad NR, Srinivasan M, Pugalendi KV, Menon VP (2006) Protective effect of ferulic acid on γ -radiation-induced micronuclei, dicentric aberration and lipid peroxidation in human lymphocytes. *Mutat Res*, **603**(2): 129-134.
 35. Srinivasan M, Sudheer AR, Pillai KR, Kumar PR, Sudhakaran PR, Menon VP (2006) Influence of ferulic acid on γ -radiation induced DNA damage, lipid peroxidation and antioxidant status in primary culture of isolated rat hepatocytes. *Toxicology*, **228**(2-3): 249-258.
 36. Salem AM, Mohammad TF, Ali MAM, Mohamed EA, Hassan HF (2016) Ellagic and ferulic acids alleviate gamma radiation and aluminium chloride-induced oxidative damage. *Life Sci*, **160**: 2-11.
 37. Brach MA, Hass R, Sherman ML (1991) Ionizing radiation induces expression and binding activity of nuclear factor kappa B. *J Clin Invest*, **88**: 691-695.
 38. Schreck R, Rieber P, Baeuerle PA (1991) Reactive oxygen intermediates as apparently widely used messengers in the activation of the NF- κ B transcription factor and HIV-1. *EMBO J*, **10**: 2247-2258.
 39. Crofford LJ, Tan B, McCarthy CJ, Hla T (1997) Involvement of nuclear factor κ B in the regulation of cyclooxygenase-2 expression by interleukin-1 in rheumatoid synoviocytes. *Arthritis Rheum*, **40**(2): 226-236.
 40. Libermann TA and Baltimore D (1990) Activation of interleukin-6 gene expression through the NF-kappa B transcription factor. *Mol Cell Biol*, **10**: 2327-2334.
 41. Collart MA, Baeuerle P, Vassalli P (1990) Regulation of tumor necrosis factor alpha transcription in macrophages: involvement of four kappa B-like motifs and of constitutive and inducible forms of NF-kappa B. *Mol Cell Biol*, **10**: 1498-1506.
 42. Chen CY, Peng WH, Tsai KD, Hsu SL (2007) Luteolin suppresses inflammation-associated gene expression by blocking NF- κ B and AP-1 activation pathway in mouse alveolar macrophages. *Life Sci*, **81**: 1602-1614.
 43. Das U, Manna K, Sinha M, Datta S, Das DK, Chakraborty A, Ghosh M, Saha KD, Dey S (2014) Role of ferulic acid in the amelioration of ionizing radiation induced inflammation: a murine model. *PLoS One*, **9**(5): e97599.
 44. Sadar SS, Vyawahare NS, Bodhankar SL (2016) Ferulic acid ameliorates TNBS-induced ulcerative colitis through modulation of cytokines, oxidative stress, iNOs, COX-2, and apoptosis in laboratory rats. *EXCLI J*, **15**: 482-499.
 45. Eid F and Al-Dossary AA (2007) Ultrastructural, histological and histochemical study on the effect of electromagnetic field on the liver of pregnant rats and their fetuses. *Egypt J Hosp Med*, **28**: 273-294.