

Intramuscular hemangioma of the forearm; Report of a case

M. Vakilha¹, F. Farhan^{*1}, F. Samiei¹, S. Shariat²

¹*Radiotherapy-Oncology Dept., Imam Hospital, Tehran University of Medical Sciences, Tehran, Iran*

²*Central Pathology Laboratory, Imam Hospital, Tehran University of Medical Sciences, Tehran, Iran*

ABSTRACT

A case of intramuscular hemangioma of the right forearm and hand muscle is presented in this study. This tumor may infiltrate the muscle and be misdiagnosed as a malignant neoplasm. The patient, a 14-year-old girl, presented to the clinic with right forearm and hand pain and swelling which began when she was 2 years old and had been gradually increasing in size. Because the mass might have been malignant, in 1990 a biopsy was performed.

Histologic analysis revealed a benign intramuscular hemangioma. A second biopsy at 1992 reported intramuscular hemangioma, mixed type again. She had not received any other treatment. She was seen in March 2003 when the size of the mass had increased and was associated with a dull ache and swelling limited hand movements. The patient subsequently received radiotherapy. *Iran. J. Radiat. Res., 2003; 1(3): 175 – 179*

Key words: *Hemangioma, forearm, MRI imaging, arteriography.*

INTRODUCTION

Hemangiomas are the most common soft tissue tumors of infancy and occur in 5 to 10 percent of 1-year-old children. Despite the frequency of these tumors, their pathogenesis is not completely understood, and the best approach to their management remains controversial, (Drolet *et al.* 1999). Less than 1% of all hemangiomas of the body occur in muscles. Intramuscular hemangiomas are nonmetastasizing benign hamartomatous congenital neoplasms, that after remaining unrecognized for long periods, may suddenly start to grow in the second and third decades of life (Rossiter *et al.* 1993). There is a tendency for male preponderance.

We reported a case of an intramuscular hemangioma that was thought to be a malignant tumor and therefore removed in part for biopsy.

*** Corresponding author:**

Dr. F. Farhan, Radiotherapy-Oncology Department, Imam Hospital, Tehran University of Medical Sciences, Tehran, Iran.

E-mail: farshidfarhan@yahoo.com

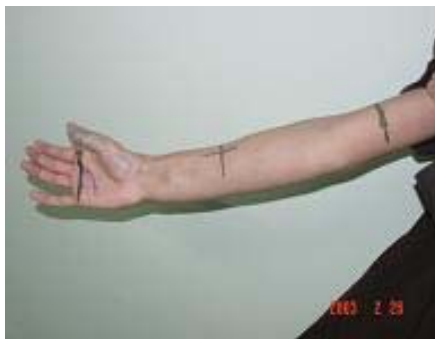CASE REPORT

The 14-year-old girl presented with a slowly growing and tender mass on her right forearm and hand. According to her medical history it was first noticed during her first month of life as a red discoloration of the skin on the dorsal aspect of right hand and forearm. Her parents first noticed the swelling on the forearm in 1990. This gradually spread inferiorly to below the wrist, restricting the movement of hand. The possibility of a malignant lesion was considered, so in 1990 she had a biopsy.

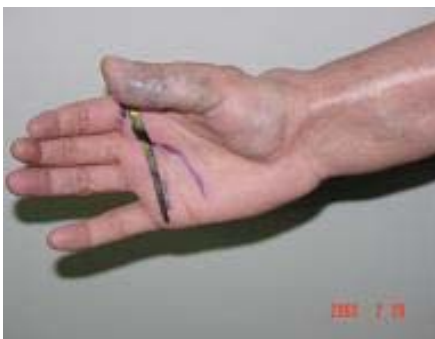Pathological examination of the specimen showed muscle and fat tissue with extensive old and new hemorrhage and proliferation of spindle cells in vascular walls that was diagnosed as intramuscular hemangioma. By 1992, the mass had grown gradually, a mass resection of the tumor attempted and again pathology reported to be intramuscular hemangioma. After surgery the tumor recurred and slowly progressed to huge mass and impaired function of the hand.

Examination revealed a firm, tender mass in the dorsal aspect of the right forearm and hand with bluish discoloration of the skin. She had no deformity. When she was putting down her hand the swelling and pain were increased, the veins of forearm and hand were extensively engorged, and after a few minute skin discoloration was appearing (figure 1 A and B). Magnetic resonance imaging showed intermediate or slightly high signal intensity on T1-weighted spin-echo image and overall extremely bright signal on T2-weighted images (figure 2 A-D). Arteriography showed multiple vascular clusters from above elbow to distal end of hand (figure 3 A-C).

We requested an angiographic embolization but unfortunately they could not be able to do it. We began radiotherapy in March 2003 with parallel opposed portals, which included hand, forearm and elbow. Total dose was 3000 cGy in 15 fractions. Six months after completion of treatment the patient felt better, the lesion had regressed, the swelling decreased very much, the hand movements had improved and she had no pain (figure 4 A-C).

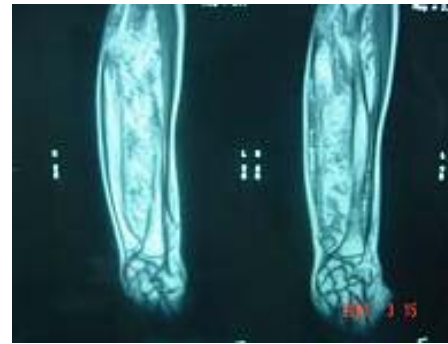

A

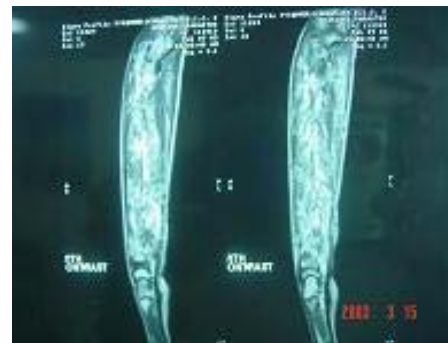

B

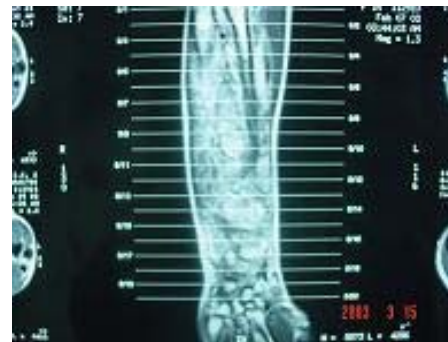Figure 1. Hand and forearm discoloration



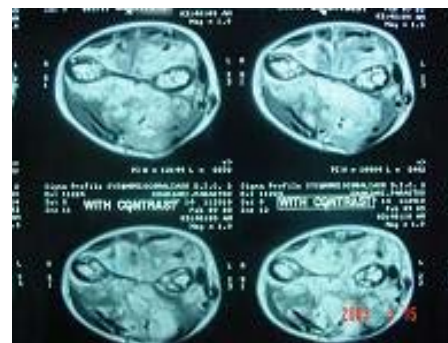
A



B

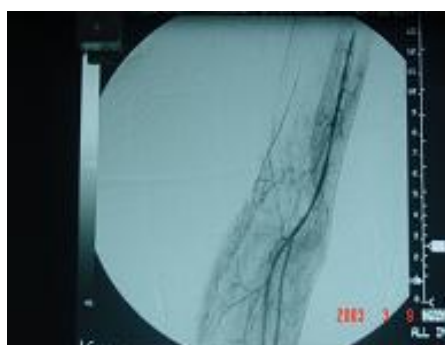

C

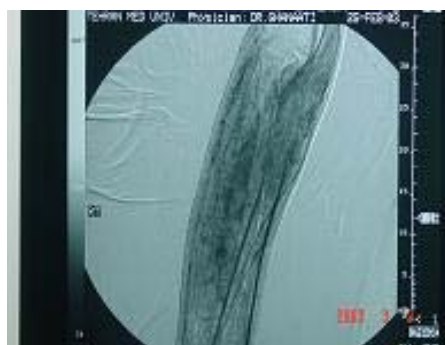

D

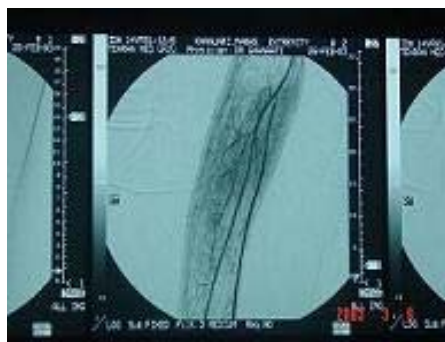Figure 2. MR images of the hand



A

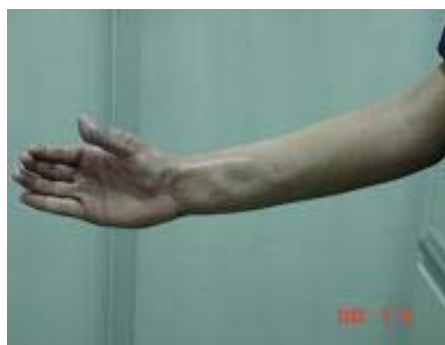

B



C

Figure 3. Arteriography showing multiple vascular clusters



A



B



C

Figure 4. Hand after treatment with improved movement and no pain

DISCUSSION

Hemangioma is not a neoplasm but, rather, a hamartomatous proliferation of endothelial tissue. The life cycle of a hemangioma differs from that of most tumors in that a hemangioma has a phase of rapid proliferation that is followed by spontaneous involution. Usually arising during childhood, it may continue to extend either continuously or intermittently throughout adult life. Approximately 55 percent of these tumors are present at birth, and the remainder develops in the first weeks of life.

Lesions in the skin are apparent by the distended bluish discoloration of the skin. In the deeper intramuscular lesions, they present as a tender mass. In bone, they are usually incidentally discovered radiographically or present with a prolonged history of discomfort rather than severe pain. They are composed of vascular elements embedded in fibrofatty tissue and can arise from cutaneous, intermuscular, synovial,

subcutaneous, intramuscular, or mixed tissues. The most accepted classification system is based on the histologic appearance of the vessels and includes the following subtypes: capillary, cavernous, venous, arteriovenous, and mixed, (Maki *et al.* 1996). Clinical manifestations may include pain, the presence of a mass, soft tissue swelling, subcutaneous discolorations, and less frequently, neurologic symptoms secondary to impingement of a nerve bundle.

These symptoms may be present for years before a diagnosis is made. Superficial soft tissue hemangiomas have a predilection for the head and neck while deep-seated hemangiomas appear more frequently in the trunk and lower extremities.

Malignant degeneration is extremely rare. Moreover, hemangiomas do not metastasize, but rather proliferate or involute with time. Conventional radiography of the affected area is usually the initial diagnostic study obtained in patients suspected of having a soft tissue mass and will often reveal an ill-defined soft tissue prominence or mass. In many cases, the radiographs are normal, however. The other major soft tissue finding is phleboliths, which can occur in 20% to 67% of cases.

However a very specific radiographic sign for soft tissue hemangiomas, phleboliths are not very sensitive. Ultrasonography with Doppler studies is a cost-effective, noninvasive technique that demonstrates the high flow pattern that is a characteristic of hemangiomas, thus differentiating them from solid tumors and malformations of the veins, lymph vessels, and capillaries. On a computed tomographic scan, a hemangioma appears as a homogeneous mass with large feeding vessels, with intense and persistent enhancement after the administration of contrast material. Magnetic resonance imaging of hemangiomas demonstrates well-circumscribed, densely lobulated masses, with an intermediate signal intensity on T1-weighted images and a moderately hyperintense signal on T2-weighted images. The definitive diagnosis is determined by biopsy.

Treatment options for intramuscular hemangioma include cryotherapy, radiotherapy, injection of sclerosing agents, and corticosteroids.

Treatment depends on the location, size, the age of the patient, the presence or likelihood of complications, the availability of certain treatments (such as laser therapy), the expertise of the treating physician, parental preference, and subtype of the soft tissue hemangioma. Although cutaneous hemangiomas often regress during early childhood, spontaneous regression of intramuscular hemangiomas has not been described. Indications for therapy include acceleration of tumor growth, uncontrollable pain, gross functional impairment, local skin necrosis, thrombocytopenia, cosmetic deformity, and suspicion of malignancy, (Avci *et al.* 2002).

Superficial capillary hemangiomas are often treated conservatively as their natural history is involution with time. The use of radiation therapy has largely been discarded in recent years because of the potential late effects in pediatric patients and because treatment is usually unnecessary. A trial of oral steroids is now the preferred treatment for skin hemangiomas requiring intervention, such as rapidly growing facial lesions causing disfigurement, and radiation therapy is reserved for lesions that threaten function or life and have failed alternative therapies, (Carlos 1998).

For deep-seated soft tissue hemangiomas, however, wide local excision is the optimal management in order to prevent recurrence. In cases of incomplete excision, there is an 18% risk of recurrence. Systemic corticosteroids can decrease the bulk of the tumor, and these drugs can also be injected into the tumor, (Rossiter *et al.* 1993). In cases that fail to respond to corticosteroids, interferon γ -2a and 2b can be used. However, this may cause irreversible spastic diplegia in 20% of cases, (Drolet *et al.* 1999).

Embolization and/or injections of sclerosing agents have produced variable results depending on the extent of the communication between the lesional vascular tissue and the systemic

circulation. Multiple feeding vessels may make embolization impractical, and insufficient communication may leave large portions of the lesion unaffected by sclerosing agents.

Radiotherapy of deep symptomatic hemangiomas has a disappointingly high incidence of persistence/recurrence and is only advisable when the lesion is disabling or is surgically inaccessible, (Enneking *et al.* 1998).

REFERENCES

- B.A. Drolet, N.B. Esterly, I.J. Frieden. (1999). Hemangiomas in children. *N. Engl. J. Med.*, **341**: 173–181.
- Enneking W., Rathe R., Cornwall G. (1998). *Clinical Musculoskeletal Pathology, CD-ROM VER. 1.0.*
- Gülden A., Serkan Y., Aykut M., Tayfun A., Lütfi K. K. (2002). Intramasseteric hemangioma. *Plastic and Reconstructive Surgery*, **109**: 1748-1750
- Maki D.D., Craig-Mueller J., Griffiths H.J. (1996). Radiologic case study. *Intramuscular hemangioma. Orthopedics*. **19**: 907-909.
- Rossiter J.L., Hendrix R.A., Tom L.W.C., Potsic W.P. (1993). Intramuscular hemangioma of the head and neck. *Otolaryngol. Head Neck Surg.*, **108**: 18–26.
- William S., Michael F.D., Richard T.H. (1998). Radiation treatment of benign disease. Principles and Practice of Radiation Oncology, Carlos A. Perez, L. W. Brady (eds.). *Lippincott-Raven Publishers, Philadelphia*, 2172.