

# Application of 64-slice spiral computed tomography angiography in a follow-up evaluation after coronary stent implantation: A Chinese clinical study

F. Huang<sup>1\*</sup>, J.G. Ye<sup>2</sup>, L.B. Su<sup>3</sup>, Y.Y. Guo<sup>1</sup>, W.X. Liu<sup>1</sup>, C. Cai<sup>1</sup>

<sup>1</sup>Department of Radiology, The second affiliated hospital, Fujian Medical University, Quanzhou, 36200, P. R. China

<sup>2</sup>Department of Radiology, Huian county hospital, Huian, China

<sup>3</sup>Department of Radiology, Anxi county hospital, Anxi, China

## ► Short report

### \*Corresponding authors:

Fang Huang, MD,

### E-mail:

huangfang8012@163.com

Revised: November 2018

Accepted: December 2018

Int. J. Radiat. Res., July 2019;  
17(3): 479-484

DOI: 10.18869/acadpub.ijrr.17.3.479

## ABSTRACT

**Background:** This study assessed the application value of 64-slice spiral computed tomography angiography (CTA) in a follow-up evaluation of patients receiving coronary stent implantation. **Materials and Methods:** A total of 468 patients who underwent percutaneous coronary intervention (PCI) at our hospital between January 2013 and October 2016 were selected for this study. Coronary angiography and 64-slice spiral coronary CTA were performed. The differences between CTA and coronary angiography regarding the diagnosis of in-stent restenosis (ISR) were compared. **Results:** The sensitivity, specificity, false positive rate, false negative rate, positive predictive value, negative predictive value, and accuracy of 64-slice spiral coronary CTA in evaluating ISR were 77.9%, 96.4%, 3.6%, 22.1%, 69.1%, 97.7%, and 94.71%, respectively. The results of the CTA and coronary angiography in diagnosing ISR in different locations of the coronary artery were not significantly different ( $P>0.05$ ). CTA imaging quality was significantly better for stents with diameters  $>3$  mm than that for stents with diameters  $\leq 3$  mm ( $P<0.05$ ). **Conclusion:** Overall, 64-slice spiral coronary CTA has very high accuracy and was not significantly different compared with coronary angiography when assessing the patency of stents. CTA is advantageous because it is inexpensive, simple and convenient, and it can be used for follow-up examinations.

**Keywords:** CT angiography, coronary angiography, coronary stent, in-stent restenosis.

## INTRODUCTION

Percutaneous coronary stent implantation is currently an important method to treat coronary heart disease in clinical practice<sup>(1, 2)</sup>. In-stent restenosis (ISR) is a major complication after percutaneous coronary intervention (PCI), and most cases occur one year after procedure<sup>(3, 4)</sup>. Approximately 50% of patients with ISR after PCI have no significant angina symptoms<sup>(5, 6)</sup>. Coronary angiography is the gold standard for diagnosing ISR, but it is expensive and involves a relatively complex procedure. Coronary

computed tomography angiography (CTA) is a simple procedure that can be used to reconstruct clear images of the coronary anatomy and shows satisfactory sensitivity and accuracy for diagnosing coronary artery disease. Moreover, this procedure is inexpensive and easy to perform<sup>(7, 8)</sup>. The current study retrospectively analyzed and compared 64-slice spiral CTA images with corresponding coronary angiography images from 468 post-PCI patients at our hospital and evaluated the application value of coronary CTA in a follow-up examination after PCI.

## MATERIALS AND METHODS

Approval was obtained from the Institutional Review Board of the University of Fujian Medical University, China, for a retrospective review of post-PCI patients with clinically suspected ISR who received CTA and coronary angiography. Additionally, written informed consent was signed by the families of the patients.

We retrospectively selected 468 patients undergoing PCI at our hospital between January 2013 and October 2016. A total of 998 stents were implanted (Resolute™ zotarolimus-eluting stents, Medtronic, Minneapolis, MN, USA). The inclusion criteria were as follows: 1) patients underwent coronary CTA and coronary angiography approximately 12 months after PCI, and the interval between the two procedures was no more than one month; and 2) no revascularization was performed within one year after PCI. The exclusion criteria were as follows: 1) patients with unstable clinical conditions including acute coronary syndrome, severe heart or lung insufficiency, or cardiogenic shock, or severe renal insufficiency; 2) patients undergoing coronary CTA or coronary angiography alone, or the interval between the two procedures was more than one month; 3) patients with atrial fibrillation or atrial flutter.

### *Preparation before examination*

Patients presenting with a heart rate of >70 beats/min (no  $\beta$ -receptor blocker contraindications were evident) were administered metoprolol tartrate tablets (25-50 mg) orally and then underwent an examination one hour later. Before the scan, the patients were asked to relax and were trained on how to control their breathing during the examination (i.e., each patient was instructed to breathe deeply and then to hold his or her breath for 15 seconds for practice).

### *Scanning methods*

A Philips 64-slice spiral CT scanner was used to continuously scan volumes in this study. First, a baseline image of the chest during a breath-hold was obtained. Then, the scanner

was operated in retrospective electrocardiogram-gated mode to perform an enhanced cardiac scan. The scanning range was from 10 mm below the tracheal carina to 10 mm below the heart. A high-pressure syringe was used for a bolus injection of iopamidol (60-70 ml, 5.0 ml/s) via the forearm vein, followed by a 20-ml normal saline flush. The scan parameters were as follows: tube voltage, 120 KV; tube current, 80 mA; collimation, 0.6 mm; pitch, 0.2; rotation time, 330 ms; and the ascending aortic root as the threshold-monitoring position, with a threshold value of 100 Hu. Scanning started five seconds after iopamidol injection.

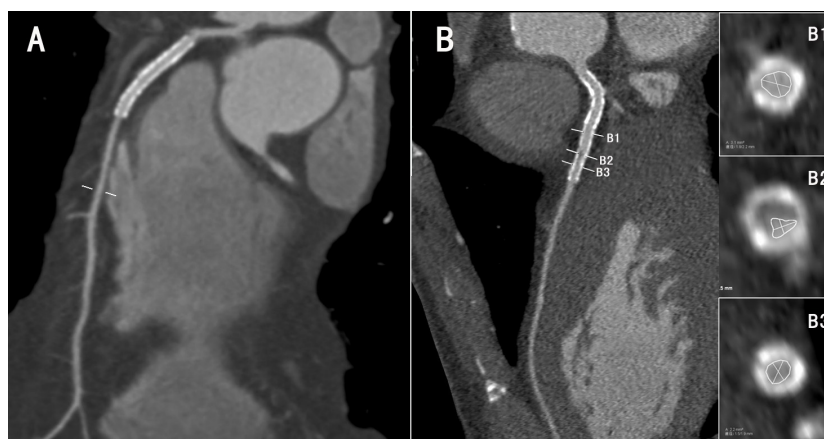
**Image analysis:** The raw images were reconstructed using processing techniques and software such as curved planar reformation. Volume rendering, maximum intensity projection, curved planar reformation, multiplanar reformation, and three-dimensional postprocessing of the scan data were performed to obtain various images of the coronary arteries. A four-step grading scale allowed classification into four groups: group 1, excellent image quality; group 2, good image quality; group 3, moderate image quality; and group 4, poor image quality. Agreement between the investigators for the grading of image quality (1-4) was calculated with the  $\kappa$  statistic. The results were interpreted as poor ( $\kappa < 0.20$ ), fair ( $\kappa = 0.21-0.40$ ), moderate ( $\kappa = 0.41-0.60$ ), good ( $\kappa = 0.61-0.80$ ), very good ( $\kappa = 0.81-0.90$ ), or excellent ( $\kappa > 0.91$ )<sup>(9)</sup>. A further imaging analysis was performed for the stent image quality scores of 1-3; stent image quality scores of 4 were rejected.

Restenosis after coronary stenting was assessed by the degree of stenosis = (normal vessel diameter proximal to the stenosis - diameter of the stenosed part) / normal vessel diameter proximal to the stenosed part  $\times 100\%$ <sup>(10)</sup>. Figure 1 referring to the research methods of Gasper, the stented segment was graded 1 to 4 according to the proportion of the vessel lumen that was poorly enhanced: grade 1, no or minimal narrowing; grade 2, moderate narrowing with obstruction of 50% of the lumen; grade 3, significant (50%) but not severe

narrowing; and grade 4, severe narrowing to total occlusion of the stented segment. Narrowing of 50% of the luminal diameter in the worst view in relation to a reference segment was defined as clinically relevant restenosis<sup>(11)</sup>.

Statistical analysis: Two physicians blinded to the study separately evaluated the results. The coronary artery angiography results were used

as the reference standard to evaluate the sensitivity, specificity, positive predictive value, negative predictive value, and accuracy of CTA in diagnosing ISR. The Statistical Package for Social Sciences software version 19.0 was used for statistical analysis. Counting data were analyzed by the Chi-square test. A P value <0.05 was defined as statistically significant.



**Figure 1.** **A** indicating images of anterior descending stent placement, and the stent was well filled with contrast agent. **B** indicating images of Irregular contrast filling defect was found in the stent lumen, and the stenosis was about 50%. (**B1**: the proximal normal lumen at the stenosis of the stent, with an area of 3.1mm<sup>2</sup>; **B2**: the stenosis of the stent, with an area of about 1.2mm<sup>2</sup>; **B3**: stent stenosis out of distal normal lumen with an area of 2.2mm<sup>2</sup>).

## RESULTS

Table 1 shows that 998 stents were implanted, although 70 stents were excluded because of poor CTA imaging. Of the remaining 928 assessable stents, ISR was identified in 86 stents on coronary angiography. CTA was used to identify 67 of 86 stents with ISR, although this procedure missed 19 stents with ISR. The sensitivity, specificity, false positive rate, false negative rate, positive predictive value, negative predictive value, and accuracy of CTA in evaluating ISR were 77.9%, 96.4%, 3.6%, 22.1%, 69.1%, 97.7%, and 94.71%, respectively. Statistical analyses did not reveal a difference between the two procedures. The positive and negative likelihood ratios were 21.87 and 0.229, respectively. No significance difference was found between the two methods ( $P>0.05$ ).

Table 2 shows that the results between CTA and coronary angiography regarding the

diagnosis of ISR in different locations of the coronary artery were not significantly different. Table 3 shows that an implanted stent with a larger diameter is associated with a lower incidence of ISR. Specifically, the restenosis rate of stents  $\leq 3$  mm in diameter was significantly higher than that of stents  $>3$  mm in diameter. In the group with stent diameters  $\leq 3$  mm, CTA differed from coronary angiography with regard to the diagnosis of ISR in the circumflex artery and therefore cannot replace coronary angiography. In the other two groups, the data were not significantly different.

The results also show that 6% of the reconstructed CT images of the stents  $>3$  mm in diameter scored between 3 and 4, whereas 12.0% of the reconstructed CT images of the stents  $\leq 3$  mm in diameter scored between 3 and 4. The imaging quality of CTA for the stents  $>3$  mm in diameter was significantly better than that for the stents  $\leq 3$  mm in diameter ( $p<0.05$ ).

**Table 1.** Comparison of ISR diagnosis results between coronary CTA and coronary angiography.

CTA	coronary angiography		total	P
	positive	negative		
positive	67	30	97	0.392
negative	19	812	831	
total	86	842	928	

**Table 2.** Comparison of ISR results between coronary CTA and coronary angiography in different locations.

item	a	b	c	d	P
left main coronary artery	8	2	1	67	0.807
left anterior descending coronary artery	29	13	10	304	0.723
left circumflex coronary artery	17	10	2	153	0.207
right coronary artery	13	5	6	288	0.865

**Table 3.** Comparison of ISR results of different diameter and length stents between coronary CTA and coronary angiography.

item		a	b	c	d	P
diameter	≤3	46	27	5	287	0.030
	3~4	14	10	6	342	0.534
	≥4	7	4	8	172	0.416

## DISCUSSION

PCI is the most direct and effective method for treating coronary heart disease. It has the advantages of reduced trauma and quick recovery, and it has been widely used in clinical practice. ISR is one of the most serious complications of PCI. Its main pathogenesis is mechanical damage and long-term stimulation by metal stents of the intima, which lead to hyperplasia of the intima cells. Elastic retraction of the blood vessels, intimal injury, and thrombosis can cause restenosis<sup>(12)</sup>. Fischman *et al.* suggested that the occurrence of restenosis among bare-metal stents (20% to 30%) and drug-eluting stents (5% to 10%) should not be ignored<sup>(13, 14)</sup>. Daemen *et al.* found that thrombosis can easily occur during the early period following PCI. The probability of ISR 4 weeks after PCI was only 0.2% to 0.6% per year<sup>(15)</sup>. However, ISR mostly occurs between 10 and 12 months after PCI. Moreover, approximately half of all patients with ISR after PCI have no apparent angina<sup>(16)</sup>. Therefore, assessment of stent patency and early detection of ISR after PCI are important to prevent myocardial ischemia and improve prognosis.

Currently, coronary angiography is the gold standard for coronary artery visualization and

the evaluation of stent patency after PCI. It can accurately display the entire coronary artery, including the anatomical location of the stent and the degree/scope of narrowing. However, this procedure is expensive, complicated to perform, and invasive, which can result in a painful experience for patients. Therefore, identification of a non-invasive, inexpensive, and simple-to-operate procedure for timely detection of ISR has been a research hotspot in the field of medical imaging.

Sixty-four-slice spiral CT scans can accurately, non-invasively, and stereoscopically display the morphology of blood vessels because of their ultrathin slice features and extremely high spatial resolution<sup>(17, 18)</sup>. CT scans have significant advantages in the diagnosis of coronary artery disease and can be considered a non-invasive modality for diagnosing coronary artery disease. This study demonstrates that CTA is consistent with coronary angiography in its evaluation of stent patency and ISR. The evaluation results of CTA for ISR, the negative predictive value, and the accuracy are similar to those of coronary angiography. Furthermore, because of its simple operation, convenience, efficiency, low cost, and low risk, CTA can be performed in outpatient clinics. Therefore, CTA can be considered an effective method for evaluating stent patency



after stenting<sup>(19,20)</sup>.

This study showed that the accuracy of coronary CTA in the diagnosis of ISR in the left main artery, anterior descending artery, circumflex artery and right coronary was high, producing results consistent with those of coronary angiography. However, a significant difference was noted between the two procedures (i.e., coronary CTA differed from coronary angiography with regard to the diagnosis of ISR in small-diameter stents), which may be associated with the larger blood supply area, larger anatomical variations, and the smaller diameter of the circumflex artery. Smaller-diameter implanted stents are associated with an increasing incidence of ISR. Stents with smaller diameters can easily produce artifacts that indicate poor CTA imaging quality and result in a higher misdiagnosis rate. Therefore, coronary angiography remains the recommended treatment for patients undergoing PCI using small-diameter stents. Some patients presented with recurrent angina symptoms after PCI, which may be related to the progression of coronary artery disease, ISR, or both. We recommend coronary angiography as the first choice for examination because a lesion can be treated immediately during the procedure.

Stent diameter is one of the important factors affecting the imaging quality of CTA. Stents with smaller diameters can easily produce artifacts and lead to poor imaging of the in-stent structure. These artifacts affect the assessment of the patency of the stent<sup>[20]</sup>. This study showed that the image quality of CTA coronary stents with stent diameters greater than 3 mm was significantly better than that of stents with diameters less than 3.0 mm. Table 3 shows that CTA of stents >3.0 mm is associated with adequate reconstructed images and shows higher specificity for the detection of ISR in target vessels. These results were consistent with those of coronary angiography, indicating that CTA coronary imaging can successfully evaluate ISR in stents >3 mm in diameter. For stents <3 mm in diameter, ISR evaluations via CTA are obviously limited.

This study has the following limitations. It was a single-center, retrospective case study that excluded patients with atrial fibrillation, a concurrent fast heart rate, and contraindications to beta blockers. Selection bias may have occurred with regard to patient enrollment. The follow-up period was brief. Previous studies have shown that the stent material is closely related to metal artifacts and is an important factor affecting the image quality of the stent structure during CTA<sup>(19,20)</sup>. Unfortunately, this study did not evaluate the application value of coronary CTA for diagnosing ISR in stents made of different materials.

## CONCLUSION

Sixty-four-slice spiral coronary CTA has the same accuracy as coronary angiography when assessing the patency of stents and has the following advantages: non-invasiveness, low cost, and simple and convenient operation. However, for stents <3 mm in diameter, ISR evaluations via CTA are obviously limited.

**Conflicts of interest:** Declared none.

## REFERENCES

1. Meliga E, De Benedictis M, Gagnor A, Belli R, Scrocca I, Lombardi P, Conrotto F, Aranzulla T, Varbella F, Conte MR (2012) Long-term outcomes of percutaneous coronary interventions with stent implantation in patients ≤40 years old. *Am J Cardiol*, **109**: 1717-1721.
2. Ishii H, Toriyama T, Aoyama T, Takahashi H, Tanaka M, Yoshikawa D, Hayashi M, Yasuda Y, Maruyama S, Matsuo S, Matsubara T, Murohara T (2012) Percutaneous coronary intervention with bare metal stent vs. drug-eluting stent in hemodialysis patients. *Circ J*, **76**: 1609-1615.
3. Holmes DR Jr, Leon MB, Moses JW, Popma JJ, Cutlip D, Fitzgerald PJ, Brown C, Fischell T, Wong SC, Midei M, Snead D, Kuntz RE (2004) Analysis of 1-year clinical outcomes in the SIRIUS trial: a randomized trial of a sirolimus-eluting stent versus a standard stent in patients at high risk for coronary restenosis. *Circulation*, **109**: 634-640.

4. Morice MC, Colombo A, Meier B, Serruys P, Tamburino C, Guagliumi G, Sousa E, Stoll HP, REALITY Trial Investigators (2006) Sirolimus- vs paclitaxel-eluting stents in de novo coronary artery lesions: the REALITY trial: a randomized controlled trial. *JAMA*, **295**: 895-904.
5. Ruygrok PN, Webster MW, de Valk V, van Es GA, Ormiston JA, Morel MA, Serruys PW (2001) Clinical and angiographic factors associated with asymptomatic restenosis after percutaneous coronary intervention. *Circulation*, **104**: 2289-2294.
6. Cutlip DE, Chauhan MS, Baim DS, Ho KK, Popma JJ, Carrozza JP, Cohen DJ, Kuntz RE (2002) Clinical restenosis after coronary stenting: perspectives from multicenter clinical trials. *J Am Coll Cardiol*, **40**: 2082-2089.
7. Juan YH, Huang YC, Sun Z, Hsieh IC, Chan WH, Chen CC, Hung KC, Wen MS, Wan YL (2014) The evolution and investigation of native coronary arteries in patients after coronary stent implantation: a study by 320-detector CT angiography. *Int J Cardiovasc Imaging*, **30**(1): 13-24.
8. Maintz D, Seifarth H, Flohr T, Krämer S, Wichter T, Heindel W, Fischbach R (2003) Improved coronary artery stent visualization and in-stent stenosis detection using 16-slice computed tomography and dedicated image reconstruction technique. *Invest Radiol*, **38**: 790-795.
9. Herzog C, Arning-Erb M, Zangos S, Eichler K, Hammerstingl R, Dogan S, Ackermann H, Vogl TJ (2006) Multi-detector row CT coronary angiography: influence of reconstruction technique and heart rate on image quality. *Radiology*, **238**: 75-86.
10. Lei Z, Gu J, Fu Q, Shi H, Xu H, Han P, Yu J (2013) The diagnostic evaluation of dual-source CT (DSCT) in the diagnosis of coronary artery stenoses. *Pak J Med Sci*, **29**: 107-111.
11. Gaspar T, Halon DA, Lewis BS, Adawi S, Schliamser JE, Rubinshtein R, Flugelman MY, Peled N (2005) Diagnosis of coronary in-stent restenosis with multidetector row spiral computed tomography. *J Am Coll Cardiol*, **46**(8): 1573-1579.
12. Park JJ, Chun EJ, Cho YS, Oh IY, Yoon CH, Suh JW, Choi SI, Youn TJ, Koo BK, Chae IH, Choi DJ (2014) Potential predictors of side-branch occlusion in bifurcation lesions after percutaneous coronary intervention: a coronary CT angiography study. *Radiology*, **271**: 711-720.
13. Fischman DL, Leon MB, Baim DS, Schatz RA, Savage MP, Penn I, Detre K, Veltri L, Ricci D, Nobuyoshi M, et al. (1994) A randomized comparison of coronary-stent placement and balloon angioplasty in the treatment of coronary artery disease. Stent Restenosis Study Investigators. *N Engl J Med*, **331**: 496-501.
14. Holmes DR Jr, Leon MB, Moses JW, Popma JJ, Cutlip D, Fitzgerald PJ, Brown C, Fischell T, Wong SC, Midei M, Snead D, Kuntz RE (2004) Analysis of 1-year clinical outcomes in the SIRIUS trial: a randomized trial of a sirolimus-eluting stent versus a standard stent in patients at high risk for coronary restenosis. *Circulation*, **109**: 634-640.
15. Daemen J, Wenaweser P, Tsuchida K, Abrecht L, Vaina S, Morger C, Kukreja N, Jüni P, Sianos G, Hellige G, van Domburg RT, Hess OM, Boersma E, Meier B, Windecker S, Serruys PW (2007) Early and late coronary stent thrombosis of sirolimus-eluting and paclitaxel-eluting stents in routine clinical practice: data from a large two-institutional cohort study. *Lancet*, **369**: 667-678.
16. Meliga E, De Benedictis M, Gagnor A, Belli R, Scrocca I, Lombardi P, Conrotto F, Aranzulla T, Varbella F, Conte MR (2012) Long-term outcomes of percutaneous coronary interventions with stent implantation in patients ≤40 years old. *Am J Cardiol*, **109**: 1717-1721.
17. Chung SH, Kim YJ, Hur J, Lee HJ, Choe KO, Kim TH, Choi BW (2010) Evaluation of coronary artery in-stent restenosis by 64-section computed tomography: factors affecting assessment and accurate diagnosis. *J Thorac Imaging*, **25**: 57-63.
18. Kong LY, Jin ZY, Zhang SY, Zhang ZH, Wang YN, Song L, Zhang XN, Zhang YQ (2009) Assessment of coronary stents by 64-slice computed tomography: in-stent lumen visibility and patency. *Chin Med Sci J*, **24**: 156-160.
19. Ligabue G, Rossi R, Ratti C, Favali M, Modena MG, Romagnoli R (2004) Noninvasive evaluation of coronary artery stents patency after PTCA: role of Multislice Computed Tomography. *Radiol Med*, **108**: 128-137.
20. Cademartiri F, Marano R, Runza G, Mollet N, Nieman K, Luccichenti G, Gualerzi M, Brambilla L, Coruzzi P, Galia M, Midiri M (2005) Non-invasive assessment of coronary artery stent patency with multislice CT: preliminary experience. *Radiol Med*, **109**: 500-507.