

# Safe chemotherapy and targeted therapy for treating locally advanced NPC in a G6PD-deficient patient: case report and literature review

Y.M Jiang and X.D. Zhu\*

Department of Radiation Oncology, Cancer Hospital of Guangxi Medical University, Nanning 530021, People's Republic of China

## ► Case report

## ABSTRACT

The article was first report a case of a 32-year-old female with NPC that is G6PD-deficient. The patient completed induction chemotherapy and concomitant chemoradiotherapy successfully. The patient experienced grade 1 neutropenia, grade 1 diarrhea, and grade 2 acne-like skin reactions during the three cycles of induction chemotherapy. Grade 1 neutropenia, grade 1 diarrhea, grade 2 oral mucositis and grade 1 skin reactions were observed during the concomitant chemoradiotherapy. No hemolytic events were observed. We conclude that it is safe for G6PD-deficient patients with NPC to received chemotherapy and targeted therapy.

**Keywords:** nasopharyngeal carcinoma, G6PD deficiency, chemotherapy, cetuximab, radiotherapy.

### \*Corresponding author:

Xiao-dong Zhu, PhD,

Fax: + 86 0771 5331466

E-mail:

zhuxiaodonggxmu@163.com

Revised: November 2018

Accepted: February 2019

Int. J. Radiat. Res., July 2019;  
17(3): 505-508

DOI: 10.18869/acadpub.ijrr.17.3.505

## INTRODUCTION

Glucose-6-phosphate dehydrogenase (G6PD) deficiency is the most common enzymopathy worldwide<sup>(1, 2)</sup>. The most significant of G6PD deficiency is hemolytic anemia. Unfortunately, some cancer patients also present with G6PD deficiency.

G6PD deficiency is a multiethnic inherited disease with a particularly high prevalence in tropical and subtropical regions, including southern China<sup>(3)</sup>. Nasopharyngeal carcinoma (NPC) is endemic in southern China. Radiotherapy with chemotherapy is the primary treatment for locally advanced nasopharyngeal carcinoma. However, chemotherapy is a challenging for NPC patients with G6PD deficiency due to the potential for oxidative stress. Unfortunately, there is a dearth of data describing this issue. Herein, we report a clinical case of an NPC patient with G6PD deficiency,

who had received chemoradiotherapy and targeted therapy successfully.

### Case presentation

A 32-year-old female clerk presented with a 1-month history of enlarged and growing lymph nodes in the right upper neck. Physical examination showed multiple enlarged lymph nodes located in the right upper neck. These enlarged lymph nodes were painless, firm and non-tender, with the largest measuring 4×3×2 cm. On nasopharyngoscopy, a mass was found in her nasopharynx and was biopsied. An MRI of the head and neck showed masses in the nasopharynx and in multiple lymph nodes in the II, III, IV, V and supraclavicular regions. Histopathological examination of the nasopharyngeal mass revealed that the patient had nasopharyngeal non-keratinizing undifferentiated carcinoma (T2N3M0, IVb stage).

In the premarital medical examination, the spectrophotometric test showed a low level of erythrocytic G6PD (2000 mU/g Hb; normal range, 3900–7800 mU/g Hb).

Concomitant chemoradiotherapy and induction chemotherapy/sequential therapy are the current standard treatments for patients with locally advanced head and neck cancer. These treatments have been shown to give improved survival and have the benefit of organ preservation<sup>(4,5)</sup>. The most effective induction chemotherapy regimen in patients with NPC is the combination of 5-fluorouracil (5-FU), docetaxel and cisplatin. Cetuximab has been shown to improve survival when used concurrently with radiotherapy in locoregionally advanced disease<sup>(6)</sup>. Velead *et al.*<sup>(7)</sup> reported a breast cancer patient with G6PD deficiency that was treated with docetaxel plus cyclophosphamide. Importantly, no hemolytic events were observed.

Despite the lack of literature data, we decided to use cetuximab, docetaxel, cisplatin and 5-fluorouracil to treat our patient because these agents were not predicted to elicit oxidative stress.

The induction chemotherapy treatment consisted of cetuximab administered by intravenous (IV) infusion over 1–2 h on days 1, 8 and 15 (loading dose of 400 mg/m<sup>2</sup> on day 1, then 250 mg/m<sup>2</sup> weekly). Docetaxel (60 mg/m<sup>2</sup>) and cisplatin (60 mg/m<sup>2</sup>) were given on day 2, followed by administration of 5-FU (600 mg/m<sup>2</sup>) as a continuous infusion for 5 days. This treatment regimen was administered every 3 weeks for three cycles.

As therapeutic doses of diphenhydramine should be used with caution in patients with G6PD deficiency, the patient was premedicated with steroids before receiving cetuximab. Thus, one day prior and one day after the docetaxel treatment, 10 mg of dexamethasone was administered. On the days with docetaxel treatment, the patient received 10 mg of dexamethasone and 50 mg of cimetidine to prevent hypersensitivity reactions. Tropisetron (5 mg, i.v.) was routinely given. The third cycle of TPF treatment and the eighth dose of

cetuximab were administered in September 2015 without any significant adverse reactions. The patient developed a cetuximab-induced rash six days after the first cetuximab treatment. The patient had grade 1 neutropenia, grade 1 diarrhea and grade 2 acne-like skin reactions during the three cycles of induction chemotherapy.

After induction chemotherapy, cisplatin was given at a dose of 100 mg/m<sup>2</sup> every 3 weeks for 3 cycles with radiotherapy. The patient was treated with radical external radiation therapy. The target volumes of the NPC and neck were irradiated with full-course intensity-modulated radiotherapy (IMRT). The gross volumes of the nasopharynx (GTVnx) and positive neck lymph node (GTVln-R/L) tumors were determined based on the borders of the primary nasopharyngeal tumor and involved lymph nodes. The clinical target volume (CTV1) included the GTVnx with a 5 to 10 mm margin. The clinical target volume (CTV2) covered CTV1 and high-risk local structures. The doses of each target area were as follows: 72.32 Gy for GTVnx, 71.04 Gy for GTVln-R, 70.06 Gy for GTVln-L, 60 Gy for CTV1 and 55.4 Gy for CTV2, with each dose being divided into 30–32 deliveries. The patient experienced grade 1 neutropenia, grade 1 diarrhea, grade 2 oral mucositis and grade 1 skin reactions during concomitant chemoradiotherapy. The therapeutic regimen was administered safely, and no hemolytic events were observed. Tumors shrink significantly after treatment (figure 1).

## DISCUSSION

G6PD deficiency is a hereditary abnormality in the activity of an erythrocyte enzyme. G6PD is essential for maintaining a normal life span in red blood cells and for oxidative processes. The most significant complication of G6PD deficiency is hemolytic anemia, which may be life-threatening. Typical clinical symptoms are jaundice, back pain, fatigue, tachycardia and tachypnea. Blood biochemistry results revealed a decrease in red blood cell counts,

reticulocytosis, and hemoglobin and increased lactate dehydrogenase and unconjugated bilirubin. Hemolysis can be triggered by infection, hyperglycemia and certain foods (i.e., fava beans) and medications. Some drugs should be avoided by all G6PD-deficient patients, such

as furazolidone, isobutyl nitrite, sulfacetamide, sulfapyridine and primaquine. Other medicines are reasonably safe for G6PD-deficient patients who do not present with non-spherocytic hemolytic anemia, such as acetaminophen, isoniazid, L-dopa and vitamin K <sup>(8)</sup>.

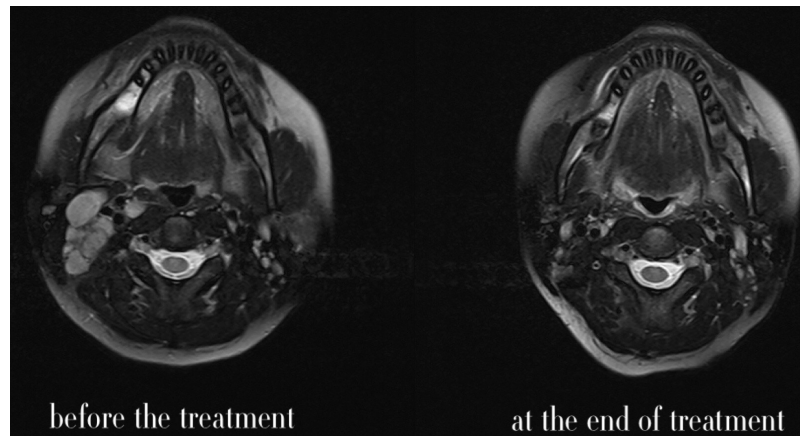


Figure 1. Cetuximab and chemoradiotherapy result in tumor regression.

NPC and G6PD deficiency both have a high prevalence in southern China. Radiotherapy and chemotherapy are the main therapeutic regimens for treating NPC; however, there are no literature reports describing the safety of NPC treatment in patients with G6PD deficiency.

The most common drugs recommended for use in NPC patients are docetaxel, cisplatin and 5-fluorouracil. Verde *et al.* <sup>(7)</sup> reported that they administered docetaxel and cyclophosphamide to a patient with G6PD deficiency who was diagnosed with breast cancer. Importantly, there were no safety issues or hemolytic events. Unfortunately, there are no literature reports describing the use of DDP and 5-FU in G6PD-deficient patients. DDP stops tumor growth by cross-linking the guanine bases in DNA double-helix strands, thereby directly attacking the DNA. This results in the two DNA strands being unable to uncoil and separate. 5-FU is a fluoropyrimidine anticancer drug. It exerts cytotoxic effects on cells by directly incorporating itself into the cell's DNA and RNA as well as by inhibiting the enzyme thymidylate synthase. The epidermal growth factor receptor (EGFR) is highly overexpressed in head and neck squamous cell carcinomas. Cetuximab

competitively inhibits the binding of epidermal growth factor (EGF) and other ligands, such as transforming growth factor- $\alpha$ . Cetuximab binding to the EGFR blocks phosphorylation and activation of receptor-associated kinases, resulting in cell growth inhibition, induction of apoptosis, decreased matrix metalloproteinase secretion and reduced vascular endothelial growth factor production <sup>(9)</sup>. Finally, none of these drugs are known to induce oxidative stress.

We evaluated the oxidative properties of several potential drugs before choosing the ones that were deemed safe for use in the treatment of our patient.

Induction chemotherapy and concomitant chemoradiotherapy are standard regimens for treating locoregionally advanced head and neck cancer. Docetaxel, cisplatin, 5-fluorouracil and cetuximab are commonly used for treating non-G6PD-deficient patients; however, data is not available for treating G6PD-deficient patients. Importantly, this treatment regimen was found to be safe and was successful in treating an NPC patient with G6PD deficiency. Several points should be noted from this work: 1, it is important to research the available data

on the oxidative properties of each potential oncological drug before using it. 2, one should carefully consider all the drugs in the treatment regimen, not just the anticancer drugs. 3, the simpler the safer.

We hope more doctors will report the successful treatment of cancer patients with G6PD deficiency. This will lead to more informed decisions when selecting a chemotherapy regimen for the treatment of G6PD-deficient cancer patients.

**Conflicts of interest:** Declared none.

## REFERENCES

1. Cappellini MD, Fiorelli G (1995) Glucose-6-phosphate dehydrogenase deficiency. *Postgraduate Medical Journal*, **71**: 1-7.
2. Nkhoma ET, Poole C, Vannappagari V, Hall SA, Beutler E (2009) The global prevalence of glucose-6-phosphate dehydrogenase deficiency: A systematic review and meta-analysis. *Blood Cells Molecules & Diseases*, **42**: 267-78.
3. Beutler E (2008) Glucose-6-phosphate dehydrogenase deficiency: a historical perspective. *Blood*, **111**: 16-24.
4. Posner MR, Hershock DM, Blajman CR, Mickiewicz E, Winquist E, Gorbounova V, et al. (2007) Cisplatin and Fluorouracil Alone or with Docetaxel in Head and Neck Cancer. *New England Journal of Medicine*, **357**: 1705-15.
5. Haddad RI and Shin DM (2008) Recent advances in head and neck cancer. *New England Journal of Medicine*, **359**: 1143-54.
6. Bonner JA, Harari PM, Giralt J, Azarnia N, Shin DM, et al. (2006) Radiotherapy plus Cetuximab for Squamous-Cell Carcinoma of the Head and Neck — NEJM. *New England Journal of Medicine*, **354**: 567-78.
7. La VN, Bramati A, Girelli S, Piva S, Moretti A, Sburlati P, et al. (2012) Safe chemotherapy and hormone therapy for treating early breast cancer in a glucose 6-phosphate dehydrogenase-deficient patient: case report. *Anti-cancer drugs*, **23**: 758-60.
8. Bulp J, Jen M, Matuszewski K (2015) Caring for Glucose-6-Phosphate Dehydrogenase (G6PD)-Deficient Patients: Implications for Pharmacy. *P&T*, **40**: 572-4.
9. Vincenzi B, Zoccoli A, Pantano F, Venditti O, Galluzzo S (2010) Cetuximab: from bench to bedside. *Current Cancer Drug Targets*, **10**: 80-95.