

Adaptive approach for nasopharyngeal carcinoma patients during Volumetric Modulated Arc Therapy treatment (VMAT)

B.I. Chibane^{1,2*}, F. Benrachi¹, M. Salah Bali²

¹Laboratoire de Physique Mathématique et Subatomique, Université des Frères Mentouri Constantine 1, Algeria

²Radiation Oncology Department, Athena Medical Center, Constantine, Algeria

ABSTRACT

► Short report

*Corresponding authors:

Bouchra Imene Chibane, Ph.D.,

E-mail:

bouchra.chibane@gmail.com

Revised: June 2019

Accepted: August 2019

Int. J. Radiat. Res., April 2020;
18(2): 369-374

DOI: 10.18869/acadpub.ijrr.18.2.369

Background: Patients with head-and-neck cancers receiving radiotherapy show significant anatomical and dosimetric changes, especially during the latter part of treatment. The aim of this study is to evaluate the dosimetric effects of an adaptive Volumetric Modulated Arc Therapy (VMAT) treatment protocol for patients with locally advanced nasopharyngeal cancer (NPC).

Material and methods: Ten patients treated with VMAT have benefited from a second computed tomography scan (CT2) after 15 fractions in order to apply a new adapted plan. A hybrid plan has been generated applying the original treatment plan configuration beam to the second CT scan. The dose-volume histograms (DVHs) of hybrid and adapted plans have been compared.

Results: At the end of the 3rd week of treatment, CT2 shows a considerable shrinkage of GTV N70 volume (45.2%) and a diminution of the left and right parotid glands volume (21.1%, 20.6% respectively). Compared to the initial plans, hybrid plans reveal that the dose delivered to target volume GTV N70 decreased by 15.2%, and the V₃₀ of the left and right parotid glands increased by 47.3% and 25.6% respectively. However, there is no significant difference for the D₂ of the brainstem and spinal cord. **Conclusion:** Our adaptive VMAT protocol improves dosimetric results in terms of GTV N70 coverage and nontoxic doses to parotid glands.

Keywords: Adaptive radiotherapy, nasopharyngeal cancer, Volumetric Modulated Arc therapy.

INTRODUCTION

Due to the nasopharyngeal carcinoma (NPC) anatomical and biological specificity, radiation therapy or chemo-radiotherapy has been recognized as a definitive treatment ⁽¹⁾.

Radiotherapy has evolved significantly passing from two-dimensional (2D) processing techniques to three-dimensional conformational (3D-RTC) ones. More recently, techniques using intensity modulation by inverse planning (IMRT, Arc therapy, and Tomotherapy) have made possible to conform the dose more precisely to the target volumes sparing the surrounding healthy tissues. The dose gradients created between the target volumes (TVs) and the

organs at risk (OARs) can be large implying more precise patient positioning. Indeed, a small displacement may cause large dose variations to TVs or to OARs. The advent of board imaging on a linear accelerator has opened the era of Image Guided Radiation Therapy (IGRT), which permits the regular acquisition of patient images in the treatment room and contributes at the treatment precision ⁽²⁾. Therefore, VMAT technique became a tool of choice in the treatment of complex shapes tumors of the head and neck cancers. Most VMAT plans are based on a single computed tomography (CT) scan obtained before the start of radiotherapy (RT). However, it has been demonstrated that patients with head-and-neck cancer receiving RT showed

significant anatomic changes due to the weight loss, the shrinkage of the primary tumor and/or involved lymph nodes, especially during the latter part of treatment. These changes could have potential dosimetric impact, when highly conformal treatment techniques are used ^(3,4). Repeated imaging and re-planning, with a single mid-treatment scan, are essential to evaluate dosimetric variations and to ensure adequate doses to TVs and safe doses to normal tissues ^(5,6). Adaptive radiation therapy (ART) according to tumor response and anatomic changes of normal structures becomes particularly important. Since 2000's, many studies have focused on ART for NPC patients. However, the optimal timing and frequency of re-planning remain unresolved ^(7,8).

In our study, we aim to evaluate anatomic and dosimetric factors that influence the need and the timing of re-planning for NPC patients, in order to implement a clinical routine of adaptive radiotherapy strategy.

MATERIALS AND METHODS

Patient characteristics

Ten consecutive patients, with loco-regionally advanced NPC treated with SIB-VMAT at the Department of Radiation Oncology, Athena Medical Center between October 2017 and February 2018 were enrolled in this study. Eligible patients were those newly diagnosed with NPC with T2, T3 or T4 and N1-N3 disease according to the 2002 American Joint Committee on Cancer (AJCC) staging classification ⁽⁹⁾. All The pretreatment information including history and physical examination, nasopharyngoscopy, chest X-ray, complete blood count, liver and renal biochemistry, contrast-enhanced CT and magnetic resonance imaging (MRI) of the head-and-neck region were obtained. No patient had distant metastatic disease, and all patients received a weekly cisplatin-based concurrent chemotherapy treatment. Patient characteristics are summarized in table 1.

Table 1. Patients characteristics

Characteristics	N=10
Age (mean) years	42.5 (24-66)
Sex (F,M) %	30%, 70%
T stage % T2, T3, T4	60%, 30%, 10%
N stage % N1, N2, N3b, N3c	10%, 70%, 10%, 10%
Dose Gy	SIB 54.0/59.4/70.0
Cisplatin	40 mg/m ²

Initial imaging and planning

All patients underwent immobilization with a five point's thermoplastic head-neck and shoulder mask. A reference CT scan of head and neck region were obtained using a 2,5 mm slice thickness with intravenous contrast enhancement, and images were transferred to a treatment planning system (TPS) (*Eclipse Version 11.1, Varian Medical Systems, USA*).

Target volumes were contoured slice by slice on the treatment planning CT images. The gross tumor volume (GTV) is defined as the gross extent of the tumor shown by imaging studies and physical examination. This includes the nasopharyngeal primary, retropharyngeal lymphadenopathy and all gross nodal disease. The high-risk clinical target volume (CTV) is defined as the GTV plus margin of potential microscopic spread. It includes the entire nasopharynx, retropharyngeal lymph nodal regions, clivus, skull base, pterygoid fossae, parapharyngeal space, inferior sphenoid sinus and posterior third of the nasal cavity and maxillary sinuses. Finally, a planning target volume (PTV), CTV plus margin of 5mm, was used to account for daily setup errors.

Treatment was delivered once daily, 5 fractions per week, over 6 weeks and 3 days. All targets were treated simultaneously. The gross tumor and lymph node metastasis, PTV70 received 70 Gy on 33 fractions with 2.12 Gy per fraction. Subclinical PTV59.4 (first echelon nodes or dissected neck area containing lymph node metastases) had 33 fractions of 1.8 Gy/fraction with a total 59.4 Gy. The low neck or

supraclavicular received 28 fractions of 1.8 Gy/fraction with a total 50.4 Gy⁽¹⁰⁾.

An initial plan was calculated using a dual arc 6MV X rays VMAT technique with a collimator rotation of 10°-15° and 350°-345°. The optimization of the dose distribution was achieved with the Varian-DVO "Dose Volume Optimization" algorithm (Version 11.0.31) and the final dose calculation was done with the Varian-AAA "Anisotropic Analytical Algorithm" (Version 11.0.31).

CT re-simulation and VMAT replanning

After fifteen fractions of the treatment course, a second simulation CT scan (CT2) was acquired. TVs and OARs were manually recontoured and their volumes recorded. The spatial relationship between the isocenters of the initial and the repeated CTs was established by using CT-CT image fusion based on bony structures, in order to eliminate setup errors between the two CT scans. This registration was used for considering anatomic changes and position differences of the target volume and OARs. Then, a second VMAT plan based on the new anatomy was generated and defined as Plan2 (CT2), which was used to complete the planned course of treatment.

the mid-treatment CT scan (CT2). A hybrid plan (HPlan) was generated for each patient by applying the beam configuration of Plan1 to the anatomy of the (CT2). Anatomical changes observed after 3 weeks of radiotherapy were compared between CT1 and CT2.

The hybrid technique reported by Hansen *et al.*⁽⁴⁾ was used to evaluate the dosimetric changes for GTV N70, parotid glands, brain stem, and spinal cord between Plan2 and HPlan. The DVHs were calculated, and the dosimetric comparison was performed for each patient.

RESULTS

Ten patients with NPC were investigated for volumetric and dosimetric changes occurring during the course of VMAT (figure1). Volumetric and dosimetric variations are summarized in table 2 and 3.

Table 2. Summary of volumetric variations results for OARs and target volume(mean±SD).

Parameter	CT1 (cm ³)	CT2 (cm ³)	change%
RPG	36.9±0.2	29.1±0.01	21.1
LPG	36.8±0.05	29.2± 0.03	20.6
GTV N70	44.0±10.3	24.1 ±1.4	45.2
V _(C1-C4)	1274.5±0.03	1202.1 ±0.05	5.7

*CT1= initial reference scan, CT2= reference scan after 15 fractions of treatment. RPG: Right parotid gland. LPG: Left parotid gland. GTV N70: Gross Tumor Volume Including lymph nodes. V (C1-C4): Cervical Volume between C1 and C4.

Table 3. Summary of dosimetric results for OARs and target volume(mean±SD)

Parameter	Plan1	Plan 2	HPlan	Plan2+HPlan
RPG V ₃₀ (%)	41.3±0.4	39.4±0.5	49.5±0	25.6%
LPG V ₃₀ (%)	49.1±0.9	40.6±0.03	59.8±2.01	47.3%
Brain stem D ₂ (Gy)	45.4±0.1	42.6±0.00	47.6±0.01	11.7%
Spinal cord D ₂ (Gy)	35.5±0.2	33.6±0.04	36.7±0.02	9.22%
GTV N 70 D ₉₅ (Gy)	99.2±0.1	99.1±0.01	84.0±0.05	15.2%

D95: dose delivered to 95% of the target volume; V30: the relative volume of the organ receiving 30Gy; D2: dose delivered to 2% of the organ. Plan 1: initial plan, Plan 2: adaptive plan, HPlan (Plan 1+CT2)

Dosimetric comparison

For the adapted plan (Plan 2), the D_{95} for the target volume (GTV 70N) was higher compared to the hybrid plan (HPlan) (table 3), whereas, the target volume dose increased in the Plan 2. The doses to some critical OARs, such as the spinal cord, the brainstem and the left and right parotid glands decreased (table 3). For the spinal cord, re-planning decreased the mean D_2 by 9.22%. However, there is no patient exceeding the tolerance dose of 45 Gy in HPlan. For the brainstem, the mean D_2 was higher in HPlan than in Plan 2 by 11.7%. The tolerance dose of 54 Gy for the brainstem was respected for all patients.

For the parotid glands, the V_{30} decreased in the adapted Plan2 with a diminution of 25.6% and 47.3%, for the right and left parotid respectively.

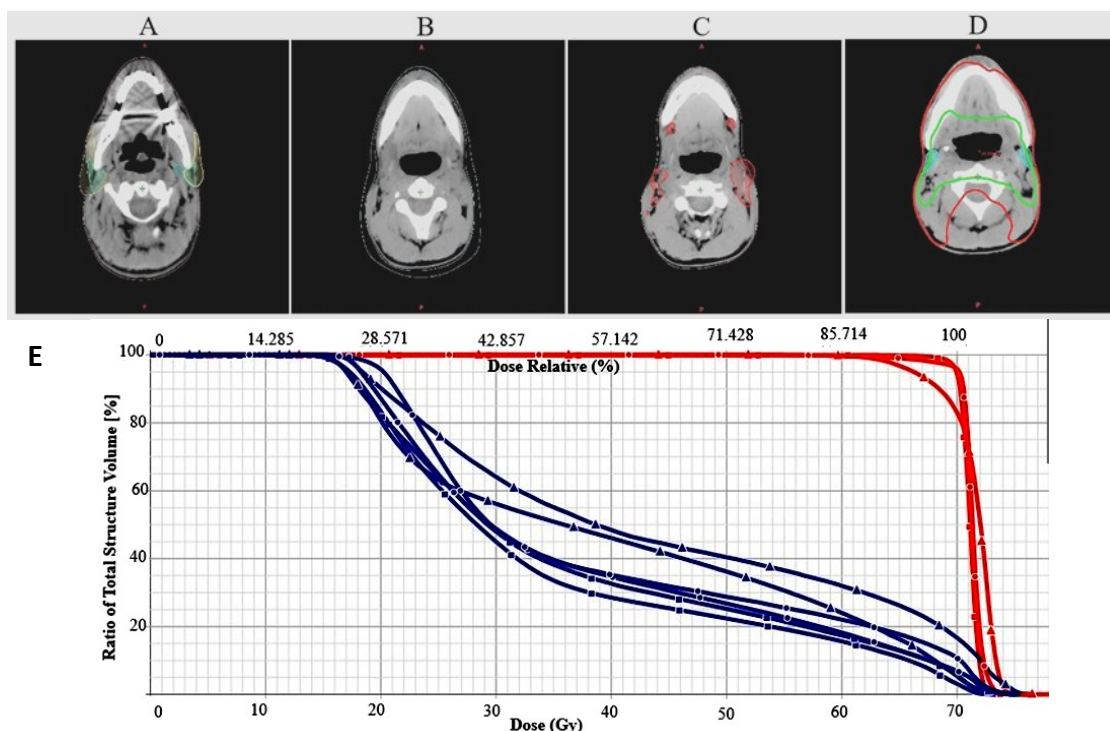


Figure 1. Volumetric and dosimetric changes: A) the parotid glands, B) V (C1-C4), C) GTV N 70, between CT1 and CT2. D) the shift of the both parotid glands toward the high-dose coverage region .E) Dose Volume Histogram summarizing dosimetric variation of the parotid glands (blue) and GTV N70 (red) during the three plans (Plan 1, Plan 2, HPlan).

DISCUSSION

Patients receiving RT to the head and neck regions are subject to significant anatomical changes during the seven-weeks of treatment course. Furthermore, many studies showed a different time point for CT2, Wang et al. suggested the necessity of a replanning before the 25th fraction for NPC patients⁽¹¹⁾. Zhao et al. reported their CT2 before the 20th fraction⁽¹²⁾. Head & Neck patients with large nodes receiving definitive chemo-radiotherapy, replanning may be considered at the commencement of the 3rd week for Brown et al.⁽¹³⁾.

In our investigation, we aim to highlight the benefits of replanning at the 15th fraction (the end of the 3rd week) by evaluating anatomical changes and their dosimetric consequences during the VMAT treatment of NPC patients.

Our results show that the average shrinkage volumes of left and right parotid glands were about 20.6%, and 21.1% respectively. This finding is analogous to the reported results in previous studies. Lu et al.⁽¹⁴⁾ noted an average

reduction of 35.1% and 24.6% for the right and left parotid glands respectively after 25 sessions. Fung et al.⁽¹⁵⁾ found an average decrease in parotid glands volume (47.54%) at the end of treatment with a daily reduction of 1.35%.

For the external contour volume ($V_{(C1-C4)}$), there is also a significant reduction (5.7%) explained by the patient's weight loss during treatment. This reduction contributes to the reduction of the parotid glands volume. Bhide et al.⁽¹⁶⁾ have found in their studies a modification on the external contour and a melting of the parotid glands, and a weight loss estimated at 7 to 10% in the end of treatment.

There is also a significant volume change of (45.2%) for GTV N70. This result differs from that reported by Zhao et al.⁽¹⁷⁾, who found no significant volume changes for GTV between initial CT and repeated one.

Various studies reported that the effect of volume changes of parotid glands is particularly important for patients with oro-and rhinopharynx tumors, in which the medial shift of the parotid glands corresponds to a shift

toward the high-dose coverage region (figure 1 (D))^(18, 19). In our study, similar dosimetric effects have been obtained. As consequence, the dose of the V_{30} for the left and right parotid glands increases of 47.3% and 25, 6% respectively. In addition, there is a significant decrease of the dose in GTV N70 (15.2%) and the physicians of our radiation oncology department decided to change the GTV N70 volume to ensure an adequate coverage for this high risk volume.

Moreover, the dosimetric comparison shows that there is no statistically significant difference for the D_2 of the brainstem and spinal cord between replanning and not replanning plan (table 2)⁽¹²⁾.

Our study shows that replanning for NPC patients after the 15th fraction during VMAT treatment, helps to ensure adequate dose coverage to the target volume GTV N70 and safe doses to both parotid glands.

CONCLUSION

The replanning treatment of a patient based on individual anatomic variations observed during irradiation is an attractive but challenging idea. Many strategies of adaptive RT are developed to facilitate the implementation in the clinical routine⁽²⁰⁾. Our adaptive radiotherapy protocol for NPC patients receiving VMAT shows that repeated CT imaging and replanning at 15th fractions during the course of radiotherapy is essential for identifying anatomical and dosimetric changes in order to deliver adequate doses to target volumes and safe doses to normal tissues.

Conflicts of interest: Declared none.

REFERENCES

1. Wang W, Feng M, Fan Z, et al. (2014) Clinical outcomes and prognostic factors of 695 nasopharyngeal carcinoma patients treated with intensity modulated radiotherapy. *Journal of Biomedicine and Biotechnology*, 1-10.
2. Marguet M (2009) Radiothérapie guidée par l'image : maîtrise des éléments matériels - application à l'analyse des conséquences dosimétriques dues aux variations anatomiques au cours de traitement ORL. Thèse de Doctorat, Université Toulouse III - Paul Sabatier - (2009).
3. Barker JL, Garden AS, Ang KK, et al. (2004) Quantification of volumetric and geometric changes occurring during fractionated radiotherapy for head-and-neck cancer using an integrated CT/linear accelerator system. *Int J Radiat Oncol Biol Phys*, **59(4)**: 960-970.
4. Vasquez Osorio E M, Hoogeman M S, Al-Mamgani A, et al. (2008) Local anatomic changes in parotid and submandibular glands during radiotherapy for oropharynx cancer and correlation with dose, studied in detail with nonrigid registration. *Int J Radiat Oncol Biol Phys*, **70(3)**: 875-882.
5. Hansen EK, Bucci MK, Quivey JM, et al. (2006) Repeat CT imaging and replanning during the course of IMRT for head-and-neck cancer. *Int J Radiat Oncol Biol Phys*, **64(2)**: 355-362.
6. Han C, Chen Y J, Liu A, et al. (2008) Actual dose variation of parotid glands and spinal cord for nasopharyngeal cancer patients during radiotherapy. *Int J Radiat Oncol Biol Phys*, **70(4)**: 1256-1262.
7. Fung WWK, Wu VWC, Teo PML (2012) Dosimetric evaluation of a three-phase adaptive radiotherapy for nasopharyngeal carcinoma using helical tomotherapy. *Med Dosim*, **37**: 92-97.
8. Huang H, Lu H, Feng, et al. (2015) Determining appropriate timing of adaptive radiation therapy for nasopharyngeal carcinoma during intensity-modulated radiation therapy. *Radiation Oncology*, **10**: 192.
9. Green FL, Page DL, Fleming ID, et al. (2003) Manuel de stadification du cancer de l'AJCC, 6e édition. *Annals of Oncology*, **14(2)**: 345-346.
10. Radiation Therapy Oncology Group (2003) A phase II study of intensity modulated radiation therapy (IMRT) +/- chemotherapy for nasopharyngeal cancer. RTOG 0225.
11. Wang W, Yang H, Hu W, et al. (2010) Clinical study of the necessity of replanning before the 25th fraction during the course of intensity-modulated radiotherapy for patients with nasopharyngeal carcinoma. *Int J Radiat Oncol Biol Phys*, **77(2)**: 617-621.
12. Zhao L, Wan Q, Zhou Y, et al. (2011) The role of replanning in fractionated intensity modulated radiotherapy for nasopharyngeal carcinoma. *Radioth and Oncol*, **98**: 23-27.
13. Brown E, Owen R, Harden F, et al. (2016) Head and neck adaptive radiotherapy: Predicting the time to replan. *Asia-Pacific Journal of Clinical Oncology*, **12(4)**: 460-467.
14. Fung WWK, Wu VWC, Teo PML (2014) Developing an adaptive radiation therapy strategy for nasopharyngeal carcinoma. *J of Radiat Res*, **55**: 293-304.
15. Lu J, Ma Y, Chen J, et al. (2014) Assessment of anatomical and dosimetric changes by a deformable registration method during the course of intensity-modulated radiotherapy for nasopharyngeal carcinoma. *J of Radiat Res*, **55**: 97-104.
16. Bhide SA, Davies M, Burke K, et al. (2010) Weekly volume and dosimetric changes during chemoradiotherapy with

intensity-modulated radiation therapy for head and neck cancer: a prospective observational study. *Int J Radiation Oncology Biol Phys*, **76(5)**:1360–1368.

17. Jin X, Han C, Zhou Y, *et al.* (2013) A modified VMAT adaptive radiotherapy for nasopharyngeal cancer patients based on CT-CT image fusion. *Radiat Oncol*, **8**: 277.
18. Ricchetti F, Wu B, McNutt T, *et al.* (2011) Volume change of selected organs at risk during IMRT for oropharyngeal cancer. *Int J Radiat Oncol Biol Phys*, **80(1)**: 161–168.
19. Chwartz D L and Dong L (2011) Adaptive radiation therapy for head and neck cancer-can an old goal evolve into a new standard. *J of Oncol*, 1–14.
20. Louvel G, Cazoulet G, Chajon E, *et al.* (2012) Radiothérapie guidée par l'image ET adaptative. *Cancer/ Radiothérapie*, **16**: 423-429.