

Investigation of the radioprotective effect of arbutin on radiation-induced lung injury in rats: a histopathological study

S.S.A. Jahanbani¹, A.H. Rezaeyan^{2*}, H. Ghaffari², A.R. Babae¹,
G.H. Haddadi³, M.M. Moeni⁴, A. Jomehzadeh⁵, S. Moatamedi⁶,
S.H. Eftekhar-Vaghefi^{1*}

¹Department of Anatomical Sciences, Afzalipour School of Medicine, Kerman University of Medical Sciences, Kerman, Iran

²Department of Medical Physics, School of Medicine, Iran University of Medical Sciences, Tehran, Iran

³Department of Radiology, School of Paramedical Sciences, Shiraz University of Medical Sciences, Shiraz, Iran

⁴Pathology and Stem Cell Research Center, Department of Pathology, Afzalipour Hospital, Kerman University of Medical Sciences, Kerman, Iran

⁵Department of Medical Physics, Kerman University of Medical Sciences, Kerman, Iran

⁶Department of physiology and pharmacology, Faculty of Medicine, Kerman University of Medical Sciences, Kerman, Iran

ABSTRACT

Background: Radiation-induced lung injury is a common complication after esophageal, breast, etc. cancer radiotherapy. We aimed to evaluate the radioprotective effect of arbutin on acute radiation-induced lung damage in male rats. **Materials and Methods:** Fifty-two male Wistar rats were divided into 4 groups: (i) control group (n = 10), (ii) vehicle group (n = 10, received distilled water intraperitoneally (ip)), (iii) X-irradiation only (n=16, chest was irradiated to a single dose of 20 Gy x-rays) and (iv) arbutin + X-irradiation (n=16, 75 mg/kg of arbutin 2 hours before irradiation (ip), and then their chest was exposed to 20 Gy x-rays). For histopathological investigation, 8 animals of each group were sacrificed 8 weeks after treatment and the rest of them were sacrificed 3 months after treatment. **Results:** The histopathological analysis in 8 weeks after X-irradiation showed that there was a significant increase in inflammatory in X-irradiation only group compared to control group. The administration of arbutin 2 hours prior to X-irradiation significantly reduced inflammation and inflammatory factors such as macrophages, mast cell and neutrophil in arbutin + X-irradiation group compared to X-irradiation only group (P<0.05). The histopathologic investigation performed 3 months after lung irradiation indicated a significant reduction in fibrosis formation in arbutin + X-irradiation group compared to irradiation only group (P<0.05). Localized chest X-irradiation with 20 Gy caused histopathologic damage to the lungs for short-term. **Conclusion:** Arbutin has a great potential in reducing the histopathologic damage to lung tissue after thoracic irradiation.

Keywords: Arbutin, lung irradiation, radioprotector, pneumonia, fibrosis.

► Original article

*Corresponding authors:

S.H. Eftekhar-Vaghefi, Ph.D.,

Abolhasan Rezaeyan, Ph.D.,

E-mail:

sheftekharv@yahoo.com

ahrezaeyan@gmail.com

Revised: August 2019

Accepted: September 2019

Int. J. Radiat. Res., July 2020;
18(3): 413-420

DOI: 10.18869/acadpub.ijrr.18.3.413

INTRODUCTION

Radiotherapy is known as one of the main non-surgical options for treating the

malignancies ⁽¹⁾. Despite recent advances in radiotherapy techniques, there is still risk of damage to healthy tissues ^(2, 3). Radiotherapy-induced side effects can be

divided into two categories: early (acute) and late radiation toxicity. Early effects occur during or within a few weeks after treatment, and late effects appear months to many years after exposure to radiation ⁽⁴⁾.

In radiotherapy for esophageal cancer, breast cancer, and lymphatic system cancer, the lungs are an important organ at risks (OARs) ^(4,5). On the other hand, Radiation-induced lung injury is considered as the main radiation dose-limiting factor in radiotherapy for lung cancer, breast cancer, lymphoma, etc. Radiation-induced lung toxicities are including pneumonia and fibrosis ^(4,5). Pneumonia is considered as an early effect of radiation that involves inflammatory response to capillary obstruction. In addition, pneumonia results in inflammatory cell infiltration such as neutrophils, macrophages, etc. into the alveolar wall and air sac. The severity of pneumonia induced by radiation directly depends on the radiation dose. Unlike pneumonia, radiation fibrosis is the late manifestation of radiation-induced lung injury and appears through the formation of collagen strands in alveoli wall ^(4,5).

Arbutin (hydroquinone- β -D-glucopyranoside) is a hydroquinone glycoside that is found abundantly in the food plants, fruits, and their products such as wheat, broccoli, stems, pepper, coffee, and shrubs. Its chemical formula is $C_{12}H_{16}O_7$ and its molecular weight is 272.25 g/mol ⁽⁶⁾. Arbutin plays an anti-apoptotic role in reducing production of intracellular hydroxyl radicals by scavenging the free radical activity ^(7,8). It is also used as a component in skin care products ⁽⁹⁾. High doses of the arbutin have the potential to become an antitumor agent ⁽⁶⁾. It has been reported that arbutin inhibits proliferation of TCC-SUP cells in bladder cancer by regulating high levels of p12 ⁽¹⁰⁾. In addition, arbutin can protect the liver against oxidative damage induced by carbon tetrachloride in rats ⁽¹¹⁾. As far as we know, the impact of arbutin on radiation-induced lung damage has not been investigated. Therefore, the purpose of this study was to evaluate the effect of arbutin on acute radiation-induced lung injury in 8 weeks and 3 months after X-irradiation in male rats.

MATERIALS AND METHODS

Animal

In this study, chemical materials including arbutin (CAS registry number: 497-76-7) were purchased from Sigma Chemical Co. (St. Louis, Mo, USA). Fifty-two adult male Wistar rats (mean weighting 220 ± 25 g, 10-12-week-old) were purchased from Neuroscience Research Center of Kerman, Iran. All rats were housed and maintained under specific pathogen-free conditions in facilities approved by National Institute of Health and Animal Atmosphere in Kerman University of Medical Sciences (KUMS), Kerman, Iran. These principles include characteristics of animal's natural life in captivity situation, using spacious cage, preparing appropriate ventilation and light, handling with care, given standard pellet diet and water ad libitum, etc., taking into account the 12-hour standby time, temperature of 25 ± 2 °C, relative humidity of 55 ± 5 %, and usual feeding of animals with sufficient diet without any additives. The study was approved by the ethics committee of KUMS, Kerman, Iran.

Experimental design

Fifty-two male Wistar rats were divided into 4 groups. Group 1 (n=10, control group) did not receive radiation and arbutin, group 2 (n=10, vehicle group) received distilled water intraperitoneally (i.p), group 3 (n=16) received a single dose of 20 Gy X-rays, and group 4 (n=16) received arbutin (75 mg/kg of arbutin 2 hours before irradiation (i.p)), and then their chest areas were exposed to 20 Gy X-rays. For histopathological investigation, 8 animals of each group were sacrificed 8 weeks after treatment and the rest of them were sacrificed 3 months after treatment.

Animal exposure

Prior to radiation exposure, all rats were anesthetized using Ketamine (Alphasan, Netherland Bv, 100 mg/kg) and Xylazine (Alfasan, Woerden, Holland, 0.5 mg/kg), and then these were placed on a transparent plate made of Prespex with a thickness of 1 cm. All

rats were immobilized in the supine position that positioning was facilitated by taping the extremities on a ventilated Prespex container. In all experiments, the thoracic regions of rats were irradiated with a 6 MV linear accelerator (Elekta Compact 6 MV, China) at Radiation Center of Shafa Hospital in Kerman, at a source-to-skin distance of 100 cm, with a field size of $5 \times 5 \text{ cm}^2$. A single dose of 20 Gy X-radiation was delivered to the whole chest regions at a dose rate of 350 monitor unite (MU). In the present study, single dose of 20 Gy was applied based on the results published by Buttner *et al.* that showed a single dose of 20 Gy can develop considerable radiation lung injury ⁽¹²⁾.

Arbutin (Sigma) was dissolved in distilled water (pH=7) and administered i.p 2 hours before irradiation. To obtain optimum radiation protective effect of arbutin, the dose of 75 mg/kg was selected for present study based on the reports by Mirshahvalad and colleagues ⁽¹¹⁾. They demonstrated that this dose has better protective effect against liver damage induced by carbon tetrachloride in rats ⁽¹¹⁾. To prepare this dose, 20 mg of arbutin was dissolved in 1 ml of distilled water.

Body weight measurement

Body weights were assessed for 4 groups at different times, pre-irradiation, 20 day, 2 months and 3 months after irradiation. Body weights assessed after irradiation were compared to baseline weight to investigate any relationship of body weight and treatment protocols.

Histopathological evaluation

For histopathologic examination, animals were anesthetized with Ketamine and Xylazine 8 weeks and 3 months after X-irradiation, and then chests were opened. The lung was perfused through right ventricle of the heart using 0.9% sodium chloride. Then, the lungs were separated and stored in formalin 10% after fixation of the samples in formalin and the tissue passage, which included insertion of samples into xylene and paraffin (Shimiran, Iran), respectively. The lungs were sliced into 5 micron thick sections and stained using Hematoxylin and Eosin (H &

E) ⁽¹³⁾, Massons Trichrome (MTC) ⁽¹⁴⁾ and Giemsa ⁽¹⁵⁾ methods. Stained patches were investigated under the light microscope (Olympus BX41TF, Japan) by a pathologist blinded to the samples. In general, several factors were considered as indicators of pulmonary injury. Descriptive factors of radiation-induced pulmonary damage include macrophage (excessive macrophage in the alveolar sac), inflammation (excessive inflammation in alveolar sac), neutrophil (excessive neutrophil counts in alveolar sac and alveolar), Lymphocyte (excess lymphocyte in alveolar lobe), mast cell (presence of mast cells in alveolar space), erythrocyte (excessive erythrocyte in alveolar wall) and fibrosis (the presence of collagen in alveolar sac). To quantify the data, the above-mentioned factors are shown as following: no increase (one), mild increase (two), average increase (three), and significant increase (four).

Statistical analysis

Statistical analysis was performed using SPSS 20.0 software (SPSS Inc., Chicago, IL, USA). Covariance analysis (ANOVA) and Tukey's post hoc test were used to investigate weight variation between groups. In histopathologic tests, Mann-Whitney Non- Parametric Bread Test was used and the groups were compared in two by two. Results were considered to be significant at P-value <0.05.

RESULTS

Body weight investigation

There was no significant difference in body weight between groups before irradiation. The results of body weight at different follow-up times are shown in table 1. In the first 20 days after irradiation, mean body weight significantly reduced in the X-irradiation and arbutin + X-irradiation groups while it increased in the control and vehicle groups ($P < 0.05$). Beyond 2 months follow-up, the mean body weights increased in the all study groups. In the third month, the mean body weights decreased in the X-irradiation and arbutin + X-irradiation groups while increase in average weight continued until

the third month in the other two groups. At the end of the third month, the mean weights in X-irradiation group and arbutin + X-irradiation group significantly decreased in comparison to the control group in the third month. Of note, there was no statistically significant difference ($P>0.05$) in average body weight between X-irradiation group and arbutin + X-irradiation group in the third month.

Histopathological examination

Lesions and pathologic changes in lung of rats in 8 weeks after irradiation are outlined in table 2. In this period, there was a statistically significant difference in terms of quality inflammation variables ($P=0.005$) and mast cell ($P=0.003$), macrophage ($P=0.006$), neutrophil ($P=0.004$), erythrocyte ($P=0.01$) lymphocyte with ($P=0.005$) between the X-irradiation group and control group. Meanwhile, a significant difference no found between X-irradiation group and control group for fibrosis. When the changes between X-irradiation group and arbutin + X-irradiation group were compared, there were statistically significant difference regarding the incidence of inflammation ($P=0.04$) and Mast cell ($P=0.005$) and presence of macrophage ($P=0.02$) and neutrophil ($P=0.02$), as displayed in figures 1 and 2.

Moreover, there was a significant difference

in all qualitative variables except fibrosis between the group receiving arbutin + X-irradiation and the control group. Besides, a significant difference in inflammation, macrophage, mast cell, and neutrophil was found between arbutin + X-irradiation and X-irradiation groups. Figures 1 and 2 illustrate the results of lung indexes of control rats versus experimental rats evaluated 8 weeks after local-thorax irradiations.

Table 3 summarizes the results of pathologic changes (lesions) in lungs of rats three months after irradiation, whereas histopathological changes are shown in figure 3 and 4. In 3 months follow-up, there was a statistically significant difference in fibrosis ($P=0.007$), inflammation ($P=0.05$), macrophage ($P=0.01$), erythrocyte ($P=0.04$) between X-irradiation group and control group. As observable in table 3, a significant difference in histopathological factors such as fibrosis ($P=0.04$) and erythrocyte ($P=0.05$) and macrophage ($P=0.005$) was observed between X-irradiation group and arbutin + X-irradiation group. In addition, there was no significant difference in histopathological factors except fibrosis ($P=0.02$) between arbutin + X-irradiation group and control group. Also, a significant difference was found between arbutin + X-irradiation group and vehicle group for fibrosis variables ($P=0.02$).

Table1. Effect of arbutin treatment on body weight of rats exposed to x-irradiation at follow-up times.

Group	Body weight (gr)			
	Before X-irradiation	20 days after X-irradiation	2 month after X-irradiation	3 month after X-irradiation
Control	203.5±14.3	222.5±18.1*	257.1±15.2*	322±18.1*
Vehicle	210.5±10.3	220±14.5*	266.8±25.5*	317.8±37.9*
X-irradiation	208±12.7	175.5±11.5*,**	229.8±18.6*	211.4±25.2**
arbutin + X-irradiation	207.2±11.4	182.1±10.8*,**	235±14.2*	214.5±7.7**

Values are expressed as the mean± standard deviation (SD). * statistically significant when compared to before X-irradiation.

Table 2. Effect of arbutin treatment at 8-week post-irradiation on histopathological factors in the lung tissue of rats.

	Control	Vehicle	X-irradiation	arbutin + X-irradiation
Inflammation	1.2 ±0.44	1.8±0.44	3.5±0.83 ^{ac}	2.5±0.54 ^{abc}
Macrophage	1.2±0.44	2± 0	3.1±0.71 ^{ac}	2.1±0.41 ^{abc}
Mast cell	1.2±0.44	1.4±0.54	3.8±0.41 ^{ac}	2.3±0.81 ^{abc}
Fibrosis	1.2±0.44	1.2±0.44	2.3±0.81	1.8±0.75
Lymphocyte	1.4±0.54	1.2±0.44	3.5±0.54 ^{ac}	2.6±1.03 ^a
Erythrocyte	1.6±0.54	1.8±0.83	3.1±0.75 ^{ac}	2.8±0.41 ^{ac}
Neutrophil	1.2±0.44	1.6±0.54	3.6±0.81 ^{ac}	2.6±0.51 ^{abc}

Values are expressed as mean±SD. $P<0.05$, statistically significant when compared between groups versus a control group, or b X-irradiation group, c Vehicle group. SD: Standard deviation.

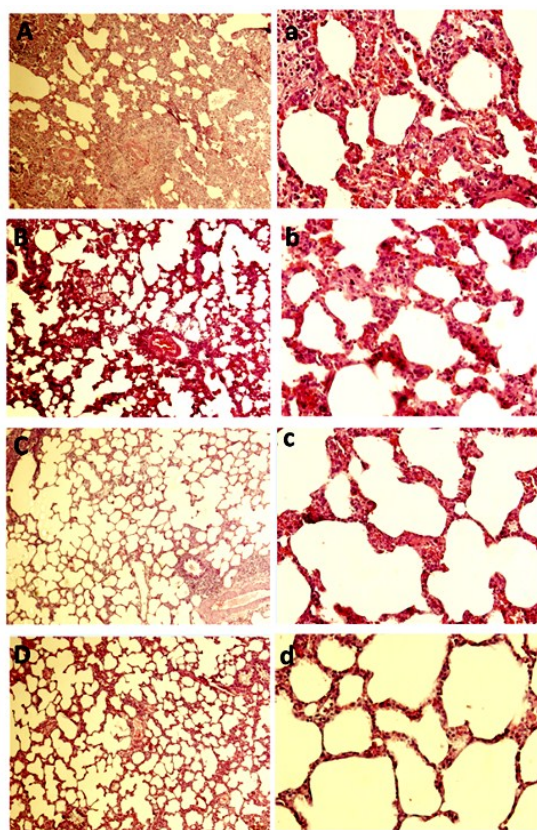


Figure 1. Histopathologic examination and radiation damage in 8 weeks after irradiation. Hematoxylin and Eosin stain with a magnification of $\times 100$ (capital letters) and $\times 400$ (lower case letters). **(A and a)** X-irradiation group: Acute inflammation in alveolar space, thickening of alveolar wall and pulmonary edema with inflammatory agents are evident. **(B and b)** arbutin+ X-irradiation group: mild inflammation. **(C and c)** Vehicle group: alveolar space, bronchiole, and vascular bed are normal. **(D and d)** Control group: Alveolar space, bronchiole, and vascular bed are normal.

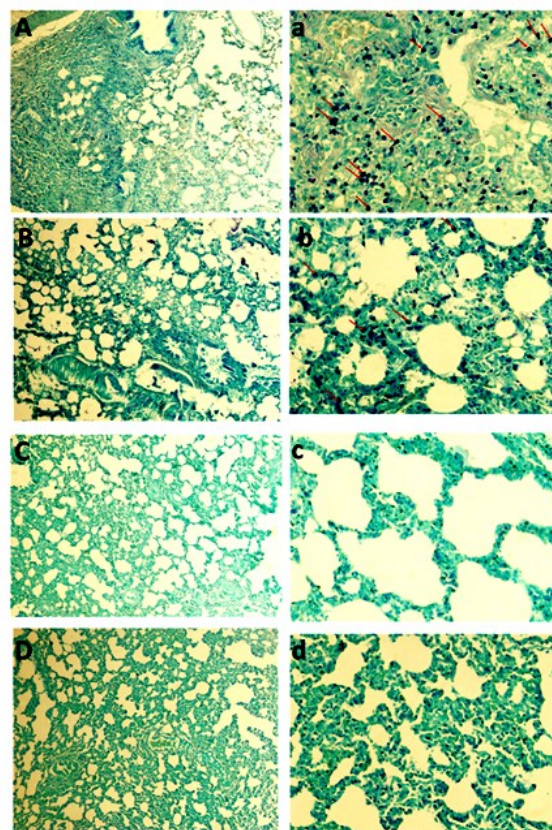


Figure 2. Histopathologic examination and radiation damage in 8 weeks after irradiation. Giemsa stain with a magnification of $\times 100$ (capital letters) and $\times 400$ (lower case letters). Mast cells are blue dots and the arrows indicate an accumulation of mast cell in lung tissue. **(A and a)** X-irradiation group: mast cell permeation is evident. **(B and b)** arbutin+ X-irradiation group: mast cell mucus is mild to moderate. **(C and c)** Vehicle group: alveolar space, bronchiole, and vascular bed are normal. **(D and d)** Control group: Alveolar space, bronchiole, and vascular bed are normal.

Table 3. Effect of arbutin treatment at 3-month post-irradiation on histopathological factors in the lung tissue of rats.

	Control	Vehicle	X-irradiation	arbutin + X-irradiation
Inflammation	1.2 \pm 0.44	1.4 \pm 0.54	3 \pm 0.71 ^a	2.2 \pm 0.83
Macrophage	1.4 \pm 0.54	1.4 \pm 0.54	2.8 \pm 0.44 ^{ac}	2 \pm 0.71 ^b
Mast cell	1.4 \pm 0.54	1.8 \pm 0.44	2.4 \pm 0.54	2.1 \pm 0.54
Fibrosis	1.4 \pm 0.54	1.4 \pm 0.54	3.6 \pm 0.54 ^{ac}	2.8 \pm 0.83 ^{abc}
Lymphocyte	1.4 \pm 0.54	1.4 \pm 0.54	2.2 \pm 0.83	2.2 \pm 1.09
Erythrocyte	2 \pm 0.71	1.6 \pm 0.54	3.2 \pm 0.83 ^{ac}	2.2 \pm 0.44 ^b
Neutrophil	1.2 \pm 0.44	1.4 \pm 0.54	2.4 \pm 0.54	2.2 \pm 0.54

Values are expressed as mean \pm SD. $P < 0.05$, statistically significant when compared between groups versus a control group, or b X-irradiation group, c Vehicle group. SD: Standard deviation.

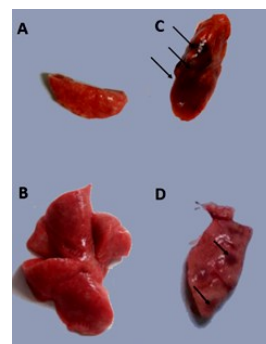


Figure 3. Macroscopic images of late pulmonary damage: **A** Control group: The lung is completely normal. **B** Vehicle group: The lung is completely normal. **C** X-irradiation group: The severe fibrosis represents as brown beads in the image (flash tip). **D** arbutin+ X-irradiation group: The mild to moderate fibrosis indicate by the black arrows.

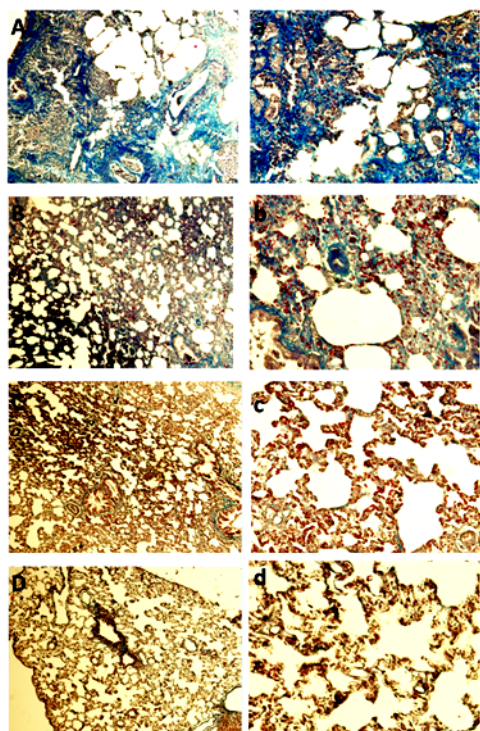


Figure 4. Histopathologic examination of radiation damage in 3 months after irradiation. Masson Trichrome stain with a magnification of $\times 100$ (capital letters) and $\times 400$ (lower case letters). Collagen sediment is shown in blue (**A and a**) X-irradiation group: Collagen fiber deposition is evident. (**B and b**) arbutin+ X-irradiation group: Collagen tissue deposition is observed moderately. (**C and c**) Vehicle group: alveolar space, bronchiole, and vascular bed are normal. (**D and d**) Control group: Alveolar space, bronchiole, and vascular bed are normal.

DISCUSSION

In the present study, rats were irradiated with a single dose of 20 Gy X-radiation alone or in the presence of arbutin to induce lung injury, and the effect of arbutin on radiation-induced lung injury was explored. The pathological changes occurs immediately after irradiation, but the clinical manifestations of radiation toxicity may not become apparent for weeks, months, or even years after radiation exposure. Regarding the lung, radiation-induced histopathological changes manifest at least 6 weeks after radiotherapy⁽¹⁶⁾. Accordingly, we investigated acute radiation-induced lung injury in 2 and 3 months after X-irradiation. Previous study showed that lung lesions were more predominant in the high doses⁽¹⁷⁾. As shown in

table 2 and 3, in a single dose of 20 Gy X-rays, we observed inflammation, fibrosis, etc.

In our study, the rats were irradiated with a single radiation dose of 20 Gy, and symptoms of decreased appetite and drinking water, and reduced physical activity such as movement and body cleaning were seen in them. In 20 days follow-up, we observed a significant reduction in body weight of X-irradiation and arbutin + X-irradiation groups in comparison with baseline body weights. These symptoms are very important because it can be a significant side effect of radiation exposure, that has a negative impact on absorption of food, and can lead to fatigue and weakness in patients after radiotherapy, and these effects reduce the likelihood of treatment, survival, and quality of life⁽¹⁸⁾.

As shown in table 2 and 3, radiation exposure increased the number of macrophages, neutrophils, lymph nodes and other inflammatory cells, as well as formation of collagen strands, resulting in inflammation 8 weeks after irradiation and fibrosis 3 months after radiation exposure. The administration of arbutin as IP injection 2 hours before irradiation, resulted in a reduction of inflammation and fibrosis, respectively, as displayed in figure 1, 2, and 4. Our data demonstrated that arbutin significantly reduced radiation-induced lung damages. The results from our study show that arbutin can be used to reduce acute inflammatory pathways induced by radiation exposure. Also, several reports have been suggested different types of biological radioprotectors such as probiotic and other bacterial-based radioprotectors for daily clinical applications⁽¹⁹⁾. The previous chemical radioprotectors may be replaced by biological radioprotectors in order to increase therapeutic outcome and reduce side effects associated with chemical radioprotectors.

Radiation-induced pulmonary fibrosis is considered as one of the common side effects after breast or lung cancer radiotherapy^(4,5). Released cytokines from macrophages that are activated in inflammatory process stimulate proliferation of fibroblasts and production of collagen. Also, macrophages release

anti-inflammatory cytokines including IL-4, IL-10, IL-13 and TGF- β that promote fibrosis^(20, 21). Mast cells help to penetrate inflammatory cells of alveolar inflammation by releasing enzymes and active amines that are rich in granules through vascular periosteum⁽²²⁾.

Studies have shown that mast cells have a critical role in fibrosis⁽²³⁾. Animal studies have been demonstrated the increased number of mast cells and neutrophils in the radiation-induced pulmonary fibrosis⁽²⁴⁾. In addition, migration of inflammatory monocytes (bone marrow-derived inflammatory monocyte) into the lungs occurs after radiotherapy. A recent study by Groves et al. showed that CCR2⁺ infiltrating monocyte-derived macrophages had a great role in the development of radiation-induced pulmonary fibrosis⁽²⁵⁾. Based on the results from our study, the number of mast cells, neutrophils, and macrophages were increased after X-irradiation. As shown in table 2 and 3, we observed a reduction in the number of mast cells, neutrophils, and macrophages in rats that were irradiated with a single dose of 20 Gy of X-ray 2 hours after IP injection of arbutin. Therefore, we propose that arbutin might be a potential lung radioprotector. Moreover, Radioprotective effects of arbutin on rat bone and human lymphoma U937 cells were explored^(7, 26, 27). The frequencies of micronuclei in 1000 polychromatic erythrocyte were significantly reduced using administration of arbutin before irradiation in mice bone marrow compared to control group⁽²⁶⁾. Arbutin can reduce intracellular hydroxyl radical production, and Bax-mitochondrial pathway including JNK/p38 MAPK activation in U937 cells, and therefore decreases X-irradiation-induced apoptosis⁽⁷⁾.

CONCLUSION

This study showed that arbutin improves symptoms of inflammation by reducing accumulation of macrophages. From our data, it can be concluded that arbutin can reduce the risk of radiation-induced lung injury in rat and acts as a lung radioprotector. Further *in-vitro*

and *in-vivo* studies are required to approve this effect and elucidate signaling pathways involved in the process of lung radioprotective effect of arbutin.

ACKNOWLEDGMENT

The authors greatly would like to thank Vice Chancellor of Research of Kerman University of Medical Sciences for authorizing and funding this study.

Conflicts of interest: Declared none.

REFERENCES

1. Ringborg U, Bergqvist D, Brorsson B, et al. (2003) The Swedish Council on Technology Assessment in Health Care (SBU) systematic overview of radiotherapy for cancer including a prospective survey of radiotherapy practice in Sweden 2001--summary and conclusion. *Acta oncologica*, **42**: 357-365.
2. Greenberger JS (2009) Radioprotection. *In vivo*, **23**: 323-336.
3. Ghaffari H, Beik J, Talebi A, et al. (2018) New physical approaches to treat cancer stem cells: a review. *Clin Transl Oncol*, **20**: 1502-1521.
4. Hanania AN, Mainwaring W, Ghebre YT, et al. (2019) Radiation-induced lung injury: assessment and management. *Chest*, **156**: 150-62.
5. Giridhar P, Mallick S, Rath GK, et al. (2015) Radiation induced lung injury: prediction, assessment and management. *Asian Pac J Cancer Prev*, **16**: 2613-7.
6. Khanal T, Kim HG, Hwang YP, et al. (2011) Role of metabolism by the human intestinal microflora in arbutin-induced cytotoxicity in HepG2 cell cultures. *Biochemical and Biophysical Research Communications*, **413**: 318-324.
7. Wu L-H, Li P, Zhao Q-L, et al. (2014) Arbutin, an intracellular hydroxyl radical scavenger, protects radiation-induced apoptosis in human lymphoma U937 cells. *Apoptosis*, **19**: 1654-1663.
8. Takebayashi J, Ishii R, Chen J, et al. (2010) Reassessment of antioxidant activity of arbutin: multifaceted evaluation using five antioxidant assay systems. *Free Radic Res*, **44**: 473-8.
9. Chakraborty AK, Funasaka Y, Komoto M, et al. (1998) Effect of arbutin on melanogenic proteins in human melanocytes. *Pigment Cell Res*, **11**: 206-12.

10. Li H, Jeong YM, Kim SY, et al. (2011) Arbutin inhibits TCCSUP human bladder cancer cell proliferation via up-regulation of p21. *Pharmazie*, **66**: 306-9.
11. Mirshahvalad S, Feizi F, Barkhordar A, et al. (2016) Hepatoprotective Effects of Arbutin against Liver Damage Induced by Carbon Tetrachloride in Rats. *Jundishapur J Nat Pharm Prod*, **11**: e33392.
12. Buttner C, Skupin A, Reimann T, et al. (1997) Local production of interleukin-4 during radiation-induced pneumonitis and pulmonary fibrosis in rats: macrophages as a prominent source of interleukin-4. *American Journal of Respiratory Cell and Molecular Biology*, **17**: 315-25.
13. Gamble M (2008) Theory and practice of histological techniques. 6 ed. Philadelphia: *Churchill Livingstone/Elsevier*, 121-134.
14. Jones ML, Bancroft JD, Gamble M (2008) Theory and practice of histological techniques. 6 ed. Philadelphia: *Churchill Livingstone/Elsevier*, 135-160.
15. Simoes JP and Schoning P (1994) Canine mast cell tumors: a comparison of staining techniques. *Journal of Veterinary Diagnostic Investigation*, **6**: 458-65.
16. Stone HB, Coleman CN, Anscher MS, et al. (2003) Effects of radiation on normal tissue: consequences and mechanisms. *Lancet Oncol*, **4**: 529-36.
17. Tabarraei Y, Bakhshandeh Z, Behrouzkhia Z, et al. (2014) Short-term changes in histopathological markers of irradiated rat's lung: preliminary study. *Research Journal of Pharmaceutical, Biological and Chemical Sciences*, **5**: 307-315.
18. Platek ME, Reid ME, Wilding GE, et al. (2011) Pretreatment nutritional status and locoregional failure of patients with head and neck cancer undergoing definitive concurrent chemoradiation therapy. *Head Neck*, **33**: 1561-8.
19. Najafi M, Shirazi A, Motevaseli E, et al. (2017) Melatonin as an anti-inflammatory agent in radiotherapy. *Inflammopharmacology*, **25**: 403-413.
20. Kolivand S, Amini P, Saffar H, et al. (2019) Evaluating the radioprotective effect of curcumin on rat's heart tissues. *Curr Radiopharm*, **12**: 23-28.
21. Farhood B, Mortezaee K, Goradel NH, et al. (2019) Curcumin as an anti-inflammatory agent: Implications to radiotherapy and chemotherapy. *J Cell Physiol*, **234**: 5728-5740.
22. Najafi M, Shirazi A, Motevaseli E, et al. (2019) The melatonin immunomodulatory actions in radiotherapy. *Biophysical Reviews*, **9**: 139.
23. Veerappan A, O'Connor NJ, Brazin J, et al. (2013) Mast cells: a pivotal role in pulmonary fibrosis. *DNA and cell biology*, **32**: 206-218.
24. Haston CK, Begin M, Dorion G, et al. (2007) Distinct loci influence radiation-induced alveolitis from fibrosing alveolitis in the mouse. *Cancer Res*, **67**: 10796-803.
25. Groves AM, Johnston CJ, Williams JP, et al. (2018) Role of infiltrating monocytes in the development of radiation-induced pulmonary fibrosis. *Radiat Res*, **189**: 300-311.
26. Nadi S, Monfared AS, Mozdarani H, et al. (2016) Effects of arbutin on radiation-induced micronuclei in mice bone marrow cells and its definite dose reduction factor. *Iran J Med Sci*, **41**:1 80-5.
27. Nadi S, Banaei A, Mozdarani H, et al. (2020) Evaluating the radioprotective effect of arbutin on mice exposed to megavoltage X-rays based on hematological parameters and lymphocytes micronucleus assay. *Int J Radiat Res*, **18**:2 275 -282.