

The effect of 900-MHz radiofrequency electromagnetic fields during the adolescence on the histological structure of rat testis and its androgen and estrogen receptors localization

F.M. Gur^{1*}, A. İkinci Keles¹, H.S. Erol², C. Guven³, E. Taskin^{3,4},
H. Kaya⁵, H.E. Gur⁶, E. Odaci⁷, M.B. Halici⁷, S. Timurkaan⁸

¹Department of Histology-Embryology, Faculty of Medicine, Niğde Ömer Halisdemir University, Niğde, Turkey

²Department of Biochemistry, Faculty of Veterinary Medicine, Kastamonu University, Kastamonu, Turkey

³Department of Biophysics, Faculty of Medicine, Niğde Ömer Halisdemir University, Niğde, Turkey

⁴Department of Biophysics, Faculty of Medicine, Çukurova University, Adana, Turkey

⁵Department of Electrical and Electronics, Faculty of Engineering, Karadeniz Technical University, Trabzon, Turkey

⁶Department of Histology-Embryology, Faculty of Medicine, Erciyes University, Kayseri, Turkey

⁷Department of Biochemistry, Faculty of Veterinary Medicine, Ataturk University, Erzurum, Turkey

⁸Department of Histology-Embryology, Faculty of Veterinary Medicine, Firat University, Elazığ, Turkey

ABSTRACT

Background: Mobile phones as an electronic device which are emitting radiofrequency-electromagnetic field (RF-EMF). In this study was intend to determine the contingent effects of cell phone induced RF-EMF on testicular tissue in adolescence. **Materials and Methods:** Rats in the RF-EMF group were exposed to 900 MHz RF-EMF, while sham and control rats were not. After the completion of the test steps, the testicular tissues which were rapidly removed from the body of sacrificed rats were examined by using histopathological and biochemical methods. Testicular tissues cut to 5 µm thickness undergo routine histological procedures. Thus, histopathological evaluation will be completed. Malondialdehyde (MDA), glutathione (GSH), catalase (CAT) and superoxide dismutase (SOD) levels in testicular tissues were measured by biochemical methods to determine whether oxidative stress occurred or not. **Results:** Histopathologic findings were not observed in any of the studied groups. There was also no difference between the groups in terms of localization of androgen and estrogen receptors. The incidence of apoptotic index and TUNEL-positive cells was similar in all three groups. In the RF-EMF group, although the levels of MDA and CAT were significantly higher, GSH levels were lower than the other groups. There was no essential difference between the groups in terms of SOD level. **Conclusions:** The obtained results of this study showed that exposed to 900 MHz RF-EMF in adolescents caused oxidative stress in the testes, but testicular damage which is caused to oxidative stress is remained too low to be detected by histopathological methods in this study.

Keywords: Androgen receptor, apoptosis, electromagnetic field, estrogen receptor, testis.

► Original article

*Corresponding authors:

Fatih Mehmet Gür, PhD.,

E-mail:

histolog44@gmail.com

Revised: March 2020

Accepted: April 2020

Int. J. Radiat. Res., January 2021;
19(1): 135-144

DOI: 10.29252/ijrr.19.1.135

INTRODUCTION

Mobile phone is a technological device that has become a crucial part of daily life. The

increase of using mobile phones in recent years has led scientists to investigate the possible effects of electromagnetic waves which is emitted by these devices on human health. Some

studies reported that RF-EMF which arise from mobile phones and base stations may seriously affect human health. It has been appeared that the severity of these effects may vary depending on RF-EMF exposure conditions, duration, tissue type, gender, energy level of RF-EMF radiation, and specific absorption rate ⁽¹⁻³⁾. Moreover, according to few studies it has been reported that 900 MHz RF-EMF may cause oxidative stress and apoptosis in cells ^(4,5). There is a controversion about the possible effects of RF-EMF on testicular tissue. In some studies, exposure to 900 MHz RF-EMF has been reported to cause pathological effects in testicular tissue such as non-thermal stress, increased apoptosis in spermatogenic cells, decrease in seminiferous tubular diameter and seminiferous epithelial thickness ^(1,6,7). In other studies to detect the effects of mobile phones on male reproductive health, 850-1900 MHz RF-EMF has been reported to cause problems which are hypospermatogenesis, decreased sperm count and motility, maturation arrest, tubular necrosis, and infertility ⁽⁸⁻¹¹⁾. On the contrary, many studies have shown that 900 MHz RF-EMF has no negative effect on testes and male reproductive health ^(3,12).

Today, it is accepted that estrogens and androgens have essential roles in germ cell development and meiosis ^(13,14). Androgens and estrogens mainly form their effects via binding-activated nuclear receptors. ^(15, 16). Studies have shown that pathological disorders such as functional deficiencies and absence of sex hormone receptors may cause infertility ^(13, 17,18). Therefore, it is important to investigate that the exposure to 900 MHz RF-EMF whether affects AR and ER receptor expression in testicular tissue or not, especially in adolescence, in order to reveal the causes of possible negative effects of EMF in the testis.

Studies on the effects of RF-EMF on the testis are generally involve in adulthood ^(1, 2, 4, 5, 7, 8, 10, 12, 19). Adolescent studies are very limited ^(3, 20, 21). As is known, adolescence is the period in which testicular tissues develop and differentiate and sperm production begins. Since tissues and organs have not yet developed properly in this period, they may be more sensitive to the effects

of RF-EMF ^(20,22-24). Mobile phones around the world serve between 800-2200 MHz radio frequencies. The frequency of the mobile phone in Turkey and Europe ranges between 880-960 MHz. For this reasons, in the study, possible effects of 900 MHz RF-EMF on adolescent rat testicular tissue were evaluated by using histopathological and biochemical methods.

MATERIALS AND METHODS

The experimental procedures were carried out with the approval of the Local Ethics Committee of Animal Experiments of Karadeniz Technical University (KTU) (Date: 17.06.2014, Protocol Number: 2014/32).

Animals

Eight rats are randomly selected for each group in twenty-four Sprague Dawley rats, aged 21 days, purchased from KTU Surgical Practice and Research Center and RF-EMF, sham and control groups were formed. During the study, the rats were kept in air-conditioned rooms with 12 hours of light and 12 hours of darkness. Also, water and food are unlimitedly served. The adolescent period in rodents is divided into three periods as early (postnatal 21 to 34 days old), mid (postnatal 34 to 46 days old) and late (postnatal 46 to 59 days old) ⁽²⁴⁾. Testicular development in rats is almost completed in the mid-adolescent period, and by the end of this period, the first sperm produced in the testes are thrown into the lumen of the seminiferous tubule ⁽²⁵⁾. This study continued from the beginning of early adolescence period to the end of mid adolescence period. RF-EMF and sham rats were kept in RF-EMF cages for 1 hour per day. At this one-hour period, RF-EMF rats were exposed to 900 MHz RF-EMF, whereas sham group rats were not exposed. Control group rats did not undergo any procedure. Experimental applications were terminated when rats reached 46 days of age.

RF-EMF application system

RF-EMF applications were realised in a special room that particularly prepared for this

purpose in KTU Surgical Applications and Research Center. The rats were kept in a plexiglass cage (size 30 cm × 42 cm × 50 cm) during RF-EMF implementation. The cage had the size of the floor space (126 cm floor space) where rats could move freely. RF-EMF rats in the cage were exposed to 900 MHz RF-EMF for one hour between 11:00 and 12:00 each day. On the other hand, sham group that were placed in the same cages between 10:00 and 11:00 each day. However, they are not faced with any kind of implementation. During the study, measurements were made prior to each application to determine whether there was an external RF-EMF in different parts of the room where the application was performed ⁽²⁶⁾. An oscillator (1218-BV, Lockable Oscillator, 900-2000 MHz, General Radio Company, Concord, Massachusetts, USA, Serial No. 1483) with an output power of approximately 300 mW and a frequency set to 900 MHz for the generation of RF-EMF of 900 MHz in the cage. An uninterruptible constant power supply (1267-B Regulated Power Supply, General Radio Company, Concord Massachusetts, USA, Serial No. 903) was used for both the operation of the oscillator and the continuous supply of energy. The output of the oscillator was connected to a half-wave dipole antenna made of a copper rod with a length of 15 cm and a diameter of 1 mm by means of a coaxial cable. The antenna was placed on a rod fixed between the right and left edges of the cage about 11 cm from the upper open surface of the cage ⁽²⁶⁾.

Humidity, temperature and RF-EMF density measurements

Humidity, temperature and RF-EMF density values were measured in daily. Detailed data on these measurements and data on the Specific Absorption Rate (SAR, 0.01 W / kg) are indicated in the previous study ⁽²⁶⁾.

Histological procedures

All rats were sacrificed by cervical dislocation after the experimental applications ended. The right and left testes, which were quickly removed from the body, were divided into two equal parts. One half of the right and left testes

were separated for biochemical analysis, and the other half was immersed in Bouin's solution for histopathological analysis and fixed at room temperature for 36 hours. Fixated tissues were embedded in paraffin through routine histological procedures. Paraffine blocks cut by microtome thickness of 5µm were stained with Hematoxylin & Eosin (H&E) method. The diameter of the seminiferous tubules and the thickness of the seminiferous epithelium were determined by measuring the six most rounded seminiferous tubules in different areas on each histological slide that using the Olympus cellsens standard program (version1.17) on an X20 objective. Histopathological examinations were performed using Olympus BX-53 microscope and photographs were taken with this microscope camera (DP 80 Olympus Japan).

Immunohistochemistry

Sections were incubated for 1 hour in a 60 °C oven to ensure stronger adhesion of the slides to the tissue, followed by a series of xylol and alcohol. In order to remove endogenous peroxidase, tissue sections were kept in 3% hydrogen peroxide (H₂O₂) (prepared with methanol) for 10 minutes and then washed in distilled water (5 minutes). The antigen retrieval protocol began by transferring tissue sections to the plastic coplin jar containing 0.01M citrate buffer (pH 6.0). The koplin jar was placed at the midpoint of the rotating platform of the microwave oven and heated four times in succession for five minutes at 600W. The amount of buffer in the coplin jar was controlled and the reduced fraction was completed with distilled water in every five minutes.

The sections removed from the microwave then allowed to cool to room temperature for 20 minutes. Antigen retrieval was completed by washing the cooled tissue sections in PBS (phosphate buffered saline) for 5 minutes. Sections washed in PBS after antigen retrieval protocol, 10% normal goat or rabbit serum was incubated at room temperature (10 minutes) to prevent nonspecific antibody binding.

To determine the localizations of AR, ERα and ERβ, tissue sections were incubated with primer antibodies in a humidified chamber at 4 °C for

16-20 hours and respectively for rabbit anti-AR (PG-21, androgen receptor polyclonal antiserum, 06-680 upstate, lot: JBC1381969), rabbit anti-Er α (estrogen receptor alpha polyclonal antiserum, bs-2098R, Bios, lot: 9K01V2) and mouse anti-Er β (estrogen receptor beta monoclonal antiserum, sc-390243; Santa Cruz, CA, lot: B2217). Before this procedure, PG-21 was diluted 1: 100 while primary antibodies of ER α and ER β were diluted 1: 200.

For negative control, PBS was used instead of primary antibody (figure 4J, K, L). Subsequently, it was incubated with biotinylated secondary antiserum for 1 hour and then with streptavidin horseradish peroxidase for 1 hour in a 37 °C humid environment. Sections were washed with PBS solution for 10 minutes before each incubation. Sections were then immersed in AEC (3-amino-9-ethylcarbazole) chromogen substrate, washed with distilled water, stained with hematoxylin (10 minutes) and covered with mounting medium. After, tissue sections were examined by microscope and photographed.

TUNEL (Terminal deoxynucleotidyl transferase dUTP nick end labeling) assay

Apoptosis was determined by examining deparaffinized testis tissue sections by TUNEL analysis. For this, the In Situ Cell Death Detection Kit was used according to the manufacturer's (Roche) instructions. Tissue sections were examined by fluorescence microscope and photographed. TUNEL positive cell number; was obtained by counting apoptotic cells in 50 seminiferous tubules in each animal (in one tissue section for each animal) of RF-EMF, sham and control rats (counted total 400 seminiferous tubules in each group). The apoptotic index (AI) of each group was determined by calculating the the average number of apoptotic cells in 400 seminiferous tubules. (AI = total TUNEL positive cells number in four hundred seminiferous tubules / 400).

Biochemical procedures

For biochemical analyzes, tissue samples (0.5 g) which taken from each rat were homogenized (4.5 ml) using an appropriate buffer. Phosphate

buffer (50 mM) was used for CAT analysis, Tris-HCl buffer (50 mM) for GSH analysis, Tris-HCl buffer (0.2 mM) for SOD analysis, and KCL solution (10%) for MDA. The mixtures were then homogenized for 15 minutes. (Ultra Turrax T25, Rose Scientific Ltd., Edmonton, Canada). The supernatants were used for analysis by centrifuging the homogenates at 4 °C for 4000 rpm 30 min for MDA, 6000 rpm 60 min for SOD, 4000 rpm 30 min for GSH and 8500 rpm 60 min for CAT.

Tissue MDA Assay

In determining tissue MDA level, the method that described by Ohkawa *et al.* (1979) was used. Supernatants collected from the homogenates were placed in sterile glass tubes with measuring buffer (80 g/L SDS, 200 g / L Acetic acid, 8 g/L TBA) added. The tubes were incubated for 1 hour at 100 °C and then allowed to cool. The tubes were then vortexed by adding a solution of n-butanol-pyridine (15: 1 v/v). The tubes were centrifuged at 3000 rpm for 5 minutes and measured at 532 nm using a spectrophotometer (Epoch, Bio-tek, USA). The results were calculated from the standard graph prepared that previously using 1, 1, 3, 3-tetraethoxypropane and expressed as nmol/g tissue.

Tissue CAT assay

Tissue CAT activity was measured using the kinetic method developed by Aebi (1984). The supernatants from the homogenates were measured at 240 nm for 3 minutes by adding the measuring solution (at 30 mM H₂O₂ pH 7 in 50 mM KH₂PO₄ buffer) to the cuvettes. The results were expressed as μ mol/minute/mg tissue by calculating the absorbances taken into the formulation.

Tissue SOD assay

Tissue SOD activity was measured using the method described by Sun *et al.* (1988) ⁽²⁷⁾. Supernatants from homogenates were added to sterile test tubes containing measuring buffer (0.3 mM xanthine, 0.6 mM EDTA, 150 150M NBT, 0.4 M Na₂CO₃, 1 g/L BSA). Then, xanthine oxidase solution (167 U/L xanthine oxidase in 2 M (NH₄)

2SO₄) was added. After 20 minutes' incubation under room temperature, stop solution (0.8 mM CuCl₂) was added to terminate the reaction. It was read at 560 nm using a spectrophotometer. Results were expressed as U/mg tissue.

Tissue GSH assay

The method which is described by Seldak and Lindsay (1968) ⁽²⁸⁾ was used to determine GSH levels in testicular tissues. Homogenized testis tissues (in 2 ml of 50 mM Tris-HCl buffer solution containing 20 mM EDTA in pH 7.5) were added 2 ml of ethanol to dissolve proteins. The mixture was then centrifuged at 4 °C for 4 minutes. GSH level was determined by measuring the reaction between GSH and 5,5 'dithiobis (2-nitrobenzoic acid) in the supernatant. GSH level was also measured by spectrophotometer at 412 nm. The results were stated in nmol/mg.

Statistical analyses

SPSS 22.0 ⁽¹⁰⁾ software was used to statistical evaluations. Numerical findings were assessed by using one-way ANOVA and Duncan's tests. Values were expressed as mean±standard error (mean±SEM). In all comparisons, $p < 0.05$ was considered statistically significant.

RESULTS

Histological analysis

In this study, histopathological changes were not observed in sham and RF-EMF group rat testes. The histological structure of the testicular tissues of these groups was similar to the control group. In all three groups, germinal epithelium is consisted with; spermatogonia, spermatocytes, round and elongated spermatids, spermium and Sertoli cells (figure 1). Seminiferous tubule diameters and germinal epithelium thicknesses were similar in all groups (figure 2). There was no significant difference between the groups in terms of histological structure of interstitial tissue. The proportion and morphology of Leydig cells were same in all three groups (figure 1).

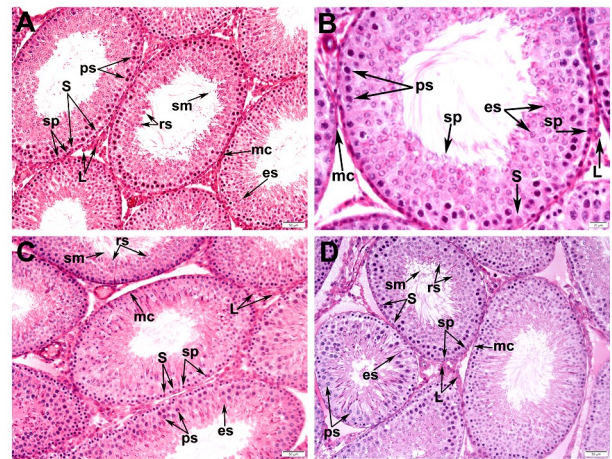


Figure 1. Light micrographs showing the RF-EMF (A, B), sham (C) and control groups' (D) testes stained with H&E (A, C, D: magnification × 200, B: magnification × 400). No histopathological changes were observed. The histological structure of the testicular tissues in all groups was similar. Mc: peritubular myoid cell, spn: spermatogonia, pst: primary spermatocytes, S: Sertoli cell, rsp: round spermatid, esp: elongated spermatid, sm: spermium, L: Leydig cell.

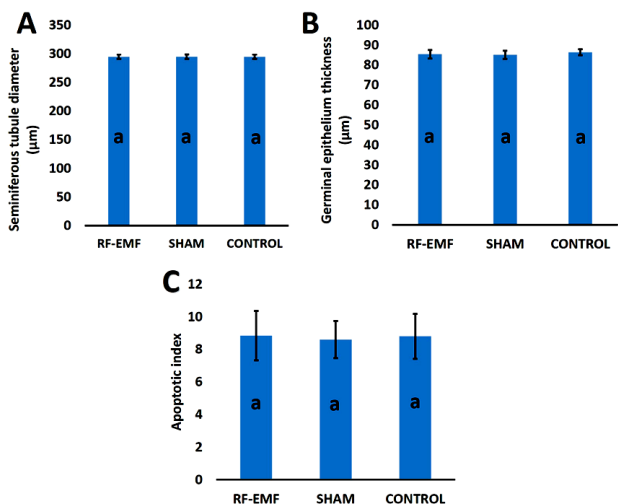


Figure 2. Seminiferous tubule's diameter (A), germinal epithelium thickness (B) and apoptotic index (C) of all of the groups. Same letter (a) on the bars indicate no statistical difference. There was no statistical differences among the groups (one way-ANOVA, $p > 0.05$).

TUNEL assay

TUNEL-positive cells (green fluorescence) were detected in testicular tissues of all groups examined (figure 3). Apoptosis was especially prominent in seminiferous tubules. RF-EMF exposure did not affect the rate of apoptosis in testicular tissues. The rate of apoptosis and the

apoptotic index in the convoluted seminiferous tubules were similar in all groups examined (figure 2).

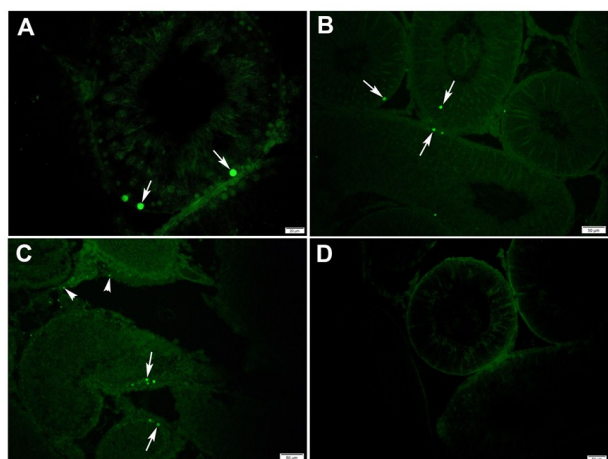


Figure 3. TUNEL assays in the testis of the RF-EMF (A), sham (B), control groups (C). Negative control (D) (A: magnification × 400, B, C, D: magnification × 200). The rate of apoptosis is similar in all of the groups. The green fluorescent signals indicate TUNEL-positive cells in germ cells (arrows) and interstitial cells (arrowheads).

Immunohistochemistry

In the RF-EMF group, AR-positive immunoreaction was detected in the nuclei, not in the cytoplasm of testicular cells. AR positive immunostaining was observed in the nuclei of peritubular myoid cells, pericytes, Sertoli cells and Leydig cells. Germ cells were AR negative. ER α -positive immunostaining was appeared in the nucleus of spermatogonium, in the acrosomal region of round spermatids and in the cytoplasm of Leydig cells. ER β positive immunoreaction was detected in the nuclei of spermatogonia and some elongate spermatids. The localizations of AR, ER α and ER β in rat testes of the RF-EMF group were similar to those of other groups (figure 4).

Biochemical analysis

As shown in figure 5, MDA and CAT levels in the testicular tissues of the RF-EMF group were significantly higher than those of the other groups, but also GSH levels were significantly lower (all, $p < 0.05$). MDA and CAT levels of the control group were lower than the sham group ($P < 0.05$). When GSH levels in testicular tissues of all three groups were compared; GSH levels

were significantly lower ($P < 0.05$) in the RF-EMF group than in the other groups, and were almost the same in the sham and control groups. There was no statistically important difference between the groups in terms of SOD levels ($P > 0.05$) (figure 5).

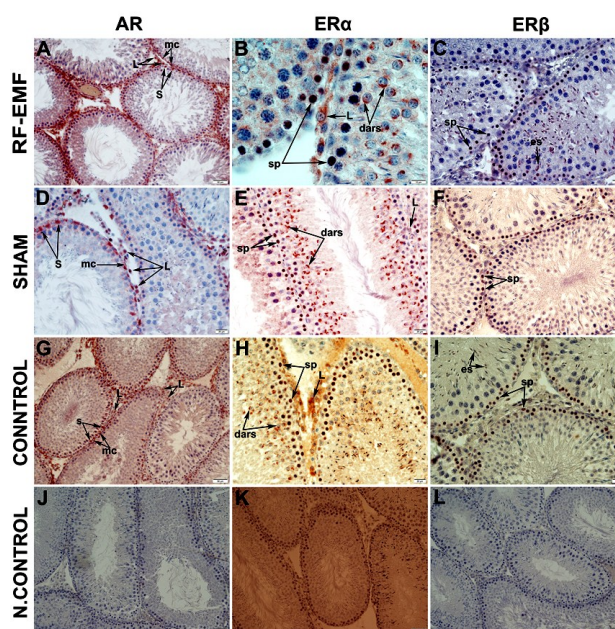


Figure 4. Immunohistochemical localisation of AR, ER α and ER β in RF-EMF group (A, B, C), sham group (D, E, F) and control group (G, H, I) testes and negative controls (J, K, L) (A, G, J, K, L: magnification × 200, C, D, E, F, H, I: magnification × 400, B: magnification × 1000). Letters show positive immunostained cells. Sp: spermatogonia, dars: developing acrosomal region of round spermatid, esp: elongated spermatid, S: Sertoli cell, L: Leydig cell, mc: peritubular myoid cell.

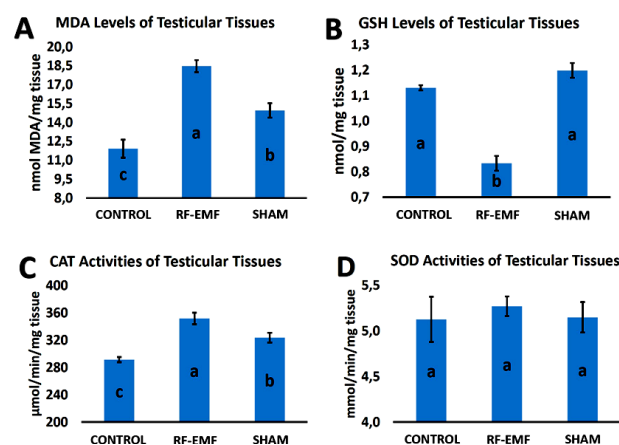


Figure 5. MDA level (A), GSH level (B), CAT (C) and SOD (D) activity in the testes of RF-EMF, sham and control group. Different letters (a, b, c) on the bars indicate statistical difference according to the Duncan test ($p < 0.05$).

DISCUSSION

The results of scientific studies on the effects of cell-based RF-EMF on testicular tissue are controversial. Although some researchers have reported that RF-EMF has no negative effect on testes ^(3, 12, 29), there are some reports that it significantly increases sperm count ⁽²⁹⁾. However, some other researchers reported that pathologic disorders in the testis tissue which is exposed to RF-EMF; such as decreasing in seminiferous tubular diameter and seminiferous epithelial thickness, necrosis in some of the seminiferous tubules, edema in interstitial tissue, germ cell degeneration, hypospermatogenesis and maturation arrest have been reported ^(1, 6, 7, 30).

Studies investigating the effects of 900 MHz RF-EMF on testicular tissue during adolescence are limited ^(20, 21). Narayanan *et al.* (2018) reported that pathological changes such as loss of spermatogonium, Sertoli cell damage, increasing in abnormal sperm count and decrease in sperm count could be formed in rat testis tissues that exposed to RF-EMF, but the rate of these changes was not statistically significant. Hancı *et al.* (2018) found that pathological changes characterized by vacuolar degeneration and irregularities in germinal epithelium in rat testicular tissues exposed to RF-EMF. On the contrary to these literatures, no histopathological changes were observed in testicular tissue in any of the RF-EMF, field and control groups examined in the study. This result is in conformity with studies reporting that there is no negative effect of RF-EMF on testicular tissue ^(3, 12, 29).

In some studies, exposure to 900 MHz RF-EMF has been reported to increase the rate of apoptosis in the germinal epithelium in adolescent and adult testicular tissues ^(6, 20, 21, 31). Therefore, in this study, TUNEL analysis was performed to determine whether RF-EMF affects the rate of apoptosis in testicular tissue. As a result of the research, it is observed that the ratio of apoptosis in germinal epithelium was similar in all groups. This result is parallel with the results of the studies indicating that RF-EMF does not affect the rate of apoptosis in testicular

tissues ^(3, 9) and it also supports the histological findings obtained in this study.

In the control group, AR positive immunohistochemical staining were observed in nuclei of Leydig, Sertoli and peritubular myoid cells. These findings were accordance with previous studies ^(13, 32, 33). Although some of the immunohistochemical studies indicated that AR positive immunostaining was also observed in germ cells such as spermatogonium ^(34, 35), spermatocyte ⁽³⁴⁾ and spermatid ^(36, 37), it was reported that germ cells were negative in most of the studies ^(32, 33, 37, 38). In the study, all germ cells in the control rat testes were AR negative.

Currently, there is no consensus on the localization of ER α in testicular cells. Saunders *et al.* (2001) reported that human and monkey testicular tissues were ER α -negative, although Zhou *et al.* (2002) ⁽³⁹⁾ and Oliveira *et al.* (2003) reported that peritubular myoid cells and Leydig cells are ER α -positive. In human testis, ER α -positive immunostaining was detected only in Leydig cells. In the rat testis, however, ER α -positive immunostaining was observed in the nucleus of Leydig cells and in the cytoplasm of spermatocytes and spermatids ⁽⁴⁰⁾. In this study, ER α -positive immunostaining was detected in the nucleus of spermatogoniums and in the acrosomal region of round spermatids in rat testis.

Although ER β -positive immunostaining was observed only in the nuclei of testicular cells in the majority of literature ⁽⁴⁰⁻⁴⁴⁾, it was also detected in the cytoplasm of the spermatocytes and round spermatids by Saunders *et al.* (1998) ⁽¹⁴⁾. In the studies on testicular tissue, ER β -positive immunostaining was observed in Sertoli cells ^(14, 40, 42, 44), Leydig cells ^(43, 45), peritubular myoid cells ^(40, 42, 43), spermatogonium ^(43, 45), spermatocytes ^(43, 45) and spermatids ⁽⁴¹⁻⁴³⁾ have been reported. In this study, ER β -positive immunoreactivity was formed in the nuclei of testicular cells such as spermatogonia and elongated spermatids in the control group.

The localizations of AR, ER α and ER β receptors in testicular cells of RF-EMF and sham groups were similar to those in the control group. That is, 900 MHz RF-EMF did not affect

the localization of sex hormone receptors in testicular cells. This result supports the data obtained with TUNEL analysis and histological examinations used in this study. So, RF-EMF has been reported to cause histopathological changes in testicular tissue in some studies (6, 20, 21). Even though these histopathological effects are accepted to exist, the data obtained in relation to sex hormone receptors in the present study show that histopathological effects cannot be related to steroid hormone receptors.

There is a special balance between free oxygen radicals and antioxidants in the body. The shift of this balance to the free oxygen radicals is called oxidative stress. Oxidative stress causes lipid peroxidation causing biomolecular damage. MDA is one of the lipid peroxidation products which is an important indicator of oxidative stress (41, 46, 47). Some researches have reported that using cell phone causes oxidative stress (1, 5). In this study, it was found that MDA levels increased significantly in the RF-EMF group compared to the other groups. Similarly, MDA levels were significantly higher in the sham group than in the control group. These results show that RF-EMF and retention in the cage cause oxidative stress in rat testis. The results of studies on the effects of cell phone-induced RF-EMF exposure on MDA levels in testicular tissue are variable. In some studies that is conducted on adolescents and adults stated that MDA levels increased significantly (1, 20, 21, 48), while others decreased significantly (31).

The level of oxidative stress in the body is regulated by enzymatic and non-enzymatic antioxidant systems. GSH is a non-enzymatic antioxidant found in all cell compartments. In this study, GSH level in the EMF group was statistically lower than in the sham and control groups. This finding, which is an indicator of oxidative stress, is consistent with the results of some studies (31, 49). However, Hanci *et al.* (2018) reported that RF-EMF did not affect GSH level.

Numerous studies have been conducted to find out the effects of 900-MHz RF-EMF on antioxidant enzyme levels in adolescent rat testicular tissue (19, 20, 31, 49). Results of studies that examining whether SOD and CAT enzyme

levels in testicular tissue are affected by RF-EMF are variable. Sepehrimanesh *et al.* (2016) reported decreased SOD and GPx activity in the RF-EMF group. Odaci and Ozyilmaz (2015) reported that SOD and CAT levels decreased significantly in the RF-EMF group compared to other groups. On the other hand, Hanci *et al.* (2018) reported an increase in contrast. In this study, the CAT level was significantly increased in the RF-EMF group compared to the other groups, but the SOD level did not show change.

In this study, changes in anti-oxidant parameters such as MDA, CAT and GSH in RF-EMF group in rat testes indicate that 900 MHz RF-EMF exposure causes oxidative stress in testicular tissue. Nevertheless, a number of specific antioxidant enzymes and free radical scavengers are available to protect the testis tissue from oxidative stress, which performs two important functions, spermatogenesis and steroidogenesis (50). This strong antioxidant system of testicular tissue is likely to prevent the level of oxidative stress occurring in the RF-EMF group from reaching the level leading to histopathological changes. However, increasing the duration of the experiment, daily RF-EMF exposure, or both, may increase the severity of oxidative stress in the testicular tissue and cause histopathological changes.

CONCLUSION

As a result; in this study, no difference was found between the RF-EMF group and other groups in the examinations performed with other analysis methods used in the study. These results can be interpreted as 900 MHz RF-EMF causes oxidative stress in testicular tissue, but damage caused by oxidative stress remains too low to be determined by other methods used in this study. Prolonged exposure to RF-EMF may possibly lead to more important pathological disorders. However, the results obtained in the present experimental model showed that exposure to 900 MHz RF-EMF during the adolescent period had no important effect on the structure, development and differentiation of testicular tissue.

Conflicts of interest: Declared none.

REFERENCES

- Ozguner M, Koyu A, Cesur G, Ural M, Ozguner F, Gokcimen A, et al. (2005) Biological and morphological effects on the reproductive organ of rats after exposure to electromagnetic field. *Saudi Medical Journal*, **26**(3): 405-10.
- Repacholi MH (2001) Health risks from the use of mobile phones. *Toxicol Letters*, **120**(1-3): 323-31.
- Tumkaya L, Kalkan Y, Bas O, Yilmaz A (2016) Mobile phone radiation during pubertal development has no effect on testicular histology in rats. *Toxicology and Industrial Health*, **32**(2): 328-36.
- Marinelli F, La Sala D, Ciccotti G, Cattini L, Trimarchi C, Putti S, et al. (2004) Exposure to 900 MHz electromagnetic field induces an unbalance between pro-apoptotic and pro-survival signals in T-lymphoblastoid leukemia CCRF-CEM cells. *The Journal of Cellular Physiology*, **198**(2): 324-32.
- Zeni O, Di Pietro R, d'Ambrosio G, Massa R, Capri M, Naarala J, et al. (2007) Formation of reactive oxygen species in L929 cells after exposure to 900 MHz RF radiation with and without co-exposure to 3-chloro-4-(dichloromethyl)-5-hydroxy-2(5H)-furanone. *Radiation Research*, **167**(3): 306-11.
- Hanci H, Odaci E, Kaya H, Aliyazicioglu Y, Turan I, Demir S, et al. (2013) The effect of prenatal exposure to 900-MHz electromagnetic field on the 21-old-day rat testicle. *Reproductive Toxicology*, **42**: 203-9.
- Sepehrimanesh M, Kazemipour N, Saeb M, Nazifi S (2014) Analysis of rat testicular proteome following 30-day exposure to 900 MHz electromagnetic field radiation. *Electrophoresis*, **35**(23): 3331-8.
- Agarwal A, Deepinder F, Sharma RK, Ranga G, Li J (2008) Effect of cell phone usage on semen analysis in men attending infertility clinic: an observational study. *Fertility and Sterility*, **89**(1): 124-8.
- Deepinder F, Makker K, Agarwal A (2007) Cell phones and male infertility: dissecting the relationship. *Reproductive BioMedicine Online*, **15**(3): 266-70.
- Meo SA, Al-Drees AM, Husain S, Khan MM, Imran MB (2010) Effects of mobile phone radiation on serum testosterone in Wistar albino rats. *Saudi Medical Journal*, **31**(8): 869-73.
- Sepehrimanesh M, Nazifi S, Saeb M, Kazemipour N (2016) Effect of 900 MHz radiofrequency electromagnetic field exposure on serum and testicular tissue antioxidant enzymes of rat. *Online Journal of Veterinary Research*, **20**(9): 617-24.
- Celik S, Aridogan IA, Izol V, Erdogan S, Polat S, Doran S (2012) An evaluation of the effects of long-term cell phone use on the testes via light and electron microscope analysis. *Urology*, **79**(2): 346-50.
- Chang C, Chen YT, Yeh SD, Xu Q, Wang RS, Guillou F, et al. (2004) Infertility with defective spermatogenesis and hypotestosteronemia in male mice lacking the androgen receptor in Sertoli cells. *Proceedings of the National Academy of Sciences of the United States of America*, **101**(18): 6876-81.
- Saunders PT, Fisher JS, Sharpe RM, Millar MR (1998) Expression of oestrogen receptor beta (ER beta) occurs in multiple cell types, including some germ cells, in the rat testis. *Journal of Endocrinology*, **156**(3): R13-7.
- Mooradian AD, Morley JE, Korenman SG (1987) Biological actions of androgens. *Endocrine Reviews*, **8**(1): 1-28.
- O'Donnell L, Robertson KM, Jones ME, Simpson ER (2001) Estrogen and spermatogenesis. *Endocrine Reviews*, **22**(3): 289-318.
- Akin JW, Behzadian A, Tho SP, McDonough PG (1991) Evidence for a partial deletion in the androgen receptor gene in a phenotypic male with azoospermia. *American Journal of Obstetrics and Gynecology*, **165**(6 Pt 1): 1891-4.
- Hess RA, Bunick D, Lee KH, Bahr J, Taylor JA, Korach KS, et al. (1997) A role for oestrogens in the male reproductive system. *Nature*, **390**(6659): 509-12.
- Sepehrimanesh M, Davis DL (2016) Proteomic impacts of electromagnetic fields on the male reproductive system. *Comparative Clinical Pathology*, **26**(2): 309-313.
- Hanci H, Kerimoglu G, Mercantepe T, Odaci E (2018) Changes in testicular morphology and oxidative stress biomarkers in 60-day-old Sprague Dawley rats following exposure to continuous 900-MHz electromagnetic field for 1 h a day throughout adolescence. *Reproductive Toxicology*, **81**: 71-78.
- Narayanan SN, Lukose ST, Arun G, Mohapatra N, Pamala J, Concessao PL, et al. (2018) Modulatory effect of 900 MHz radiation on biochemical and reproductive parameters in rats. *Bratislava Medical Journal*, **119**(9): 581-587.
- Kerimoglu G, Aslan A, Bas O, Colakoglu S, Odaci E (2016) Adverse effects in lumbar spinal cord morphology and tissue biochemistry in Sprague Dawley male rats following exposure to a continuous 1-h a day 900-MHz electromagnetic field throughout adolescence. *The Journal of Chemical Neuroanatomy*, **78**: 125-130.
- Spear LP (2000) The adolescent brain and age-related behavioral manifestations. *Neuroscience & Biobehavioral Reviews*, **24**(4): 417-63.
- Tirelli E, Laviola G, Adriani W (2003) Ontogenesis of behavioral sensitization and conditioned place preference induced by psychostimulants in laboratory rodents. *Neuroscience & Biobehavioral Reviews*, **27**(1-2): 163-78.
- Knorr DW, Vanha-Perittula T, Lipsett MB (1970) Structure and function of rat testis through pubescence. *Endocrinology*, **86**(6): 1298-304.
- Keles AI, Yildirim M, Gedikli O, Colakoglu S, Kaya H, Bas O, et al. (2018) The effects of a continuous 1-h a day 900-MHz electromagnetic field applied throughout early and mid-adolescence on hippocampus morphology and learning behavior in late adolescent male rats. *Journal of Chemical Neuroanatomy*, **94**: 46-53.
- Sun Y, Oberley LW, Li Y (1988) A simple method for clinical assay of superoxide dismutase. *Clinical Chemistry*, **34**(3): 497-500.

28. Sedlak J and Lindsay RH (1968) Estimation of total, protein-bound, and nonprotein sulfhydryl groups in tissue with Ellman's reagent. *Analytical Biochemistry*, **25(1)**: 192-205.
29. Imai N, Kawabe M, Hikage T, Nojima T, Takahashi S, Shirai T (2011) Effects on rat testis of 1.95-GHz W-CDMA for IMT-2000 cellular phones. *Systems Biology in Reproductive Medicine*, **57(4)**: 204-9.
30. Meo SA, Arif M, Rashied S, Khan MM, Vohra MS, Usmani AM, et al. (2011) Hypospermatogenesis and spermatozoa maturation arrest in rats induced by mobile phone radiation. *Journal of College of Physicians and Surgeons Pakistan*, **21(5)**: 262-5.
31. Odaci E and Ozyilmaz C (2015) Exposure to a 900 MHz electromagnetic field for 1 hour a day over 30 days does change the histopathology and biochemistry of the rat testis. *International Journal of Radiation Biology*, **91(7)**: 547-54.
32. Gur FM and Timurkaan S (2012) Effects of prepubertal epididymal ligation on the androgen receptor distribution of the rat testis. *Analytical and quantitative cytology and histology*, **34(6)**: 317-24.
33. Timurkaan S, Gur FM, Karan M (2012) Immunohistochemical distribution of androgen receptor in rat testis during postnatal development. *Revue De Medecine Veterinaire*, **163(3)**: 112-115.
34. Kimura N, Mizokami A, Oonuma T, Sasano H, Nagura H (1993) Immunocytochemical localization of androgen receptor with polyclonal antibody in paraffin-embedded human tissues. *Journal of Histochemistry & Cytochemistry*, **41(5)**: 671-8.
35. Zhou X, Kudo A, Kawakami H, Hirano H (1996) Immunohistochemical localization of androgen receptor in mouse testicular germ cells during fetal and postnatal development. *The Anatomical Record*, **245(3)**: 509-18.
36. Goyal HO, Bartol FF, Wiley AA, Khalil MK, Chiu J, Vig MM (1997) Immunolocalization of androgen receptor and estrogen receptor in the developing testis and excurrent ducts of goats. *The Anatomical Record*, **249(1)**: 54-62.
37. Vornberger W, Prins G, Musto NA, Suarez-Quian CA (1994) Androgen receptor distribution in rat testis: new implications for androgen regulation of spermatogenesis. *Endocrinology*, **134(5)**: 2307-16.
38. Bremner WJ, Millar MR, Sharpe RM, Saunders PT (1994) Immunohistochemical localization of androgen receptors in the rat testis: evidence for stage-dependent expression and regulation by androgens. *Endocrinology*, **135(3)**: 1227-34.
39. Zhou Q, Nie R, Prins GS, Saunders PT, Katzenellenbogen BS, Hess RA (2002) Localization of androgen and estrogen receptors in adult male mouse reproductive tract. *Journal of Andrology*, **23(6)**: 870-81.
40. Pelletier G, Labrie C, Labrie F (2000) Localization of oestrogen receptor alpha, oestrogen receptor beta and androgen receptors in the rat reproductive organs. *Journal of Endocrinology*, **165(2)**: 359-70.
41. Aebi H (1984) Catalase in vitro. *Methods in Enzymology*, **105**: 121-6.
42. Nie R, Zhou Q, Jassim E, Saunders PT, Hess RA (2002) Differential expression of estrogen receptors alpha and beta in the reproductive tracts of adult male dogs and cats. *Biology of Reproduction*, **66(4)**: 1161-8.
43. Saunders PT, Sharpe RM, Williams K, Macpherson S, Urquart H, Irvine DS, et al. (2001) Differential expression of oestrogen receptor alpha and beta proteins in the testes and male reproductive system of human and non-human primates. *Molecular Human Reproduction*, **7(3)**: 227-36.
44. Taylor AH and Al-Azzawi F (2000) Immunolocalisation of oestrogen receptor beta in human tissues. *Journal of Molecular Endocrinology*, **24(1)**: 145-55.
45. Oliveira CA, Nie R, Carnes K, Franca LR, Prins GS, Saunders PT, et al. (2003) The antiestrogen ICI 182,780 decreases the expression of estrogen receptor-alpha but has no effect on estrogen receptor-beta and androgen receptor in rat efferent ductules. *Reproductive Biology and Endocrinology*, **1**: 75.
46. Ohkawa H, Ohishi N, Yagi K (1979) Assay for lipid peroxides in animal tissues by thiobarbituric acid reaction. *Analytical Biochemistry*, **95(2)**: 351-8.
47. Shoji H and Koletzko B (2007) Oxidative stress and antioxidant protection in the perinatal period. *Current Opinion in Clinical Nutrition & Metabolic Care*, **10(3)**: 324-8.
48. Mailankot M, Kunnath AP, Jayalekshmi H, Koduru B, Valsalan R (2009) Radio frequency electromagnetic radiation (RF-EMR) from GSM (0.9/1.8GHz) mobile phones induces oxidative stress and reduces sperm motility in rats. *Clinics (Sao Paulo)*, **64(6)**: 561-5.
49. Bin-Meferij MM and El-Kott AF (2015) The radioprotective effects of Moringa oleifera against mobile phone electromagnetic radiation-induced infertility in rats. *International Journal of Clinical and Experimental Medicine*, **8(8)**: 12487-97.
50. Aitken RJ, Bennetts LE, Sawyer D, Wiklendt AM, King BV (2005) Impact of radio frequency electromagnetic radiation on DNA integrity in the male germline. *International Journal of Andrology*, **28(3)**: 171-9.