

# The protective role of l-Carintine and vitamin E on gamma irradiated rat's tongue mucosa

D.H. El-Rouby<sup>1</sup> and A.A. El-Batouti<sup>2\*</sup>

<sup>1</sup>Oral Pathology Department, Faculty of Dentistry, Cairo University, Egypt

<sup>2</sup>Health Radiation Research Department, National Centre for Radiation Research and Technology (NCRRT), Atomic Energy Authority, Cairo, Egypt

## ABSTRACT

### ► Original article

**\*Corresponding author:**

Amal A. El-Batouti, Ph.D.,

**E-mail:**

[molashosho@gmail.com](mailto:molashosho@gmail.com)

Revised: November 2020

Accepted: January 2021

Int. J. Radiat. Res., October 2021;  
19(4): 987-992

DOI: 10.29242/ijrr.19.4.987

**Background:** The aim of this study was to investigate the antioxidant effect of L-carnitine (LC) against gamma-irradiation-induced oxidative damage in tongue of albino rats after total body irradiation with a single dose of 6 Gy.

**Materials and Methods:** 48 adult rats were randomly divided into 3 groups of 16 animals each. Group I was irradiated with a single dose of 6 Gy. Group II received a daily i.p. injection of LC (250 mg/kg, i.p.) for 5 consecutive days and 1 h after the last dose, rats were irradiated with a single dose (6 Gy). Group III received a daily i.p. injection of LC (250 mg/kg, i.p.) and Vitamin E 40 mg/kg intramuscular daily for 5 consecutive days and 1 h after the last dose, rats were irradiated with a single dose (6 Gy). At day 7 and day 14 after treatment exposure, 8 rats from each group were sacrificed. **Results:** Administration of LC resulted in attenuation of the histological changes noticed in irradiated rats. The number of p53 positive nuclei significantly decreased in rats receiving LC alone or in combination with VE. **Conclusion:** LC and VE has shown positive effect in minimizing the epithelial atrophy of tongue mucosa after radiotherapy, which was emphasized by decreasing apoptotic activity in these tissues.

**Keywords:** Gamma irradiation, tongue mucosa, L-carintine, vitamin E.

## INTRODUCTION

Mostly one hundred percent of those experiencing high dose radiation therapy for head and neck cancers suffer from some degree of oral mucositis (OM) <sup>(1)</sup>. OM was first termed in 1980 as a side effect of radiotherapy (RT) in cancer patients <sup>(2)</sup>. OM is a normal tissue injury caused by radiation/ RT <sup>(3)</sup>, which starts as an acute inflammation of oral mucosa, tongue, and pharynx after 24 RT exposure and lasts between 7 and 98 days <sup>(3, 4)</sup>.

Cancer therapy directly damages DNA and causes strand breaks that result in the death of a small fraction of basal and suprabasal epithelial cells <sup>(5, 6)</sup>. A more pronounced effect is believed to be derived from the generated reactive oxygen species (ROS); since they are also important mediators of downstream events that drive tissue damage <sup>(7, 8)</sup>; or through enzymatic

or transcription factor activation in multiple cellular elements within the mucosa <sup>(9)</sup>. This complex mechanism ends by diminished regenerative capacity of the oral and alimentary epithelium, leading to atrophy, erythema, ulceration, and, usually, the loss of mucosal barrier <sup>(10)</sup>. This leads to cancer treatment interruption, alterations in radiation dose fractionation and limitations of local tumor control <sup>11-15</sup>.

L-carnitine (LC) is a natural compound known as vitamin BT (γ-trimethyl amino butyrate) widely distributed in the body <sup>(16, 17)</sup>. LC is obtained mostly from the diet, good sources being dairy products, red meat, nuts, and seeds, pulses and fruits such as apricots, bananas and avocado <sup>(18)</sup> or can be given exogenously. It can also be synthesized endogenously by skeletal muscle, heart, liver, kidney and brain from the essential amino acids lysine and methionine <sup>(16,</sup>

<sup>19</sup>). LC and its derivatives prevent the formation of ROS, scavenge free radicals and protect cells from peroxidative stress <sup>(20-26)</sup>. It therefore plays a modulatory role against the cellular damage produced by free radicals induced by ionizing radiation <sup>(27)</sup>. LC is the only known substance that allows fatty acids to cross the mitochondria membrane, The human body needs an adequate supply of iron, vitamin C, pyridoxine, and niacin for its endogenous synthesis, which takes place mainly in the cytosol and in the mitochondrial matrix of liver and kidney cells. LC is critical for energy generation by mitochondrial  $\beta$ -oxidation <sup>(28)</sup>; therefore deficiencies must be avoided. It has no known harmful side effects, it possesses extensive anti-oxidant properties and can be used as a supplement against oxidative stress <sup>(18)</sup>.

The radioprotective effect of LC on several tissues including kidney, lens, retina, brain, cochlea, salivary glands, ovaries, small intestine and colon has been shown in earlier studies <sup>(29-37)</sup>.

LC has a capacity to enhance non-enzymatic antioxidants, such as VE <sup>(22)</sup>. Antioxidative micronutrients such as vitamin C, vitamin E, retinoids, and selenium do not act merely as radical scavengers but have many essential metabolic functions in addition to the antioxidant cell protection. They have immunomodulating and apoptosis-inducing properties, as well as regulatory effects on cell proliferation and differentiation <sup>(38, 39)</sup>.

VE physically stabilizes membrane permeability and its fluidity. VE is a potent anti-inflammatory agent <sup>(40)</sup> and it may not only protect intact tissues by decreasing apoptosis induced by damaging condition <sup>(41)</sup>, but it may also increase apoptosis with a direct selective action on cancer cells <sup>(42)</sup>.

Consequently, recent evidences have demonstrated the antioxidant, anti-inflammatory, and cytoprotective roles of both VE <sup>(40, 43, 44)</sup> and LC <sup>(33, 45-49)</sup>.

The present study was established to assess the preventive capacity of L-carnitine (LC), alone and in combination with vitamin E (VE), for reducing radiation induced oral mucositis, in terms of preserving the epithelium integrity and decreasing the apoptotic activity.

## MATERIAL AND METHODS

### *Animals*

Forty-eight male Albino rats (weighing 120–150g) were obtained from the animal farm of the Egyptian Holding Company for Biological Products and Vaccines, Egypt. Upon arrival, the animals were allowed to acclimatize for 1 week before starting the experiment. Animals were kept under standard conditions and were allowed free access to a standard requirement diet and water ad libitum. Animals were kept under a controlled lighting condition (light: dark, 11h-11h). The animals' treatment protocol was approved by the animal care committee of the National Center for Radiation Research and Technology (NCRRT), Cairo, Egypt.

### *Irradiation*

Whole-body gamma-irradiation was performed at the National Centre for Radiation Research and Technology (NCRRT), Atomic Energy Authority, Cairo, Egypt, using (137cesium) Gamma Cell-40 biological irradiator. Animals were irradiated at an acute single dose level of 6 Gy delivered at a dose rate of 0.012 Gy/s <sup>(50-54)</sup>.

### *Horse Radish peroxidase*

#### *Collection and preparation*

At day 7 and day 14 after treatment exposure, 8 rats from each group were sacrificed by decapitation. Tongue was dissected and immediately fixed in 10 % formalin and embedded in paraffin. Five microns thick paraffin sections were stained by haematoxylin and eosin, for histological evaluation.

For p53 immunostaining, formalin-fixed paraffin embedded tissue specimens were cut into approximately 4- $\mu$ m thick sections and attached to positively charged glass slides. Before immunostaining, the sections were treated in a pressure cooker reaching maximum temperature of 121°C using Tris-HCL buffered saline, pH 9.0 as retrieval solution. The sections were incubated with a primary monoclonal antibody (anti-p53, clone DO-7, Dako, Glostrup, Denmark) at room temperature for 30 minutes (dilution 1:100). Horse Radish Peroxidase -

*Int. J. Radiat. Res., Vol. 19 No. 4, October 2021*

detection system was used (EnVision Plus-HRP, Dako, Glostrup, Denmark) according to manufacturer's instructions. Diaminobenzidine was used as chromogen.

### Evaluation of immunoexpression and statistical analysis

The Computer image analyzer system, Leica Qwin 500 software (Leica Microsystems, Wetzlar GmbH, DM LB2/11888111, Germany) was used in counting the number of p53 positive nuclei of in each field. Three fields from each slide were chosen in a standard measuring frame using a magnification of  $\times 400$  by light microscopy transferred to the monitor's screen. The number of the positive cells was described as mean values  $\pm$  standard deviation ( $\pm$ SD). One way analysis of variance (ANOVA) test was used to compare between the studied groups. It was followed by Tukey Post Hoc multiple 2-group comparisons

## RESULTS

In group I, seven days following irradiation, crowded nuclei and disrupted architecture of basal cells were noted. Keratin tips were lost over some papillae. In the underlying lamina propria, some blood vessels were dilated; areas of edema and mild chronic inflammatory cell infiltrate could also be noticed (figure 1a). Fourteen days following irradiation, altered basal cell architecture was still noticed but was less obvious in comparison to the previous group. In the underlying lamina propria, smaller areas of degeneration and edema among the collagen fibers were observed (figure 1d).

In group II, seven days following irradiation, the dorsal surface of the tongue presented nearly normal keratinized stratified squamous epithelium without obvious changes in its structure except for localized areas showing reduced keratin height over some lingual papillae (figure 1b). Fourteen days following irradiation, normal tongue mucosa was covered by keratinized stratified squamous epithelium. Normal filliform papillae could be detected. The underlying connective tissue stroma was

composed of collagen fibers, fibroblasts and few blood vessels. (figure 1e)

In group III, seven days following irradiation, the dorsal surface of the tongue revealed no significant change. Keratin and lingual papillary height and the basal cell layer architecture were apparently preserved in most areas. (figure 1c). Fourteen days following irradiation, filliform papilla appeared intact, with normal keratinization. Sporadic inflammatory cells and some dilated blood vessels were seen in the connective tissue. (figure 1f)

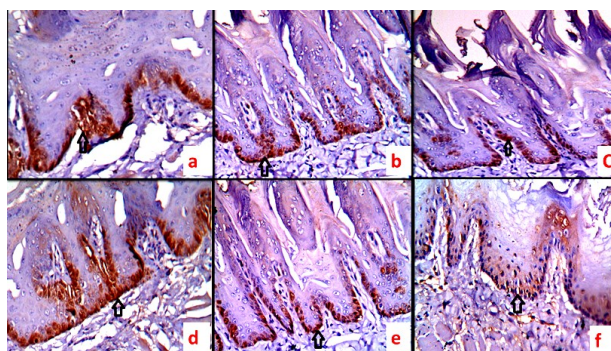
### p53 immunohistochemistry

p53 immunostaining was mainly confined to the basal and supra basal layers of the epithelium. Staining intensity was greatest in group I at 7 and 14 days (figure 2 a,d). The number of p53 positive nuclei decreased in group II at both observations times (figure 2 b,e), as well as in group at 7 days, to reach its lowest level at 14 days (figure 2 c,f). ANOVA test revealed a significant difference between groups (table 1, figure 3).

**Table 1.** Number of P53 positive nuclei in different groups (ANOVA test).

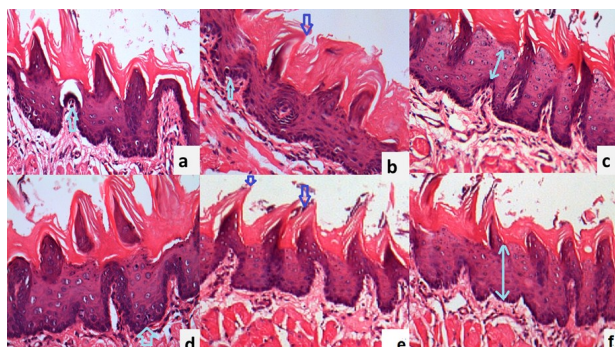
	Group I (Single dose, 6 Gy)		Group II (ALC+ Single dose, 6 Gy)	Group III (ALC+ Vit. E+ Single dose, 6 Gy)		
	7 days	14 days	7 days	14 days	7 days	14 days
Mean	34.67 <sup>a</sup>	30.00 <sup>a</sup>	17.33 <sup>b</sup>	15.46 <sup>b</sup>	16.84 <sup>b</sup>	10.50 <sup>c</sup>
SD	11.79	5.55	3.37	3.02	3.16	2.87
F value	58.21					
P value	<0.0001*					

Significance level  $P < 0.05$ , \*significant

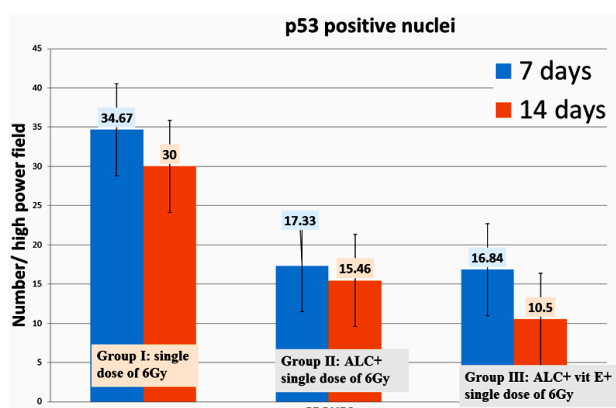


**Figure 1.** Photomicrograph of the dorsal surface of the tongue in Group I at 7 (a) and 14 (d) days following radiation showing disturbed architecture of basal cells. LC treated group II reveals slight alteration in basal cell architecture and preserved keratin tips over the lingual papillae at 7 (b) and 14 (e) days following radiation. LC & VE treated group III reveals normal appearance of the filliform papillae and normal epithelial thickness at 7 (c) and 14 (f) days following radiation. (H&E,  $\times 200$ ).





**Figure 2.** Photomicrograph of the dorsal surface of the tongue showing intense p53 staining in basal cells Group I at 7 days (a) and 14 days (d). Decrease in p53 immunostaining is noted in group II at 7 days (b) and 14 days (e), with marked decrease in group III at 7 days (c) and 14 days (f) (H&E,  $\times 200$ ).



**Figure 3.** Column chart showing mean number of p53 positive cells/ high power ( $\times 400$ ) field in different group.

## DISCUSSION

L-carnitine possesses a strong antioxidant activity and suppresses the mitochondrial release of free electrons that generate free radicals <sup>(55)</sup>. Improvement of epithelial integrity after the administration of high-dose L-carnitine can be attributed not only to an improved cellular energy balance from improved mitochondrial fat burning but also to the favorable effect of LC on glucose utilization and cytokine metabolism <sup>(56)</sup>. There are many experimental studies reporting the protective effect of carnitine against the toxicity of irradiation and antineoplastic agents including doxorubicin and cisplatin <sup>(58)</sup>.

The biological functions of LC go far beyond its role in the transport of fatty acids. Carnitine

and its acetylated derivatives facilitate the  $\beta$ -oxidation and improve energy metabolism, minimize the toxic effects of free forms of long-chain fatty acids in and around mitochondria, protect the mitochondrial membranes and prevent permeability transitions, therefore, suppresses the release of free electrons that generate free radicals and cytochrome that activates caspases. LC protects against oxidative stress and reduces the apoptosis rate <sup>(55-57)</sup>. Regarding apoptosis, an increase in the apoptotic protein p53 after receiving radiotherapy is consistent with prior studies in animals, human cell lines, and intestinal crypts after treatment with chemotherapy and/or radiotherapy and is correlated to increased apoptotic activity which results in intestinal mucositis <sup>(59)</sup>. Down regulation of apoptotic proteins p53 with time at 14 days corresponding with improvement of the histological appearance. Remarkably, these findings correlate with the five-phase theoretical mucositis model suggested by Sonis (2004) <sup>(60)</sup>.

## CONCLUSIONS

LC and VE has shown positive effect in minimizing the epithelial atrophy of tongue mucosa after radiotherapy, which was emphasized by decreasing apoptotic activity in these tissues.

**Conflicts of interest:** Declared none.

## REFERENCES

1. Bowen JM, Gibson RJ, Keefe DM, Cummins AG (2005) Cytotoxic chemotherapy upregulates pro-apoptotic Bax and Bak in the small intestine of rats and humans. *Pathology*, **37**(1): 56–62.
2. Köstler WJ, Hejna M, Wenzel C, Zielinski CC (2001) Oral mucositis complicating chemotherapy and/or radiotherapy: options for prevention and treatment. *CA Cancer J Clin*, **51**(5): 290–315.
3. Muanza TM, Cotrim AP, McAuliffe M, Sowers AL, Baum BJ, Cook JA, et al. (2005) Evaluation of radiation-induced oral mucositis by optical coherence tomography. *Clin Cancer*

- Res, **11(14)**: 5121–7.
4. Al-Ansari S, Zecha JAEM, Barasch A, de Lange J, Rozema FR, Raber-Durlacher JE (2015) Oral mucositis induced by anticancer therapies. *Curr Oral Health Rep*, **2**: 202–11.
5. Sonis ST (2004). The pathobiology of mucositis. *Nat Rev Cancer*, **4(4)**: 277–284.
6. Youngjoo K (2016) Mechanism-based management for mucositis: option for treating side effects without compromising the efficacy of cancer therapy. *Onco Targets and Therapy*, **9**: 2007-2016.
7. Conklin KA (2004) Chemotherapy-associated oxidative stress: impact on chemotherapeutic effectiveness. *Integr Cancer Ther*, **3(4)**: 294–300.
8. Valerie K, Yacoub A, Hagan MP, Curiel DT, Fisher PB, Grant S, et al. (2007) Radiation-induced cell signaling: inside-out and outside-in. *Mol Cancer Ther*, **6 (3)**: 789–801.
9. Herr I and Debatin KM (2001) Cellular stress response and apoptosis in cancer therapy. *Blood*, **98(9)**: 2603–2614.
10. Inomata I, Horii, Suzuki K (2002) 5-Fluorouracil-induced intestinal toxicity: what determines the severity of damage to murine intestinal crypt epithelia? *Toxicology Letters*, **133(23)**: 231–240.
11. Karthaus M, Rosenthal C, Ganser A (1999) Prophylaxis and treatment of chemo- and radiotherapy-induced oral mucositis – are there new strategies? *Bone Marrow Transplant*, **24(10)**: 1095 – 108.
12. Naidu MU, Ramana GV, Rani PU, Mohan IK, Suman A, Roy P (2004) Chemotherapy-induced and/or radiation therapy-induced oral mucositis—complicating the treatment of cancer. *Neoplasia*, **6(5)**: 423–31.
13. Rosenthal C and Karthaus M (2001) Current approaches in prevention and therapy of chemo- and radiotherapy-induced oral mucositis. *Wien Med Wochenschr*, **151(34)**: 53–65.
14. Volpato LE, Silva TC, Oliveira TM, Sakai VT, Machado MA (2007) Radiation therapy and chemotherapy-induced oral mucositis. *Braz J Otorhinolaryngol*, **73(4)**: 562–8.
15. Maria OM, Eliopoulos N, Muanza T (2017) Radiation-Induced Oral Mucositis. *Front Oncol*, **7**: 89.
16. Bertelli A, Conte A, Ronca G (1994) L-propionyl carnitine protects erythrocytes and low density lipoproteins against peroxidation. *Drugs Exp Clin Res*, **20**: 191-7.
17. Sally SA, Aziza MH, Nermine KEH, Dalia EN, Mona GA (2010) Radioprotective activity of L- carintin and  $\alpha$ -Lipoic acid against whole body  $\gamma$ -irradiation in rats. *Journal of American Science*, **6 (12)**: 866.
18. Sharma K, Tayade A, Singh J, Walia S (2020) Bioavailability of Nutrients and Safety Measurements Functional Foods and Nutraceuticals, **3(11)**: 543-593.
19. Rebouche CJ and Seim H (1998) Carnitine metabolism and its regulation in microorganisms and mammals. *Annu Rev Nutr*, **18**: 39-61.
20. Packer L, Valenza M, Serbinova P, Starke-Reed, Frost K, Kagan V (1991) Free radical scavenging is involved in the protective effect of L-propionylcarnitine against ischemia-reperfusion injury of the heart. *Arch Biochem Biophys*, **288**: 533-537.
21. Luo X, Reichetzer B, Trines J, Benson LN, Lehotay DC (1999) L-carnitine attenuates doxorubicin induced lipid peroxidation in rats. *Free Radic Biol Med*, **26**: 1158-1165.
22. Arockia Rani PJ andPanneerselvam C (2001) Carnitine as a free radical scavenger in aging. *Exp Gerontol*, **36**: 1713-1726.
23. Izgut-Uysal VN, Agac A, Derin N (2003) Effect of L-carnitine on carragenan-induced inflammation in aged rats. *Gerontology*, **49**: 287-292.
24. Sener G, Paskaloglu K, Satiroglu H, Alican I, Kacmaz A, Sakarcan A (2004) L-carnitine ameliorates oxidative damage due to chronic renal failure in rats. *J Cardiovasc Pharmacol*, **43**: 698-705.
25. Dokmeci D (2005) Oxidative stress, male infertility and the role of carnitines. *Folia Med (Plovdiv)*, **47**:26-30.
26. Dokmeci D, Akpolat M, Aydogdu N, Doganay L,Turan FN (2005) L-carnitine inhibits ethanol-induced gastric mucosal injury in rats. *Pharmacol Rep*, **57**: 481-488.
27. Dokmeci D, Akpolat M, Aydogdu N, Cem Uzal M (2006) The protective effect of L-carnitine on ionizing radiation-induced free oxygen radicals. *Scand J Lab Anim Sci*, **33(2)**: 75-83.
28. Kraft M, Kraft K, Gärtner S, Mayerle J, Simon P, Weber E, et al. (2012) L-Carnitine-supplementation in advanced pancreatic cancer (CARPAN)—A randomized multicentre trial. *Nutr*, **11**: 52.
29. Caloglu M, Yurut-Caloglu V, Durmus-Altun G, Oz-Puyan F, Ustun F, Cosar-Alas R, et al. (2009) Histopathological and scintigraphic comparisons of the protective effects of l-carnitine and amifostine against radiation-induced late renal toxicity in rats. *Clin Exp Pharmacol Physiol*, **36**: 523-30.
30. Mansour HH (2006) Protective role of carnitine ester against radiation-induced oxidative stress in rats. *Pharmacol Res*, **54**: 165-71.
31. Altas E, Ertekin MV, Gundogdu C, Demirci E (2006) L-Ccarnitine reduces cochlear damage induced by gamma irradiation in Guinea pigs. *Ann Clin Lab Sci*, **6**: 312-8.
32. Kocer I, Taysi S, Ertekin MV, Karslioglu I, Gepdiremen A, Sezen O, et al. (2007) The effect of L-Carnitine in the prevention of ionizing radiation-induced cataracts: A rat model. *Graefes Arch Clin Exp Ophthalmo*, **245**: 588-94.
33. Ucuncu H, Ertekin MV, Yoruk O, Sezen O, Ozkan A, Erdogan F, et al. (2006) Vitamin E and l-Ccarnitine, separately or in combination, in the prevention of radiation-induced oral mucositis and myelosuppression: A controlled study in a rat model. *J Radiat Res*, **47**: 91-102.
34. Caloglu M, Caloglu YV, Yalta T, Yalcin O, Uzal C (2012) The histopathological comparison of L-carnitine with amifostine for protective efficacy on radiation-induced acute small intestinal toxicity. *Journal of Cancer Research andTherapeutics*, **8(2)**: 260-263.
35. Manal HA, Noha AS, Omayma MM (2015) Protective effect of l-carnitine on ionizing radiation-induced damage in rat submandibular gland: histological study. *Egyptian Journal of Histology*, **38(2)**: 346-355.
36. Caloglu YV, Caloglu M, Eskiocak S, Tastekin E, Ozen A, Kurkcu N, et al. (2015) Comparison of the protective roles of L-carnitine and amifostine against radiation-induced

- acute ovarian damage by histopathological and biochemical methods. *Journal of Cancer Research and Therapeutics*, **11(2)**: ??-??.
37. Tas S, Ozkan FO, Cikman O, Kiraz A, Akgun Y, Karaayvaz M (2016) L- carnitine has a protective effect on the colonic mucosa during abdominopelvic radiotherapy in rats. *Acta Cir. Bras*, **31(9)**: 615-620.
  38. Prasad KN (2004) Multiple dietary antioxidants enhance the efficacy of standard and experimental cancer therapies and decrease their toxicity. *Integr. Cancer. Ther*, **3**: 310-322.
  39. Prasad KN, Cole WC (2006) Antioxidants in cancer therapy. *J Clin Oncol*, **24**: e8-e9.
  40. Karslioglu I, Ertekin MV, Kocer I, Taysi S, Sezen O, Gepdiremen A, Balci E (2004) Protective role of intramuscularly administered vitamin E on the levels of lipid peroxidation and the activities of antioxidant enzymes in the lens of rats made cataractous with gamma-irradiation. *Eur J Ophthalmol*, **14**: 478-485.
  41. Osakada F, Hashino A, Kume T, Katsuki H, Kaneko S, Akaike A (2003) Neuroprotective effects of alpha-tocopherol on oxidative stress in rat striatal cultures. *Eur J Pharmacol*, **465**: 15-22.
  42. Neuzil J, Tomasetti M, Mellick AS, Alleva R, Salvatore BA, Birringer M, Fariss MW (2004) Vitamin E analogues: a new class of inducers of apoptosis with selective anti-cancer effects. *Curr Cancer Drug Targets*, **4**: 355-372.
  43. Canturk NZ, Canturk Z, Utkan NZ, Yenisey C, Ozbilim G, Yildirim C, et al. (1998) Cytoprotective effects of alpha tocopherol against liver injury induced by extrahepatic biliary obstruction. *East Afr Med J*, **75**: 77-80.
  44. Grammas P, Hamdheydari L, Benaksas EJ, Mou S, Pye QN, Wechter WJ, et al. (2004) Anti-inflammatory effects of tocopherol metabolites. *Biochem Biophys Res Commun*, **319**: 1047-1052.
  45. Caruso A, Cutulivm , DeBernardis E, Leonardi G, Amico-Roxas M (1995) Protective effect of propionyl-L-carnitine against PAF induced rat paw oedema. *Pharmacol Res*, **31**: 67-72.
  46. Chang B, Nishikawa M, Sato E, Utsumi K, Inoue M (2002) LCarnitine inhibits cisplatin-induced injury of the kidney and small intestine. *Arch Biochem Biophys*, **405**: 55-64.
  47. Rani PJ and Panneerselvam C (2002) Effect of L-carnitine on brain lipid peroxidation and antioxidant enzymes in old rats. *J Gerontol A Biol Sci Med Sci*, **57**: 134-137.
  48. Vanella A, Russo A, Acquaviva R, Campisi A, Di Giacomo C, Sorrenti V, et al. (2000) L-propionyl L-carnitine as superoxide scavenger, antioxidant, and DNA cleavage protector. *Cell Biol Toxicol*, **16**: 99-104.
  49. Sezen O, Ertekin VM, Demircan B, Karslioglu I, Erdoğan F, Koçer I, et al. (2008) Vitamin E and L-carnitine, separately or in combination, in the prevention of radiation-induced brain and retinal damages. *Neurosurg Rev*, **31**: 205-213.
  50. Korany NS, Mehanni SS, Hakam HM, El- Maghraby EM (2012) Evaluation of socket healing in irradiated rats after diode laser exposure (histological and morphometric studies). *Arch oral Biol*, **57(7)**: 884-891.
  51. Mehanni SS, Ibrahim NF, Hassan AR, Rashed LA (2013) New approach of bone marrow-derived mesenchymal stem cells and human amniotic epithelial cells applications in accelerating wound healing of irradiated albino rats. *Int J Stem Cells*, **6(1)**: 45-54.
  52. Eissa OS and Moustafa NA (2007) The Protective Role of Septilin Against Gamma Radiation-Induced Testicular Toxicity in Rats. *The Egyptian Journal of Hospital Medicine*, **27**: 176-187.
  53. Malik IA, Moriconi F, Sheikh N, Naz N, Khan S, Dudas J, Mansuroglu T, Hess CF, Rave-Frank M, Christiansen H, Ramadori G (2010) Single-dose gamma-irradiation induces up-regulation of chemokine gene expression and recruitment of granulocytes into the portal area but not into other regions of rat hepatic tissue, *Am J Pathol*, **176**, (4):1801-1813.
  54. Dalke C, Neff F, Bains SK, Bright S, Lord D (2018) Lifetime study in mice after acute low-dose ionizing radiation: a multifactorial study with special focus on cataract risk. *Radiation and Environmental Biophysics*, **57**: 99-113.
  55. Zhu X, Sato EF, Wang Y, Nakamura H, Yodoi J, Inoue M (2008) Acetyl-L-carnitine suppresses apoptosis of thioredoxin 2-deficient DT40 cells. *Arch Biochem Biophys*, **478**: 154-60.
  56. Ahmed SM (2010) Role of carnitine in cancer chemotherapy-induced multiple organ toxicity. *Saudi Pharm J*, **18**: 195-206.
  57. Chapela SP, Kriguer N, Fernández EH, Stella CA (2009) Involvement of L-Carnitine in Cellular Metabolism: Beyond Acyl-CoA Transport. *Mini- Reviews in Medicinal Chemistry*, **9**: 1518-1526.
  58. Mannelli DC, Ghelardini C, Calvani M, Nicolai R, Mosconi L, Vivoli E, et al. (2007) Protective effect of acetyl L – carnitine on the apoptotic pathway of peripheral neuropathy. *Eur J Neurosci*, **26**: 820-827.
  59. Mannelli DC, Ghelardini C, Calvani M, Nicolai R, Mosconi L, Toscano A, et al. (2009) Neuroprotective effects of acetyl-L -carnitine on neuropathic pain and apoptosis: a role for the nicotinic receptor. *J Neurosci Res*, **87**: 200-207.
  60. Sonis STA (2004) Biological approach to mucositis. *Journal of Supportive Oncology*, **29(1)**: 21-32.