

Postoperative low-dose external radiotherapy for diffuse pigmented villonodular synovitis (PVNS) of the knee: A case report and literature review

J. Lai^{1*}, S. Hu², Y. Luo³, R. Zheng³, P. Chen³, F. He³

¹Department of Oncology, Jiujiang First People's Hospital, Jiujiang, Jiangxi 332000, People's Republic of China

²Department of Infectious Diseases, Jiujiang Third People's Hospital, Jiujiang, Jiangxi 332000, People's Republic of China

³Department of Radiation Oncology, Yiwu Central Hospital, The Affiliated Yiwu Hospital of Wenzhou Medical University, Yiwu, Zhejiang 322000, People's Republic of China

► Case report

*Corresponding author:

Junming Lai, Ph.D.,

E-mail:

haixin27691@foxmail.com

Received: June 2021

Final revised: October 2021

Accepted: November 2021

Int. J. Radiat. Res., July 2022;
20(3): 719-722

DOI: 10.52547/ijrr.20.3.29

ABSTRACT

Background: Pigmented villonodular synovitis (PVNS) is a rare benign proliferative disease of the synovium which most commonly affects the knee. It is regarded as a benign disease, but has a local invasion. Postoperative adjuvant radiotherapy is very necessary for PVNS, but there is no consensus on the total dose of radiotherapy. **Case presentation:** A 22-year-old young male with diffuse PVNS of right knee was referred to our hospital with ongoing right knee swelling and limitation of motion of the knee. Preoperative magnetic resonance imaging (MRI) showed synovium of the joint was obviously thickened with multiple nodular low signals of long T1 and short T2 which is the typical characteristic of PVNS. The patient was treated with arthroscopic synovectomy combined with adjuvant postoperative low-dose external radiotherapy (20 Gy). **Conclusions:** Based on related literature about radiotherapy of PVNS, arthroscopic synovectomy combined with postoperative low-dose external radiotherapy is an ideal treatment and prevents the recurrence for PVNS of the knee.

Keywords: Case report, Pigmented villonodular synovitis, PVNS, Radiotherapy.

INTRODUCTION

Pigmented villonodular synovitis (PVNS) also termed tenosynovial giant cell tumor, PVNS is a rare benign proliferative disease occurring in mucinous bursa, synovial membrane and tendon sheath. It is characterized by synovial hyperplasia, yellowish brown villonodular protuberances and hemosiderin deposition⁽¹⁻³⁾. Jaffe HL firstly described PVNS as a chronic proliferative disease that occurs in the joint, tendon and bursa synovium⁽⁴⁾. PVNS is regarded as a benign disease, but has a local invasion. This proliferative disorder is very rare and the incidence is estimated to be 1.8 / million. PVNS mostly involved single large joint (especially knee joint, accounting for about 80%) and young adults are most often affected⁽³⁾. PVNS can be divided into localized and diffuse variants based on the extent of synovial involvement. Localized PVNS (LPVNS) often presents as a single nodule with clear boundary. Diffuse PVNS (DPVNS) often presents as villous and nodular which can destroy the joint capsule, invade the surrounding soft tissue and even the whole joint⁽⁵⁾. Surgical resection of the lesion is considered the preferred treatment, but there is a high postoperative recurrence rate,

especially in DPVNS⁽⁶⁻⁷⁾. Previous studies have suggested that radiotherapy can reduce postoperative recurrence rate, so postoperative adjuvant radiotherapy is necessary, especially for DPVNS.

We report a case about DPVNS of the knee that underwent arthroscopic synovectomy and adjuvant postoperative low-dose (20 Gy) external radiotherapy, and then the related literature of radiotherapy of PVNS was reviewed.

Case presentation

A 22-year-old male presented with 8 years swelling of the right knee and gradually increasing with 1 week pain of the right knee, and had limited knee motion. By asking about his medical history, he denied any previous illness and a history of familial genetic disease.

Preoperative magnetic resonance imaging (MRI) of right knee joint (figure 1) showed synovium of the joint was obviously thickened with multiple nodular (low signals of T1WI and T2WI). The synovial lesions of the right knee joint were considered as DPVNS. The patient further underwent arthroscopic synovectomy of the knee. One month after operation,

postoperative MRI of right knee joint (figure 2) showed postoperative changes that the knee joint space was slightly narrowed and the synovial membrane was thickened. After exclusion of radiotherapy contraindications, the patient was fixed with stereotactic frame and vacuum bag, and marked in the surface. At last, the patient lied down in the supine position, and was fixed with and vacuum bag marked in the surface. The patient was treated

with conformal radiotherapy with two radiation fields, 6MV X-ray by using Artiste linear accelerator (Siemens, Germany). The total dose of 20 Gy, each time for 2Gy, 5 times a week. Clinical target volume (CTV) includes tumor beds, complete joints, and a range of 2cm from the edges of surgical scars. Planning target volume (PTV) was defined from the CTV with a margin of 5 mm (figure 3).

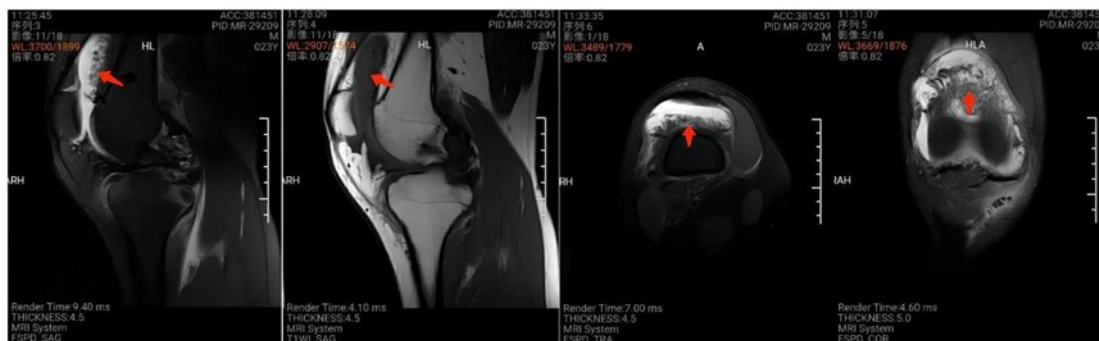

Figure 1. Preoperative MRI of right knee with DPVNS of the knee Synovium of the joint was obviously thickened with multiple nodular (low signals of T1WI and T2WI). Red tines indicate lesions.

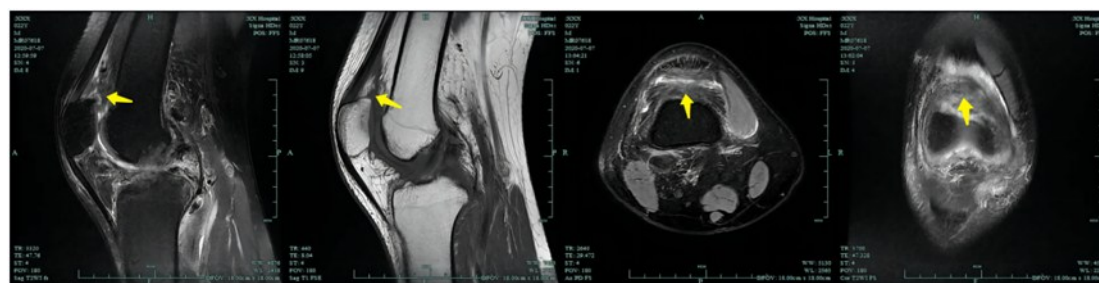


Figure 2. Postoperative MRI of right knee with DPVNS of the knee Postoperative changes that the knee joint space was slightly narrowed and the synovial membrane was thickened. Yellow tines indicate lesions.

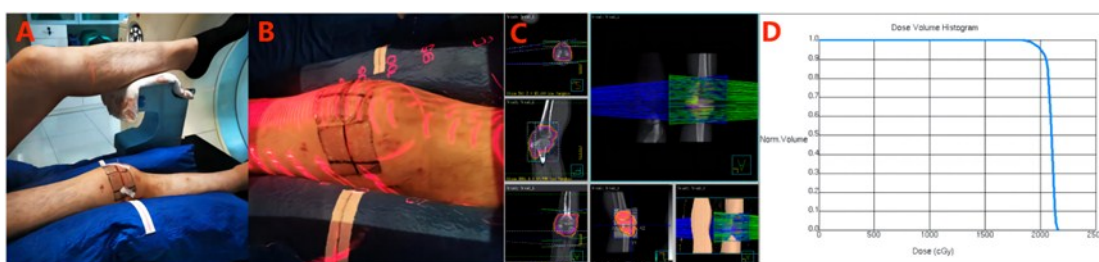


Figure 3. Position fixation and plan of radiotherapy (A, B) The patient lied down in the supine position, and was fixed with and vacuum bag marked in the surface. (C) The patient was treated with conformal radiotherapy with two radiation fields, linear accelerator 6 MV X-ray external irradiation. (D) Dose Volume Histogram (the total dose of 20 Gy).

DISCUSSION

Diffuse pigmented villonodular synovitis is a rare disease that may result in the appearance of pain, swelling together with significant functional impairment in the affected joints. Because of nonspecific symptoms of PVNS, it is very difficult to diagnose the disease as early as possible. Because of the lack of typical clinical manifestations, misdiagnosis and delayed diagnosis often occur. PVNS have characteristic imaging findings on Magnetic resonance imaging (MRI), and MRI can

assist diagnosis. DPVNS of the knee has typical MRI findings: diffuse irregular thickening of the synovium, low or equal signal on T1WI and low signal on T2WI, in which multiple scattered villous nodules and hemosiderosis are observed, as well as varying degrees of joint effusion. And diffuse thickening of the synovium and low signal on T2WI are the main MRI features. MRI is the most ideal imaging method for the diagnosis of DPVNS (8-9). MRI of this case of right knee joint showed synovium of the joint was obviously thickened with multiple nodular (low signals of T1WI and T2WI), and it is consistent with

the above characteristic findings of PVNS. The diagnosis of PVNS is not reliable by MR, others like the joint fluid test, but the pathology diagnosis is the gold standard and the differential diagnosis including synovial sarcoma, which has a very high misdiagnosis rate, should be very careful in clinical working.

Complete excision of all lesions is the standard treatment for PVNS⁽¹⁰⁾. Arthroscopic synovectomy is thought to improve surgical area healing and reduce postoperative adverse complications. Because of the anatomical limitation of the lesion, radical resection of DPVNS is very difficult. Arthroscopic synovectomy has a very high local recurrence for DPVNS (51%)⁽¹¹⁾, especially for the tumor at the posterior of the joint. A large number of reports (table 1) have confirmed that adjuvant postoperative external beam radiotherapy can further reduce the recurrence rate. Postoperative adjuvant radiotherapy is very necessary, but there is no consensus on the total dose of radiotherapy.

After consulting the literature of postoperative adjuvant radiotherapy for PVNS patients, we summarized and analyzed the related studies (table 1), especially for the dose of radiotherapy. Blanco *et al.*⁽¹²⁾ described 22 patients with knee DPVNS treated with partial arthroscopic synovectomy combined with postoperative external radiotherapy (26 Gy).

Local control of knee lesion was 86%. Arthroscopic synovectomy combined with low-dose postoperative radiotherapy was equally effective but to cause less morbidity. Wei⁽¹⁸⁾ reported that 26 DPVNS patients received postoperative adjuvant radiotherapy (20 Gy to 30 Gy). All patients showed no recurrence at postoperative follow-up, and the Lysholm knee joint function score increased from 54.3±9.0 at preoperation to 71.2±6.7 at postoperation ($P<0.01$). Park *et al.*⁽¹⁷⁾ thought that Low-dose postoperative radiotherapy (20 Gy) was as effective as moderate-dose postoperative radiotherapy (around 35 Gy). Followed up for 108 months with a better local control rate (83%) and late radiation reactions. De Carvalho *et al.*⁽¹⁹⁾ also assessed patients with DPVNS treated with partial arthroscopic synovectomy combined with anterior open synovectomy followed by postoperative adjuvant radiotherapy (20 Gy). No cases of major postoperative complications or radiotherapy-related side effects were occurred. In a follow-up time of 103 months, only one patient was observed recurrence (12.5%). The above studies suggested that low-dose postoperative adjuvant radiotherapy is an effective and acceptable modality to reduce local recurrence for DPVNS of the knee.

Table 1. Previous studies about postoperative radiotherapy for PVNS of the knee.

Author and year	Total number of patients	Prescription dose (Gy)	Radiotherapy energy (MV)	Follow-up time(months)	LCR (%)
Blanco C E R 2001 ⁽¹²⁾	22	26	NA	33(26-76)	86
Chin KR 2002 ⁽¹³⁾	5	35	NA	37 (32-42)	60
Berger B 2007 ⁽¹⁴⁾	5	40(30-50)	6	29 (3-112)	100
Horoschak M 2009 ⁽¹⁵⁾	12	34(20-36)	4-15	46 (8-181)	75
Heyd R 2010 ⁽¹⁶⁾	25	36(30-50)	4-15	69(13-150)	95.1
Park G 2012 ⁽¹⁷⁾	23	20 (12-34)	4 or 6	108 (9.6-144)	83
Wei L 2015 ⁽¹⁸⁾	26	NA(20-30)	NA	54 (24-72)	100
De Carvalho 2012 ⁽¹⁹⁾	8	20 (10-39.6)	15	103(36-168)	87.5

NA: Not applicable, LCR: Local control rate.

CONCLUSION

This case reported underwent arthroscopic synovectomy of the knee, then postoperative adjuvant external radiotherapy (20 Gy). Based on related literature about radiotherapy of PVNS, arthroscopic synovectomy combined with postoperative low-dose external radiotherapy is an ideal treatment and prevents the recurrence for PVNS of the knee.

Ethical Approval: The institutional review board of our hospital waived informed consent for use of the data due to its retrospective nature.

Funding: This study was not funded by any funding source.

Conflict of Interests: The authors declare that there are no conflict of interests.

Consent for publication: Authors have received an informed consent from the patient.

Authors' contributions: JL performed the planning

study and the statistical analysis, and drafted the manuscript. SH participated in information and data collection. YL and RZ helped to draw target outline. PC, FH and FZ helped to draft the manuscript. All authors read and approved the final manuscript.

REFERENCES

1. Fałek A, Niemunis-Sawicka J, Wrona K, Szczypiór G, Rzepecka-Wejs L, Cięszczyk K, *et al.* (2018) Pigmented villonodular synovitis. *Folia medica Cracoviensia*, **58**(4): 93–104.
2. Jendrissek KA, Hotfiel T, Swoboda B, Söder S, Janka R (2016) Pigmentierte villonoduläre Synovialitis. *Z Rheumatol*, **75**(2): 157–165.
3. Fang Y and Zhang Q (2020) Recurrence of pigmented villonodular synovitis of the knee: A case report with review of literature on the risk factors causing recurrence. *Medicine*, **99**(16): e19856.
4. Jaffe HL, Lichtenstein L, Suro CJ (1941) Pigmented villonodular synovitis, bursitis and tenosynovitis. *Arch Pathol*, **31**: 731–765.
5. Bernthal NM, Ishmael CR, Burke Z (2020) Management of Pigmented Villonodular Synovitis (PVNS): an Orthopedic Surgeon's Perspective. *Curr Oncol Rep*, **22**(6): 63.
6. Temponi EF, Barros A, Paganini VO, Barbosa V, Badet R, Carvalho Júnior LH (2017) Diffuse pigmented villonodular synovitis in knee joint: diagnosis and treatment. *Rev Bras Ortop*, **52**(4): 450–457.
7. De Ponti A, Sansone V, Malcherè M (2003) Result of arthroscopic

- treatment of pigmented villonodular synovitis of the knee. *Arthroscopy*, **19**(6): 602-607.
8. Schumacher HR (2010) A case of villonodular synovitis of the shoulder in an adolescent: imaging and pathologic diagnosis. *Revista Brasileira de Reumatologia*, **50**(4): 478-480.
 9. Addicott BT, Jose J, Kaplan LD, Clifford PD (2009) Imaging series. Pigmented villonodular synovitis. *Am J Orthop*, **38**(12): 635-636.
 10. Sharma H, Jane MJ, Reid R (2005) Pigmented villonodular synovitis: Diagnostic pitfalls and management strategy. *Current Orthopaedics*, **19**(3): 215-222.
 11. Mollon B, Lee A, Busse JW, Griffin AM, Ferguson PC, Wunder JS, et al. (2015) The effect of surgical synovectomy and radiotherapy on the rate of recurrence of pigmented villonodular synovitis of the knee: an individual patient meta-analysis. *Bone Joint J*, **97-B** (4): 550-557.
 12. Blanco CE, Leon HO, Guthrie TB (2001) Combined partial arthroscopic synovectomy and radiation therapy for diffuse pigmented villonodular synovitis of the knee. *Arthroscopy*, **17**(5): 527-531.
 13. Chin KR, Barr SJ, Winalski C, Zurakowski D, Brick GW (2002) Treatment of advanced primary and recurrent diffuse pigmented villonodular synovitis of the knee. *J Bone Joint Surg Am*, **84**(12): 2192-2202.
 14. Berger B, Ganswindt U, Bamberg M, Hehr T (2007) External beam radiotherapy as postoperative treatment of diffuse pigmented villonodular synovitis. *Int J Radiat Oncol Biol Phys*, **67**(4): 1130-1134.
 15. Horoschak M, Tran PT, Bachireddy P, West RB, Mohler D, Beaulieu CF, et al. (2009) External beam radiation therapy enhances local control in pigmented villonodular synovitis. *Int J Radiat Oncol Biol Phys*, **75**(1): 183-187.
 16. Heyd R, Micke O, Berger B, Eich HT, Ackermann H, Seegenschmiedt MH, et al. (2010) Radiation therapy for treatment of pigmented villonodular synovitis: results of a national patterns of care study. *Int J Radiat Oncol Biol Phys*, **78**(1): 199-204.
 17. Park G, Kim YS, Kim JH, Lee SW, Song SY, Choi EK, et al. (2012) Low-dose external beam radiotherapy as a postoperative treatment for patients with diffuse pigmented villonodular synovitis of the knee: 4 recurrences in 23 patients followed for mean 9 years. *Acta orthopaedica*, **83**(3): 256-260.
 18. Li W, Sun X, Lin J, Ji W, Ruan D (2015) Arthroscopic synovectomy and postoperative assisted radiotherapy for treating diffuse pigmented villonodular synovitis of the knee: An observational retrospective study. *Pak J Med Sci*, **31**(4): 956-960.
 19. de Carvalho LH, Jr Soares LF, Gonçalves MB, Temponi EF, de Melo Silva O (2012) Long-term success in the treatment of diffuse pigmented villonodular synovitis of the knee with subtotal synovectomy and radiotherapy. *Arthroscopy*, **28**(9): 1271-1274.