

A study on the diagnostic abilities of ultrasound scans in assessing uterine fibroids against magnetic resonance imaging findings in the same population

B. Al Omran^{1*}, A. Mohamed Mehad², S. Matoi², S.M. Abdul Qadir², A. Peluola², R. O'Sullivan², N. Dayoub³

¹Radiology Department, Bahrain Defense Force Hospital, Riffa, Bahrain

²Royal College of Surgeons in Ireland, Medical University Bahrain, Muharraq, Bahrain

³Assisted Reproduction and Gynecology Center London, United Kingdom

► Original article

*Corresponding author:

Bedoor Al Omran, MB, BCh, BAO,
E-mail:

drbedooralomran@gmail.com

Received: January 2022

Final revised: May 2022

Accepted: June 2022

Int. J. Radiat. Res., October 2022;
20(4): 779-784

DOI: 10.52547/ijrr.20.4.8

Keywords: Fibroid size, Ultrasound, Magnetic resonance imaging, Fibroid type, Fibroid site.

ABSTRACT

Background: This study was designed to evaluate the matching percentage among findings of the ultrasound scans (USS) to the magnetic resonance imaging (MRI) in women with fibroids. **Materials and Methods:** This descriptive, retrospective study was conducted from January 2016 to December 2018. This study includes 205 female patients referred from the Gynaecological Department to the Radiological Department in the Bahrain Defense Force Hospital for MRI and USS for fibroid evaluation. The data collected included their age, parity, and nationality. The StatsDirect software was used to analyze the fibroids according to the site, size, type, and number. **Results:** The findings of USS matched the MRI in the posterior fibroid sites in 52.5% of cases, followed by anterior (38.1%) and fundal (21.8%). For fibroid size, USS matched MRI findings in 83.3% for fibroids between >5 to ≤10 cm, 78.3% for fibroids between >2 to ≤5 cm, and 36.8% for fibroids sized ≤2 cm. Fibroids more than 10 cm in size were in agreement for 33.33% of fibroids. Submucosal fibroids matched in just 29.4% of cases, but for the subserosal fibroids, it was 44.8%. The matching score for more than four fibroids was 61.8%, followed by single fibroids (54.8%) and two fibroids (34.8%). **Conclusions:** Results of USS and MRI were reasonably correlated in terms of fibroid location and size. USS diagnosis of posterior wall and fibroids of size less than 2 cm highly matched MRI diagnosis.

INTRODUCTION

Uterine fibroids (or uterine leiomyomas) are the main gynecological tumors occurring in up to 50% of women of reproductive age globally ⁽¹⁾. More than 30% of the women over the age of 30 years are affected by fibroids, and it is estimated that more than 70% of the women will be affected in their lifetime ⁽²⁾. Since most affected women do not encounter any distressing effects or symptoms, uterine fibroids often go undiagnosed ⁽³⁾. However, fibroids do have an approximately 0.1 to 0.8% risk of transforming into malignant sarcomas. Affected women have increased morbidity and risk of encountering reproductive problems such as infertility and miscarriages ⁽⁴⁾.

Traditionally, the diagnosis of leiomyomas has been carried out using diagnostic imaging modalities, with ultrasound scans (USS). It has shown relatively high sensitivity and specificity, usually being the first-line imaging examination ⁽⁵⁾. USS is used as the standard confirmatory modality because they are relatively cheap, accessible, harmless, and can differentiate uterine fibroids from a pregnant uterus

or other adnexal tumors ⁽⁶⁾. The two main routes used for ultrasonography are the transvaginal ultrasound scans (TVUSS) and transabdominal ultrasound scans (TAUSS) routes, and ideally, both should be performed to detect, characterize and map the uterine fibroids ⁽⁷⁾. TVUSS has a higher sensitivity for smaller fibroids and is capable of visualizing fibroids as small as 5 mm ^(7,8). However, when the uterus is retroverted or bulky, TAUSS is preferred because the uterine fundus could possibly be out of view transvaginally ⁽⁷⁾. TAUSS has a wider field of view, increased transducer movement, more signal penetration ability, and offers the ability to examine other organs ⁽⁹⁾. TAUSS itself has a limitation; it is difficult to be used in very obese patients and is less effective when the uterus is greater than 300 ml in total volume ⁽⁸⁾. Noticeably, USS has several disadvantages; it has low efficacy when multiple fibroids are present since these fibroids may then produce acoustic shadows through which sound fails to propagate ⁽⁸⁾. It may miss smaller fibroids and be unable to determine the exact number and their location. USS may miss subserosal fibroids ^(7, 10). Another disadvantage associated with USS is that it

also has considerable inter-observer/intra-observer variability or operator dependence; therefore, in the hands of a less skilled user, fibroids may be missed (7). Overall, it could be interpreted that USS results have lesser reproducibility when compared to magnetic resonance imaging (MRI), which is the other diagnostic test for uterine fibroids (7).

Although MRI is more expensive, it is the most sensitive and accurate modality as it can diagnose, measure, localize and quantify all the lesions, including very small fibroids (11–13). Other than the higher sensitivity in identifying fibroids than USS, MRI also does not use any ionizing radiation. MRI provides greater spatial resolution, greater contrast resolution, and superior multiplanar capabilities. Combined, this makes MRI a superior evaluator of the uterine zone anatomy (clearly differentiating subserosal, intramural and submucosal fibroids) and also superior in its localization of small and unusually located uterine fibroids and cervical fibroids (14, 15). Additionally, MRI can also diagnose other pelvic abnormalities, and pathologies missed on the USS and is useful in assessing fibroid response to the treatment (7, 16).

Since physicians have a high probability of encountering women with uterine fibroids, and nearly 40% of them may have significant morbidity, knowledge of the diagnostic modalities for leiomyomas among them is essential for fibroid management. The aim of this study is to investigate whether USS was as accurate as MRI in diagnosing fibroids in female patients. This is the first descriptive, retrospective study conducted in the Kingdom of Bahrain evaluating the performances of MRI and pelvic USSs in diagnosing uterine fibroids.

MATERIALS AND METHODS

Study design and sample selection

This study was carried out by recruiting 205 adult female patients who underwent MRI and USS diagnostic tests to diagnose fibroids at Bahrain Defense Force (BDF) Royal Medical Services Military Hospital from January 2016 to December 2018. Ethical approval was obtained from the research and research ethics committee at BDF Hospital prior to conducting this research (reference number 338). Patients were referred from the Gynecological Department to the Radiological Department to diagnose and evaluate fibroids, regardless of their age, parity, or nationality during this period. Therefore, this descriptive, retrospective study included both the patients entitled to free care and private care patients. Patients with missing data or patients who underwent only one type of diagnostic modality were excluded.

Data extraction and diagnostic equipment

All the official radiological reports of MRI and USS

were reviewed. The USS was done at both the departments viz. Gynecological Clinics and radiological X-ray departments by different experience operators, a total of three consultant radiologists, and the reports weren't double read by external radiologists. The interpretation of findings was standardized among the radiologists. However, some USSs in the Gynecological department were retained from the primary hand-written notes. Regarding the diagnostic equipment used, all patients USSs were performed using two machines: Hitachi and General Electric (GE). USSs were carried out both trans-abdominally and trans-vaginally. Further, for MRI also, the department has two machines with different magnetic powers: GE was 3 Tesla and Siemens with 1.5 Tesla. Any patient with missing information was excluded from the study.

Statistical analysis

The software used to analyze the data was StatsDirect statistical package version 3.1.22 (Cambridge, UK, 2018). Using this software, the patients were analyzed according to their demographics such as age and nationality, parity, entitlement, symptoms, type of imaging conducted, as well as fibroid characteristics observed. Information on the clinical features of the patients observed was categorized into bleeding, irregular periods, pain, mixed symptoms, and asymptomatic. We also included the percentage of patients who underwent post-procedure imaging along with patients who did not and the patients with unknown outcomes of the care. The percentage of patients not identified with specific subcategories of fibroid site, type, and number were also reported. Normally distributed continuous variables have been presented as mean \pm SD. Non normally distributed continuous variables have been presented as median with range. Categorical variables have been presented as percentages. The Chi-square test in crosstabs was used to compare rates, and Fisher-Freeman-Halton exact was used when any cell had an expectation less than 5. P values of less than 0.05 were considered statistically significant.

RESULTS

Patient characteristics

In this study, a total of 205 female patients were diagnosed with fibroids after undergoing MRI and USS of the pelvis over the period of two years (from January, 2016 to December, 2018). The average age of the patients was 43 years (SD \pm 10.1). Among all the recruited patients, nearly 81.5% were Bahraini women and only 18.5% consisted of females from other nationalities. The majority of the women were entitled to free care (73.7%) and the other 26.3% diagnosed received treatment under private care. The predominant clinical features observed were

bleeding, irregular periods, and pain, with bleeding (23.9%) being the most common solitary symptom across the patients. Moreover, the highest percentage of females experienced mixed symptoms (32.7%). Forty-one patients were found to be asymptomatic, and 80% of the patients were with symptoms. Further, 105 patients (51.2%) did not undergo the procedure for the removal of fibroids, 91 patients (44.4%) did, and the procedural history of a few patients (4.4%) was unknown (table 1).

Table 1. History, clinical presentation, and characteristics of female patients with fibroids, admitted to Bahrain Defense Force Hospital, Bahrain.

Age (years)	Mean \pm SD 42.6 \pm 10.1 /median (range) (20-78)
Nationality	
Bahraini	167/205 (81.5%)
Others	38/205 (18.5%)
Parity	Mean \pm SD 2.3 \pm 2.5/ median (range) (0-15)
Entitlement	
Private	54/205 (26.3%)
Entitle to free care	151/205 (73.7%)
Symptoms	
Bleeding	49/205 (23.9%)
Irregular periods	12/205 (5.8%)
Pain	36/205 (17.6%)
Mixed	67/205 (32.7%)
asymptomatic	41/205 (20%)
Procedure performed	
Yes	91/205 (44.4%)
No	105/205 (51.2%)
Unknown	9/205 (4.4%)

Fibroid characteristics by MRI

Most of the cases identified in the study presented with fundal fibroid location (38%), followed by anterior (20.5%) and posterior (19.5%) sites. The least was the cervical fibroid site which was only found in 5.4% of patients.

Fibroid size is an important characteristic observed in the terms of diagnosis. The most common size of fibroids diagnosed by MRI was >2 to \leq 5 cm (44.9% of patients). Fibroids >5 to \leq 10 cm in size were the second most common subcategory diagnosed (32.2% of patients). Fibroids \leq 2 cm and >10 cm in size were seen in the smallest percentage of patients (table 2). The location of the fibroid is also an important diagnostic characteristic. Intramural (38%) was the most common fibroid type diagnosed by MRI in our patients, followed by subserosal (28.3%). Very few cases were identified for the submucosal (8.3%) and mixed (14.6%) fibroid types.

Further, approximately half of the patients diagnosed by MRI showed multiple fibroids (>3) [102 patients (49.8%)]. The second most common type was single fibroids (35.6%), and these were followed by two fibroids (11.2%). The fibroid numbers in a

small percentage of patients were not identified in this study.

Table 2. Fibroid characteristics observed under magnetic resonance imaging in patient sample.

Uterine volume cm ³	Mean \pm SD 398 \pm 376 median (range) (25-2479)
Fibroid site	
Anterior	42/205 (20.5%)
Posterior	40/205 (19.5%)
Lateral	21/205 (10.2%)
Fundal	78/205 (38%)
Cervical	11/205 (5.4%)
Complex	12/205 (5.9%)
Not identified	1/205 (0.5%)
Fibroid size	
0 to \leq 2 cm	38/205 (18.5%)
>2 cm to \leq 5 cm	92/205 (44.9%)
>5 cm to \leq 10 cm	66/205 (32.2%)
>10 cm	9/205 (4.4%)
Fibroid type	
Sub serosal	58/205 (28.3%)
Submucosal	17/205 (8.3%)
Intramural	78/205 (38%)
Mixed	30/205 (14.6%)
Not identified	22/205 (10.7%)
Fibroid number	
1 fibroid	73 (35.6%)
2 fibroids	23 (11.2%)
3 fibroids	5 (2.4%)
Multiple fibroids	102 (49.8%)
Not identified	2/205 (1%)

USS findings weighed against MRI findings

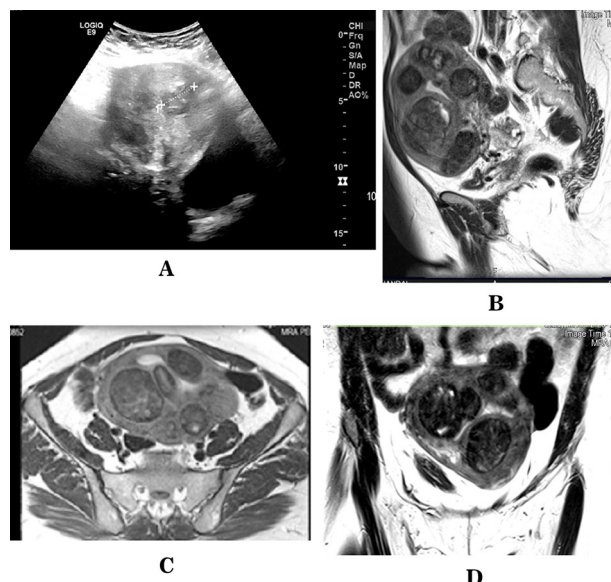
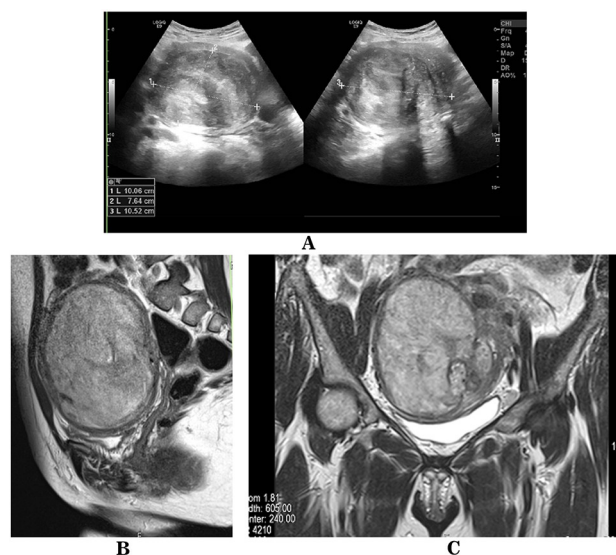
In regard to the fibroid site, the highest percentage of the matched scan to the MRI was in the posterior fibroid sites (52.5%), showing that more than half of the scan cases matched the gold standard diagnostic method ($P=0.0004$). Anterior fibroid sites followed at 38.1% and the fundal at 21.8%. Cervical fibroid sites had 18.2% of the scans matching the MRI, and the match rates were not good for the lateral fibroid sites (9.5%) (table 3).

A trend in the fibroid size was also noted revolving around the matching of US scans to the MRI findings. The highest percentages of matching findings were with fibroid sizes between >5 to \leq 10 cm (83.3%) ($p=0.008$), followed by >2 to \leq 5 cm and 0 to \leq 2 cm, respectively. Surprisingly, fibroids more than 10 cm in size were observed to have the lowest match (33.3%). Moreover, the highest matched scans for the fibroid types were observed in intramural (44.9%) ($P=NS$) and subserosal (44.8%) compared to the mixed types being only 10% (table 3) (figures 1 and 2).

The highest agreement found in identifying the fibroid number was in the presence of multiple fibroids at 61.8% ($p=NS$), followed by a single fibroid at 54.8%. The lowest matching was observed with two fibroids at 34.8% (table 3).

Table 3. Ultrasound scan of patients with fibroids correlating with magnetic resonance imaging findings.

	MRI findings	USS matching MRI findings	P value
Fibroid site			
Anterior	42/205 (20.5%)	16/42 (38.1%)	NS
Posterior	40/205 (19.5%)	21/40 (52.5%)	0.0004
Lateral	21/205 (10.2%)	2/21 (9.5%)	NS
Fundal	78/205 (38%)	17/78 (21.8%)	NS
Cervical	11/205 (5.4%)	2/11 (18.2%)	NS
complex	12/205 (5.9%)	0/12 (0%)	NS
Fibroid size			
0 to ≤ 2 cm	38/205 (18.5%)	14/38 (36.8%)	<0.0001
>2 cm to ≤ 5 cm	92/205 (44.9%)	72/92 (78.3%)	0.03
>5 cm to ≤ 10 cm	66/205 (32.2%)	55/66 (83.3%)	0.008
>10 cm	9/205 (4.4%)	3/9 (33.3%)	0.04
Fibroid type			
Sub serosal	58/205 (28.3%)	26/58 (44.8%)	NS
Submucosal	17/205 (8.3%)	5/17 (29.4%)	NS
Intramural	78/205 (38%)	35/78 (44.9%)	NS
mixed	30/205 (14.6%)	3/30 (10%)	0.001
Fibroid number			
1 fibroid	73/205 (35.6%)	40/73 (54.8%)	NS
2 fibroids	23/205 (11.2%)	8/23 (34.8%)	NS
3 fibroids	5/205 (2.4%)	2/5 (40%)	NS
Multiple fibroids	102/205 (49.8%)	63/102 (61.8%)	NS

**Figure 2.** MRI findings are superior to US findings, A- US, B-Sagittal T2WI, C- Axial T2WI, D-Coronal T2WI of the same patient shows only one fibroid in US compared to five fibroids in MRI.**Figure 1.** MRI and US of the same patient have the same fibroid findings, A-US images, B-Sagittal T2W and C-Coronal T2W of the same patient showing one large uterine fibroid.

DISCUSSION

Previously published studies have compared the merits of USS and MRI findings with regard to fibroid management. It has been cumulatively observed that MRI has more sensitivity and better specificity, indicating the numbers of fibroids present and their location more accurately ⁽¹⁴⁾. Consequently, MRI has been widely considered to represent the gold standard in such radiological investigations. In one recent study, more than half the patients who underwent USS were found to have additional gynecological problems after undergoing MRI ⁽¹⁶⁾. For these reasons, MRI is seen as the gold standard

investigation as it can detect other gynecological abnormalities in addition to fibroids. It has been noted that women with fibroids can present with non-specific symptoms, and on the contrary, they can also be asymptomatic ^(1, 17). In this study, 20% of the patients were found to be asymptomatic. Typical symptoms observed in the case of fibroids were infertility, dysmenorrhea, pelvic pain and menorrhagia, which are broad and non-specific ^(3, 18).

In a study by Dueholm and colleagues (2002), it was reported that the average number of fibroids located by MRI was 15 ± 2.8 compared to TVUSS, which located 8 ± 2.6 fibroids. USS missed more fibroids than MRI, and the discrepancy almost doubled when fibroids were classified according to both the position and uterine wall embedment ⁽¹⁹⁾. Levens' study showed that MRI is twice as sensitive as USS in diagnosing fibroids with a rate of 80% compared to 40% ⁽²⁰⁾. Our data showed that the best correlation between USS and MRI findings was in the cases with multiple fibroids over the three categories, as shown in table 3. This finding needs to be considered with caution, as we assessed the matching in the group of patients with over three fibroids without being specific about their number. It could be explained as when USS detected four fibroids, and MRI confirmed the presence of more fibroids in the same patient, the data entry was still considered matched. Noticeably, the accurate and clear observation is that when there is only one fibroid, the chance of matching with the scan was over 50%.

Detection of subserous fibroids using USS showed to have reduced sensitivity, with some fibroids being undetectable or completely missed in some cases ⁽²¹⁾. In our study, USS matched the MRI findings in 44.8% of the subserosal fibroids. Our study demonstrated variable matching abilities between USS and MRI in

different fibroid types. The data of the present study further confirmed that submucosal fibroids are usually difficult to be differentiated on the USS scan. Only 29% of those cases matched the MRI findings. Other contributing factors would have been added to the equation, such as the size and the site. Contrary to our finding, a study by the Ahmad group found USS to have higher specificity and positive prediction value (PPV) than MRI in diagnosing the submucous fibroids.

In the study conducted by De La Cruz *et al.*, fibroids were classified according to size, site, and number, but no percentages were given for the rate of occurrence for each individual characteristic of fibroids. The best matching site was the posteriorly located fibroid in the present study. This could be due to the angle of the vagina, where the posterior wall would be more accessible and nearer to the TVUSS. Surprisingly, our study showed that the cervical fibroids had a lower matching rate than the MRI. This could simply be due to the mislabeling as anterior or posterior rather than cervical. Determining the accurate size of the fibroids is crucial for its management plan. In a previous study analyzing fibroid size, USS underestimated the size of a large 16.6 cm diameter fibroid to be 12.5 cm ⁽²²⁾. The findings of our study were in line with this previously published data and showed that fibroids over 10 cm correlated poorly with the USS (matching only 33.3% of cases) (table 3). However, the USS findings in our study matched very well with the MRI findings in the case of fibroids between 2 and 10 cm in diameter.

There are limitations to all of these studies, as technical skills play a crucial role in producing accurate USS results. The reality is that different levels of experience and competence influence the findings, as do the differences between the models of USS and MRI machines used. In addition, missing data reported as non-identified could also skew the results. Increasing the sample size of the study could help to reduce the error, but it will not entirely eliminate it.

CONCLUSION

Although MRI has been considered superior in fibroids diagnosis based on its various properties, it does not negate the merits of USS as a preliminary diagnostic tool, especially where MRI is not readily accessible. In the present study, USS and MRI findings correlated reasonably well in terms of posterior wall and fibroids sized less than 2 cm.

ACKNOWLEDGMENTS

We would like to thank the RCSI summer research school and BDF hospital for helping in conducting this research.

Competing interests: The authors declare that they have no competing interests.

Ethics approval and consent to participate: The ethical approval was obtained from the research and research ethics committee at BDF hospital prior to conducting this research (reference number 338). An ethical approval form was also obtained from the RCSI Bahrain summer research to enroll the medical students (Amal Mohamed Mehad, Simbarashe Matoi, Seemal Maqsood, Ayomide Peluola) to participate in this paper. The research was conducted in accordance with the 1964 Helsinki Declaration.

Funding: This research did not receive any specific grant from the funding agencies in the public, commercial, or not-for-profit sectors.

Authors' contributions:

BAO and ND contributed to the study conception and design. The data collection was performed by SM. The first draft of the manuscript was written by AMM, SM and AP. The final version was revised by BAO and AMM. The English proofing was done by RO. The project supervision was done by ND and all authors commented on previous versions of the manuscript. All authors read and approved the final manuscript. Authors testify that all persons designated as authors qualify for authorship and have checked the article for plagiarism.

REFERENCES

1. Woźniak A and Woźniak S (2017) Ultrasonography of uterine leiomyomas. *Przegląd menopauzalny= Menopause Rev*, **16**: 113.
2. Aboulghar M, Al-Inany H, Aboulghar M, Serour G, Mansour R (2004) The effect of Intramural Fibroids on the Outcome of IVF. *Middle East Fertil Soc J*, **9**: 263–267.
3. Bolan C and Caserta MP (2016) MR imaging of atypical fibroids. *Abdominal Radiol*, **41**: 2332–2349.
4. Morin SJ and Schlaff WO (2017) Optimal approaches to fibroid management: consider fibroid location and the patient's pregnancy plans. *Contemporary OB/GY*, **62**: 21–26.
5. Wise LA, Radin RG, Palmer JR, Kumanyika SK, Boggs DA, Rosenberg L (2011) Intake of fruit, vegetables, and carotenoids in relation to risk of uterine leiomyomata. *Am J Clin Nutr*, **94**: 1620–1631.
6. Stewart EA (2015) Uterine fibroids. *N Eng J Med*, **372**: 1646–1655.
7. Khan A, Shehmar M, Gupta J (2014) Uterine Fibroids: Current Perspectives. *Int J Women's Health*, **6**: 95–114.
8. McLucas B (2008) Diagnosis, Imaging and Anatomical Classification of Uterine Fibroids. *Best Pract Res Clin Obstet Gynaecol*, **22**: 627–642.
9. Testa AC, Di Legge A, Bonatti M, Manfredi R, Scambia G (2016) Imaging techniques for evaluation of uterine myomas. *Best Pract Res Clin Obstet Gynaecol*, **34**: 37–53.
10. De La Cruz M and Buchanan E (2017) Uterine Fibroids: Diagnosis and Treatment. *Am Fam Physician*, **95**: 100–107.
11. Badawy M, Elkholi D, Sherif M, Hefedah M (2015) Magnetic resonance imaging for diagnosis of pelvic lesions associated with female infertility. *Middle East Fertil Soc J*, **20**: 165–175.
12. Parker W (2007) Etiology, Symptomatology, and Diagnosis of Uterine Myomas. *Fertil Steril*, **87**: 725–736.
13. Hossain MZ, Rahman MM, Ullah MM, Mukthadira M, Akter FA, Jahan AB (2017) A Comparative study of magnetic resonance imaging and trans abdominal ultrasonography for the diagnosis and evaluation of uterine fibroids. *Mymensingh Med J*, **26**: 821–827.
14. Rashid S, Chou Y, Tiu C (2016) Ultrasonography of Uterine Leiomyomas. *J Med Ultrasound*, **24**: 3–12.
15. Ahmad R, Sadek S, Ragheb A (2015) Evaluation of the Uterine

- Cavity by Magnetic Resonance Imaging, Three Dimensional Hysterosonography and Diagnostic Hysteroscopy in Women with Pre- and Post-menopausal Bleeding. *Middle East Fertil Soc J*, **20**: 70–78.
16. Vu K, Fast A, Shaffer R, Rosenberg J, Dababou S, Marrocchio C (2019) Evaluation of the Routine Use of Pelvic MRI in Women presenting with Symptomatic Uterine Fibroids: When is Pelvic MRI useful? *J Magn Reson Imaging*, **49**: e271–e281.
 17. Elkattan E, Kamel R, Elghazaly H, ElAriki E (2016) Can Three-Dimensional (3D) Power Doppler and Uterine Artery Doppler differentiate between Fibroids and Adenomyomas? *Middle East Fertil Soc J*, **21**: 46–51.
 18. Abbas H, Awad I, Alharbi E, Alameri H, Althubaiti S, Ashkar L (2016) Prevalence and Incidence of Uterine Fibroid at King Abdulaziz University Hospital Saudi Arabia. *Clin Med Diagn*, **6**: 45-48.
 19. Dueholm M, Lundorf E, Hansen E, Ledertoug S, Olesen F (2002) Accuracy of Magnetic Resonance Imaging and Transvaginal Ultrasonography in the Diagnosis, Mapping, and Measurement of Uterine Myomas. *Am J Obstet Gynecol*, **186**: 409-415.
 20. Levens E, Wesley R, Premkumar A, Blocker W, Nieman L (2009) Magnetic Resonance Imaging and Transvaginal Ultrasound for Determining Fibroid Burden: Implications for Research and Clinical Care. *Am J Obstet Gynecol*, **200**: 537–e1.
 21. De La Cruz M and Buchanan E (2017) Uterine Fibroids: Diagnosis and Treatment. *Am Fam Physician*, **95**: 100-107.
 22. Spielmann A, Keogh C, Forster B, Martin M, Machan L (2006) Comparison of MRI and Sonography in the Preliminary Evaluation for Fibroid Embolization. *Am J Roentgenol*, **187**: 1499-1504.