

# Concurrent administration of Hydroxychloroquine and whole brain radiation therapy for patients with brain metastases

F. Farhan<sup>1</sup>, S. Mansouri<sup>1</sup>, F. Samiee<sup>1</sup>, A. Kazemian<sup>1</sup>, B. Kalaghchi<sup>1</sup>,  
M. Lashkari<sup>1</sup>, H. Alizadeh<sup>2</sup>, M. Yamrali<sup>1\*</sup>

<sup>1</sup>Radiation Oncology Research Center (RORC), Cancer Institute, Tehran University of Medical Sciences, Tehran, Iran

<sup>2</sup>Department of Pediatric Radiology, Children's Medical Center, Tehran University of Medical Sciences, Tehran, Iran

## ABSTRACT

### ► Original article

#### \*Corresponding author:

Maisa Yamrali, M.D.,

E-mail: maisa36@yahoo.com

Received: September 2021

Final revised: June 2022

Accepted: June 2022

Int. J. Radiat. Res., October 2022;  
20(4): 809-813

DOI: 10.52547/ijrr.20.4.12

**Keywords:** Whole brain radiation therapy, hydroxychloroquine, brain metastases, autophagy, radio-sensitizers.

**Background:** The main purpose of the present study was to evaluate the safety and efficiency of concurrent administration of hydroxychloroquine (HCQ) and whole brain radiation therapy (WBRT) in patients with brain metastases. Based on numerous preclinical reports, inhibition of autophagy by HCQ can significantly enhance the efficacy of DNA-damaging therapies improving results of radiation therapy. The primary end point of this study was response to treatment and complications, determined by the National Cancer Institute Common Toxic Criteria for Adverse Events (CTCAE) scale V5.0. **Material and Methods:** Patients with pathologically-confirmed primary solid malignancies together with single or multiple brain metastases on magnetic resonance imaging (MRI) were enrolled in the study (n=64). Treatment with HCQ (200 mg/P.O. once daily) was begun concurrent with WBRT (total dose of 30 Grays (Gy) in 10 daily fractions) in case group. Control group received the standard regimen. **Results:** Analysis of complications and response rate at each follow up points revealed no statistically significant differences between the case and control groups. Although, median brain metastasis specific Progression Free Survival (PFS) was non-significantly longer in HCQ group compared to control. No grade 3 or more severe toxicities were reported during therapy in both groups of the study. **Conclusion:** Although concurrent administration of HCQ with WBRT in patients who suffers from brain metastases was well tolerated, this combination did not meaningfully improve outcomes in comparison to WBRT alone.

## INTRODUCTION

Almost 20% of patients diagnosed with cancer will progress brain metastasis during their disease journey, with great portion of them being those with breast, colorectal and lung cancers, renal cell carcinoma and melanoma <sup>(1)</sup>. Due to the complicated nature of the disease, especially when symptomatic, treatment options at the time of diagnosis are mostly limited. Furthermore, the choice of surgical resection is precluded in most cases due to the existence of several metastases at different sites of brain. Unfortunately, based on several clinical reports, chemotherapeutic agents are only effective in a narrow spectrum of highly chemo-sensitive primary tumors <sup>(2-4)</sup>.

The value of radiation therapy, irrespective of the primary tumor's histological characteristics, was confirmed in the treatment of brain metastases originated from both radio-resistant and radio-sensitive tumors <sup>(5)</sup>. This peerless potency of radiation to efficiently alleviate brain metastases regardless of primary tumor's histology has turned whole brain radiation therapy (WBRT) to the cornerstone of brain metastases therapy through

relieving symptoms, reducing the need for corticosteroids for controlling tumor related edema and potentially, improving the quality of life <sup>(6-8)</sup>.

Yet, an important approach to further improve WBRT's efficacy in treating brain metastases is application of radiation sensitizers. Chloroquine (CQ) and its most important derivative Hydroxychloroquine (HCQ), agents with anti-malarial activity for more than a half of century, are two potential radiation sensitizers which have recently been studied for potential application concurrent with radiation therapy. CQ and HCQ have shown to be effective in modulating inflammation and immune responses, as well as improving sensitivity to cancer therapies. Besides, these agents are capable of inducing apoptosis through the activation of p53 pathway and blocking autophagy, an important cellular process sustaining cancer cell survival under stressful conditions in glioma cells <sup>(9)</sup>. Most importantly, based on recent prospective randomized clinical trials, concurrent administration of low doses of CQ with external beam radiotherapy and chemotherapy improved responses to treatment and enhanced overall survival in high-grade glioma patients <sup>(10, 11)</sup>.

As HCQ has immunological effects, it may play role as a safe radiation sensitizer in combination with WBRT in the management of brain metastasis. In addition, HCQ and CQ are equipotent in inhibiting autophagy, the most important mechanism responsible for their radio-sensitizing effects, and since HCQ induces less cumulative retinal toxicity<sup>(12)</sup>, we hypothesized that HCQ may serve as a safer and better radiation sensitizer in combination with WBRT in the treatment of brain metastases. In the present study, we investigated the outcomes of concurrent HCQ with WBRT in terms of drug tolerability, clinical response, progression free survival and adverse effects in Iranian patients with brain metastases.

## MATERIALS AND METHODS

### Patient selection

Following approval of the study protocol by "Ethics committee of Tehran University of Medical Sciences (registration code: IR.TUMS.VCR.REC.1395.593)", informed consent was acquired from each patient. To be considerable for inclusion in the study, patients must have had a pathologically-confirmed primary tumor together with single or multiple brain metastases on magnetic resonance imaging (MRI) and Karnofsky performance status (KPS) of more than 70. Patients only received HCQ in the case which physicians confirmed that the drug may not cause any complications to them. Exclusion criteria consisted of pregnancy, prior history of brain radiotherapy, cardiomyopathy, hypotension, epilepsy or any hypersensitivity reactions to 4-aminoquinolone agents. Patients were also withdrawn from the study if any visual or auditory complications or severe gastrointestinal complications including diarrhea or vomiting were observed during HCQ therapy.

### Administration of HCQ during WBRT

All patients underwent computerized tomography scan (Philips® CT scanner) and whole brain contouring was performed in all patients prior to treatment. WBRT was delivered in total dose of 30 Grays (Gy) in 10 daily fractions via a linear accelerator (Elekta Compact™, Sweden). For reproducing daily positioning, all patients were positioned in supine direction while wearing a head immobilizing mask. HCQ under the brand name of Modaqueuil® (Modif pharmaceutical Co., Iran) was used in the study. Administration of HCQ with a dose of 200 mg/day orally began from the first day of radiation therapy and continued for a total of 4 weeks. The other group was treated with the similar schedule without HCQ.

### Endpoints and statistical analysis

Response to treatment was the primary end point of the study and also complications, determined by

one score change in patients' neurological complications including headache, nausea, vertigo, ataxia, sensory or motor dysfunction, and visual disturbance, based on the National Cancer Institute Common Toxic Criteria for Adverse Events (CTCAE V5.0) scale<sup>(13)</sup>. Weekly patient visits were performed during the treatment as well as the first 30 days after completing the treatment for all patients. Afterwards, follow up visits continued every 3 months for one year. Data were analyzed using SPSS software (IBM®, USA). Mantel-Haenszel test was used for comparing CTCAE's scores between two groups of the study. Progression free survival and toxicities were included as secondary end points and measured by the Kaplan-Meier method and univariable cox-regression analysis.

## RESULTS

### Patient evaluation

From the year 2016 to 2018, a total of sixty-four patients entered the study among which 26 were male and 38 were female. Mean patient age was  $56.8 \pm 1.4$  years while it was  $62.7 \pm 2.1$  and  $52.8 \pm 1.6$  years in males and females respectively. The median age of the patients was 57 years, ranging from 26-77. Tumor characteristics, as well as patient's demographic data are depicted in table 1. Concurrent HCQ and WBRT lasted for 14 days and HCQ was then continued for 14 more days (total of 28 days). The clinical follow up continued for up to 12 months from the beginning of HCQ. Fifty-six patients completed the therapy. Among the 8 withdrawn patients, four died and 4 were lost to follow because of lack of compliance to therapy. Remaining fifty-six patients completed radiotherapy without any treatment interruptions due to adverse effects or toxicity. Figure 1 shows a patient with brain metastasis in MRI (A) and treatment planning based on contouring on CT slices (B and C).

### Clinical response and patient survival

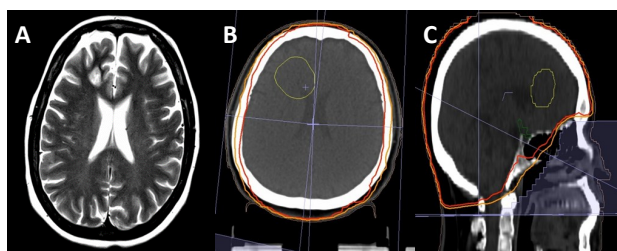
Neurological complications of patients were evaluated weekly for the first month and then every 3 months following concurrent HCQ and WBRT therapy. Analysis of complications and response rate at each follow up visits demonstrated non-significant differences between the two groups of the study.

At the end of study, twenty-nine patients had passed away among which fourteen belonged to the group receiving concurrent HCQ and WBRT. As depicted in table 2, analysis of the causes of death did not demonstrate any significant differences between the two groups. The median progression free survival (PFS) for the evaluated population was estimated to be 8.17 months. The estimated six-month PFS rates for treatment and control groups (0.23 and 0.58 respectively) did not significantly differ from each other. Same result was also observed for

twelve-month PFS rates (0.44 and 0.48 respectively). In addition, although the brain metastases specific PFS was longer in the group receiving concurrent HCQ and WBRT, the difference was not statistically significant (13 vs. 11.9 months,  $P > 0.05$ ). Also, sub-group analysis for PFS in terms of tumor size, age, number of brain lesions and having extracranial metastases, did not demonstrate any significant differences between the two groups (table 2).

**Table 1.** Summary of demographic and clinicopathologic data.

Variables	No of patients	Hydroxychloroquine	Control	P value
Age				NS
>55	32	16	16	
<55	32	16	16	
Missing		0	0	
Extra-cranial metastasis				0.446
Present	31	13	18	
Absent	31	18	13	
Missing		1	1	
No of lesions				0.005
Single	9	8	1	
2-4 lesions	24	14	10	
>4 lesions	22	5	17	
Missing		5	4	
Primary origin				0.195
Breast cancer	21	8	13	
Lung cancer	20	11	9	
Colorectal cancer	8	4	4	
Head and neck cancer	4	4	0	
Renal cell carcinoma	2	1	1	
Cancer of unknown origin	2	2	0	
Ovary	2	0	2	
Endometrial cancer	1	1	0	
Prostate	1	0	1	
Esophagus	1	1	0	
Missing		0	2	
<b>Sex 0.446</b>				
Male	26	15	11	
Female	38	17	21	
Missing		0	0	

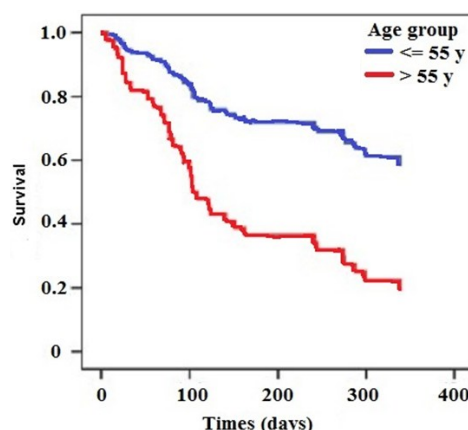


**Figure 1.** 58 years old woman with brain metastasis. A: the MRI shows an enhancing mass in right frontal lobe, near the anterior horn of third ventricle, representing a brain metastasis. B: planning target volume (PTV) was contoured on axial CT slice (yellow line). Isodoses 95% and 90% were shown with red and orange lines, respectively. C: lines related to isodoses 95% and 90% were shown on sagittal view of CT.

Based on the univariate cox-regression analysis, the relative risk of recurrence or death in patients aged 55 or older was significantly higher in comparison to the younger group ( $P=0.003$ ). Figure 2 represents the differences of PFS between patients aged 55 or older and younger ones. Other variables including gender ( $P=0.17$ ), tumor size ( $P=0.65$ ), tumor site ( $P=0.45$ ), number of brain lesions ( $P=0.09$ ) and presence or absence of extracranial metastases ( $P=0.06$ ) did not make any significant differences between groups. The univariate Cox-regression analysis for clinical characteristics is shown in table 3.

**Table 2.** Specific deaths in two arms.

	No of patients	Hydroxychloroquine	Control	P value
Specific death				0.198
Brain metastasis	13	8	5	
Extracranial progression	16	6	10	
Missing		0	0	



**Figure 2.** Kaplan–Meier curve. As it was shown in the picture, PFS in patients with 55 years and more was significantly lower compared to the younger ones.

**Table 3.** Univar able Cox-regression analysis for age, sex, extra-cranial metastasis, number of lesions and primary origin

Risk factors	$\beta$ coefficient	Standard error	HR	P value
Age (55 $\leq$ / 55 $>$ )	-1.2	0.38	0.33	0.003
Sex (male/female)	-0.48	0.35	0.62	0.17
Extra-cranial metastasis (absent/present)	-0.7	0.37	0.5	0.06
No. of lesions (4 $\leq$ /4 $>$ )	-0.65	0.38	0.52	0.09
Primary origin (breast/other sites)	-0.28	0.44	0.36	0.52
Primary origin (lung/other sites)	0.25	0.48	0.78	0.61

### Treatment toxicity

Hematologic toxicities (such as neutropenia, anemia and pan cytopenia), cardiac toxicities (including long QT interval, arrhythmia and cardiomyopathy), gastrointestinal toxicities (including nausea, vomiting, diarrhea), neurologic toxicities (such as headache, blurry vision, vertigo, and nystagmus), skin toxicities (such as rash and dry skin), liver dysfunction and hyperglycemia were

surveyed during determined time intervals during this study. None of the well-documented toxicities of HCQ was different between the case and control group ( $p$  value > 0.05). Furthermore, no radiotherapy treatment interruptions occurred for any patient during treatment. Also, no grade 3 or more toxicities were recorded during therapy.

## DISCUSSION

The efficacy of numerous schedules of dose and radiation fractionations in the management of patients with brain metastases had been evaluated in different prospective clinical trials, but none had shown significant improvement in survival so far (14-17). As results of radiation dose escalations up to more than 50 Gy did not reveal any significant improvement in survival outcomes, many researchers have now focused on using a group of pharmacological agents with the capability of radiation sensitizing in order to further the outcomes of WBRT. Among different studied agents, only few have shown effectiveness without causing serious adverse effects (18-22). Motexafin gadolinium and efaproxaril are two promising examples of these radio-sensitizers which have shown promising results in improving survival and quality of life of breast cancer patients with brain metastases (23-25).

CQ and HCQ, are among the most potent inhibitors of the process of autophagy. These agents have long been used for treating malaria, as well as other disorders including rheumatoid arthritis, and human immunodeficiency virus (HIV) infection (26-28). Both agents are available as cost-effective oral formulations and demonstrate good penetration into central nervous system. Based on results of in-vitro studies, doses required for blocking tumor cell autophagy and inducing cell death are higher compared to the ones required for demonstrating anti-rheumatoid and anti-malarial effects. As autophagy induced by radiation in most cases provides a protective function in cell culture studies, autophagy inhibitors may be considered as an effective group of radio-sensitizers.

In a study performed on 20 patients with intracranial metastases (NCT01894633), concurrent administration of 250 mg CQ once daily, started 1 week prior to WBRT, and WBRT resulted in complete response in two patients and partial response in 16 patients. This treatment did not demonstrate any grade 3/4 toxicities and evaluated mean overall survival was equal to 8.9 months (29). Similarly, the study conducted by Rojas-Puentes et al. (30) showed that administration of 150 mg CQ concurrent with radiation for brain metastasis can improve local control and PFS but not OS.

Since previous studies have shown that adding CQ to radiotherapy for the treatment of brain metastases increases the efficacy of radiotherapy and HCQ

causes less toxicity compared to CQ, we decided to administer HCQ concurrent with whole brain radiotherapy. This combination treatment was well tolerated, but the administered dose of HCQ did not result in any significant improvement in PFS rates. Also, we observed that PFS in patients with 55 years and more was significantly lower compared to the younger ones.

## CONCLUSION

Administration of CQ concurrent with brain radiation has been shown to be effective in terms of longer PFS. However, HCQ does not seem to be a proper alternative for CQ, despite demonstrating a safer toxicity profile.

## ACKNOWLEDGEMENT

We would like to thank all of our colleagues in radiation oncology department of Cancer institute.

**Conflict of interest:** The authors declare no conflict of interest.

**Ethical considerations:** The study was approved by "Ethics committee of Tehran University of Medical Sciences" (registration code: IR.TUMS.VCR.REC.1395.593).

**Author contribution:** F. Farhan: Study design. S. Mansouri: Writing the manuscript. F. Samiee and H. Alizadeh: Reviewing and editing the manuscript. B. Kalaghchi and A. Kazemian: Planning radiation therapy. M. Lashkari: Data analysis. M. Yamrali: Data collection.

## REFERENCES

1. Achrol A, Rennett R, Anders C, Soffiatti R, S. Ahluwalia M, Nayak L, et al. (2019) Brain metastases. *Nat Rev Dis Primers*, **5**: 5.
2. van den Bent M (2003) The role of chemotherapy in brain metastases. *Eur J Cancer*, **39**: 2114-2120.
3. Gremmer R, Schröder M, ten Huinink W, Brandsma D, Boogerd W (2008) Successful management of brain metastasis from malignant germ cell tumours with standard induction chemotherapy. *J Neurooncol*, **90**: 335-339.
4. Goldstein D and Berkowitz R (2012) Current management of gestational trophoblastic neoplasia. *Hematol Oncol Clin North Am*, **26**: 111-131.
5. Chao J, Phillips R, Nickson J (1954) Roentgen-ray therapy of cerebral metastases. *Cancer*, **7**: 682-689
6. Andrews D, Scott C, Sperduto P, et al. (2004) Whole brain radiation therapy with or without stereotactic radiosurgery boost for patients with one to three brain metastases: phase III results of the RTOG 9508 randomised trial. *Lancet*, **363**: 1665-1672.
7. Bezjak A, Adam J, Panzarella T, Levin W, Barton R, Kirkbride P, et al. (2001) Radiotherapy for brain metastases: defining palliative response. *Radiother Oncol*, **61**: 71-76.
8. Gaspar L, Scott C, Rotman M, Asbell S, Phillips T, Wasserman T, et al. (1997) Recursive partitioning analysis (RPA) of prognostic factors in three radiation therapy oncology group (RTOG) brain metastases trials. *Int J Radiat Oncol Biol Phys*, **37**: 745-751
9. Kim E, Wustenberg R, Rubsam A, Schmitz-Saluc C, Warnecke G, Bucker E, et al. (2010) Chloroquine activates the p53 pathway and induces apoptosis in human glioma cells. *Neuro-Oncology*, **12**: 389-40010.
10. Briceño E, Calderon A, Sotelo J (2007) Institutional experience with chloroquine as an adjuvant to the therapy for glioblastoma multiforme. *Surg Neurol*, **67**: 388-391.



11. Sotelo J, Briceño E, López-González M (2006) Adding chloroquine to conventional treatment for glioblastoma multiforme. *Ann Intern Med*, **144**: 337.
12. Marmor M, Kellner U, Lai T, Lyons J, Mieler W (2011) Revised Recommendations on Screening for Chloroquine and Hydroxychloroquine Retinopathy *Ophthalmol*, **118**: 415-422.
13. Freitas-Martinez A, Santana N, Arias-Santiago S, Viera A (2021) Using the common terminology criteria for adverse events (CTCAE – Version 5.0) to evaluate the severity of adverse events of anti-cancer therapies. (*English Edition*) *Actas Dermosifiliogr*, **112**: 90-92.
14. Borgelt B, Gelber R, Larson M, Hendrickson F, Griffin T, Roth R (1981) Ultra-rapid high dose irradiation schedules for the palliation of brain metastases: Final results of the first two studies by the radiation therapy oncology group. *Int J Radiat Oncol Biol Phys*, **7**: 1633-1638.
15. Davey P, Hoegler D, Ennis M, Smith J (2008) A phase III study of accelerated versus conventional hypofractionated whole brain irradiation in patients of good performance status with brain metastases not suitable for surgical excision. *Radiother Oncol*, **88**: 173-176
16. Haie-Meder C, Pellae-Cosset B, Laplanche A, Lagrange J, Tuchais C, Nogues C, et al. (1993) Results of a randomized clinical trial comparing two radiation schedules in the palliative treatment of brain metastases. *Radiother Oncol*, **26**: 111-116
17. Murray K, Scott C, Greenberg H, Emami B, Seider M, Vora N, et al. (1997) A randomized phase III study of accelerated hyperfractionation versus standard in patients with unresected brain metastases: A report of the radiation therapy oncology group (RTOG) 9104. *Int J Radiat Oncol Biol Phys*, **39**: 571-574.
18. Antonadou D, Paraskevaidis M, Sarris G, Coliarakis N, et al. (2002) Phase II randomized trial of temozolomide and concurrent radiotherapy in patients with brain metastases. *J Clin Oncol*, **20**(17): 3644-3650.
19. DeAngelis L, Currie V, Kim J, Krol G, O'Hehir M, Farag F, et al. (1989) The combined use of radiation therapy and lisdamine in the treatment of brain metastases. *J Neurooncol*, **7**(3): 241-7.
20. Eyre H, Ohlsen J, Frank J, LoBuglio A, McCracken J, Weatherall T, et al. (1984) Randomized trial of radiotherapy versus radiotherapy plus metronidazole for the treatment metastatic cancer to brain. *J Neurooncol*, **2**(4): 325-330.
21. Komarnicky LT, Phillips T, Martz K, Asbell S, Isaacson S, Urtasun R (1991) A randomized phase iii protocol for the evaluation of miso-nidazole combined with radiation in the treatment of patients with brain metastases (RTOG-7916). *Int J Radiat Oncol Biol Phys*, **20**: 53-58.
22. Phillips T, Scott C, Leibel S, Rotman M, Weigensberg I (1995) Results of a randomized comparison of radiotherapy and bromodeoxyuridine with radiotherapy alone for brain metastases: Report of RTOG trial 89-05. *Int J Radiat Oncol Biol Phys*, **33**: 339-348.
23. Mehta M, Shapiro W, Phan S, et al. (2009) Motexafin gadolinium combined with prompt whole brain radiotherapy prolongs time to neurologic progression in non-small-cell lung cancer patients with brain metastases: Results of a phase III trial. *Int J Radiat Oncol Biol Phys*, **73**: 1069-1076.
24. Scott C, Suh J, Stea B, Nabid A, Hackman J (2007) Improved survival, quality of life, and quality-adjusted survival in breast cancer patients treated with efaproxiral (Efaproxyn) plus whole-brain radiation therapy for brain metastases. *Am J Clin Oncol*, **30**: 580-587.
25. Suh J, Stea B, Nabid A, et al. (2006) Phase III Study of Efaproxiral As an Adjunct to Whole-Brain Radiation Therapy for Brain Metastases. *J Clin Oncol*, **24**: 106-114
26. O'Neill P, Bray P, Hawley S, Ward S, Park B (1998) 4-Aminoquinolines—Past, present, and future; A chemical perspective. *Pharmacol Ther*, **77**: 29-58.
27. Romanelli F, Smith K, Hoven A (2004) Chloroquine and Hydroxychloroquine as Inhibitors of Human Immunodeficiency Virus (HIV-1) Activity. *Curr Pharm Des*, **10**: 2643-2648.
28. Katz S and Russell A (2011) Re-evaluation of antimalarials in treating rheumatic diseases: re-appreciation and insights into new mechanisms of action. *Curr Opin Rheumatol*, **23**: 278-281.
29. Eldredge H, DeNittis A, DuHadaway J, Chernick M, Metz R, Prendergast G (2013) Concurrent whole brain radiotherapy and short-course chloroquine in patients with brain metastases: a pilot trial. *Radiat Oncol J*, **2**: 315-321.
30. Rojas-Puentes L, Gonzalez-Pinedo M, Crismatt A, Ortega-Gomez A, Gamboa-Vignolle C, Nuñez-Gomez R, Dorantes-Gallareta Y, Arce-Salinas C, Arrieta O (2013) Phase II randomized, double-blind, placebo-controlled study of whole-brain irradiation with concomitant chloroquine for brain metastases. *Radiat Oncol*, **8**: 209.
31. Brazil L, Swampillai A, Mak K, et al. (2018) P01.072 Hydroxychloroquine and short course radiotherapy for elderly patients with glioma: a randomised study. *Neuro Oncol*, **20**: iii246-iii246.

