

Choline glycerophosphate and silymarin modulate brain and intestinal injuries in rats exposed to gamma-radiation

N. Abdel-Aziz¹, A.A. Elkady^{2*}, E.M. Elgazzar²

¹Radiation Biology Research Department, ²Health Radiation Research Department, National Centre for Radiation Research and Technology (NCRRT), Egyptian Atomic Energy Authority (EAEA), P.O. Box 29, Nasr City, Cairo, Egypt

► Original article

*Corresponding author:

Ahmed Amer Elkady, Ph.D.,

E-mail:

elkadyah13@gmail.com

Received: September 2021

Final revised: May 2022

Accepted: June 2022

Int. J. Radiat. Res., October 2022;
20(4): 829-837

DOI: 10.52547/ijrr.20.4.15

Keywords: γ -radiation, choline glycerophosphate, silymarin, brain and intestinal injury.

ABSTRACT

Background: the aim of this study was to investigate the role of choline glycerophosphate (GPC) either alone or combined with silymarin in modulating whole body gamma irradiation-induced brain and intestinal injuries in rats. **Materials and Methods:** Rats were irradiated with 7Gy then subjected to GPC and/ or silymarin for two weeks. At the end of the experiment, the animals were sacrificed then, brain and intestine samples were removed for biochemical, molecular and histopathological examinations. **Results:** it has been detected that GPC alone or combined with silymarin ameliorated the adverse effects of radiation as revealed by the inhibition of oxidative stress, apoptotic and inflammatory markers [Malondialdehyde (MDA), Caspase-3 Tumors necrosis factor- α (TNF- α), interleukin-1 β (IL-1 β) and nuclear factor kappa-B (NF- κ B)]. However, Total antioxidant capacity (TAC), anti-inflammatory marker, Interleukin-10 (IL-10) and inhibitor of Nuclear factor kappa-Ba (IkBa) mRNA were increased. This was also accompanied by a significant increase in the Acetylcholine (ACh) level, Choline Acetyltransferase (ChAT) activity and Alpha-7 nicotinic receptor (α 7nAChR), mRNA-expression and a significant decrease in the activity of Acetylcholine esterase (AChE) as compared with the corresponding values of the irradiated group. Moreover, a reduction in the tissue lesions was observed in brain and intestinal tissues. **Conclusion:** Choline glycerophosphate and silymarin exhibited modulating effect against detrimental effects of gamma-radiation via cholinergic anti-inflammatory pathway.

INTRODUCTION

Radiotherapy is one of the commonly used modalities in the treatment of malignant tumours, is associated with negative side effects on different organs of the body. Acute radiation can produce cellular damage in organs that having rapidly proliferating cells, such as the alimentary tract ⁽¹⁾. Additionally, the brain, with its high oxygen consumption and lipid-rich content, is highly susceptible to oxidative stress ⁽²⁾. The cellular damage can be induced by direct or indirect effects of radiation. The direct effect is resulted from the interaction of radiation itself directly with the cellular molecules; however, the indirect effect can be caused by the interaction of radiation with cellular water to create the free radicals and the hydrogen peroxide. Due to their high reactivity, free radicals interact with the biological molecules, most importantly the DNA and may form additional free radicals ⁽³⁾.

Acute gastrointestinal injury after radiotherapy includes nausea, vomiting, diarrhea, and increased stool frequency. These symptoms may be related to oxidative stress and inflammation induced by ionizing-radiation ⁽⁴⁾. The enteric nervous system, a part of the peripheral nervous system that

embedded within the gut wall and interconnected with the enteroendocrine and the gastrointestinal immune system, and involved in the physiological functions of the gastrointestinal tract, has also been demonstrated to play a critical role in the intestinal radiation injury ⁽⁵⁾. In fact, the central nervous system cooperates with the immune system to regulate inflammation. Acetylcholine (ACh), an important neurotransmitter in the cholinergic system, is synthesized and released by cholinergic neurons, and exerts its effects on the central and the peripheral nervous system through ACh receptors. Also, the ACh is released by non-neuronal tissues where it is involved in controlling various functions such as cell proliferation, survival and apoptosis ⁽⁶⁾. Also, brain injury including the morphological and the functional changes as neuronal degeneration and neuroendocrine disturbance may occur after head or whole body irradiation ^(7, 8).

Unfortunately, there are no safe and effective drugs to prevent the development of the radiation damage after whole or partial body irradiation. Hence, there is an urgent need for safe agents to mitigate radiation injury in the animal models. The ameliorating effect of the antioxidants and the anti-inflammatory agents have been hypothesized ⁽⁹⁾.

The Silymarin is a natural herbal product extracted from the seeds and fruits of *Silybum marianum*, commonly known as milk thistle, contains different flavonolignans (silibinin, isosilibinin, silichristin and silidianin) and has been long used to treat the liver diseases ⁽¹⁰⁾. Several studies have shown a beneficial effect of Silymarin supplementation in various diseases such as diabetes, metabolic syndrome, ⁽¹¹⁾ cardiovascular diseases, ^[12,13] memory impairments and depression, ⁽¹⁴⁾ in addition to its protective effect against sepsis-induced hepatic and renal injury. ⁽¹⁵⁾ It was reported that silymarin may act as a chemopreventive agent and has a chemosensitizing activity against various cancers ⁽¹⁶⁾.

The Choline Glycerophosphate (GPC) is a choline donor compound, widely used as a food supplement ⁽¹⁷⁾. Under the physiological conditions, the GPC can be involved in maintaining the structural integrity of the biological membranes. It has been shown that exogenous GPC administration reduced the reactive oxygen and the nitrogen species production caused by an ischemia-reperfusion insult ⁽¹⁸⁾. Previous studies on rat models have demonstrated that GPC administration protected against the ethanol-induced hepatic mitochondrial electron transport chain dysfunction ⁽¹⁹⁾ and the double stress stimuli of noise and restraint-induced cognitive dysfunction ⁽²⁰⁾. Moreover, the clinical studies have shown the efficacy of Alpha-GPC in decreasing the cognitive decline in patients with Alzheimer's disease or dementia ⁽²¹⁾ and epilepsy ⁽²²⁾. The effect of GPC against ionizing radiation induced negative side effects on different organs of the body is rare. Planga'r *et al.*, 2014 and Tóké's *et al.*, 2014 were investigated its protective effects against partial brain irradiation-induced cognitive decline and peripheral cytokine production ^(23, 24). However, the modulating effect of GPC on the whole body irradiation induced brain and intestinal injury has, to the best of our knowledge, never been studied before. Therefore, the current study aimed to investigate the modulatory role of the choline glycerophosphate as a single agent and as a co-treatment with the silymarin on the brain and intestinal injuries in rats exposed to whole body irradiation as well as the mechanisms by which the choline glycerophosphate and the silymarin could provide their potential amelioration actions.

MATERIALS AND METHODS

Chemicals

Choline glycerophosphate and silymarin were purchased from Sigma-Aldrich Co. (St. Louis, MO, USA). All other reagents used in this study were of analytical grade.

Animals

Adult male Wister rats weighing 180-220g were

used in this experiment, obtained from the animal house that belongs to the National Centre for Radiation Research and Technology (NCRRT), Cairo, Egypt. Rats were fed on a normal standard rodent diet and provided water *ad-libitum*. The animals were maintained at 12h light/ dark cycle, at constant temperature ($22\pm 2^\circ\text{C}$) and humidity ($50\pm 5\%$). All experimental procedures were performed according to the international guidelines of animal handling and care of the National Institute of Health (NIH publication No. 85- 23, 1996).

Radiation process

Whole-body gamma-irradiation of the animals was performed at the NCCRT, Cairo, Egypt, using a Canadian Gamma Cell-40, (^{137}Cs) irradiation unit. The rats were exposed to a single dose (7 Gy) with a dose rate of 0.38Gy/ min, according to the Dosimeter Department in the NCRRT at the time of the experiment.

Experimental design

The rats were divided into eight groups, 6 rats each. Group 1 (control) animals of this group were kept as control. Group 2 (GPC) animals were injected intraperitoneally with GPC (dissolved in saline, 0.9% NaCl) at a dose level of 150mg/ kg based on Tayebati *et al.*, daily for two weeks ⁽²⁵⁾. Group 3 (Sil) animals were orally supplemented with silymarin (dissolved in water) at a dose level of 50mg/kg based on Cruz *et al.*, 2001 & Shokouhi *et al.*, 2020, daily for two weeks ^(26,27). Group 4 (GPC+Sil) animals were injected intraperitoneally with GPC and orally supplemented with silymarin. Group 5 (Rad) rats were whole-body exposed to gamma-radiation at a dose level of 7Gy. Group 6 (Rad+GPC) animals were exposed to 7Gy gamma radiation and then received GPC 5min after irradiation and continued for two weeks as group 2. Group 7 (Rad+ Sil) animals were whole-body exposed to gamma-radiation at a dose level of 7Gy and orally supplemented with silymarin daily for two weeks after irradiation. Group 8 (Rad+Sil+Cit) rats were exposed to 7 Gy gamma radiation and received Sil and GPC for two weeks after irradiation.

Animals were sacrificed 24h after the last dose of GPC or silymarin or two weeks after irradiation. The brain and the intestine were immediately excised. Parts of the brain and intestine were preserved frozen at -80°C until used for Real-time PCR analysis and another parts were homogenized in phosphate-buffered saline (PBS) (1g tissue: 10ml PBS), centrifuged at 5000xg for 15min at 4°C , then the supernatant was collected and preserved frozen at -20°C until used for the biochemical analyses. For the histopathological examination, parts of the brain (one brain hemisphere) and intestine were fixed in 10% formalin.

Biochemical analyses

The MDA content was estimated in the brain and the intestine homogenates using Rat

Malondialdehyde Quantikine Enzyme-Linked Immunosorbent Assay (ELISA-kit, Cat. No. LS-F28018) from LifeSpan BioSciences, Inc. USA, following the manufacturer's guideline. The TAC was measured by ELISA kit (Cat. No. MBS733414_48T) from MyBioSource, Inc. USA.

The level of IL-1 β and IL-10 were quantified in brain and intestine homogenates using specific enzyme-linked immunosorbent assay kits, Cat. No. MBS825017 and Cat. No. MBS034393, respectively (MyBioSource, Inc. USA) according to the manufacturer's instructions. Nuclear factor kappa-B (NF- κ B) and Tumor necrosis factor- α (TNF- α) levels were measured using Rat NF- κ B and TNF- α ELISA kits (Cat. No. MBS722386 and MBS355371, respectively), according to the manufacturer's directions.

Acetylcholine (ACh) was measured in the brain and the intestine homogenates using the EnzyChrom™ Acetylcholine Assay Kit, Cat. No: EACL-100 (BioAssay Systems) in accordance to the manufacturer's instruction. The Choline Acetyltransferase (ChAT) and the Acetylcholinesterase (AChE) activities were measured using Rat ELISA Kit (Cat. No: E-BC-K125-S and E-BC-K174-M, respectively), Elabscience Biotechnology Inc.

Gene expression of Caspase 3, IKBa and α 7 nAChR in brain and intestine tissues

Total RNA was isolated using Qiagen tissue extraction kit (Qiagen, USA) according to the manufacturer's guideline. The isolated RNA was used for complementary DNA (cDNA) conversion using high capacity cDNA reverse transcription kit (Fermentas, USA). The amplification and the analysis of real-time qPCR were performed using an Applied Biosystem with software version 3.1 (StepOne™, USA). The reaction contained SYBR Green Master Mix (Applied Biosystems), gene-specific primer pairs were designed with Gene Runner Software (Hasting Software, Inc., Hasting, NY) from RNA sequences from the gene bank. The relative expression of Caspase-3, IKBa and α 7 nAChR was calculated according to Applied Bio system software using the comparative threshold cycle method. All values were normalized to the beta actin gene as an endogenous control (reference gene).

Primer sequences for the genes amplified:

Caspase-3 F: 5'-GTGGAAGTACGATGATATGGC-3'

R: 5'-CGCAAAGTGACTGGATGAACC-3'

IKBa F ACCTGGTCTCGCTCCTGTTG

R GCTCTCCTCATCCTCACTCTCG

α 7nAChR F: 5'-GCAAAGAGCCATACCCAG-3'

R: 5'-CAGCAAGAATACCAGCAGAG-3'

b-actin F TTGTCCCTGTATGCCTCT

R TAATGTCACGCACGATTTCC

Histopathological processing

Samples of the brain and the intestine tissues were collected from all groups, sliced, and fixed in 10% formalin solution. Paraffin blocks were prepared from those samples after a serial of dehydration, clearing and embedding. The paraffin-embedded material was prepared in 4-5 μ m thick slices by the microtome, mounted on microscope slides and stained with the hematoxylin and eosin stain ⁽²⁸⁾. Finally, it was examined under a light microscope to evaluate the histopathological changes.

Statistical analysis

Statistical analysis of the results was carried out using the SPSS computer program (version 20). All data were presented as mean values \pm standard errors of the means. Statistical comparison between groups was done by using one-way analysis of variance (ANOVA) followed by a post hoc, LSD. Differences were considered significant at $P < 0.05$.

RESULTS

Oxidative stress and apoptosis

In the brain tissues the results presented in table 1 showed that supplementation of GPC to the normal rats induced non-significant changes in the levels of TAC, MDA and caspase-3 mRNA compared to their normal control levels. However, the administration of GPC and the silymarin resulted in a significant ($P < 0.05$) elevation in the level of the TAC together with a significant decrease in the MDA level compared to their values of the control group. Whole body gamma irradiation (7Gy) of rats has provoked oxidative stress in the brain tissue, that has been demonstrated by a significant ($P < 0.05$) decrease in the TAC together with a significant elevation in the level of MDA and the expression level of caspase-3 mRNA compared to their values of the normal control group. However, the GPC or the silymarin administration for two weeks' post-irradiation induced a significant ($P < 0.05$) decrease in the levels of MDA & the caspase-3 and a significant elevation in the TAC compared to the corresponding values of the irradiated group. Also, the results revealed that the combined treatment of the GPC and the silymarin produced a better effect in reducing the oxidative stress and apoptosis (table 1).

Table 1. Changes in brain total antioxidant capacity (TAC) and Malondialdehyde (MDA) levels and expression level of Caspase-3 mRNA of adult male albino rats in different groups.

Brain	TAC (ng/g tissue)	MDA (ng/g tissue)	Caspase-3 mRNA
Control	7.33 \pm 0.44 b	9.67 \pm 0.44 b	1.03 \pm 0.044 b
GPC	6.92 \pm 0.47 b	9.83 \pm 0.53 b	0.99 \pm 0.026 b
Sil	7.67 \pm 0.57 b	7.92 \pm 0.58 ab	0.91 \pm 0.037 b
GPC+ Sil	8.83 \pm 0.53 a b	6.58 \pm 0.47 ab	0.85 \pm 0.039 b
Rad	4.50 \pm 0.41 a	20.42 \pm 0.71 a	3.72 \pm 0.174 a
Rad + GPC	6.10 \pm 0.53 b	14.75 \pm 0.63 abc	2.23 \pm 0.131 abc
Rad + Sil	6.42 \pm 0.50 b	13.08 \pm 0.85 abc	2.17 \pm 0.223 abc
Rad+ GPC + Sil	6.70 \pm 0.49 b	10.83 \pm 0.60 b	1.75 \pm 0.111 ab

In the intestine tissues the results presented in table 2 showed that the administration of GPC to the normal rats induced significant ($P<0.05$) increase in the level of TAC compared to their normal control levels. Moreover, the combined treatment of the GPC and the silymarin resulted in a significant ($P<0.05$) elevation in the level of TAC together with a significant decrease in the MDA level compared to their values of the control group. Whole body gamma-irradiation (7Gy) of rats has instigated oxidative stress in the intestine tissue, that has been demonstrated by a significant ($P<0.05$) elevation in the level of MDA associated with a significant decrease in the TAC compared to their values of the control group. Also, a significant increase in the expression level of caspase-3 mRNA was detected. However, the GPC or the silymarin administration for two weeks post-irradiation induced a significant ($P<0.05$) decrease in the levels of the MDA & the caspase-3 mRNA and a significant elevation in the TAC compared to the corresponding values of the irradiated group. Also, the results indicated that the combined treatment of GPC and silymarin produced a better effect in reducing the oxidative stress and apoptosis (table 2).

Table 2. Changes in intestine total antioxidant capacity (TAC) and Malondialdehyde (MDA) levels and expression level of Caspase-3 mRNA of adult male albino rats in different groups.

Intestine	TAC (ng/g tissue)	MDA (ng/g tissue)	Caspase-3 mRNA
Control	10.48± 0.47 b	07.32± 0.44 b	1.05± 0.12 b
GPC	12.20± 0.35 ab	07.17± 0.43 b	0.88± 0.06 b
Sil	12.95± 0.29 ab	06.57± 0.39 b	1.02± 0.05 b
GPC + Sil	14.12± 0.39 ab	05.72± 0.34 ab	0.88± 0.03 b
Radiation	07.12± 0.31 a	18.00± 0.61 a	3.65± 0.18 a
Rad + GPC	09.45± 0.47 bc	13.48± 0.58 abc	2.40± 0.15 abc
Rad + Sil	10.37± 0.41 b	12.58± 0.58 abc	2.25± 0.14 abc
Rad+ GPC + Sil	10.68± 0.30 b	10.50± 0.65 ab	1.70± 0.17 ab

Cholinergic and inflammatory markers

In the brain tissues the results in tables 3 & 5 showed non-significant changes in the studied cholinergic and the inflammatory markers upon administration of the GPC and/ or silymarin to normal rats compared to their normal control levels. Also, the results (table 3) exposure to ionizing radiation resulted in a significant ($P<0.05$) elevation in the levels of NF- κ B, pro-inflammatory cytokines, TNF- α and IL-1 β compared to their values of the control group. As well, a significant ($P<0.05$) decrease in the level of IL-10 and the expression level of IkBa mRNA was observed two weeks after irradiation compared to their values of the control group. Administration of the GPC and/or the silymarin ameliorated the changes induced by exposure to radiation.

In the intestine tissues the results in tables 4 & 6 showed non-significant changes in the studied cholinergic and the inflammatory markers upon administration of the GPC and/or the silymarin to the normal rats compared to their normal control levels.

Exposure to ionizing radiation (table 4) resulted in a significant ($P<0.05$) elevation in the levels of NF- κ B and pro-inflammatory cytokines, TNF- α and IL-1 β compared to their values of the control group. As well, a significant ($P<0.05$) decrease in the level of IL-10 and the expression level of IkBa mRNA was observed two weeks after irradiation compared to their values of the control group. Administration of the GPC and/ or the silymarin ameliorated the changes induced by exposure to radiation. The data presented in table 5 indicated that the whole body irradiation induced a significant ($P<0.05$) decrease in the level of ACh & the activity of ChAT and the expression level of α 7nAChR along with a significant increase in the AChE activity compared to their values of the control group. However, the GPC and/ or the silymarin administration ameliorated these changes.

Table 3. Changes in brain tumor necrosis factor- α (TNF α), Interleukin 1 beta (IL-1 β), Interleukin 10(IL-10), and nuclear factor kappa (NF- κ B) levels and expression level of IkBa mRNA of adult male albino rats in different groups.

Brain	TNF α (pg/mg tissue)	IL-1 β (pg/mg tissue)	IL-10 (pg/mg tissue)	NF- κ B (pg/mg tissue)	IKB mRNA
Control	12.50± 0.76 b	15.83± 0.56 b	108±5.20 b	18.25± 0.62 b	1.03± 0.044 b
GPC	11.75± 0.63 b	14.92± 0.58 b	107±6.89 b	17.02± 0.76 b	1.05± 0.048 b
Sil	11.40± 0.96 b	15.25± 0.70 b	105±6.74 b	16.17± 0.90 b	0.98± 0.042 b
GPC + Sil	11.52± 0.88 b	14.92± 0.50 b	110±7.60 b	17.00± 0.93 b	0.97± 0.051 b
Rad	25.75± 0.63 a	30.50± 0.99 a	62.2± 3.79 a	37.57± 0.10 a	0.65± 0.029 a
Rad + GPC	18.50± 0.76 ab	22.18± 0.89 abc	79.3±3.70 ab	24.78± 0.76 abc	0.85± 0.0549 ab
Rad + Sil	19.08± 0.58 ab	20.37± 0.75 ab	81.7±4.45 ab	25.28± 0.82 abc	0.83± 0.0418 ab
Rad+ GPC + Sil	17.25± 0.63 ab	19.28± 0.83 ab	91.1±5.27 ab	22.03± 0.94 ab	0.93± 0.0295 b

Data are represented as means \pm SE. a: Significantly different from the control group, b: Significantly different from the Rad group, c: Significant difference of Rad + GPC group or Rad + Sil group from Rad+ GPC+ Sil group. The mean difference is significant at the 0.05 level.

Table 4. Changes in intestine tumor necrosis factor- α (TNF α), Interleukin 1 beta (IL-1 β), Interleukin 10(IL-10), and nuclear factor kappa (NF- κ B) levels and expression level of IkBa mRNA of adult male albino rats in different groups.

Intestine	TNF α (pg/mg tissue)	IL-1 β (pg/mg tissue)	IL-10 (pg/mg tissue)	NF- κ B (pg/mg tissue)	IKB mRNA
Control	14.27± 0.60 b	20.55± 0.67 b	96.68± 4.39 b	24.87± 0.77 b	1.06± 0.08 b
GPC	13.00± 0.52 b	19.07± 0.58 b	103.33± 4.41 b	22.83± 0.86 b	1.07± 0.07 b
Sil	13.17± 0.55 b	19.00± 0.78 b	98.63± 5.05 b	22.00± 1.08 b	1.03± 0.08 b
GPC + Sil	13.38± 0.76 b	19.78± 0.94 b	102.50± 5.28 b	21.50± 1.18 b	1.05± 0.06 b
Rad	24.50± 0.58 a	36.75± 1.17 a	55.83± 3.96 a	47.70± 0.78 a	0.64± 0.04 a
Rad + GPC	18.30± 0.48 ab	25.52± 0.71 ab	71.45± 3.50 ab	29.45± 0.73 abc	0.83± 0.03 ab
Rad + Sil	18.45± 0.71 ab	24.67± 0.82 ab	69.77± 4.46 ab	28.07± 1.48 b	0.84± 0.04 ab
Rad+ GPC+ Sil	17.45± 0.63 ab	23.22± 0.67ab	79.67± 3.83 ab	25.35± 2.45 b	0.92± 0.08 b

Data are represented as means \pm SE. a: Significantly different from the control group, b: Significantly different from the Rad group, c: Significant difference of Rad + GPC group or Rad + Sil group from Rad+ GPC+ Sil group. The mean difference is significant at the 0.05 level.

Table 5. Changes in brain Acetylcholine (ACh) level, Choline Acetyltransferase (ChAT) activity, Acetylcholinesterase (AChE) activity and $\alpha 7$ nAChR mRNA levels of adult male albino rats in different groups.

Brain	ACh (nmol/g tissue)	ChAT (U/g tissue)	AChE (U/mg tissue)	$\alpha 7$ nAChR mRNA
Control	29.33±1.87 b	32.33±1.84 b	0.21±0.017 b	1.04±0.047 b
GPC	32.33±1.52 b	33.17±1.08 b	0.20±0.017 b	0.98±0.029 b
Sil	30.17±1.72 b	32.17±1.14 b	0.17±0.018 b	1.00±0.040 b
GPC + Sil	31.17±1.08 b	32.50±0.76 b	0.18±0.022 b	1.02±0.045 b
Rad	17.17±0.95 a	19.33±1.23 a	0.39±0.013 a	0.41±0.010 a
Rad + GPC	24.67±1.67 ab	24.97±1.53 ab	0.25±0.015 b	0.61±0.011 abc
Rad + Sil	22.83±1.54 ab	25.97±1.51 ab	0.24±0.017 b	0.56±0.008 abc
Rad+ GPC + Sil	26.50±1.18 b	28.30±1.14 ab	0.23±0.012 b	0.77±0.017 ab

Data are represented as means \pm SE. a: Significantly different from the control group, b: Significantly different from the Rad group, c: Significant difference of Rad + GPC group or Rad + Sil group from Rad+ GPC+ Sil group. The mean difference is significant at the 0.05 level.

Table 6. Changes in intestine Acetylcholine (ACh) level, Choline Acetyltransferase (ChAT) activity, Acetylcholinesterase (AChE) activity and $\alpha 7$ nAChR mRNA levels of adult male albino rats in different groups.

Intestine	ACh (nmol/g tissue)	ChAT (U/g tissue)	AChE (U/mg tissue)	$\alpha 7$ nAChR mRNA
Control	29.67±0.88 b	26.67±1.28 b	0.17±0.017 b	0.99±0.037 b
GPC	30.17±1.35 b	27.17±1.25 b	0.18±0.016 b	0.92±0.026 b
Sil	27.50±1.57 b	27.33±1.02 b	0.16±0.019 b	0.98±0.048 b
GPC + Sil	31.00±1.18 b	28.38±1.37 b	0.17±0.013 b	0.97±0.033 b
Rad	15.17±0.95a	17.78±0.77 a	0.37±0.021 a	0.49±0.017 a
Rad + GPC	21.00±1.81 abc	21.32±0.90 ab	0.23±0.016 ab	0.71±0.015 abc
Rad + Sil	19.83±0.95 abc	20.28±0.67 a	0.24±0.014 ab	0.67±0.014 abc
Rad+ GPC + Sil	25.00±1.37 ab	22.12±0.99 ab	0.22±0.016 b	0.84±0.027 ab

Data are represented as means \pm SE. a: Significantly different from the control group, b: Significantly different from the Rad group, c: Significant difference of Rad + GPC group or Rad + Sil group from Rad+ GPC+ Sil group. The mean difference is significant at the 0.05 level.

The data presented in table 6 indicated that whole body irradiation induced a significant ($P < 0.05$) decrease in the ACh level & ChAT activity and the expression level of $\alpha 7$ nAChR along with a significant increase in the AChE activity compared to their values of the control group. However, the GPC and/or the silymarin ameliorated these changes. Moreover, the combined treatment of GPC and silymarin showed a better modulating effect on the ACh level and its receptor as compared with each of them separately.

Histopathological examination

The Brain cerebral gray matter of control rat's showed normal histological structure (figure 1A). Also, the Cerebrum gray matter in both GPC (figure 1B) and silymarin groups showed a normal structure as control. In whole body irradiated rats, the neuronophagia and the degenerative changes of brain tissue are not severing and appeared in different parts of the brain especially the cerebrum, in all investigated rats of this group and epitomized by numerous pyknotic neurons with proliferation of

the glial cells in gray matter (figure 1C). In the Rad+ GPC group, the gray matter of some rats showed little degenerated pyramids neurons (figure 1D) but the gray matter of the rat treated with the GPC, silymarin and radiation, the majority of neurons and matrix shows normal morphological picture (figure 1E).

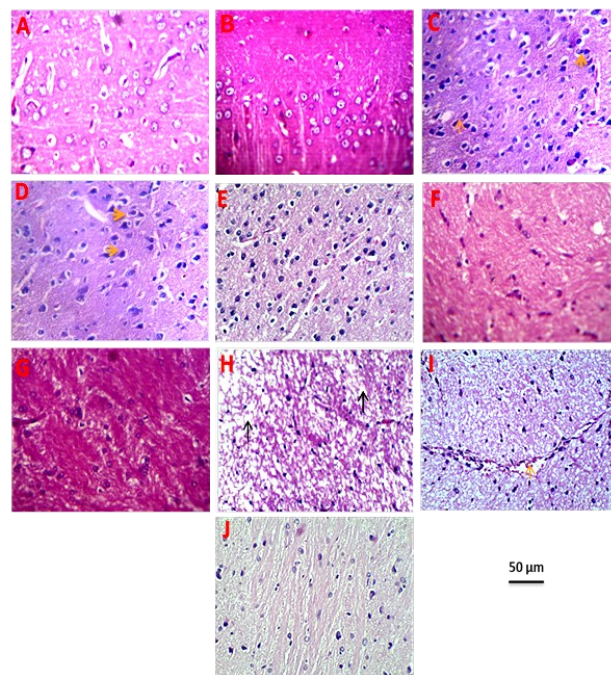


Figure 1. Effect of choline and silymarin on normal and γ -rays induced histopathological alterations of rat's cerebrum (H&E 400 x). **A)** Gray matter of control showing normal structure. **B)** Gray matter of GPC treated rat showing normal structure. **C)** Gray matter of irradiated rat showing numerous pyknotic neurons (\uparrow) with proliferation of glia cells. **D)** Gray matter of rat treated with GPC and radiation showing little degenerated pyramids neurons (\rightarrow). **E)** Gray matter of rat treated with GPC, silymarin and radiation, the majority of neurons and matrix shows normal morphological picture. **F)** White matter of control rat showing normal structure. **G)** White matter of silymarin treated rat showing normal structure. **H)** White matter of irradiated rat showing spongiform degeneration (\uparrow). **I)** White matter of rat treated with silymarin and radiation showing dilated blood vessel (\uparrow). **J)** White matter of rat treated with GPC, silymarin and radiation, the majority of nerve axons shows normal morphological picture.

Cerebrum white matter of control, GPC and silymarin groups showed normal histological structures (figure 1F, G). The white matter of irradiated rats showed spongiform degeneration (figure 1H) and increasing of glia cells with or without dilated blood vessels. While white matter of Rad+ Sil group showed dilated blood vessel with microcavitation (figure 1I). Moreover, white matter of rats treated with GPC and silymarin after irradiation, in some cases there are residual degenerated pyramids appeared while the majority of neurons, matrix, and nerve axons showed normal morphological structure (figure 1J).

Intestine of control rat's showed normal histological structure (figure 2A&B). Also, both GPC and silymarin groups are showed normal structure as

the control. Intestine of irradiated rats showed marked villous tips loss (erosions), mucosal layer are necrosis and inflammatory cell invasion of the submucosal layer (figure 2C&D&E). The intestine of rats treated with the GPC and radiation showed histologically significant improvement than that's of irradiated one, in some cases showed expanded intestinal gland or leucocytic infiltration around degenerated Bruner's glands (figure 2F, G). While the intestinal rat treated with the silymarin and radiation appear mild erosion of mucosal layer and the mucosa and submucosa showed still inflammation, oedematous and dystrophic external muscular layer (figure 2H&I). Intestine of rats treated by the GPC and the silymarin after irradiation showed more improvement than those treated by the GPC or silymarin separately, it appeared without any erosions or necrosis, in some cases there were dilated intestinal blood vessels or expanded intestinal gland (figure 2J&K&L).

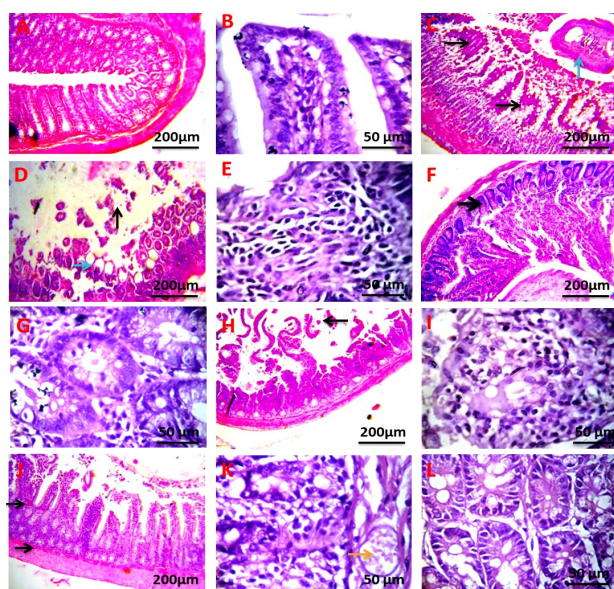


Figure 2. Effect of choline and silymarin on normal and γ -rays induced histopathological alterations of rat intestine. **A)** Control showing normal structure (H&E 100 x). **B)** Control showing normal intestinal villi (H&E 400 x). **C)** Irradiated showing severe erosion (\uparrow), necrosis of the mucosal layer (\rightarrow) (H&E 100 x). **D)** Irradiated rat showing loss mucosal layer (\uparrow) with degenerated and necrotic intestinal glands (\rightarrow) (H&E 100 x). **E)** Irradiated rat showing severe erosion, necrosis of the mucosal layer, swelling and invasion of inflammatory cells of the submucosal layer (H&E 400 x). **F)** Treated with GPC and radiation showing slightly expanded intestinal gland (\rightarrow) (H&E 100 x). **G)** Treated with GPC and radiation showing leucocytic infiltration around degenerated Bruner's glands (H&E 400 x). **H)** Treated with silymarin and radiation showing mild erosion of the mucosal layer (\leftarrow) (H&E 100 x). **I)** Treated with silymarin and radiation, the mucosa and submucosa showed still inflammation, edematous and dystrophic external muscular layers (H&E 400 x). **J)** Treated with GPC, silymarin and radiation showing normal structure with dilated blood vessels (\rightarrow) (H&E 100 x). **K)** Treated with GPC, silymarin and radiation showing dilated blood vessels (\rightarrow) (H&E 400 x). **L)** Treated with GPC, silymarin and radiation showing normal or slightly expanded intestinal glands (H&E 400 x).

DISCUSSION

Exposure to ionizing radiation initiates a series of molecular and biochemical signaling events that may repair the damage or induce cell phenotypic modifications, depending on the dose of exposure and the sensitivity of exposed cells. The intestinal cells are among the most sensitive cells⁽²⁹⁾. The brain tissues are susceptible to oxidative damage due to its high oxygen utilization, lipid rich content and its low endogenous antioxidant content.² Previous studies showed that ionizing-radiation enhanced reactive oxygen species (ROS) production, apoptosis and inflammation, and reduced the Ach levels in the brain and colon^(8, 30). Therefore, it was hypothesized that the GPC-as a precursor of the ACh- and the silymarin a strong natural antioxidant might influence the radiation-induced oxidative stress, apoptosis, inflammation and cholinergic system disturbance in the brain and the intestinal tissues. The authors set out to investigate the consequences of the GPC and the silymarin administration on the markers of the oxidative stress and the cholinergic anti-inflammatory pathway in rats exposed to whole body gamma radiation.

The results of the present study showed that whole body gamma irradiation (7 Gy) of male albino rats triggered the oxidative stress indicated by a significant increase in the MDA level as an index of lipid peroxidation and a significant decrease in the TAC. This injurious effect of radiation is caused mainly by the over production of ROS which interact with the cellular macromolecules producing harmful free radicals leading to lipid peroxidation in brain,⁽⁷⁾ intestine⁽²⁹⁾ and liver⁽³¹⁾.

The excessive production of the free radicals immediately after irradiation is considered as the first pro-inflammatory signal in irradiated tissues⁽⁵⁾. Free radicals interact with biological targets causing DNA damage which initiate apoptotic and inflammatory responses, characterized by the production of apoptotic markers (caspases-9 and -3) and pro-inflammatory cytokines, such as the TNF- α , IL-1 β and IL6^(4, 32). Besides, the NF- κ B is activated by the oxidative stress induced after irradiation, which in turn targets the production of many genes related to inflammation⁽³³⁾. It is well known that inactive NF- κ B is located in the cytosol and is bound to an inhibitory protein, I κ Ba. However, the induced oxidative stress results in I κ Ba phosphorylation, dissociation from NF- κ B, ubiquitination, and subsequent degradation. Consequently, the NF- κ B translocates to the nucleus, where the transcription process of certain cytokines (like IL-1, IL-6, and TNF- α) is up-regulated⁽³⁴⁾.

In the present study, gamma radiation decreased the level of IL-10 and the expression level of I κ Ba, however, it elevated the levels of TNF- α , IL-1 β & NF- κ B and the expression levels of caspase-3 indicating

the role of inflammatory cytokines and apoptotic markers in the radiation-induced brain and intestinal injury. These results were confirmed by the degenerated intestinal mucosa with inflammatory cells infiltration and degenerative changes in the brain tissue that was demonstrated in the current histopathological study.

Whole body irradiation induced a significant decrease in the level of ACh, the important neurotransmitter in the cholinergic system, ChAT, and the expression level of $\alpha 7$ nAChR associated with a significant increase in the AChE level in brain and intestine (tables 5 & 6). These results agree with that of Mansour et al. 2017 and El kiki & Galal 2018 who observed that whole body irradiation (6Gy) induced a significant decrease in neurotransmitters and a significant increase in AChE activity in the rat brain (35,36). Erukainure *et al.*, 2021 demonstrated that oxidative stress has been implicated in the elevation of AChE activity in the testicular tissue (37). The significant decrease in ACh level observed in the current study may be attributed to the decrease in ChAT, the enzyme responsible for the ACh synthesis, and the increase in AChE, the enzyme that hydrolyzes ACh. This disturbance may terminate the interaction between neurotransmitter, ACh and the corresponding receptor protein, $\alpha 7$ nAChR (38).

Since $\alpha 7$ nAChR is located on neuronal and non-neuronal cells such as immune cells, it was demonstrated that immune cells in the gut could be the target of ACh that act as an immune modulator (39). Indeed, the enteric nervous system is a large division of the peripheral nervous system embedded within the gut wall and regulates various physiological functions of the gastrointestinal tract such as mucus secretion, immunity, and inflammatory processes (40). Evidence suggested that the enteric nervous system and its interactions with the immune system have a critical role in the early intestinal radiation response (5).

From the above results, it is thought that the oxidative stress, and the consequent inflammation and cholinergic system disturbance are the probable pathogenic mechanisms in the radiation-induced brain and intestinal injury. Hence, stimulation of the cholinergic anti-inflammatory pathway plays an important role in controlling the inflammatory response which is mediated by increasing the release of ACh and activation of $\alpha 7$ nAChR on the surface of macrophages. Particularly, ACh, the essential neurotransmitter in the vagus nerve, inhibits the production of the pro-inflammatory cytokines through a mechanism dependent on the $\alpha 7$ nAChR (41). Moreover, the anti-inflammatory role of ACh in the modulation of the inflammatory response through inhibition of AChE has been described (42).

GPC and / or silymarin administration after whole body irradiation helped to minimize the oxidative stress, the results indicated by the significant increase of TAC and the significant decrease of MDA

levels (tables 1& 2) in the brain and intestinal tissues as compared to the corresponding values of the irradiated group. These results are in agreement with the previous studies which indicated that silymarin attenuated the oxidative stress in the brain of rats intoxicated with $AlCl_3$ (43) and inhibited the toxic effect of microcystin-LR on mice by increasing the reduced glutathione which may reduce the lipid peroxidation and protein carbonyl content in the spleen and intestine (44). Due to the presence of phenolic hydroxyl groups in its structure, the silymarin could attenuate the oxidative stress through scavenging free radicals, inhibiting the free radical formation and preserving the cellular antioxidant status, thus preventing peroxidation of membrane lipids (43). Likewise, the GPC administration reduced the reactive oxygen and nitrogen species production in rodent models of the intestine and liver ischemia-reperfusion injuries (18, 45). The current observation of the reduction of caspase-3 mRNA expression by the GPC and/ or silymarin treatment after irradiation indicates their role as anti-apoptotic agents. This effect may be related to their ability to reduce the ROS and MDA production and maintain the structural integrity of the biological membranes. The results indicated that the combined treatment of GPC and silymarin produced a better effect in reducing MDA level indicating their synergistic effects.

Moreover, the GPC and/ or silymarin administration after whole body irradiation modulated the inflammation and the enzymes responsible for the ACh synthesis and hydrolysis, and increased the level of ACh and the expression level of its receptor, $\alpha 7$ nAChR, as compared to the corresponding values of the irradiated group (tables 3- 6). The anti-inflammatory effect of these agents may takes place via the inhibition of NF- κ B signaling pathway and increase the anti-inflammatory cytokine, IL-10. Recently, it was described that the dietary choline supplement improved the immune function and restrained the NF- κ B signaling pathway by up-regulating the expression level of I κ B α and down-regulating NF- κ Bp65, and NF- κ Bp52 expression as well as decreasing the mRNA level of pro-inflammatory cytokines, TNF- α , IL-1 β , and IL-6, and increasing the mRNA abundance of anti-inflammatory cytokines, IL-10 (46). Consequently, the pro-inflammatory cytokine production and the occurrence of inflammation are inhibited. Regarding the cholinergic anti-inflammatory pathway, GPC administration increased the release of the ACh that inhibited macrophage likely by activation of $\alpha 7$ nAChR expressed on the cell surface of the macrophage (47). Additionally, the GPC protected against cognitive decline, cellular damage (23) and peripheral cytokine production (24) induced after partial brain irradiation. Moreover, it has been reported that silymarin can resist the inflammatory response of the nervous system and can also increase

the ACh content by inhibiting cholinesterase activity (43, 48). Thus, modulation of the cholinergic signaling pathway, including the inhibition of AChE, the activation of ChAT, and the promotion of ACh synthesis, may serve as a strategy for the treatment of whole body gamma irradiation-induced brain and intestinal injuries. The histopathological examination of the brain and intestinal tissues supported the biochemical results and confirmed the ameliorative effect GPC and silymarin against ionizing radiation.

CONCLUSION

According to the results obtained in this study, GPC - as a precursor of ACh- and silymarin - a strong natural antioxidant- exhibited modulating effect against detrimental effects of gamma radiation in rats via cholinergic anti-inflammatory pathway. This effect might be attributed to the activation of anti-oxidative, anti-apoptotic, and anti-inflammatory mechanisms. Therefore, the GPC and silymarin might be suggested to serve as a strategy for the treatment of the negative side effects induced by the exposure to ionizing radiation. However, further studies are required to support these results before a clinical application can be recommended.

Competing Interests: The authors declare that they have no conflict of interest.

Ethical approval: This experiment was carried out according to the international guidelines of animal handling and care (NIH no. 85:23, 1996). Human participants, human data or human tissue are not applicable.

Data availability: The data and materials used in the present study are available from the corresponding author on reasonable request.

Funding: This article received no specific gift from any funding agency in the public, commercial, or not-for-profit sectors.

Author contributions: Nahed Abdel-Aziz designed the study, conducted animal experiments, and participated in some laboratory measurement. She also wrote and reviewed the research for publication. Ahmed A. Elkady did histopathological studies and published the research. Eman M. Elgazzar participated in laboratory measurements, statistical analysis and publishing process.

REFERENCES

1. Yu J (2013) Intestinal stem cell injury and protection during cancer therapy. *Translational Cancer Research*, **2**(5): 384.
2. Salim S (2017) Oxidative stress and the central nervous system. *Journal of Pharmacology and Experimental Therapeutics*, **360**(1): 201-205.
3. Ahmed AQ, Salman AY, HassanAB, Abojassim AA, Mraity HAA (2020) The impact of Gamma Ray on DNA molecule. *International Journal of Radiology and Radiation Oncology*, **6**(1): 011-013.
4. Radwan RR and Karam HM (2020) Resveratrol attenuates intesti-

- nal injury in irradiated rats via PI3K/Akt/mTOR signaling pathway. *Environmental Toxicology*, **35**(2): 223-230.
5. Moussa L, Usunier B, Demarquay C, Benderitter M, Tamarat R, Sémont A, Mathieu N (2016) Bowel radiation injury: complexity of the pathophysiology and promises of cell and tissue engineering. *Cell Transplantation*, **25**(10): 1723-1746.
6. Zoli M, Pucci S, Vilella A, Gotti C (2018) Neuronal and extraneuronal nicotinic acetylcholine receptors. *Curr Neuropsychopharmacol*, **16**(4): 338-349.
7. El-Missiry MA, Shabana S, Ghazala SJ, Othman AI, Amer ME (2021) Melatonin exerts a neuroprotective effect against γ -radiation-induced brain injury in the rat through the modulation of neurotransmitters, inflammatory cytokines, oxidative stress, and apoptosis. *Environ Sci Pollut Res Int*, **28**(24): 31108-31121.
8. Abdel-Aziz N, Moustafa EM, Saada, HN (2021) The impact of citicoline on brain injury in rats subjected to head irradiation. *Environmental Science and Pollution Research*, **28**(8): 9742-9752.
9. Yahyapour R, Shabeeb D, Cheki M, Musa AE, Farhood B, Rezaeyan A, et al. (2018) Radiation protection and mitigation by natural antioxidants and flavonoids: implications to radiotherapy and radiation disasters. *Current Molecular Pharmacology*, **11**(4): 285-304.
10. Gillissen A and Schmidt HHJ (2020) Silymarin as supportive treatment in liver diseases: A narrative review. *Advances in therapy*, **37**(4): 1279-1301.
11. Vahabzadeh M, Amiri N, Karimi G (2018) Effects of silymarin on metabolic syndrome: a review. *Journal of the Science of Food and Agriculture*, **98**(13): 4816-4823.
12. Taleb A, Ahmad KA, Ihsan AU, Qu J, Lin N, Hezam K, Koju N, Hui L, Qilong D (2018) Antioxidant effects and mechanism of silymarin in oxidative stress induced cardiovascular diseases. *Biomedicine & Pharmacotherapy*, **102**: 689-698.
13. Zalat ZA, Kohaf NA, Alm El-Din MA, Elewa HA, Abdel-Latif MM (2021) Silymarin: A promising cardioprotective agent. *Azhar Int J Pharm Med Sci*, **1**(1): 13-21.
14. El-Elmat T, Alzoubi KH, AbuAlSamen, MM, Al Subeh ZY, Graf TN, Oberlies NH (2019) Silymarin prevents memory impairments, anxiety, and depressive-like symptoms in a rat model of post-traumatic stress disorder. *Planta Medica*, **85**(01): 32-40.
15. Al-Kadi A, Ahmed AS, El-Tahawy NFG, Khalifa MMA, El-Daly M (2020) Silymarin protects against sepsis-induced acute liver and kidney injury via anti-inflammatory and antioxidant mechanisms in the rat. *Journal of advanced Biomedical and Pharmaceutical Sciences*, **3**(4): 190-197.
16. Delmas D, Xiao J, Vejux A, Aires V (2020) Silymarin and cancer: A dual strategy in both in chemoprevention and chemosensitivity. *Molecules*, **25**(9): 2009.
17. Tuboly E, Gáspár R, Ibor MO, Gömöri K, Kiss B, Striffler G, Hartmann P, et al. (2019) L-Alpha-glycerolphosphorylcholine can be cytoprotective or cytotoxic in neonatal rat cardiac myocytes: A double-edged sword phenomenon. *Molecular and Cellular Biochemistry*, **460**(1): 195-203.
18. Tóké T, Tuboly E, Varga G, Major L, Ghyczy M, Kaszaki J, Boros M (2015) Protective effects of l-alpha-glycerolphosphorylcholine on ischaemia-reperfusion-induced inflammatory reactions. *European Journal of Nutrition*, **54**(1): 109-118.
19. Tuboly E, Molnár R, Tóké T, Turányi RN, Hartmann P, Mészáros, AT et al. (2017) Excessive alcohol consumption induces methane production in humans and rats. *Scientific Reports*, **7**(1): 1-10.
20. Xu ZQ, Zhang WJ, Su DF, Zhang GQ, Miao CY (2021) Cellular responses and functions of $\alpha 7$ nicotinic acetylcholine receptor activation in the brain: a narrative review. *Annals of Translational Medicine*, **9**(6).
21. Traini E, Bramanti V, Amenta F (2013) Choline alfoscerate (alpha-glycerolphosphoryl-choline) an old choline-containing phospholipid with a still interesting profile as cognition enhancing agent. *Current Alzheimer Research*, **10**(10): 1070-1079.
22. Lee SH, Choi BY, Kim JH, Kho AR, Sohn M, Song HK, Choi HC, Suh SW (2017) Late treatment with choline alfoscerate (l-alpha glycerolphosphorylcholine, α -GPC) increases hippocampal neurogenesis and provides protection against seizure-induced neuronal death and cognitive impairment. *Brain research*, **1654**: 66-76.
23. Plangár I, Szabó, ER, Tóké T, Mán I, Brinyiczki K, Fekete G, et al. (2014) Radio-neuroprotective effect of L-alpha-glycerolphosphorylcholine (GPC) in an experimental rat model. *Journal of neuro-oncology*, **119**(2): 253-261.
24. Tóké T, Varga G, Garab D, Nagy Z, Fekete G, Tuboly E, Plangár I, Mán I, Szabó RE, et al. (2014) Peripheral inflammatory activation after hippocampus irradiation in the rat. *Int J Radiat Biol*, **90**(1): 1-6.

25. Tayebati SK, Tomassoni D, Di Stefano A, Sozio P, Cerasa LS, Amenta F (2011) Effect of choline-containing phospholipids on brain cholinergic transporters in the rat. *Journal of the neurological sciences*, **302**(1-2): 49-57.
26. Cruz T, Gálvez J, Crespo E, Ocete MA, Zarzuelo A (2001) Effects of silymarin on the acute stage of the trinitrobenzenesulphonic acid model of rat colitis. *Planta Medica*, **67**(01): 94-96.
27. Shokouhi G, Kosari-Nasab M, Salari AA (2020) Silymarin sex-dependently improves cognitive functions and alters TNF- α , BDNF, and glutamate in the hippocampus of mice with mild traumatic brain injury. *Life Sciences*, **257**: 118049.
28. Suvarna KS, Layton C, Bancroft JD (2013) Bancroft's theory and practice of histological techniques, 7th Edition, Churchill Livingstone, USA, 766.
29. Musa AE, Shabeeb D, Alhilfi HSQ (2019) Protective effect of melatonin against radiotherapy-induced small intestinal oxidative stress: biochemical evaluation. *Medicina*, **55**(6): 308.
30. Song C, Gao X, Song W, Zeng D, Shan S, Yin Y, Li Y, Baranenko D, Lu W (2020) Simulated spatial radiation impacts learning and memory ability with alterations of neuromorphology and gut microbiota in mice. *RSC Advances*, **10**(27): 16196-16208.
31. Hassan AA, Moustafa EM, El-khashab IH, Mansour SZ (2021) Mangosteen Hinders Gamma Radiation-Mediated Oxidative Stress and Liver Injury by Down-Regulating TNF- α /NF- κ B and Pro-Fibrotic Factor TGF- β 1 Inducing Inflammatory Signaling. *Dose Response*, **19**(2): 15593258211025190.
32. El-Maraghi EF, Abdel-Fattah KI, Soliman SM, El-Sayed WM (2020) Taurine abates the liver damage induced by γ -irradiation in rats through anti-inflammatory and anti-apoptotic pathways. *Int J Radiat Biol*, **96**(12): 1550-1559.
33. Ismail AF and El-Sonbaty SM (2016) Fermentation enhances Ginkgo biloba protective role on gamma-irradiation induced neuroinflammatory gene expression and stress hormones in rat brain. *Journal of Photochemistry and Photobiology B: Biology*, **158**: 154-163.
34. Saha S, Buttari B, Panieri E, Profumo E, Saso L (2020) An overview of Nrf2 signaling pathway and its role in inflammation. *Molecules*, **25**(22): 5474.
35. Mansour SZ, El-Marakby, SM, Moawad FS (2017) Ameliorative effects of rutin on hepatic encephalopathy-induced by thioacetamide or gamma irradiation. *Journal of Photochemistry and Photobiology B: Biology*, **172**: 20-27.
36. Elkiki S and Galal S (2018) Panax ginseng extract modulates cerebral damage caused by gamma Irradiation in male albino rats. *Egyptian Journal of Radiation Sciences and Applications*, **31**(2): 111-124.
37. Erukainure OL, Atolani O, Banerjee P, Abel R, Poore OJ, Adeyemi, et al. (2021) Oxidative testicular injury: effect of l-leucine on redox, cholinergic and purinergic dysfunctions, and dysregulated metabolic pathways. *Amino Acids*, **53**(3): 359-380.
38. Pal A, Kumar KH, Bhushan B, Saharan V (2017) Ashwagandha root extract inhibits acetylcholine esterase, protein modification and ameliorates H₂O₂-induced oxidative stress in rat lymphocytes. *Pharmacognosy Journal*, **9**(3).
39. Brinkman DJ, Ten Hove AS, Vervoordeldonk MJ, Luyer MD, de Jonge WJ (2019) Neuroimmune interactions in the gut and their significance for intestinal immunity. *Cells*, **8**(7): 670.
40. Niesler B, Kuerten S, Demir IE, Schäfer KH (2021) Disorders of the enteric nervous system—a holistic view. *Nature Reviews Gastroenterology & Hepatology*, **18**(6): 393-410.
41. Chen, F., Wei, X., Chen, X., Xiang, L., Meng, X. and Feng, J. (2020) The role of the α 7nAChR-mediated cholinergic anti-inflammatory pathway in Hirschsprung associated enterocolitis. *Inflammation*, **44**(3): 821-834.
42. Rosas-Ballina M and Tracey KJ (2009) Cholinergic control of inflammation. *Journal of Internal Medicine*, **265**(6): 663-679.
43. Aboelwafa HR, El-Kott AF, Abd-Ella EM, Yousef HN (2020) The possible neuroprotective effect of silymarin against aluminum chloride-prompted Alzheimer's-like disease in Rats. *Brain Sciences*, **10**(9): 628.
44. Al-hazmi A, Alomery A, Abderrahim LA (2019) Silymarin as a therapeutic extract for intestinal and splenic injuries induced by microcystin-LR in mice. *Journal of King Saud University-Science*, **31**(4): 1414-1417.
45. Striffler G, Tuboly E, Görbe A, Boros M, Pécz D, Hartmann P (2016) Targeting Mitochondrial Dysfunction with L-Alpha Glycerolphosphorylcholine. *plos one*, **11**(11): e0166682.
46. Yuan ZH, Feng L, Jiang WD, Wu P, Liu Y, Jiang J, Kuang SY, Tang L, et al. (2021) Dietary choline-enhanced skin immune response of juvenile grass carp might be related to the STAT3 and NF- κ B signaling pathway (Ctenopharyngodon idella). *Front Nutr*, **8**: 652767.
47. Kimura H, Imura YK, Tomiyasu H, Mihara T, Kaji N, Ohno K, Unno T, et al. (2019) Neural anti-inflammatory action mediated by two types of acetylcholine receptors in the small intestine. *Scientific reports*, **9**(1): 1-11.
48. Guo H, Cao H, Cui X, Zheng W, Wang S, Yu J, Chen Z (2019) Silymarin's inhibition and treatment effects for Alzheimer's disease. *Molecules*, **24**(9): 1748.

