

A retrospective study on pre-operative CT-guided hook-wire localization of pulmonary nodules

Z. Xu¹, Y. Ni¹, B. Gu¹, H. Zhou², Y. Luo¹, N. Li³, S. Chen^{1*}

¹Department of Thoracic Surgery, The Affiliated Huaian No.1 People's Hospital of Nanjing Medical University, Huai'an223300, China

²Department of Thoracic Surgery, Guanyun People's Hospital, Guanyun222299, China

³Department of Sanatorium 1, Air Force Health Care Center for Special Service Hangzhou Sanatorium 5, Hangzhou310002, China

ABSTRACT

► Original article

***Corresponding author:**

Sheng Chen, Ph.D.,

E-mail:

chenshengnj@outlook.com

Received: February 2023

Final revised: April 2023

Accepted: May 2023

Int. J. Radiat. Res., July 2023;
21(3): 377-382

DOI: 10.52547/ijrr.21.3.4

Keywords: Pulmonary nodules, computed tomography, thoracoscopy.

Background: The Background: Currently, surgical resection of the small and sub-centimeter pulmonary nodules (< 2 cm) is quite challenging via the thoroscopic procedure. Our retrospective study aimed to evaluate the clinical efficiency of pre-operative CT-guided hook-wire localization of targeted pulmonary nodule patients prior to video-assisted thoracoscopic surgery (VATS) or surgery. **Materials and Methods:** 60 patients comprising pre-operative computed tomography (CT)-guided hook-wire localization of pulmonary nodules with < 2 cm diameter were retrospectively enrolled. Herein, we evaluated clinical variables, pathological outcomes, hook-wire localization procedure-related features, and complications from targeted pulmonary nodules patients. **Results:** Pre-operative CT-guided hook-wire localization was carried out successfully in 60 (100%) patients with wedge resection 41 (68%), segmentectomy 10 (16.7%), and lobectomy 9 (15%). Hook-wire localization procedure had mean time of 0.91±0.29 h, and 11 (18.3%) blood loss. All pulmonary nodule patients were positive pathological diagnoses for benign or malignant lesions, such as 5 (8.3%) benign lesions, 29 (48.3%) minimal adenocarcinoma (MIA) or invasive adenocarcinoma (IAC), and 21 (33.3%) adenocarcinoma in situ (AIS) malignant lesions. The majority of patients with hook-wire localization were either asymptomatic 19 (31.7%) or shown to have mild pain 25 (41.7%) and irritable cough 7 (11.7%). **Conclusion:** Preoperative CT-guided hook-wire localization of pulmonary nodules is safe and effective, which can reduce the operative time of targeted pulmonary nodules, and improve the safety and outcomes of surgery.

INTRODUCTION

With the development and popularity of computed tomography (CT) technology and increased health awareness, pulmonary nodules (PNs) can be diagnosed at the early stages of lung diseases ⁽¹⁾. The use of video-assisted thoracoscopic surgery (VATS) to excise PNs for definitive diagnosis and treatment is often recommended when minimally invasive techniques cannot be used for accurate diagnosis ⁽²⁾. VATS allows both diagnosis and radical resection of PNs, and is the recommended treatment for suspected malignant PNs with a long course ^(3, 4). With the increasing sophistication of VATS lung segmentectomy, not only can sufficient diseased tissue be removed, but also healthier lung tissue can be preserved ⁽⁵⁾. However, patients with benign or malignant PNs are difficult to accurately resect and to intraoperatively explore PNs with small and unevenly dense lesions, which are distant from the visual pleura ⁽⁶⁾. If the nodule lesion cannot be localized preoperatively, some patients might be

forced to undergo lobectomy due to the lesion cannot be detected. Therefore, accurate and effective preoperative localization is the key to radical resection of the lesion ⁽⁷⁾.

The usefulness of conventional procedures such as CT-guided fine-needle aspiration biopsy or transbronchial) could be constrained by the smaller diameter of PNs ⁽⁸⁾, thus hindering accurate localization. Preoperative CT-guided localization of the nodule positions assures rapid nodule localization and directs intraoperative management of the surgical margins, which improves surgical safety and also saves operative time ⁽⁹⁾. CT-guided lung puncture localization is not therapeutically feasible. It only serves to guide the precise localization of PNs lesions that needs to be excised during surgery, ensures surgical margins, shortens surgical duration, and minimizes surgical errors and complications ⁽¹⁰⁾. A variety of techniques are known for localizing PNs, which include hook-wire ⁽¹¹⁾, palpations by finger ⁽¹²⁾, ultrasound during operation ⁽¹³⁾, methylene blue ⁽¹⁴⁾, and micro coils ⁽¹⁵⁾. High

detection rates of up to 100% have been achieved with radionuclides or iodine oil (16-18).

Besides, accurate preoperative localizations and surgical resections of the small and sub-centimeter PNs (< 2 cm) are challenging via the thoracoscopic procedures. Henceforth, our retrospective study aimed to evaluate the clinical significance of preoperative CT-guided hook-wire localization prior to VATS or surgery in PNs patients. The novelty of our study was that the application of preoperative CT-guided hook-wire localization of pulmonary nodules could reduce the operative time of targeted pulmonary nodules, and improved the safety and outcomes of surgery.

MATERIALS AND METHODS

Patients

Our study enrolled 60 PNs patients who underwent pre-operative CT-guided localization from 2020 January to 2022 August, retrospectively. According to the Declaration of Helsinki, the study was carried out in accordance with the ethics committee of the Affiliated Huaian No.1 People's Hospital of Nanjing Medical University (Registration No. 2019(L)-008A, August, 2019, March), and recruited patients who provided informed permission while in the hospital. Inclusion criteria include: 1) Patients had hook-wire localization before nodule excision surgeries such as wedge resection, segmentectomy, and lobectomy. 2) Complete medical records of patients with localization, surgery, and pathological results. 3) Clinical stage Ia non-small-cell lung cancer (NSCLC) nodules with ≤ 2 cm diameter and low tumor malignancy. 4) Ground glass nodules (GGO) component $\geq 50\%$. 5) Blood tumor indicators such as carcinoembryonic antigen (CEA), neuron specificity enolase (NSE), and squamous cell carcinoma antigen (SCC cytokeratin 19 fragment (CYFRA21-1)) were normal. Exclusion criteria include: 1) Nodule lesion was highly malignant or suspected lymph node metastasis. 2) Nodules situated close to the hilum, where adequate margins couldn't be guaranteed or required lobectomy.

CT-guided puncture localization procedure

All patients were admitted to our hospital prior to the procedure to evaluate the location of lesion. CT (SOMATOM Definition Flash dual-source 128 CT machine, Siemens, Germany) guided nodule puncture localization was performed using a hook-wire procedure. Hook-wire positioning process was as follows: Preoperatively, the patients were brought to the CT room, where CT scans were firstly done to locate the nodule based on the previous CT images, and punctures were localized according to CT guidance and performed lung puncture localizations using a hook-wire. After punctures, another scan was performed to determine if the needles (Argon A02A,

Texas, USA) 21 G (0.8 mm) \times 10 cm were precisely positioned on the nodule of each patient. The prototype CT image of pulmonary nodules and lung puncture localization was displayed in figure 1. After localization, patients entered the operating room, and were anesthetized and sterilized for elected surgeries. The operating site was usually selected at the 4th or 5th intercostal space in the anterior axillary line, and the other observation site was usually selected at the 7th intercostal space in the mid-axillary line. Once operating instruments were inside the lung cavity, the lung tissue at the location of the localization needle was lifted, depending on the location of the needle. Generally, in 2 cm surroundings from the nodal margins, the nodules were excised and sutured with an endoscopic linear suture. After surgery, the pleural cavity was flushed with normal saline solutions and a 28 F chest tube was inserted. Post-operative paraffin pathology specimens were collected and analyzed for all recruited patients.

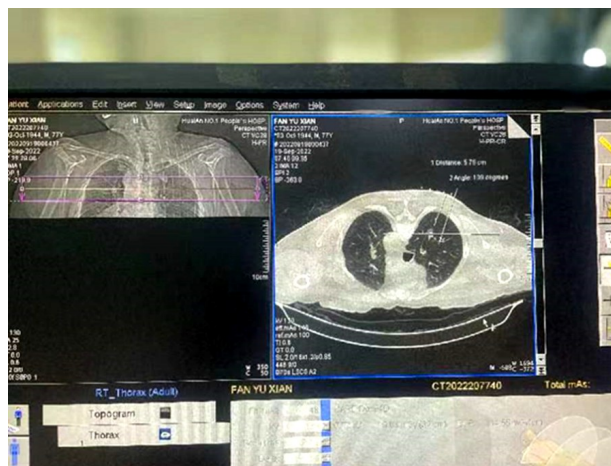


Figure 1. The prototype CT image of pulmonary nodules and lung puncture localization.

Statistical analysis

SPSS software (version 20.0, International Business Machines Corporation, USA) was used throughout the study for statistical analysis and all the data were represented as mean \pm standard deviation. Descriptive clinical data and variables were represented as proportions (%). $P < 0.05$ was considered to be statistical significance.

RESULTS

Characteristics of patients

Our study enrolled a total of 60 PNs patients, 28 males (46.7%) and 32 females (53.3%), and the mean age was 51.07 ± 5.32 years. Herein, 19 (31.7%) patients had a smoking history. PNs had a mean size of 10.6 mm (range 6 ~ 19 mm), where 6-10 mm and > 10 mm diameter PNs were 61.7% and 38.3% respectively. Nineteen patients of PNs were located at the right upper lobe (31.7%), 16 patients of PNs were

located at the left upper lobe (26.7%), 13 patients of PNs were located at the left lower lobe (21.7%), 9 patients of PNs were located at the right lower lobe (15%) and 3 patients of PNs were located at the right middle lobe (5%), as displayed in table 1.

Table 1. Clinical characteristics of enrolled PNs patients.

Variables	
Male/female	28/32
Mean age (years)	51.07±5.32
Smoke history	19(31.7%)
Size (mm)	Mean, 10.6, range, 6.0–19.0
6-10	8.46(61.7%)
>10	14.09(38.3%)
Locations	
RUL	19(31.7%)
RML	3(5%)
RLL	9(15%)
LUL	16(26.7%)
LLL	13(21.7%)

Abbreviations: RUL-Right upper lobe, RML-Right middle lobe, RLL-Right lower lobe, LUL-Left upper lobe, LLL-Left lower lobe.

Hook-wire localization procedure and complications

Besides, it was revealed in table 2 that, preoperative CT-guided hook-wire localization was carried out in 41 PNs patients underwent wedge resection (68%), 10 PNs patients underwent segmentectomy (16.7%), and 9 PNs patients underwent lobectomy (15%). The hook-wire procedure in wedge resection, segmentectomy, and lobectomy was 0.74 ± 0.14 hours, 1.26 ± 0.16 hours, and 1.31 ± 0.20 hours, respectively, and the average time was 0.91±0.29 hours. Based on hook-wire localization, it was discovered that PNs from pleural distances were 12.11 ± 4.94 mm. The first puncture was successful in 35 patients (58.3%), and the puncture more than once was 25 patients (41.7%). The pathological results of PNs patients were positive pathological diagnoses for benign or malignant lesions, including 5 cases of benign lesions (8.3%), 29 cases of minimal adenocarcinoma (MIA) or invasive adenocarcinoma (IAC) (48.3%), 4 cases of atypical adenomatous adenocarcinoma (AAH) (6.7%), 21 cases of adenocarcinoma in situ (AIS) (33.3%) and 1 case of metastases-related malignant PNs (1.7%). Eleven PNs patients had procedure-related blood loss (18.3%) and the post-operative hospitalization days were 5.50 ± 1.07 days.

The incidence of hook-wire localization-related complications was displayed in table 3. It was found that 19 PN patients were asymptomatic (31.7%), 25 PN patients had mild pain (41.7%), 7 PN patients had irritable cough (11.7%), 4 PN patients had pneumothorax (6.7%), 4 PN patients had hemoptysis (6.7%) and 1 PN patient had severe pain (1.7%).

Table 2. Hook-wire procedure-related features and pathological results.

Pathological results, procedure-related features	
Type of resection	
Wedge resection	41(68.3%)
Segmentectomy	10(16.7%)
Lobectomy	9(15%)
Procedure timing(h)	0.91±0.29
Wedge resection	0.74±0.14
Segmentectomy	1.26±0.16
Lobectomy	1.31±0.20
Nodule from pleural distance (mm)	12.11±4.94
Puncture times	
1	35(58.3%)
>1	25(41.7%)
Pathological results	
Benign lesions	5(8.3%)
MIA or IAC	29(48.3%)
AAH	4(6.7%)
AIS	21(33.3%)
Metastases	1(1.7%)
Procedure-related blood loss	11(18.3%)
Post-operative hospitalization day	5.50±1.07

Abbreviations: MIA-Minimal invasive adenocarcinoma, IA-Invasive adenocarcinoma, AAH-Atypical adenomatous adenocarcinoma, AIS-Adenocarcinoma in situ. h-hour.

Table 3. Incidence of hook-wire localization-related complications.

Preoperative complications	
Asymptomatic	19(31.7%)
Mild pain	25(41.7%)
severe pain	1(1.7%)
Irritable cough	7(11.7%)
Pneumothorax	4(6.7%)
Hemoptysis	4(6.7%)

DISCUSSION

Nowadays, localization methods of PNs are widely applied, including preoperative CT localization with local injection of sclerosing agent or stain, preoperative CT-guided hook-wire localization, intraoperative ultrasound localization, CT fluoroscopic localization, etcetera, which have significant advantages and disadvantages⁽¹⁹⁾. In accordance with the current clinical situation, our study applied the preoperative CT-guided hook-wire localization method. The method has the advantages of being cost-effective, simplified procedure, high localization accuracy, and minimized complication (bleeding/pneumothorax) rate, while disadvantages of CT-based radiation and pain, etcetera. In addition, VATS lobectomy and wedge resection were also carried out in our study. For thoracic adhesions or deeply located PNs, the localization of such lesions can be quickly determined intraoperatively after the effective placement of the localization needle. The effective positioning of the needle can quickly

determine the location and depth of the lesion intraoperatively, which can guide intraoperative exploration, reducing intraoperative omissions and malignant spread, and metastasis caused by repeated compression of lung tissue. Similarly, a hook-wire localization needle can be lifted intraoperatively to position the lesion at the top of the lung tissue to obtain adequate margins. Meanwhile, based on the markings of the localizing needle, the lung tissue can be repeatedly squeezed to avoid the spread and metastasis of malignant lesions. As a result, the pathologist can quickly detect the lesion and perform the frozen section examination by the localization target lesions, and provide timely feedback intraoperatively. Therefore, the unique advantages of CT-guided hook-wire localization are shortening surgery time and reducing surgical trauma⁽²⁰⁻²²⁾.

PNs are clinically referred to as lesions with a diameter of < 3 cm, well-defined borders, and circular opaque areas. In terms of density, nodules are classified as solid, partially solid, solid, or pure ground glass-like nodules⁽²³⁾. Small PNs are characterized by well-defined nodules, <1.0 cm, and CT values ≥ 130 Hu. Recently, frequent lung diseases have been characterized as small indeterminate PNs, with both high rates of missed and misdiagnosis due to the complex and diverse etiology of the disease and the lack of unique clinical manifestations⁽²⁴⁾. In the majority of cases, small PNs are benign or early-stage malignant lesions. Most benign nodules are inflammatory, hemangioma, or tuberculosis, whereas malignant, most of them are early-stage lung cancer or metastatic cancer⁽²⁵⁾. Consistently, in our study, the outcomes of Table 2 also confirmed 5 cases of non-neoplastic lesions (8.3%) that were either inflammatory or fibrotic lesions. Meanwhile, 29 cases of MIA or IAC (48.3%), 21 cases of AIS (33.3%), 1 case of metastases-related malignant PNs (1.7%) and 4 cases of AAH (6.7%) were observed.

Small PNs biopsy by percutaneous fine needle puncture under multilayer spiral CT positioning has the capability of being precisely localized, allowing a certain amount of tissue strip specimens to be obtained, and allowing the specimen to remain morphologically unchanged and without damage to facilitate histological observation of lesions⁽²⁶⁾. However, due to the small size of PNs, the number of tissue specimens obtained by puncture may not achieve the histologic characterization⁽²⁷⁾. In order to obtain more information, modern diagnostic pathology combines conventional histological diagnosis with immunohistochemistry. The development of immunohistochemical techniques and the use of new specific antibodies have provided a scientific basis for the pathological diagnosis of tumors and are important in clarifying the pathological diagnosis. In histological combination immunohistochemical tests, the diagnostic accuracy can reach more than 98%^(28, 29). In line with the above literatures, the results of table 2 in our study

also confirmed that all 60 cases were successfully punctured and localized with a success rate of 100%. The diagnostic rate was also fully achieved. The PNs specimens obtained by puncture were examined by immunohistochemical analysis, and PNs could be identified as benign or early NSCLC, which were consistent with a previous study proposed by Zhou *et al*⁽³⁰⁾.

Preoperative CT-guided hook-wire localization is an invasive localization method with some inevitable complications, including pneumothorax and dislodgement and displacement of the localization needle. Since lungs are non-substantial organs, pulmonary tissue is loose and distended, and thus hook-wire needle dislocation is often seen after placement into lung tissues. Nevertheless, some studies have shown that subpleural hemorrhage or hematoma could be found after detachment based on preoperative CT and anatomical localization, resulting in effective excision of the lesion^(9, 20, 22). In our study, the outcomes of table 3 displayed 25 patients had mild pain, 1 patient had severe pain, and 4 patients had hemoptysis during pre-operative CT scan after localization needle placement. At the same time, 4 patients presented with pneumothorax and 7 patients with an irritable cough but the remaining patients were asymptomatic and not treated with any specific treatment, except for routine intraoperative management, which was similar to former report⁽³¹⁾.

In addition, the results of table 2 in our study demonstrated that hook-wire localization procedure had a mean localization procedure time of (0.91 ± 0.29) h, which proved the effectiveness and easiness of the localization method, which was accordance with former reports⁽³²⁾. Due to the deep position of the lesion edge (12.11 ± 4.94) mm from the pleura of the wall, the hook-wire localization needle was not prone to dislodgement and displacement. The first puncture was successful in 35 patients (58.3%), and the puncture more than once was 25 patients (41.7%). In actual practice, attention is required to the following points: (1) after puncturing is completed, patients should be transferred to the operating theater with horizontal trolleys as soon as possible. (2) Patients should stay in the prone position during transfer to prevent unwanted movement. (3) After the thoracoscope enters the chest cavity, marking can be done on the lung surface with electrocoagulation, and the puncturing needle can be shortened and placed in the thoracic cavity to avoid dislodging of the hook-wire during intraoperative operation or pulmonary atrophy, which also facilitate confirmation of the targeted lesion. The targeted lesions can also be easily identified to assure a safe procedure.

Along with the increasing sophistication of lung segmentectomy/wedge resection, and the rising recognition of PNs, lung segmentectomy/wedge resections are gradually being applied in PNs surgical management⁽³³⁾. While the treatment of nodules

located in the periphery of the lung or the adjacent subpleural parenchyma was previously achieved by performing a simple wedge resection. However, if the nodule is located deep in the lung, then an adequate cut-edge distance might be difficult to ensure. Lobectomy can completely excise deeply located PNs while ensuring adequate margins, although a significant loss of pulmonary functions remains inevitable⁽³⁴⁾. Based on several studies from China and abroad, the advantages of thoracoscopic lung segment resection for benign nodules > 2 cm from the pleura and ground glass nodules < 1 cm were reported, which included complete resection of the lesion, minor surgical trauma, minor complications, with similar prognosis as lung lobectomy⁽³⁵⁻³⁷⁾. In our study, 51 patients underwent wedge resections and lung segmentectomy to ensure that the tumor was at least 2 cm from the resection margin and part of the lesion was located at the intersegment level. In benign disease, complete excision of the lesion is required instead of considering the intersegmental level, and veins may be managed along with the intersegmental level. Thoracoscopic lobectomies are performed by an experienced surgical practitioner, and while learning thoracoscopic nodules resection techniques, one should start from lingual and dorsal segments with well-defined anatomy and less vascular variation, and then gradually expand to other lung segments. Our study showed that all patients had successful localization and excision of lung segment-based nodule lesions with no obvious major complications. However, the current study was carried out in a single-center retrospective manner. Due to the relatively limited sample size of the present study, further studies and refinements are warranted. As surgeons acquire expertise in lung segmental resections of lesions, considerably more patients with PNs would be benefited.

CONCLUSION

Preoperative CT-guided hook-wire localization of pulmonary nodules is safe and effective, which can reduce the operative time of targeted pulmonary nodules, and improvise the safety and outcomes of surgery.

ACKNOWLEDGMENT

None.

Funding: None.

Conflict of interest: The authors confirm they have no conflicts of interest to declare.

Ethical consideration: This study was carried out with the approval of the ethics committee of the Affiliated Huaian No.1 People's Hospital of Nanjing Medical University (Registration No. 2019(L)-008A, August, 2019, March).

Author contribution: Zhongneng Xu, Yaojun Ni, Biao Gu and Hao Zhou participated in the study design and the literature search. Zhongneng Xu, Biao Gu, Yonggang Luo and Nunu Li collected the data and wrote the manuscript. Zhongneng Xu, Yaojun Ni, Biao Gu, Hao Zhou, Yonggang Luo, Nunu Li and Sheng Chen revised the manuscript. All authors read and approved the final manuscript.

REFERENCES

- Swensen SJ, Jett JR, Hartman TE, et al. (2005) CT screening for lung cancer: five-year prospective experience. *Radiology*, **235**(1): 259-65.
- Hsu HH, Shen CH, Tsai WC, et al. (2015) Localization of nonpalpable pulmonary nodules using CT-guided needle puncture. *World J Surg Oncol*, **13**: 248.
- Rivera MP, Mehta AC, Wahidi MM (2013) Establishing the diagnosis of lung cancer: Diagnosis and management of lung cancer, 3rd ed: American College of Chest Physicians evidence-based clinical practice guidelines. *Chest*, **143**(5): e1425-e1655.
- Bernard A (1996) Resection of pulmonary nodules using video-assisted thoracic surgery. The Thorax Group. *Ann Thorac Surg*, **61**(1): 202-4; discussion 204-5.
- Greenfield AL, Steiner RM, Liu JB, et al. (1997) Sonographic guidance for the localization of peripheral pulmonary nodules during thoracoscopy. *AJR Am J Roentgenol*, **168**(4):1057-60.
- Gould MK, Fletcher J, Lannettoni MD, et al. (2007) Evaluation of patients with pulmonary nodules: when is it lung cancer? ACCP evidence-based clinical practice guidelines (2nd edition). *Chest*, **132**(3): 1085-1305.
- Gould MK, Donington J, Lynch WR, et al. (2013) Evaluation of individuals with pulmonary nodules: when is it lung cancer? Diagnosis and management of lung cancer, 3rd ed: American College of Chest Physicians evidence-based clinical practice guidelines. *Chest*, **143**(5): e935-e1205.
- Heerink WJ, de Bock GH, de Jonge GJ, et al. (2017) Complication rates of CT-guided transthoracic lung biopsy: meta-analysis. *Eur Radiol*, **27**(1):138-148.
- Chen S, Zhou J, Zhang J, et al. (2011) Video-assisted thoracoscopic solitary pulmonary nodule resection after CT-guided hookwire localization: 43 cases report and literature review. *Surg Endosc*, **25**(6):1723-9.
- Zhou JH, Li WT, Chen HQ, et al. (2009) CT-guided hookwire localization of small solitary pulmonary nodules in video-assisted thoracoscopic surgery. *Zhonghua Zhong Liu Za Zhi*, **31**(7): 546-9.
- Ichinose J, Kohno T, Fujimori S, et al. (2013) Efficacy and complications of computed tomography-guided hook wire localization. *Ann Thorac Surg*, **296**(4): 1203-1208.
- Suzuki K, Nagai K, Yoshida J, et al. (1999) Video-assisted thoracoscopic surgery for small indeterminate pulmonary nodules: indications for preoperative marking. *Chest*, **115**(2): 563-8.
- Kondo R, Yoshida K, Hamanaka K, et al. (2009) Intraoperative ultrasonographic localization of pulmonary ground-glass opacities. *J Thorac Cardiovasc Surg*, **138**(4): 837-42.
- Lenglinger FX, Schwarz CD, Artmann W (1994) Localization of pulmonary nodules before thoracoscopic surgery: value of percutaneous staining with methylene blue. *AJR Am J Roentgenol*, **163**(2): 297-300.
- Mayo JR, Clifton JC, Powell TI, et al. (2009) Lung nodules: CT-guided placement of microcoils to direct video-assisted thoracoscopic surgical resection. *Radiology*, **250**(2): 576-85.
- Zaman M, Bilal H, Woo CY, et al. (2012) In patients undergoing video-assisted thoracoscopic surgery excision, what is the best way to locate a subcentimetre solitary pulmonary nodule in order to achieve successful excision? *Interact Cardiovasc Thorac Surg*, **15**(2): 266-72.
- Chella A, Lucchi M, Ambrogi MC, et al. (2000) A pilot study of the role of TC-99 radionuclide in localization of pulmonary nodular lesions for thoracoscopic resection. *Eur J Cardiothorac Surg*, **18**(1): 17-21.
- Watanabe K, Nomori H, Ohtsuka T, et al. (2006) Usefulness and complications of computed tomography-guided lipiodol marking for fluoroscopy-assisted thoracoscopic resection of small pulmo-

- nary nodules: experience with 174 nodules. *J Thorac Cardiovasc Surg*, **132**(2): 320-4.
19. Jin X, Wang T, Chen L, et al. (2021) Single-stage pulmonary resection via a combination of single hookwire localization and video-assisted thoracoscopic surgery for synchronous multiple pulmonary nodules. *Technol Cancer Res Treat*, **20**:15330338211042511.
 20. Zhang H, Li Y, Yimin N, et al. (2020) CT-guided hook-wire localization of malignant pulmonary nodules for video assisted thoracoscopic surgery. *J Cardiothorac Surg*, **15**(1): 307.
 21. Wang T, Ma S, Yan T, et al. (2015) Computed tomography guided hook-wire precise localization and minimally invasive resection of pulmonary nodules. *Zhongguo Fei Ai Za Zhi*, **18**(11): 680-5.
 22. Hanauer M, Perentes JY, Krueger T, et al. (2016) Pre-operative localization of solitary pulmonary nodules with computed tomography-guided hook wire: report of 181 patients. *J Cardiothorac Surg*, **11**: 5.
 23. Au-Yong ITH, Hamilton W, Rawlinson J, et al. (2020) Pulmonary nodules. *BMJ*, **371**:m3673.
 24. Bueno J, Landeras L, Chung JH. (2018) Updated Fleischner Society Guidelines for Managing Incidental Pulmonary Nodules: Common Questions and Challenging Scenarios. *Radiographics*, **38**(5):1337-1350.
 25. Mazzone PJ and Lam L. (2022) Evaluating the patient with a pulmonary nodule: A Review. *JAMA*, **327**(3): 264-273.
 26. Laurent F, Montaudon M, Latrabe V, et al. (2003) Percutaneous biopsy in lung cancer. *Eur J Radiol*, **45**(1): 60-8.
 27. Cheng D, Wang Z, Cui J, et al. (2020) Does percutaneous transthoracic needle biopsy increase the risk of pleural recurrence in patients with stage I lung cancer? *Interact Cardiovasc Thorac Surg*, **30**(6): 834-838.
 28. Azour L, Liu S, Washer SL, et al. (2021) Percutaneous transthoracic lung biopsy: Optimizing yield and mitigating risk. *J Comput Assist Tomogr*, **45**(5):765-775.
 29. Sakai H and Takeda M (2019) Percutaneous transthoracic needle biopsy of the lung in the era of precision medicine. *J Thorac Dis*, **11**(9): S1213-S1215.
 30. Zhou JH, Li WT, Chen HQ, et al. (2009) [CT-guided hookwire localization of small solitary pulmonary nodules in video-assisted thoracoscopic surgery]. *Zhonghua Zhong Liu Za Zhi*, **31**(7): 546-9.
 31. Zhang H, Li Y, Yimin N, et al. (2020) CT-guided hook-wire localization of malignant pulmonary nodules for video assisted thoracoscopic surgery. *J Cardiothorac Surg*, **15**(1): 307.
 32. Lv X, Yang Y, Hu J, et al. (2011) [Clinical application of CT-guided preoperative pulmonary nodule localization technique]. *Zhongguo Fei Ai Za Zhi*, **14**(5): 418-20.
 33. Schuchert MJ, Abbas G, Awais O, et al. (2012) Anatomic segmentectomy for the solitary pulmonary nodule and early-stage lung cancer. *Ann Thorac Surg*, **93**(6):1780-5; discussion 1786-7.
 34. Endoh H, Tanaka S, Yajima T, et al. (2010) Pulmonary function after pulmonary resection by posterior thoracotomy, anterior thoracotomy or video-assisted surgery. *Eur J Cardiothorac Surg*, **37**(5):1209-14.
 35. Shaw JP, Dembitzer FR, Wisnivesky JP, et al. (2008) Video-assisted thoracoscopic lobectomy: state of the art and future directions. *Ann Thorac Surg*, **85**(2):S705-9.
 36. Leshnowar BG, Miller DL, Fernandez FG, et al. (2010) Video-assisted thoracoscopic surgery segmentectomy: a safe and effective procedure. *Ann Thorac Surg*, **89**(5):1571-6.
 37. Li W, Wang Y, He X, et al. (2012) Combination of CT-guided hookwire localization and video-assisted thoracoscopic surgery for pulmonary nodular lesions: Analysis of 103 patients. *Oncol Lett*, **4**(4): 824-828.