

Analysis of application of uniportal video-assisted thoracoscopic surgery in the treatment of non-small cell lung cancer and value of improving the immune function of patients

T. Guo[#], Y. Yu[#], H. Wang, B. Zhou, X. Zhang, D. Zhang, H. Li^{*}, Z. Sun^{*}

Department of Thoracic Surgery, Affiliated Hospital of Hebei University, No. 212, Yuhua East Road, Lianchi District, Baoding, Hebei, 071000, China

ABSTRACT

► Original article

*Corresponding author:

Hefei Li and Zhenqin Sun, Ph.D.,

E-mail: sunzq18@163.com,
surgerylihefei@sina.com

Received: March 2023

Final revised: June 2023

Accepted: July 2023

Int. J. Radiat. Res., October 2023;
21(4): 821-826

DOI: 10.52547/ijrr.21.4.30

Keywords: Video-assisted thoracic surgeries, non-small cell lung cancer, immune system phenomena, inflammation, postoperative complications.

Background: To investigate the use of uniportal video-assisted thoracoscopic surgery (U-VATS) in the treatment of non-small cell lung cancer (NSCLC). **Materials and Methods:** A total of 82 patients with early NSCLC in our hospital from May 2019 to January 2021 were enrolled to this study. Forty-one patients treated with spontaneous breathing U-VATS were the research group (RG), and 41 with conventional thoracoscopy were the control group (CG). Fasting peripheral blood was drawn from patients before (T0), one (T1) and three days after surgery (T2), respectively. White blood cells (WBC), interleukin-6 (IL-6), tumor necrosis factor- α (TNF- α), matrix metalloproteinase-9 (MMP-9) and T-lymphocyte subsets were measured in the blood. In addition, we counted the conversion rate to open chest and tracheal intubation in the RG, and compared the operation time, intraoperative bleeding, chest drainage, chest tube retention time, antibiotic application time, postoperative hospital stays and complications between groups. Finally, a 1-year prognostic follow-up was performed to record overall survival, chemotherapy rate, and recurrent metastasis rate. **Results:** At T1, WBC, IL-6, TNF- α , and MMP-9 were lower in the RG than in the CG, while immune function was better in the RG at T1 and T2 ($P < 0.05$). Complication rates were lower in the RG than in the CG when compared ($P > 0.05$). The prognosis of 1-year overall survival, chemotherapy rate, and recurrence rate were not different between the two groups ($P > 0.05$). **Conclusion:** Spontaneous breathing U-VATS can effectively reduce the inflammation and enhance the stability of immune function in NSCLC patients undergoing surgery.

INTRODUCTION

Recently, the incidence and mortality rate of lung cancer (LC) have been increasing, and it has become one of the most threatening malignancies to human health and life ⁽¹⁾. According to statistics, there are about 1.6 million new LC patients worldwide each year, of which more than 85% are non-small cell LC (NSCLC) ⁽²⁾. It is clinically believed that NSCLC is associated with long-term environmental and genetic interactions, and early-stage patients generally have no typical symptoms; Most NSCLC is diagnosed at mid- to late-stage, and the prognostic survival of patients is generally poor, their prognostic survival period is typically only 8-20 months, with a mortality rate of 80% or more within 5 years of prognosis ⁽³⁾. Surgery is currently the most important treatment for NSCLC. With the continuous development of medicine, minimally invasive surgery has become the mainstream surgical procedure, which has a significant positive effect on reducing intraoperative trauma and speeding up recovery ^(4,5).

Uniportal video-assisted thoracoscopic surgery (U-VATS) has been well developed in thoracic surgery and has realized the concept of promoting rapid patient recovery and greatly reducing intraoperative pain ^(6,7). In recent years, with the continuous improvement of anesthesia technology and surgical risk management, U-VATS under anesthesia with preserved spontaneous breathing has been gradually applied to clinical treatment and has played an important role in a variety of open-heart surgeries ^(8,9). Studies have pointed out that spontaneous breathing U-VATS has various advantages such as fewer complications, faster postoperative recovery, and shorter hospital stays, and is now used as the preferred ventilation option in various procedures in thoracic surgery ^(10,11).

However, due to the difficulty of the operation of spontaneous breathing U-VATS, it has not yet been fully popularized in clinical practice, and studies related to its application in NSCLC are still relatively rare. Therefore, this trial will investigate the application of spontaneous breathing U-VATS in the

treatment of NSCLC and the value of improving the immune function of patients, aiming to provide new ideas and means when diagnosing and treating NSCLC.

MATERIALS AND METHODS

The study was carried out at department of Affiliated Hospital of Hebei University from May 2019 to February 2022. This study was approved by the Ethics Committee of Affiliated Hospital of Hebei University (HDFYLL-IIT-2022-004, March 15, 2019).

Eighty-two patients with early-stage NSCLC admitted to our hospital from May 2019 to January 2021 were enrolled to this study, and were divided into research group (RG) (n=41) and control group (CG) (n=41) using random number table. The RG was treated with spontaneous breathing U-VATS and the CG was with normal thoracoscopic surgery. The experiment was conducted in strict compliance with the Declaration of Helsinki and was informed, consent was obtained from all study subjects and their families.

Inclusion and exclusion criteria

Inclusion criteria: The diagnosis of NSCLC was confirmed after a single lobectomy with conventional mediastinal lymph node dissection and pathology biopsy in our hospital, consistent with the clinical presentation of NSCLC¹²; all participants had complete data; Patients or immediate family members signed an informed consent form. Exclusion criteria: Patients with comorbid other oncological diseases and major organ damage; Patients who have received treatment for the disease; Patients with immune disorders; Patients with low treatment adherence; Those who are contraindicated for surgery; Persons contraindicated to anesthesia; Patients with drug allergies; Transferred patients.

Surgical methods

The surgeries were all performed by the same team in our hospital, and the RG was sedated with 5.0-10.0 µg of sufentanil (H20054171, Yichang Renfu Pharmaceutical Company Limited, Hubei, China), 0.5-1.0 µg/kg of dexmedetomidine hydrochloride (H20090248, Hengrui Pharmaceutical Company Limited, Jiangsu, China), and 1.5-2.0 mg/kg of propofol (H20051843, Jiabo Pharmaceutical Co., Guangdong, China) for induction of anesthesia. After loss of consciousness, 1.5-5.0 sevoflurane (H20180046, GE HEALTHCARE AS, Shanghai, China) was inhaled, and 0.5-1.0 µg/kg/h of dexmedetomidine hydrochloride and 0.01-0.05 µg/kg/min of remifentanyl (H20030197, Yichang Renfu Pharmaceutical Company Limited, Hubei, China) were pumped to maintain anesthesia. Nerve block anesthesia was performed in the paravertebral space

of the 5th-6th and 7th-8th thoracic vertebrae under ultrasound localization. Altogether 1% lidocaine (H11022295, Shanxi Jinxin Shuanghe Pharmaceutical, Shanxi, China) 10 mL was sprayed evenly on the surface of the dirty pleura for pleural surface anesthesia, and 0.375% ropivacaine (H20060137, Hengrui Pharmaceutical Company Limited, Jiangsu, China) 2 mL for vagal nerve block. Procedure: release of the inferior pulmonary ligament - clearance of the lymph nodes - dissection of the upper pulmonary veins - opening of the pulmonary fissure - dissection of the branches of the pulmonary arteries - dissection of the bronchi - clearance of the upper mediastinal lymph nodes. In the CG, anesthesia was induced as above, and a double-lumen tracheal tube was placed after loss of consciousness, with a single-lung mechanical ventilation in volume-controlled mode. Inhalation of 1.5-2.0% sevoflurane, pumping of dexmedetomidine hydrochloride 0.5-1.0 µg/kg/h, remifentanyl 0.01-0.02 µg/kg/min, and maintenance of anesthesia with additional ecortisone 0.2 mg/kg at 40-min intervals. The surgical procedure was as above.

Blood sample collection

Fasting peripheral blood was drawn from patients at preoperative (T0), 1 day (T1) and 3 days postoperative (T2), respectively, and the blood was tested for white blood cells (WBC), interleukin-6 (IL-6), tumor necrosis factor-α (TNF-α), matrix metalloproteinase-9 (MMP-9), cluster of differentiation (CD)3⁺, CD4⁺, CD8⁺, and NK. WBC was counted using a fully automated hematology analyzer BC-760 CS (Myriad, USA).

Enzyme linked immunosorbent assay (ELISA)

The serum was obtained by centrifugation (1505×g) for 10 min, and IL-6, TNF-α and MMP-9 were detected according to the instructions of the ELISA kit. The kit was purchased from TransGen Biotech (Beijing, China), and the operation was carried out strictly according to the kit instructions.

Flow cytometer

100 µL of blood was added with 10 µL each of CD3, CD4, CD8 and NK monoclonal fluorescent antibodies (abcam, USA), shaken and mixed, then 2 mL of hemolysin (Shanghai Lianzu Biotechnology Co., Ltd., China) was added, the supernatant was discarded after centrifugation, PBS buffer (abcam, USA) was added, the supernatant was discarded after centrifugation again, 300 µL of fixative (reagent for flow cytometry) was added, and CD3⁺, CD4⁺, CD8⁺ and NK cell concentrations were detected by flow cytometry (Beckman Coulter CytoFLEX S, USA).

Prognostic follow-up

Patients were followed up with a 1-year prognosis in the form of regular hospital reviews with an

interval of no more than 3 months between each recurrence.

Outcome measures

Safety indexes: The conversion rate to open chest and tracheal intubation in both groups were counted, and the statistical result $<5\%$ was considered as higher safety. (2) Clinical indexes: The operation time, intraoperative bleeding, chest drainage, chest drainage tube retention time, antibiotic application time and postoperative hospital stay were counted in both groups. (3) Inflammation: WBC, IL-6, TNF- α , MMP-9 levels in blood samples. (4) Immune function: T lymphocyte subsets CD3+, CD4+, CD8+ and NK cell levels in blood samples. (5) Postoperative complications: complications during the postoperative period to hospital discharge, and the complication rate was calculated. (6) Prognosis: prognosis 1-year overall survival rate, chemotherapy rate, recurrent metastasis rate.

Statistical methods

Statistical Package for the Social Sciences (SPSS) 24.0 software (IBM, America) was used for statistical analysis. Indicators such as the conversion rate to open heart were recorded as (%), comparative analysis was performed by chi-square test, measurement data were expressed as ($\bar{x} \pm s$), and comparative analysis was performed by independent sample t-test and paired t-test. $P < 0.05$ indicated statistically remarkable differences.

RESULTS

Comparison of clinical data

To guarantee the reliability of the test results, clinical data such as age, gender, and BMI were compared between both groups. It revealed no statistically remarkable differences ($P > 0.05$, table 1), confirming that both groups were comparable and confirming the credibility of the test results.

Table 1. Comparison of clinical data, none of the differences between the two groups were statistically significant.

Project	Control group (n=41)	Research group (n=41)	t/c ²	P
Age	58.68 \pm 5.99	58.00 \pm 8.05	0.434	0.666
BMI (kg/m ²)	23.63 \pm 3.54	24.37 \pm 2.97	1.025	0.308
Gender			0.052	0.820
Male/female	26/15	25/16		
Smoking			0.668	0.414
Yes/no	34/7	31/10		
Drinking			0.196	0.658
Yes/no	18/23	20/21		
TNM staging			0.195	0.659
I/II	22/19	20/21		
Surgical site			0.053	0.817
Left/right	14/27	15/26		
Pathological type			0.157	0.925
Adenocarcinoma/squamous cell carcinoma/other	37/3/1	36/4/1		

Comparison of safety indexes

The RG had a conversion rate to open chest of 2.44% and tracheal intubation of 0.0%, both results did not exceed the limit (5.00%), with a good safety profile. The CT findings of the patient before and after treatment are shown in figure 1A, B. A more significant reduction of the lesion in the lower lobe of the left lung was seen after treatment.

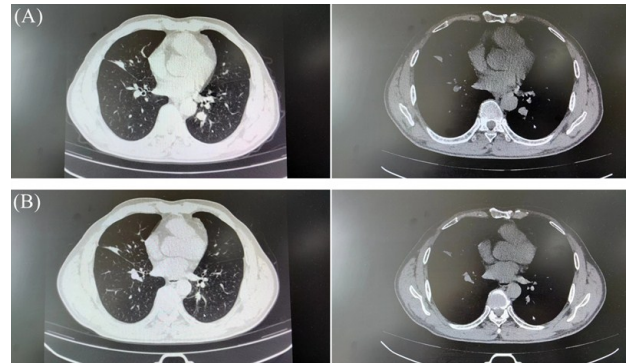


Figure 1. CT findings of a patient before and after treatment (male, 67 years old). (A) Images of the lung window and mediastinal window before treatment. (B) Images of the lung window and mediastinal window after treatment.

Comparison of clinical indicators

Comparison of operative time, intraoperative bleeding, chest drainage, chest tube retention time, antibiotic application time, and postoperative hospital stays between both groups manifested no statistical difference ($P > 0.05$, figure 2A-F).

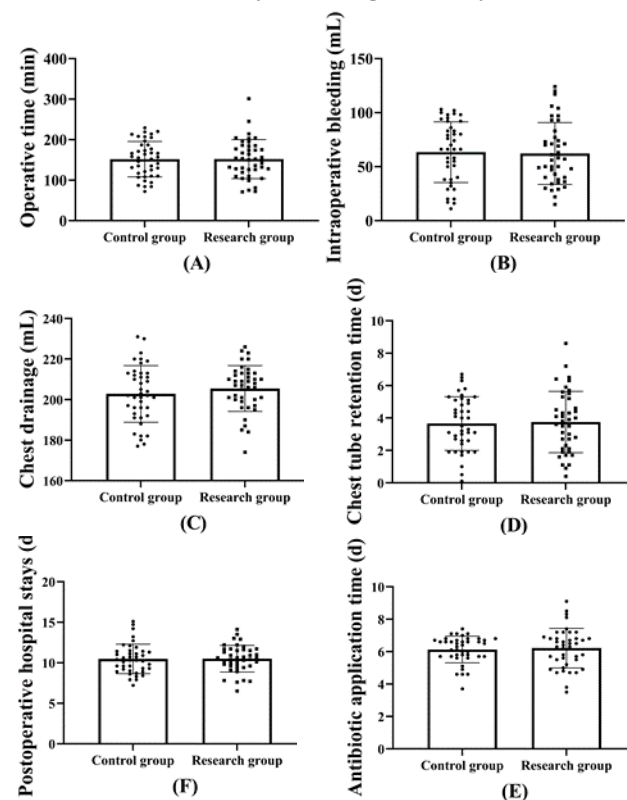
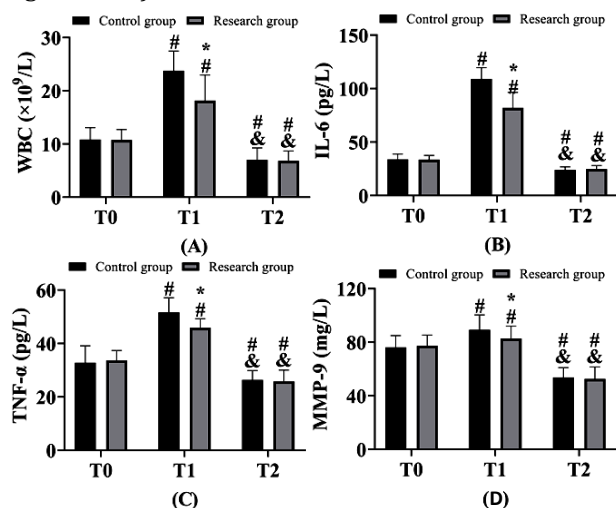


Figure 2. Comparison of clinical indicators. (A) Comparison of operative time. (B) Comparison of intraoperative bleeding. (C) Comparison of chest drainage. (D) Comparison of chest tube retention time. (E) Comparison of antibiotic application time. (F) Comparison of postoperative hospital stays.

Comparison of inflammation

At T0 and T2, there was no statistically remarkable difference in WBC, IL-6, TNF- α , and MMP-9 between both groups ($P>0.05$), and at T1, WBC, IL-6, TNF- α , and MMP-9 were lower in the RG than in the CG ($P<0.05$). Inflammatory factor levels were higher at T1 than at T0 in both groups, while they were lower at T2 than at T0 and T1 ($P<0.05$, figure 3A-D).



Comparison of immune function

Similarly, there was no difference in CD3⁺, CD4⁺, CD8⁺ and NK between both groups at T0 ($P>0.05$), and CD3⁺, CD4⁺ and NK were lower in both groups at T1 than at T0, but higher in the RG than in the CG ($P<0.05$). CD8⁺ was higher in both groups at T1 than

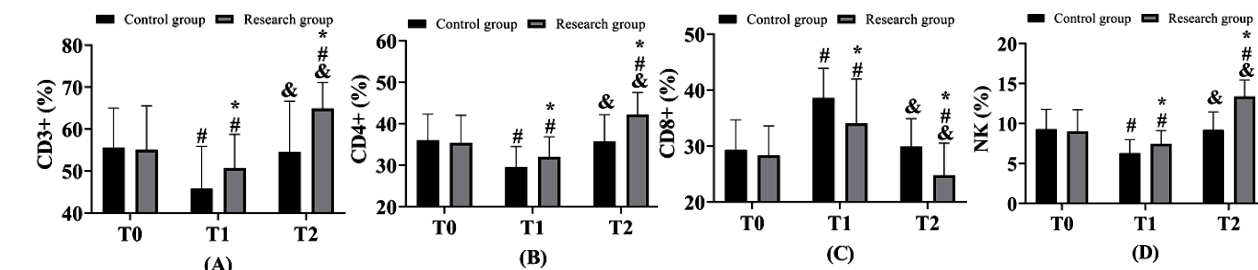


Figure 4. Comparison of immune function. (A) Comparison of CD3⁺ cell. (B) Comparison of CD4⁺ cell. (C) Comparison of CD8⁺ cell. (D) Comparison of NK cell. *Indicates that there is statistical significance compared with the control group ($P<0.05$). At preoperative (T0) and 1 d postoperative (T1) and 3 d postoperative (T2). # indicates that there is statistical significance compared with T0 ($P<0.05$). & indicates that there is statistical significance compared with T1 ($P<0.05$).

Table 2. Comparison of complications, research group had a lower rate of complications than control group.

Symptom	Hoarseness	Palpitations	Poor lung expansion	Pulmonary infection	Pleural effusion after extubation	Complication rates (%)
Control group (n=41)	3 (7.32)	2 (4.88)	2 (4.88)	2 (4.88)	2 (4.88)	26.83
Research group (n=41)	2 (4.88)	1 (2.44)	1 (2.44)	0 (0.0)	0 (0.0)	9.76
χ^2						3.998
P						0.046

Table 3. Comparison of prognosis, the overall survival rate, chemotherapy rate between the two groups. There was no difference in the recurrence rate.

Investigation item	Overall survival rate	Chemotherapy rate	Recurrence rate
Control group (n=41)	41 (100.0)	11 (26.83)	2 (4.88)
Research group (n=41)	41 (100.0)	8 (19.51)	1 (2.44)
χ^2	-	0.617	0.346
P	-	0.432	0.556

at T0, but lower in the RG than in the CG ($P<0.05$). There was no difference in CD3⁺, CD4⁺, CD8⁺ and NK in the CG at T2 compared with T0 ($P>0.05$), while CD3⁺, CD4⁺ and NK were higher than T0 and CD8⁺ was lower than T0 in the RG at T2 ($P<0.05$), and the results of comparison between both groups were consistent with T1 ($P<0.05$, figure 4A-D).

Comparison of complications

A total of four patients (9.76%) in the RG had post-operative complications, including two cases of hoarseness, one of palpitations, and one of poor lung expansion. While 11 patients (26.83%) in the CG had postoperative complications, including 3 cases of hoarseness, 2 of palpitations, 2 of pulmonary infection, 2 of pleural effusion after extubation, and 2 of poor lung expansion. No patient in either group developed complications such as respiratory failure or death. Complication rates were lower in the RG than in the CG when compared ($P<0.05$, table 2).

Comparison of prognosis

All study subjects were successfully followed up during the 1-year post-prognosis period, with an overall survival rate of 100.0% in both groups, with a chemotherapy rate of 19.51% in the RG and 26.83% in the CG. The recurrence rate was 2.44% in the RG and 4.88% in the CG. There was no statistically remarkable difference between both groups in terms of prognosis 1-year overall survival rate, chemotherapy rate, and recurrence rate ($P>0.05$, table 3).

DISCUSSION

Currently, NSCLC remains one of the most common malignancies worldwide. Surgery, as the most direct and effective method of LC treatment, has been a long-standing clinical research focus to continuously pursue higher safety while ensuring surgical outcomes⁽¹³⁾. In conventional NSCLC surgery, general anesthesia with tracheal intubation, in which patients' voluntary breathing is replaced by the external force of a ventilator, is usually performed before surgical radical surgery⁽¹⁴⁾. The advantage is that it is easier for the physician to perform, and the procedure is less risky⁽¹⁵⁾. However, studies have found a higher likelihood of complications associated with post-tracheal intubation in patients and a negative impact on postoperative anesthetic drug metabolism⁽¹⁶⁾. Thus, this study can lay a reliable foundation for the future treatment of NSCLC and the promotion and popularization of spontaneous breathing U-VATS by analyzing its application in NSCLC.

In this trial, we compared the differences in the indices of NSCLC patients treated with spontaneous breathing U-VATS and general thoracoscopy, and found no remarkable differences in surgical safety, clinical indices (figure 2) and prognosis (table 3) between groups, suggesting that both our spontaneous breathing U-VATS and general thoracoscopy have more desirable results in the treatment of NSCLC. Artificial pneumothorax is the basis of thoracoscopic surgery⁽¹⁷⁾. In this context, conventional tracheal intubation avoids lung collapse during surgery, while providing patients with a clear operative field and reducing the risk of mechanical trauma, as well as avoiding the possibility of infectious secretions obstructing the bronchi and lungs¹⁸. At the same time, the possibility of bronchospasm and ventilator-associated lung injury in patients will be greatly increased, and in more serious cases, severe respiratory failure will be caused, endangering life safety⁽¹⁹⁾. Spontaneous breathing U-VATS can effectively avoid various toxic side effects in tracheal intubation, and in this trial, we also found a lower rate of postoperative complications in the RG (table 2). In previous studies, spontaneous breathing U-VATS was found to reduce the adverse effects after upper lung resection with interstitial lung biopsy, consistent with the results of the present experiment^(20, 21). Furák *et al.* even mentioned a greater risk of intraoperative bleeding due to greater lung activity in patients during spontaneous breathing⁽²²⁾. In contrast, the results of the comparison of the above indicators in both groups of patients in this trial were not different, the reason for which we believe may be due to statistical calculation chance caused by the small number of cases. Besides, it may also be because there is still a lack of accepted clinical guidelines for the use of

spontaneous breathing U-VATS in NSCLC, so there is still much room for optimization in the surgical approach.

Nevertheless, in the comparison of postoperative inflammation and immune function between both groups, we saw that the status of the RG was dramatically better than that of the CG at 3 d postoperatively, which indicates a better anti-inflammatory effect and immune function protective benefit of spontaneous breathing U-VATS in radical NSCLC surgery. It is well known that disruption of body function after mechanical invasive operations is the key cause of postoperative recovery and infection in patients⁽²³⁾. Laparoscopic surgery was also invented to effectively reduce postoperative mechanical stress injuries in patients⁽²⁴⁾. The use of spontaneous breathing U-VATS is clinically applicable to laparoscopic surgery as it reduces postoperative inflammation and improves immune function of patients. Previously, we also found that spontaneous breathing U-VATS reduced stress injury after lymphangioleiomyoma surgery⁽²⁵⁾, which could corroborate the results of the current experiment. Of course, the lack of difference in inflammatory factors at T2 between groups may also be due to the less invasive laparoscopic surgery and the return to a stable state of organism function by 3 d postoperatively.

In subsequent studies, we need to include a larger number of study cases to confirm the specific effects of spontaneous breathing U-VATS on NSCLC and further validate its value in future LC treatment. We also need to follow the patients longer and compare the differences in the long-term prognosis. Meanwhile, there is still much room for optimization of specific surgical protocols for spontaneous breathing U-VATS, and these limitations will be the focus of our subsequent research.

CONCLUSION

Spontaneous breathing U-VATS can effectively reduce the inflammation and enhance the stability of immune function in patients with NSCLC surgery and has a high clinical safety. In the future, clinics should pay attention to the cultivation of physicians' spontaneous breathing U-VATS and popularize the clinical application to provide more reliable safety for patients.

ACKNOWLEDGEMENTS

Not applicable.

Competing Interests: The authors report no conflict of interest.

Availability of data and materials: The data that support the findings of this study are available from the corresponding author upon reasonable request.

Funding: This study is supported by the Major

livelihood special project of Hebei Provincial Department of Science and Technology (No. 20377770D).

Author contributions: T.G. and Y.Y. conceived and designed the project, and wrote the paper. H.W. and B.Z. generated the data. X.Z. and D.Z. analyzed the data. H.L. and Z.S. modified the manuscript. All authors gave final approval of the version to be published, and agree to be accountable for all aspects of the work.

REFERENCES

- Wu F, Wang L, Zhou C (2021) Lung cancer in China: current and prospect. *Current Opinion in Oncology*, **33**(1): 40–46.
- Alexander M, Kim SY, Cheng H (2020) Update 2020: Management of non-small cell lung cancer. *Lung*, **198**(6): 897–907.
- Herbst RS, Morgensztern D, Boshoff C (2018) The biology and management of non-small cell lung cancer. *Nature*, **553**(7689): 446–454.
- Jonna S and Subramaniam DS (2019) Molecular diagnostics and targeted therapies in non-small cell lung cancer (NSCLC): an update. *Discovery Medicine*, **27**(148): 167–170.
- Broderick SR (2020) Adjuvant and neoadjuvant immunotherapy in non-small cell lung cancer. *Thoracic Surgery Clinics*, **30**(2): 215–220.
- Elkhayat H and Gonzalez-Rivas D (2019) Non-intubated uniportal video-assisted thoracoscopic surgery. *Journal of thoracic disease*, **11**(3): S220–S222.
- Kim HK and Han KN (2017) Uniportal video-assisted thoracoscopic surgery segmentectomy. *Thoracic Surgery Clinics*, **27**(4): 387–398.
- Sanna S, Bertolaccini L, Brandolini J, et al. (2017) Uniportal video-assisted thoracoscopic surgery in hemothorax. *Journal of Visualized Surgery*, **3**: 126.
- Lerut T (2017) Uniportal video-assisted thoracoscopic surgery in esophageal diseases: an introduction. *Journal of Visualized Surgery*, **3**: 182.
- Huang PM and Lin WY (2020) Suction ventilation for uniportal video-assisted thoracic surgery without endotracheal intubation. *The Annals of Thoracic Surgery*, **109**(4): e301–e303.
- Bedetti B, Patrini D, Bertolaccini L, et al. (2018) Uniportal non-intubated thoracic surgery. *Journal of Visualized Surgery*, **4**: 18.
- Pennell NA, Arcila ME, Gandara DR, West H (2019) Biomarker testing for patients with advanced non-small cell lung cancer: Real-world issues and tough choices. *American Society of Clinical Oncology educational book, American Society of Clinical Oncology, Annual Meeting*, **39**: 531–542.
- Ettinger DS, Wood DE, Aisner DL, Akerley W, et al. (2017) Non-small cell lung cancer version 5, 2017 NCCN clinical practice guidelines in oncology. *Journal of the National Comprehensive Cancer Network: JNCCN*, **15**(4): 504–535.
- Tandberg DJ, Tong BC, Ackerson BG, Kelsey CR (2018) Surgery versus stereotactic body radiation therapy for stage I non-small cell lung cancer: A comprehensive review. *Cancer*, **124**(4): 667–678.
- Aoki MN, Amarante MK, de Oliveira CEC, Watanabe MAE (2018) Biomarkers in non-small cell lung cancer: Perspectives of individualized targeted therapy. *Anti-cancer Agents in Medicinal Chemistry*, **18**(15): 2070–2077.
- Scarci M, Gonzalez-Rivas D, Schmidt J, Bedetti B (2017) Management of intraoperative difficulties during uniportal video-assisted thoracoscopic surgery. *Thoracic Surgery Clinics*, **27**(4): 339–346.
- Hou X, Zhuang X, Zhang H, et al. (2017) Artificial pneumothorax: a safe and simple method to relieve pain during microwave ablation of subpleural lung malignancy. *Minimally invasive therapy & allied technologies: MITAT: Official Journal of the Society for Minimally Invasive Therapy*, **26**(4): 220–226.
- Hernandez-Arenas LA, Purmessur RD, Gonzalez-Rivas D (2018) Uniportal video-assisted thoracoscopic segmentectomy. *Journal of Thoracic*, (Suppl 10): S1205–S1214.
- Sakaguchi M (2021) Kyobu geka. *The Japanese Journal of Thoracic Surgery*, **74**(11): 921–924.
- Galvez C, Navarro-Martinez J, Bolufer S, et al. (2017) Non-intubated uniportal left-lower lobe upper segmentectomy (S6). *Journal of Visualized Surgery*, **3**: 48.
- Cherchi R, Grimaldi G, Pinna-Susnik M, et al. (2020) Retrospective outcomes analysis of 99 consecutive uniportal awake lung biopsies: a real standard of care? *Journal of Thoracic Disease*, **12**(9): 4717–4730.
- Furák J and Szabó Z (2021) Spontaneous ventilation combined with double-lumen tube intubation in thoracic surgery. *General Thoracic and Cardiovascular Surgery*, **69**(6): 976–982.
- Wormser C and Runge JJ (2016) Advances in Laparoscopic Surgery. *The Veterinary clinics of North America, Small Animal Practice*, **46**(1): 63–84.
- Cullinan DR, Schill MR, DeClue A, et al. (2017) Fundamentals of Laparoscopic Surgery: Not Only for Senior Residents. *Journal of surgical education*, **74**(6): e51–e54.
- Mantovani S, Vannucci J, Bassi M, et al. (2021) Left uniportal VATS for lung decortication after chemical pleurodesis under spontaneous breathing in patient with lymphangiomyomatosis. *Multimedia Manual of Cardiothoracic Surgery: MMCTS*, **2021**: 10, 1510/mmcts.