

Maxillary sinus anterior wall recurrence after intensity-modulated radiotherapy for nasopharyngeal carcinoma

Y. Fang^{1,2}, L. Wang¹, X. Chen¹, C. Cao^{1*}

¹Department of Radiation Oncology, The Cancer Hospital of the University of Chinese Academy of Sciences (Zhejiang Cancer Hospital), Institute of Basic Medicine and Cancer (IBMC), Chinese Academy of Sciences, Key Laboratory of Head & Neck Cancer Translational Research of Zhejiang Province, China

²Postgraduate training base Alliance of Wenzhou Medical University (Zhejiang Cancer Hospital), Hangzhou, Zhejiang, 310022, China

► Case report

*Corresponding author:

Caineng Cao, Ph.D.,

E-mail: caocn@zjcc.org.cn

Received: June 2023

Final revised: December 2023

Accepted: December 2023

Int. J. Radiat. Res., January 2024;
22(1): 239-242

DOI: 10.52547/ijrr.21.35

Keywords: *Nasopharyngeal carcinoma, intensity-modulated radiotherapy, recurrence, maxillary sinus, local failure.*

INTRODUCTION

Nasopharyngeal carcinoma (NPC) is a type of epithelial cancer that is associated with Epstein-Barr virus (EBV) infection, environmental and genetic factors, occurring mainly in East and Southeast Asia (1, 2). Due to its deep anatomical location and sensitivity to ionizing radiation, radiotherapy has become the mainstay of treatment for NPC. With the development of radiotherapy techniques, intensity-modulated radiotherapy (IMRT) has become the standard radiotherapy technique and has achieved excellent loco-regional control rates (3). However, approximately 10% of NPC patients developed local recurrence after IMRT, especially for patients with T4 NPC (4).

Recurrence of NPC is classified as “in-field”, “marginal” as well as “outside”. The majority of local recurrences are “in-field” (5). Rare sites of NPC recurrence after IMRT, such as the parotid and mastoid recurrence were reported previously (6-8). In this case, the site of recurrence was the anterior wall of the maxillary sinus. So far, recurrence in the anterior wall of the maxillary sinus after IMRT for NPC has not been reported in detail in the relevant literature.

ABSTRACT

Nasopharyngeal carcinoma (NPC) is a radiotherapy-sensitive tumor, but local recurrence still exists in part of the patients after receiving radiotherapy. The location of local recurrence of NPC is usually “in-field” and cases of parotid and mastoid recurrences have been reported. We report a fifty-nine-year-old female patient who presented with maxillary sinus anterior wall recurrence seven months after intensity-modulated radiotherapy (IMRT). Magnetic resonance imaging (MRI) showed a soft tissue mass in the anterior wall of the right maxillary sinus and the recurrence of NPC was confirmed by histopathology after biopsy. To date, the patient is alive with disease without distant metastasis. To our knowledge, this is the first report of maxillary sinus anterior wall recurrence after IMRT for NPC.

CASE REPORT

A 58-year-old female patient was admitted to our hospital with complaints of right-sided facial numbness and epistaxis for three months. The patient was diagnosed with non-keratinizing (differentiated) carcinoma by biopsy of the primary tumor. Nasopharyngoscopy findings showed a large raised neoplasm in the nasopharynx with involvement of the bilateral posterior choanae. Magnetic resonance imaging (MRI) on a 3.0-T system (Verio, Siemens Healthcare, Erlangen, Germany) (figure 1) showed irregular thickening of the nasopharyngeal walls on both sides and the parietal wall, extending to the right maxillary sinus lateral wall, right orbital apex, right cavernous sinus, and enlarged cervical lymph nodes on the right side.

Further clinical examination, including whole-body bone scanning (Infinia & Hawkeye; GE Medical Systems, Milwaukee, WI, USA), chest computed tomography (CT) (Ingenuity, Philips, Amsterdam, Netherlands), showed no evidence of distant metastasis. The disease was staged as cT₄N₁M₀, clinical stage IVa according to the Union for International Cancer Control and American Joint Committee on Cancer staging system for NPC, 8th edition. The patient received neoadjuvant

chemotherapy plus concurrent chemoradiotherapy. Neoadjuvant chemotherapy consisting of nedaplatin (Jilin Jinheng Pharmaceutical Co., Ltd, China) (75 mg/m²) and docetaxel (Jiangsu Hengrui Pharmaceuticals Co., Ltd, China) (75 mg/m²) was given every three weeks for 3 cycles. The dose of IMRT prescribed was 6996cGy, 6996cGy, 6105cGy and 5445cGy in 33 fractions delivered over 6 weeks at the periphery of the the planning target volume (PTV)nx+rn, PTVnd, PTV1 and PTV2, respectively. Nedaplatin (80 mg/m² every 3 weeks) and nimotuzumab (Biotech Pharmaceutical Co., Ltd, China) (200 mg per week) were given concurrently with IMRT.

After the completion of radiotherapy, the patient was followed up: 1 month after the completion of radiotherapy, every 3 months in the first 2 years. Seven months after IMRT, MRI of the head and neck (figure 2) showed a soft tissue mass in the anterior wall of the right maxillary sinus with bony destruction. Recurrence was confirmed by pathological biopsy (hematoxylin-eosin staining reagent, Tong Sheng Bio-technology, Ningbo, China) (figure 3). Immunohistochemistry (IHC) was conducted in the department of pathology of our hospital with P40 (I10172E-01, Biolyinx, China), CK5/6 (IHC-M060, Guangzhou LBP Medicine Science & Technology Co.,Ltd, China), EGFR (790-4347, Ventana Medical Systems, USA) and EBER (MC-3003, MXB Bio, Fuzhou, Fujian, China) using the standard protocol for routine diagnostic specimens (figure 3). The dose distribution at the level of the maxillary sinuses anterior wall recurrence was shown in figure 4. The patient is currently enrolled in a clinical trial without any distant metastasis.

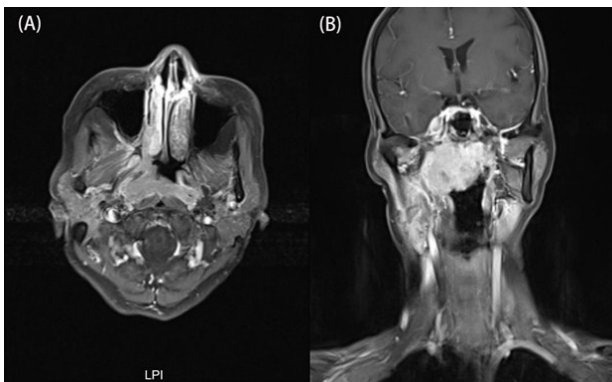


Figure 1. MR image before treatment showed irregular thickening of the nasopharyngeal walls on both sides and the parietal wall, extending to the right maxillary sinus lateral wall, right orbital apex. (A):T1-weighted Axial MRI image. (B):T1-weighted coronal MRI image.

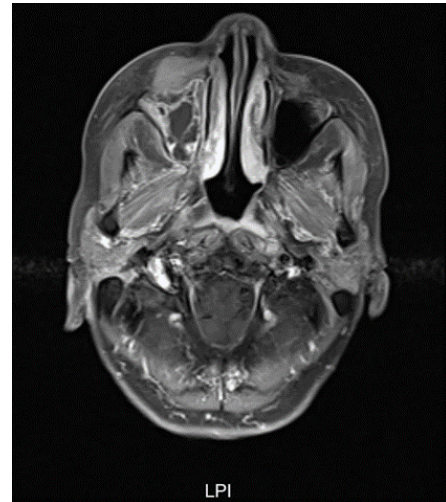


Figure 2. MR image showed maxillary sinuses anterior wall recurrence with a soft tissue mass in the anterior wall of the right maxillary sinus and bony destruction.

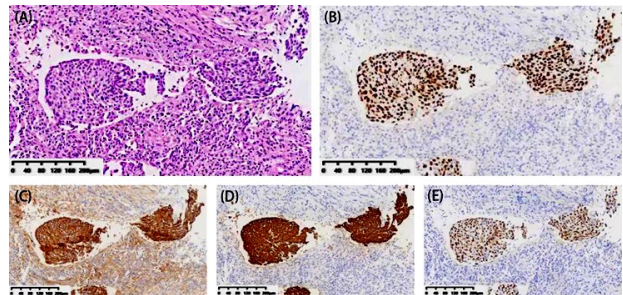


Figure 3. Representative hematoxylin and eosin staining (A), immunohistochemistry staining of P40 (B), CK5/6 (C), EGFR (D) and EBER (E) in the anterior wall of the right maxillary sinus biopsies.

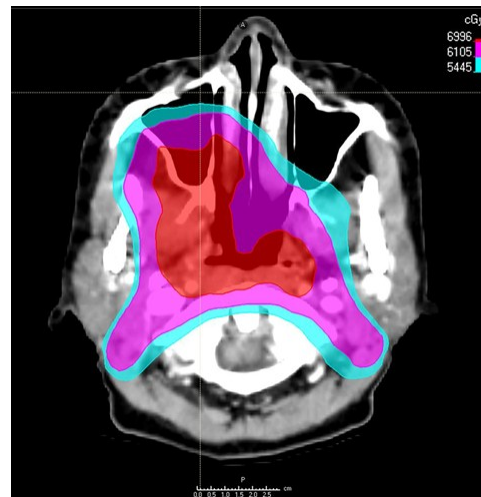


Figure 4. Dose distribution at the level of the maxillary sinuses anterior wall recurrence.

DISCUSSION

The anterior wall of the maxillary sinus is not a common site for recurrence after IMRT for NPC. Recurrence at the Maxillary sinus anterior wall needs to be differentiated from a secondary primary malignancy. Although IMRT has become the standard radiotherapy technique for NPC, radiation-associated malignancy should raise concern for its large volume of low-dose radiation and high number of monitor units⁽⁹⁾. For patients with NPC after IMRT, the median latency from the first day of IMRT to diagnosis of secondary primary malignancies was 37 months (range, 6 to 102 months)⁽¹⁰⁾. Study suggests radiation is a major factor in the development of second primary tumors in those NPC survivors⁽⁹⁾. The patient presented with a mass in the anterior wall of the right maxillary sinus 7 months after IMRT. Recurrence was confirmed by hematoxylin-eosin staining and immunohistochemistry (figure 3). This is the first reported case of recurrence and formation of lump in the anterior wall of the maxillary sinus after IMRT for NPC.

Radiation dose is positively correlated with local control rates and lower doses may lead to local recurrence of NPC⁽¹¹⁾. Radiation dose of at least 66.5Gy to the target volume was recommended for NPC to reduce the local failure rate⁽¹²⁾. At the time of this patient's initial visit, tumor involving the orbital apex and the lateral wall of the maxillary sinus. The dose to the anterior wall of the maxillary sinus was low due to dose limitation of the eye. The anterior maxillary sinus wall recurrence may be associated with low-dose radiotherapy (figure 4).

In the international guideline of NPC, the concept of "5+5 mm expansion" margin from the Gross Tumor Volume (GTV) to delineate the clinical target volume (CTV) was recommended⁽¹³⁾. However, the "5+5" recommendation of GTV expansion was extrapolated from pathological evidence of microscopic spread observed in other head and neck squamous cell carcinomas, which did not share exactly the same biological behavior as NPC^(13,14). In addition, the whole-organ histopathology of recurrent NPC indicated that MRI tended to underestimate the transverse and longitudinal length of the tumor⁽¹⁵⁾. The tumor involved the lateral wall of the maxillary sinus and there was a possibility of subclinical lesions in the anterior wall of the maxillary sinus. In certain contexts, subclinical lesions may be omitted according to the "5 + 5" recommendation.

For the recurrence in the parotid region after IMRT for NPC, the high risk factors for parotid lymph node metastasis (PLNM) were explored and preservation of the parotid gland was not recommended for radiotherapy in patients at high risk of PLNM⁽¹⁶⁾. Therefore, screening for high-risk factors for maxillary sinus recurrence is an important direction for future research.

In conclusion, Recurrence in the anterior wall of the maxillary sinus for NPC after IMRT was rare. Although the mechanism of maxillary sinus anterior wall recurrence is not fully understood, this case serves as a reminder to clinicians for future clinical decisions.

ACKNOWLEDGMENTS

None.

Funding: This work was supported by grants from the Medical and Health Research Project of Zhejiang Province (No. 2022KY079, 2023KY575).

Conflicts of interest: All authors declare that they have no conflict of interest.

Ethical considerations: Written informed consent was obtained from the patient for presentation of relevant data in this report.

Authors' contributions: Conception and design: C.C.; data collection: Y.F. and L.W.; drafting of the article: Y.F.; revising the article: C.C. and X.C. All of the authors have read and agreed to the published version of the manuscript.

REFERENCES

1. Chen YP, Chan ATC, Le QT, et al. (2019) Nasopharyngeal carcinoma. *Lancet*, **394**(10192): 64-80.
2. Tang LL, Chen YP, Chen CB, et al. (2021) The Chinese Society of Clinical Oncology (CSCO) clinical guidelines for the diagnosis and treatment of nasopharyngeal carcinoma. *Cancer Commun (Lond)*, **41**(11): 1195-227.
3. Sun XS, Li XY, Chen QY, Tang LQ, Mai HQ (2019) Future of radiotherapy in nasopharyngeal carcinoma. *Br J Radiol*, **92**(1102): 20190209.
4. Kong L, Wang L, Shen C, et al. (2016) Salvage intensity-modulated radiation therapy (IMRT) for locally recurrent nasopharyngeal cancer after definitive IMRT: A novel scenario of the modern era. *Sci Rep*, **6**: 32883.
5. Dawson LA, Anzai Y, Marsh L, et al. (2000) Patterns of local-regional recurrence following parotid-sparing conformal and segmental intensity-modulated radiotherapy for head and neck cancer. *Int J Radiat Oncol Biol Phys*, **46**(5): 1117-26.
6. Zhang X, Luo J, Gao L, Xu G (2011) Mastoid recurrence after radiotherapy for nasopharyngeal carcinoma: two case studies. *Head Neck*, **33**(10): 1535-8.
7. Autorino R, Micciché F, Dinapoli N, et al. (2012) Recurrence in region of spared parotid gland in patient receiving definitive intensity-modulated radiotherapy for nasopharyngeal cancer: a case report. *Acta Oncol*, **51**(8): 1095-9.
8. Cao CN, Luo JW, Gao L, et al. (2013) Clinical characteristics and patterns of failure in the parotid region after intensity-modulated radiotherapy for nasopharyngeal carcinoma. *Oral Oncol*, **49**(6): 611-4.
9. Chow JCH, Tam AHP, Cheung KM, et al. (2020) Second primary cancer after intensity-modulated radiotherapy for nasopharyngeal carcinoma: A territory-wide study by HKNPCSG. *Oral Oncology*, **111**: 105012.
10. Zhang LL, Li GH, Li YY, et al. (2019) Risk assessment of secondary primary malignancies in nasopharyngeal carcinoma: a big-data intelligence platform-based analysis of 6,377 long-term survivors from an endemic area treated with intensity-modulated radiation therapy during 2003-2013. *Cancer Res Treat*, **51**(3): 982-91.
11. Ng WT, Lee MC, Chang AT, et al. (2014) The impact of dosimetric inadequacy on treatment outcome of nasopharyngeal carcinoma with IMRT. *Oral Oncol*, **50**(5): 506-12.
12. Ng WT, Lee MC, Hung WM, et al. (2011) Clinical outcomes and patterns of failure after intensity-modulated radiotherapy for nasopharyngeal carcinoma. *Int J Radiat Oncol Biol Phys*, **79**(2): 420-8.

13. Lee AW, Ng WT, Pan JJ, *et al.* (2018) International guideline for the delineation of the clinical target volumes (CTV) for nasopharyngeal carcinoma. *Radiother Oncol*, **126**(1): 25-36.
14. Ng WT, Chow JCH, Beitler JJ, *et al.* (2022) Current radiotherapy considerations for nasopharyngeal carcinoma. *Cancers (Basel)*, **14**(23): 5773.
15. Chan JY, Wong ST, Wei WI (2014) Whole-organ histopathological study of recurrent nasopharyngeal carcinoma. *Laryngoscope*, **124**(2): 446-50.
16. Wang HZ, Cao CN, Luo JW, *et al.* (2016) High-risk factors of parotid lymph node metastasis in nasopharyngeal carcinoma: a case-control study. *Radiat Oncol*, **11**(1): 113.