

# Temozolomide Overdose in Treating High-Grade Glioma: A Case Report

A. Ebrahimi<sup>1</sup>, D. Khoramian<sup>2\*</sup>, N. Tabatabaei<sup>1</sup>, S. Sarvzadeh<sup>2</sup>

<sup>1</sup>The Advocate Center for Clinical Research, Ayatollah Yasrebi Hospital, Kashan, Iran

<sup>2</sup>Department of Medical Physics, The Advocate Center for Clinical Research, Ayatollah Yasrebi Hospital, Kashan, Iran

## ► Case report

### \*Corresponding author:

Daryoush Khoramian,

### E-mail:

daryoushkhormian@gmail.com

Received: October 2023

Final revised: January 2024

Accepted: January 2024

*Int. J. Radiat. Res.*, July 2024;  
22(3): 807-809

DOI: 10.61186/ijrr.22.3.807

**Keywords:** Medication errors, Temozolomide, Chemotherapy Overdose, High-Grade Glioma.

## ABSTRACT

Here, we report a non-smoker, a 38-year-old male patient with High-Grade Glioma (HGG). The patient with the initial signs of swelling of his left arm and leg and dizziness without any nausea and vomiting and other neurological symptoms was referred to a neurosurgeon and then underwent Magnetic Resonance Imaging (MRI). The MRI showed the enhancement in T1 and T2 and flair. The radiologist suggested a tumor probably, HGG. The patient was treated with external beam radiation therapy (EBRT) with a total dose of 54 Gy in 27 fractions combined with the Temozolomide (TMZ) regime (75 mg/m<sup>2</sup>/day). The patient was prescribed 140 mg TMZ per day. By mistake, the patient received a 280 mg drug dose daily for 29 days. Due to this miscalculation, he was hospitalized and recovered for one month. After 30 months he is alive and is free of progression according to the MRI.

## INTRODUCTION

Brain and nervous system cancers accounted for about 1.6 percent of all malignancies, worldwide. According to GLOBOCAN (2018), the number of new cases of Brain and nervous system tumors was more than 296,000 cases in 2018. The mortality is more than 241,000 people per year (2.5 percent of all sites). Brain tumors are more common among men than women. The age-standardized incidence rates (ASIRs) are 3.8 and 3.1 in males and females, respectively. Also, the age-standardized mortality rates (ASMRs) are higher in men than women (3.2 and 2.3, respectively) <sup>(1)</sup>.

Gliomas are one of the most common primary brain tumors that are diagnosed by medical centers. It accounted for 32 percent of all primary brain tumors <sup>(2)</sup>. Just in the US, about 70 percent of malignant primary brain tumors are malignant gliomas <sup>(3)</sup>. Unfortunately, patients with malignant gliomas show poor prognosis with a median survival of 15 months <sup>(4)</sup>. The main therapeutic approaches for treating gliomas are surgery, chemotherapy, and radiation therapy (RT). However, various studies have shown that a specific combination of those treatments can improve the control of disease progression <sup>(5)</sup>. It has been shown that the combination of RT and TMZ (RT+TMZ) can increase the overall survival of HGG patients (2011). Therefore the use of TMZ has become a key role in

HGG <sup>(6)</sup>.

In addition to the clinical benefits of TMZ, its use has benefits for patients. The TMZ is taken orally and there is no need for hospitalization. Despite the benefits of its simplicity of use, delegating responsibility for the correct use of the drug to the patient or his/her caregivers can increase the probability of medication errors and toxicities <sup>(7)</sup>. Letarte *et al.* <sup>(8)</sup> analyzed the TMZ medication errors from 1997 to 2012 (45 cases). They reported that the most common errors are patient or caregiver accounting for 47 % of errors. Those errors were accidental overdose, intentional overdose, wrong duration of treatment, and wrong method of administration. Accordingly, human errors play an important role in medication errors. Here we report a medication error in a 38-year-old patient with HGG with prolonged survival after a TMZ overdose which has never been reported.

### Case representation

Here we present a non-smoker 38-year-old male patient. The patient was a member of a big textile factory with symptoms of headache and gaiting problems. The patient with the initial signs of swelling of the arm and left leg and dizziness without symptoms of nausea and vomiting and other neurological symptoms are referred to a neurologist and undergoes MRI.

The MRI was taken and revealed the enhancement

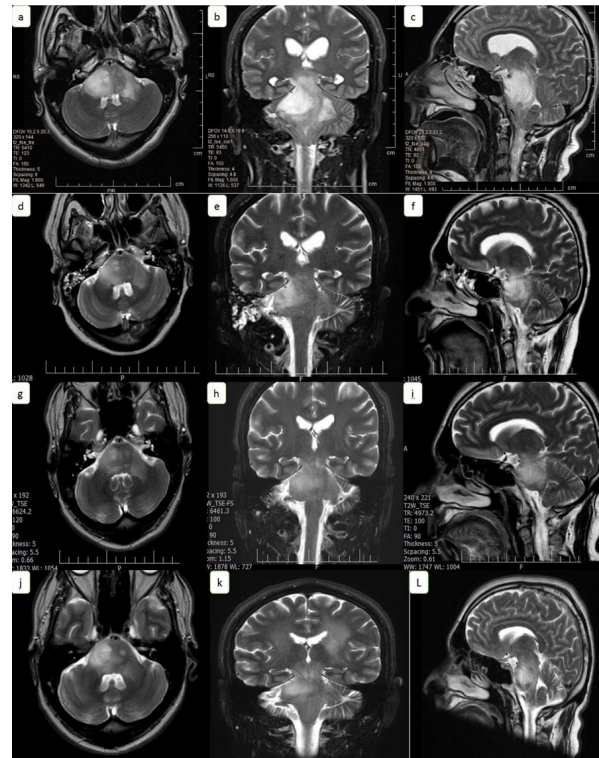
in T1 and T2 and flair. The radiologist suggested a high-grade glioma. The tumor size was 33.5×56.7×40.5 mm<sup>2</sup> located in the mid-brain and pons region. The biopsy was not taken due to the sensitive location of the tumor. The patient's family history was unremarkable. It does not mention any disease and has no previous history of seizures or radiation. The patient had been referred to the radiotherapy center by a neurosurgeon.

Our radiation oncologist decided to treat the patient with concurrent RT with TMZ with an expectancy of HGG. He was treated with EBRT (on Siemens Primus linear accelerator) with a total dose of 54 Gy in 27 fractions combined with the TMZ (AMITZO) regime, 75 mg/m<sup>2</sup>/day. Treatment plan was carried out by medical physicist on Isogray treatment planning system (TPS) (Dosisoft company). Treatment plan included two opposed-lateral beam with gantry angle of 90 and 270 degrees and a non-coplanar beam to cover planning target volume (PTV) by 95 percent of prescription does, besides avoiding critical organ at risks (OARs) including brain stem, chiasma, optic nerve, and eye globe. The TMZ capsules are available in five different forms: 5, 20, 100, 140, and 250 mg. Because the patient was not completely conscious, the caregiver was given instructions on how to use the drug. The patient was ordered to use 140 mg TMZ per day. By mistake, the patient received a 280 mg drug dose daily for 29 days. The first use of TMZ (date) was the 4<sup>th</sup> (2020/08/26) day of radiotherapy treatment. During the treatment course, CBC got three times and the results were normal. The patient was healthy until the 26<sup>th</sup> day and his CBC tests were normal. According to the nurse's report, the patient came in a wheelchair and had epistaxis, on the 33rd day. According to the patient-caregiver, he took two doses of 140 mg of TMZ daily. The patient's treatment was stopped due to the overdose of the TMZ and the patient was hospitalized.

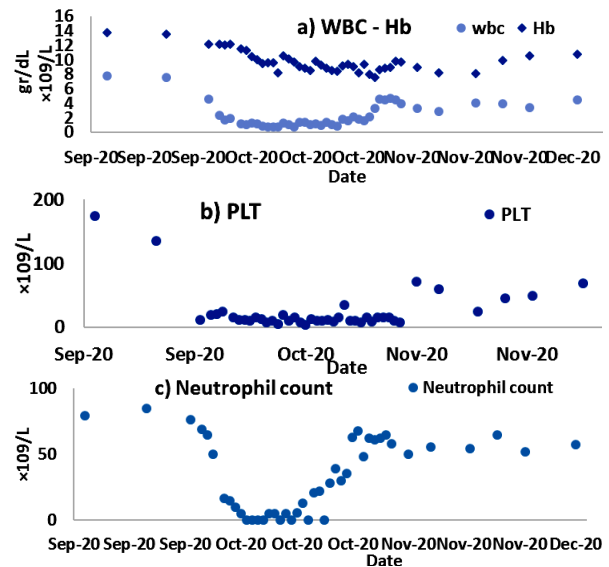
On the first day of hospitalization, October 5, 2020, the WBC, Hb, PLT, and neutrophil count were 1.3 (×10<sup>9</sup>/L), 10.4 (gr/dL), 12 (×10<sup>9</sup> /L) and 10 (×10<sup>9</sup> /L), respectively. During 32 days of hospitalization, the WBC ranged between 0.8 to 4.7 (×10<sup>9</sup>/L), the Hb ranged between 7.6 to 10.5 (gr/dL), the PLT ranged between 4 to 72 (×10<sup>9</sup> /L) and the neutrophil count ranged between 5 to 67.8 (×10<sup>9</sup>/L).

The patient received Filgrastim 300 mg/0.5 mL two times a day and Erythropoietin 4000 units/mL eight times during 32 days of hospitalization. Also, the patient was supported with 28 units of PLT and supported with nine units of blood products. The variations in the WBC, Hb, PLT, and neutrophil count are presented in figure 1. He was discharged four weeks later when the PLT count was raised to 72 (×10<sup>9</sup> /L). Notably he gets infected with the Covid-19 virus during his hospitalization. After discharge, three MRIs were taken 2, 7, and 15 months after the

end of the treatment. He was free of recurrence according to MRI assessments.



**Figure 1.** a, b, and c respectively, the axial, coronal, and sagittal view of Magnetic Resonance Imaging (MRI) before treatment, d, e, and f, 2 months after the overdose, g, h, and i, 7 months after the end of the radiotherapy, j, k, and L, 15 months after the end of the radiotherapy.



**Figure 2.** From the top to bottom: the a) WBC-Hb, b) PLT, and c) Neutrophil count

### DISCUSSION

The patient is progression-free according to MRI assessments after about 30 months by the end of the overdose of the TMZ. His Karnofsky performance score is 90% at the time of manuscript writing.

The excessive dosage of the TMZ is reported by the Spence *et al.* (9). They reported a 53-year-old man with glioblastoma multiform (GBM). After subtotal resection of his tumor, he was treated with conventional RT (59.4 Gy, 1.8 Gy per fraction) followed by the TMZ. By mistake, the patient received 5500 mg/m<sup>2</sup> of the TMZ, about 2.8 times the standard dose over 2 days. After the accident, he was admitted to the University of Washington Medical Center. He was supported with GCSF 480 µg/day for 23 days, 10 transfusions, 6 units each, from day 10-26, Erythropoietin 10,000 units three times weekly, 2 transfusions day 17 and 21, and erythropoietin 40,000 units weekly for 8 weeks. After four months he received TMZ 50 mg/day orally. His WBC dropped to 2.2 (×10<sup>9</sup>/L) and neutrophils to 0.9 (×10<sup>9</sup>/L). He recovered over four weeks and survived about 24 months which about 22 months were progression-free survival. According to the patient's outcome, they recommended that the dose escalation of the TMZ up to 2800 mg/m<sup>2</sup> or more combined with hematopoietic stem cell rescue may be sensible.

## CONCLUSION

Our data suggest the use of more doses of TMZ for HGG patients. Further investigations are needed to confirm this point. Also, the side effects of an overdose with TMZ should be considered.

## ACKNOWLEDGMENTS

The authors would like to thank the Advocate Center for Clinical Research, Ayatollah Yasrebi Hospital, Kashan, Iran.

**Financial support:** No funding sources.

**Conflicts of interest:** The authors have no conflicts of interest to declare.

**Ethical Approval:** The ethical committee of our hospital declared that due to the retrospective nature of the study it could waived to informed consent and did not required institutional approval.

**Author contribution:** A.E., and D.K., study design; A.E., D.K., N.T., M.S., data collection and data analysis; D.K. and S.S., writing of original draft and editing manuscript.

## REFERENCES

1. Bray F, Ferlay J, Soerjomataram I, Siegel RL, Torre LA, Jemal A (2018) Global cancer statistics 2018: GLOBOCAN estimates of incidence and mortality worldwide for 36 cancers in 185 countries. *CA: a Cancer Journal for Clinicians*, **68**(6): 394-424.
2. Hadziahmetovic M, Shirai K, Chakravarti A (2011) Recent advancements in multimodality treatment of gliomas. *Future Oncology*, **7**(10): 1169-83.
3. Ahmed R, Oborski MJ, Hwang M, Lieberman FS, Mountz JM (2014) Malignant gliomas: current perspectives in diagnosis, treatment, and early response assessment using advanced quantitative imaging methods. *Cancer Management Research*, **6**: 149.
4. Parvez K, Parvez A, Zadeh G (2014) The diagnosis and treatment of pseudoprogression, radiation necrosis and brain tumor recurrence. *Int J Mol Sci*, **15**(7): 11832-46.
5. Chowdhary MM, Ene CI, Silbergeld DL (2015) Treatment of Gliomas: How did we get here? *Sur Neuro Int*, **6**(Suppl 1): S85.
6. Raizer J, Parsa A. Current understanding and treatment of gliomas: Springer; 2015.
7. Paolieri F, Sbrana A, Bloise F, Biasco E, Galli L (2018) Do We Need to Improve Oral Chemotherapy Adherence Monitoring? A Case Report of Temozolomide Overdose. *Int J Case Rep*, **2**(1): 2.
8. Letarte N, Gabay MP, Bressler LR, Long KE, Stachnik JM, Villano JL (2014) Analyzing temozolomide medication errors: potentially fatal. *Journal of Neuro-Oncology*, **120**(1): 111-5.
9. Spence AM, Kiem H-P, Partap S, Schuetz S, Silber JR, Peterson RA (2006) Complications of a temozolomide overdose: a case report. *Journal of Neuro-Oncology*, **80**: 57-61.

