

Effectiveness of levonorgestrel-based intrauterine insemination system therapy combined with hysteroscopic electrosurgery and radiotherapy in the treatment of highly differentiated endometrial cancer

P. Lian^{1#}, H. Xu^{2#}, S. Liu³, H. Qian^{4*}

¹Department of Nursing College of Changsha Health Vocational College, Changsha, Hunan 410600, China

²Department of Oncology, Ezhou Central Hospital, Ezhou, Hubei 436000, China

³Department of clinical nutrition, Ezhou Central Hospital, Ezhou, Hubei 436000, China

⁴Department of Gynecology, Hubei Geological Hospital, Wuhan, Hubei 430000, China

ABSTRACT

► Original article

*Corresponding author:

Hong Qian, M.D.,

E-mail:

medicalsciences.paper@gmail.com

Received: November 2023

Final revised: May 2024

Accepted: May 2024

Int. J. Radiat. Res., April 2025;
23(2): 329-334

DOI: 10.61186/ijrr.23.2.329

Keywords: Endometrial cancer, levonorgestrel intrauterine contraceptive system, hysteroscopic electrocution, fertility function, radiotherapy.

#These authors contributed equally to this work.

Background: Exploring the efficacy of levonorgestrel intrauterine contraceptive system combined with hysteroscopic resection for the treatment of early and highly differentiated endometrial cancer in young patients and its impact on reproductive function. **Materials and Methods:** According to the grouping method, the patients were divided into a single hysteroscopy group and a combined progesterone group, with 77 patients in each group. Among them, the single hysteroscopy group received hysteroscopic resection surgery, while the combined progesterone group received levonorgestrel intrauterine contraceptive system treatment on hysteroscopic resection surgery beside radiation. **Results:** After treatment, endometrial thickness, uterine volume and myoma volume were lower in the combined treatment group than in the intrauterine sustained release group ($P < 0.05$); after treatment, estradiol, FSH and progesterone levels were lower in the combined treatment group compared with the intrauterine sustained release group ($P < 0.05$); after treatment, Hb and VEGF levels were lower in the combined treatment group compared with the intrauterine sustained release group ($P < 0.05$); after treatment, compared with the intrauterine sustained release group, Hb and VEGF levels were lower in the combined treatment group ($P < 0.05$); Compared with the intrauterine sustained release group, the dysmenorrhea score and CA125 expression level in the combined treatment group were lower ($P < 0.05$); compared with the intrauterine sustained release group, the effective rate of the combined treatment group was higher ($P < 0.05$). **Conclusion:** The application of mifepristone combined with levonorgestrel intrauterine sustained release system in the treatment of patients with uterine fibroids can effectively improve the symptoms of patients, alleviate clinical symptoms, alleviate dysmenorrhea, effectively inhibit the further development of the disease, reduce the expression level of CA125, improve the prognosis of patients, and have a significant therapeutic effect.

INTRODUCTION

Endometrial cancer, as one of the more common gynecological tumors in clinical practice, has a high incidence rate, and it is mostly found in postmenopausal women. However, with the change of social life style, the incidence of endometrial cancer is becoming younger. When patients are younger than 40 years old, who are in their childbearing years and have a strong desire to have children, how to preserve reproductive function is an important issue to be faced ⁽¹⁾. Total hysterectomy and bilateral adnexectomy is a standard treatment for endometrial cancer, but it is not suitable for young women with fertility desire ⁽²⁾. Hysteroscopic

electrosurgery and radiotherapy is a minimally invasive procedure with less trauma and lower impact on the patient, while preserving the patient's reproductive function ⁽³⁾. Relevant studies have shown that the treatment of endometrial cancer patients at an early stage through progesterone-assisted electrosurgery and radiotherapy can help to shorten the postoperative time and have a better prognosis ⁽⁴⁾. Based on this, in this paper we carried out levonorgestrel intrauterine sterilization system treatment combined with hysteroscopic electrosurgery and radiotherapy for young patients with early stage highly differentiated endometrial cancer. Then, we analyzed its effects on patients' therapeutic efficacy and reproductive function to

provide a basis for comprehensive clinical promotion.

MATERIALS AND METHODS

General information

Research subjects: 144 cases of endometrial cancer patients who received treatment in our hospital from September 2022 to September 2023 were selected. According to the grouping method, the patients were divided into single hysteroscopy group and combined progesterone group, each with 77 cases. The patients in the single hysteroscopy group were aged 35-39 years with a mean age of (36.5 ± 3.0) years, and the patients in the combined progesterone group were aged 35-38 years with a mean age of (35.8 ± 4.2) years. There was no statistically significant difference in the general information of the study subjects between the two groups ($P > 0.05$) with comparability. All study subjects and their families gave informed consent to this study, which was approved by the Ethics Committee of our hospital.

Inclusion criteria: ① age less than 40 years old; ② fertility requirements; ③ hysteroscopy and segmental diagnostic scraping pathology, determined as endometrioid adenocarcinoma G1; ④ MRI examination, suggesting that the lesion limited to the endometrium; ⑤ no contraindications to drug treatment or pregnancy; ⑥ after adequate communication, the patient understood that preservation of fertility was not the standard treatment mode of endometrial cancer.

Exclusion criteria: ① combined with malignant lesions of endometrium or cervix; ② incomplete data; ③ other organic lesions; ④ serious heart, liver, kidney and hematopoietic system and psychiatric diseases; ⑤ combined with serious bacterial and viral infections; ⑥ those who may be resistant to the means or drugs used in this study.

Treatment methods

Both groups of patients were treated with hysteroscopic electrosurgery and radiotherapy. First of all, general anesthesia was applied to the patients. Then, a No. 10 to No. 12 dilatation rod was chosen to dilate the uterus. When the pressure in the uterine cavity reached 70 mmHg, glycine solution with a concentration of 1.5% was taken and injected into the uterus. After it was completely filled, a 10.0 mm electrosurgical scope was introduced into the uterus. Subsequently, a 5.0-mm electrocutting ring was used, and the output power was adjusted to 100 w to cut the lesion area, and the superficial muscle layer 2.0-3.0 mm below the lesion was also removed. After the operation, oral medroxyprogesterone, purchased from Zhejiang Xianju Pharmaceutical Co., Ltd, with the national drug authorization code H20123089, was administered at 160 mg/d, once/d, for a total of

6 months. In the combined progesterone group, levonorgestrel intrauterine insemination system was placed in the patient's uterine cavity at 1 week after surgery, totaling 52 mg. The trade name was Mannitol, which was purchased from Bayer Healthcare, Germany, model J20090144. The daily release of the drug was 20 µg, which was performed strictly according to the guidelines by a professional gynecologist in our hospital.

Observation indexes

The clinical efficacy of the two groups of patients was compared. The evaluation criteria of efficacy were as follows: complete remission meant that the tumor foci basically disappeared and no cancerous tissues were found in the clinical examination; partial remission meant that atypical hyperplasia existed in the post-treatment review; and ineffective meant that the foci still existed lesions in the post-treatment review. The total effective rate of treatment = (number of cases in complete remission + number of cases in partial remission)/total number of cases $\times 100\%$.

In both groups, 5 ml of venous blood was withdrawn in the early morning on an empty stomach and centrifuged. Firstly, the venous blood was stored in an anticoagulation tube, and then the anticoagulation tube was placed in a centrifuge with a rotational speed of 3000 r/min and centrifuged for 10 min. The upper layer of serum was separated and stored at -30° for use. The estradiol and FSH levels before and after treatment were detected by Beckman Access chemiluminescence instrument, which was purchased from Beckman. The Hb level of the two groups of patients before and after treatment was detected by applying fully automatic routine blood detector, and the detection instrument was dxh600 fully automatic routine detector. The serum CA125 level of the two groups was detected by γ radioimmunoassay counter with radioimmunoassay, and the instrument was purchased from Anhui Zhongke Zhongjia Scientific Instrument Co.

The VAS visual analog scoring method⁽⁵⁾ was applied to evaluate the patients' pain at 1 week after surgery and 1 month after surgery. Symptom scores were from 0 to 10, which were filled out according to the patients' own actual conditions. When the score was higher, it indicated that the patient's pain symptoms were more severe. Both groups of patients were tested and recorded before and after treatment by physicians with more than seven years of high seniority in our hospital for comparison. We recorded the re-pregnancy of patients in both groups, including successful conception within 1 year after treatment and pregnancy outcome.

Statistical treatment

SPSS21.0 software was used for analysis. Comparison of measurement data was analyzed by

repeated measures data ANOVA, and the comparison between two groups was carried out by independent t-test, with a P value of <0.05 indicating a statistically significant criterion.

RESULTS

Comparison of estradiol and FSH levels

As shown in figure 1, there is no statistically significant difference in the comparison of estradiol and FSH levels between the two groups before treatment ($P>0.05$). After treatment, compared with the single hysteroscopy group, estradiol and FSH levels were lower in the combined progesterone group, with statistical differences ($P<0.05$).

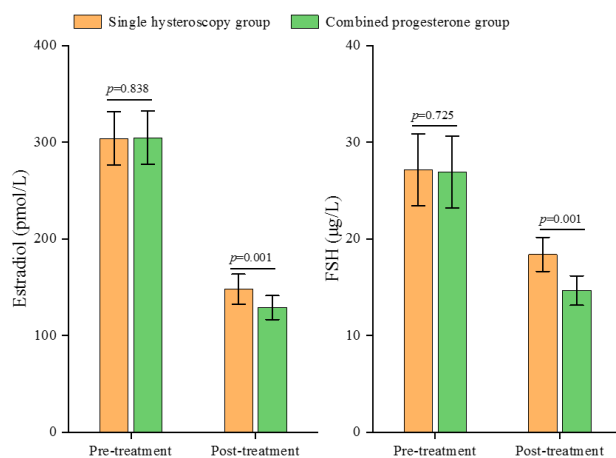


Figure 1. The levels of estradiol and FSH between the two groups before and after treatment.

Comparison of Hb and VEGF levels

As shown in figure 2, the Hb and VEGF levels of the two groups were compared before treatment, and there was no statistical difference ($P>0.05$). After treatment, compared with the single hysteroscopy group, the Hb level was higher and VEGF level was lower in the combined progesterone group, which was statistically different ($P<0.05$).

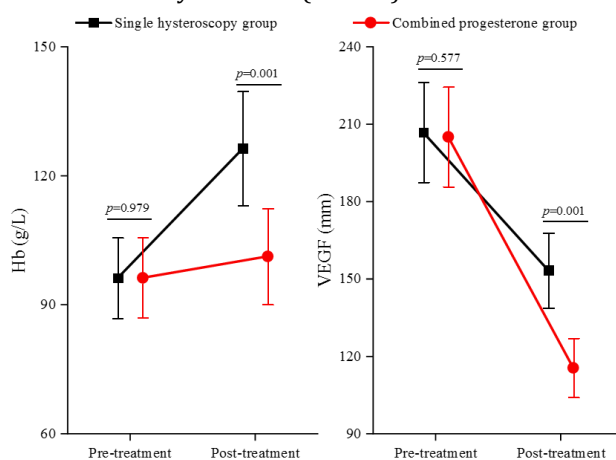


Figure 2. The levels Hb and VEGF of the two groups.

Comparison of VAS score and CA125 expression level

As shown in table 1, before treatment, VAS score and CA125 expression level were compared between the two groups, with no statistical difference ($P>0.05$). After treatment, VAS scores and CA125 expression levels were lower in the combined progesterone group compared with the single hysteroscopy group, with statistical differences ($P<0.05$).

Comparison of repeat pregnancies

As shown in table 2, comparing the postoperative successful conception rate between the two groups, the postoperative successful conception rate in the single hysteroscopy group was lower than that in the combined progesterone group, with a statistical difference ($P<0.05$). Comparing the pregnancy outcomes between the two groups, the full-term birth rate in the single hysteroscopy group was lower than that in the combined progesterone group, with a statistical difference ($P<0.05$).

Comparison of treatment effective rate

As shown in figure 3, the treatment effective rates of the two groups were compared. The treatment effective rate of the combined progesterone group was higher compared with that of the single hysteroscopy group, which was statistically different ($P<0.05$).

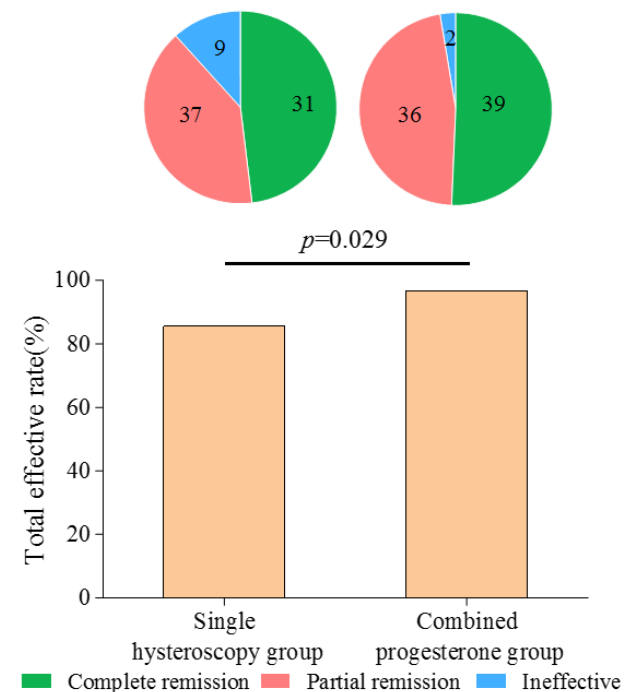


Figure 3. Comparison of the treatment effective rates the combined progesterone group with that of the single hysteroscopy group.

Table 1. Comparison of VAS score and CA125 expression level before and after treatment in two groups of patients ($\bar{x} \pm s$).

Groups	Number of cases (n)	VAS scores (points)		CA125 (KU/L)	
		Pre-treatment	Post-treatment	Pre-treatment	Post-treatment
Single hysteroscopy group	77	6.31 \pm 0.73	2.39 \pm 0.25	41.86 \pm 5.32	36.37 \pm 2.42
Combined progesterone group	77	6.33 \pm 0.72	1.23 \pm 0.16	42.12 \pm 5.29	29.64 \pm 1.43
<i>t</i>		0.171	34.290	0.304	21.009
<i>P</i>		0.964	0.001	0.761	0.001

Table 2. Comparison of re-pregnancy in two groups of patients.

Groups	Number of cases (n)	Successful postoperative conception rate	Pregnancy outcome		
			Full-term labor	Premature labor	Miscarriage
Single hysteroscopy group	77	44/77	25 (56.82)	11 (25.00)	8 (18.18)
Combined progesterone group	77	64/77	50 (78.12)	12 (18.75)	2 (3.13)
<i>x²</i>		12.399	7.036		
<i>P</i>		0.001	0.008		

DISCUSSION

With the development of society, most young endometrial cancer patients have not yet given birth under the delayed age of marriage and childbearing. Therefore, this has led to a higher demand for the treatment of endometrial cancer, that is, the preservation of the patient's reproductive function ⁽²⁾. Most endometrial cancers that occur in young patients are highly differentiated and early stage cases, basically type I endometrial cancer. Therefore, there exists a theoretical basis for treatment that preserves fertility ⁽⁶⁾. Due to the existence of invisibility, the main means of treatment at the time of discovery is already surgery. At present, the clinical treatment of endometrial cancer is mostly applied to hysteroscopic electrosurgery and radiotherapy, which can not only reduce the postoperative recovery time, but also will not cause damage to the patient's uterus. There exists the premise of preserving the patient's reproductive function ^(7,8).

Hysteroscopic electrosurgery and radiotherapy is a minimally invasive technique that can accurately reach the lesion when performing endometrial cancer lesion removal. The operator can remove the lesion site with the help of hysteroscope. By implementing electrocoagulation for hemostasis, it helps to reduce the amount of intraoperative bleeding, shortens the operation time, and facilitates postoperative recovery ⁽⁹⁾. Relevant studies have shown that in the treatment of early endometrial cancer (confined to the mucosa, without obvious myometrial invasion) and complex atypical hyperplasia, the preservation of reproductive function through high-efficiency progesterone, oral contraceptive pills, tamoxifen and other drugs can achieve certain results ⁽¹⁰⁾.

Hysteroscopic electrosurgical treatment method has more advantages, mainly including the ability to directly view the specific uterine cavity situation and the specific cervical canal situation. So that the operator can obtain accurate tumor lesion information, cervical canal with or without

involvement information ⁽¹¹⁾. However, hysteroscopic electrosurgery and radiotherapy alone cannot better regulate hormone levels in endometrial cancer patients ⁽¹²⁾. As a new intrauterine contraceptive system, the levonorgestrel intrauterine sterilization system contains 52 mg of levonorgestrel in its pill compartment, which acts after placement in the uterus via a slow-release system that is able to achieve a stable, slow, and low-dose release of levonorgestrel ⁽¹³⁾. Levonorgestrel is a type of progestin, characterized by inhibiting estrogen activity and reducing estrogen receptors in the lesion. In turn, this is done to attenuate the sensitivity between the endometrium and estrogen and inhibit endometrial proliferation ⁽¹⁴⁾. The results of this paper showed that the treatment of young patients with early stage highly differentiated endometrial cancer by levonorgestrel intrauterine sterilization system combined with hysteroscopic electrosurgery and radiotherapy had a higher effective rate compared with hysteroscopic electrosurgery and radiotherapy alone. Analyzing the reasons, it is possible that the combination of levonorgestrel intrauterine sterilization system with hysteroscopic electrodesiccation treatment exerts the inhibition of endometrial proliferation, which in turn promotes the atrophy of endometrial glands and accelerates the necrosis and degeneration of their lesions.

In endometrial cancer, the levels of estradiol and FSH are significantly higher than those of normal muscle tissue. Estradiol and FSH levels are closely associated with the development of uterine fibroids. Elevated estradiol levels can stimulate the growth of uterine smooth muscle cells. In concert with FSH, it is able to promote the secretion of estrogen from mature follicles, as well as the continued growth of the lesions ⁽¹⁵⁾. The results of this paper showed that estradiol and FSH levels were significantly reduced in young patients with early-stage highly differentiated endometrial cancer treated with levonorgestrel intrauterine device system combined with hysteroscopic electrosurgery and radiotherapy. It indicates that treatment by levonorgestrel intrauterine sterilization system combined with hysteroscopic electrosurgery and radiotherapy can

regulate the hormone levels of patients, effectively inhibit the growth of endometrium and regulate the menstrual situation.

Relevant studies have shown that changes in hemoglobin levels in gynecological tumor patients can affect the treatment effect about patients, and at the same time have a close correlation with the prognosis of gynecological tumor patients ⁽¹⁶⁾. Vaginal bleeding is often associated with endometrial cancer patients. When persistent vaginal bleeding occurs, there is a significant loss of blood, which in turn leads to lower hemoglobin levels. VEGF is involved in the development of many tumors and promotes endothelial cell division and proliferation, which accelerates the emergence of new blood vessels ⁽¹⁷⁾. Vascular proliferation is one of the important conditions for tumor development. Therefore, VEGF is a tumor-promoting growth factor that plays an important role in tumorigenesis and development ⁽¹⁸⁾. The results of this paper showed that Hb levels were elevated and VEGF levels were lower in young early stage highly differentiated endometrial cancer treated with levonorgestrel intrauterine system combined with hysteroscopic electrosurgery and radiotherapy, indicating that treatment with levonorgestrel intrauterine system combined with hysteroscopic electrosurgery and radiotherapy can improve the patient's prognosis and surgical effect.

Hysteroscopic electrosurgery and radiotherapy can preserve the patient's uterus. Precise operation can be performed under hysteroscopy, which can accurately identify and directly resect the lesions without causing damage to the uterus and normal tissues, and reduce the pain of patients to a certain extent ⁽¹⁹⁾. CA125 is not only a specific marker for ovarian cancer, but also shows high expression in patients with endometrial cancer and cervical cancer, and there is a certain relationship between serum CA125 level and disease progression. Therefore, it can be used for disease detection and efficacy assessment of endometrial cancer ⁽²⁰⁾. The results of this study showed that VAS score and CA125 level were significantly reduced in young patients with early stage highly differentiated endometrial cancer treated with levonorgestrel intrauterine system combined with hysteroscopic electrosurgery and radiotherapy, indicating that the treatment of levonorgestrel intrauterine system combined with hysteroscopic electrosurgery and radiotherapy can alleviate the pain of the patients and accelerate the apoptosis, thus preventing the tumor from invading and proliferating.

In young endometrial cancer patients, most of them are early, highly differentiated, endometrioid adenocarcinomas for which the possibility of a better prognosis exists. Therefore, there is a strong desire for preservation of fertility during treatment ⁽²¹⁾. Although hysteroscopic electrosurgery and

radiotherapy has a higher success rate in preserving fertility during the treatment of endometrial cancer, there is a risk of incomplete resection of the lesion and recurrence. If endometrial cancer patients are treated with high-dose progesterone alone for fertility preservation, the recurrence rate is higher, and the prognosis and pregnancy outcome cannot be effectively ensured ⁽²²⁾. Therefore, a strong combination of the two can ensure the therapeutic effect and prognosis while preserving fertility. The results of this study showed that the postoperative successful conception rate was higher in young patients with early stage highly differentiated endometrial cancer treated with levonorgestrel intrauterine system combined with hysteroscopic electrosurgery and radiotherapy, indicating that the treatment with levonorgestrel intrauterine system combined with hysteroscopic electrosurgery and radiotherapy can increase the successful conception rate and improve the pregnancy outcome.

In conclusion, the treatment of young patients with early stage highly differentiated endometrial cancer by levonorgestrel intrauterine insemination system combined with hysteroscopic electrodesiccation has a high surgical efficiency, accelerates apoptosis, and improves the patient's prognosis, increases the rate of successful conception and improves the pregnancy outcome.

ACKNOWLEDGMENT

None.

Declaration of interests: None to declare.

Fund support: Jiangsu Province maternal and child health project (Fund No.: F201839).

Ethical considerations: All study subjects and their families gave informed consent to this study, which was approved by the Ethics Committee of our hospital.

Author contributions: All authors were involved in all aspects of the research and preparation of the manuscript. All authors read and approved the final version of the manuscript.

Conflicts of interest: None declared.

REFERENCES

1. Lu YY, Yang F, Zheng Y (2021) Research progress and prospect on the application of sentinel lymph nodes in endometrial cancer. *Chinese Journal of Cancer*, **31**(10): 944-948.
2. Laganà AS, Franchi MP, Garzon S (2022) Conservative management of atypical endometrial hyperplasia and early endometrial cancer in childbearing age women. *Medicina (Kaunas)*, **58**(9): 1256.
3. Mo JS, Su BL, Liang XM, et al. (2019) Study on the efficacy and recurrence of hysteroscopic electrosurgery and radiotherapy combined with progesterone in the treatment of young patients with early progesterone receptor-positive endometrial cancer. *Chinese Journal of Practical Medicine*, **46**(12): 58-60.
4. Zhang YX, Duan GT, Meng P (2020) Observation on the efficacy of conservative hysteroscopic surgery combined with progestin in the treatment of early endometrial cancer. *Journal of Clinical and*

- Experimental Medicine*, **19**(12): 1339-1341.
5. Fu LY, Duan SY, Wan SZ (2008) Application of visual analog scoring method in patient satisfaction survey. *China Nursing Management*, **8**(9): 68-69.
 6. Li J, Wu S, Zhang Z (2022) Brusatol sensitizes endometrial hyperplasia and cancer to progestin by suppressing NRF2-TET1-AKR1C1-mediated progestin metabolism. *Lab Invest*, **102**(12): 1335-1345.
 7. Li AL, Hou QX, Lei WL (2020) Effect of hysteroscopic electrodesiccation combined with hormonal therapy for endometrial cancer on patients' serum PLGF level, disease progression and recurrence. *Journal of Practical Cancer*, **35**(9): 1449-1455.
 8. Ye XY (2021) Effect of mifepristone combined with hysteroscopic electrosurgery and radiotherapy on fertility function of endometrial cancer patients. *China Maternal and Child Health Care*, **36**(19): 4618-4620.
 9. Zhao YR, Xu YX, Zhou Y (2022) Effect of goserelin combined with hysteroscopic electrosurgery and radiotherapy on postoperative disease remission and recurrence in patients with early endometrial cancer. *China Drugs and Clinics*, **22**(4): 358-360.
 10. Li S, Yang JM, Sun L, et al. (2021) Clinical efficacy and conservation function of hysteroscopic laparoscopic surgery combined with high-efficiency progestin in the treatment of endometrial cancer patients. *Cancer Progress*, **19**(5): 519-529.
 11. Aizetz M (2017) Observation on therapeutic effect of hysteroscopic electrosurgery and radiotherapy with biochemical soup plus flavor in the treatment of early endometrial cancer. *Modern Journal of Integrative Chinese and Western Medicine*, **26**(2): 202-225.
 12. Liu SM, Meng B, Meng YG (2019) Meta-analysis of the efficacy of hysteroscopic electrodesiccation combined with mannuelle in the treatment of early endometrial cancer with preservation of reproductive function. *Journal of Guangxi Medical University*, **36**(6): 898-904.
 13. Ma Z, Tian CH, Yang MF, et al. (2021) Effects of miR-21 antagonist and levonorgestrel on proliferation and apoptosis of endometrial cancer Ishikawa cells. *Journal of Ningxia Medical University*, **43**(11): 1109-1124.
 14. Xiao XC, Zhou X, Wang YX (2021) Efficacy of gonadotropin-releasing hormone combined with levonorgestrel intrauterine system for the treatment of patients with early-stage highly differentiated endometrial cancer and the impact on pregnancy outcome. *Cancer Progress*, **19**(20): 2129-2144.
 15. Emons G and Gründker C (2021) The role of gonadotropin-releasing hormone (GnRH) in endometrial cancer. *Cells*, **10**(2): 292.
 16. Yang YF and Zhang J (2021) Observation on the safety of endometrial cancer staging surgery in patients with endometrial cancer after percutaneous coronary intervention with antiplatelet therapy. *Chinese Medicine*, **16**(6): 900-904.
 17. Guo YS, Feng RL, Weng YH, et al. (2018) Study on changes in serum VEGF and CRP levels and correlation in endometrial cancer patients with different clinical stages. *Journal of Chengdu Medical College*, **13**(1): 68-70, 105.
 18. Su LZ, Meng J, Jin J, et al. (2022) Expression of miR-155, HE4, and VEGF in endometrial cancer and its relationship with patient prognosis. *Laboratory Medicine and Clinics*, **19**(22): 3062-3068.
 19. Zhang X, Sang CM, Tian SX, et al. (2021) Effect of hysteroscopic electrosurgery and radiotherapy and drug treatment for focal early endometrial cancer. *Journal of Qingdao University*, **57**(1): 39-42.
 20. Li Y, Mu KK, Dong YH, et al. (2019) Study on the value of CEA, CA19-9, CA125, HE4 and menopausal ROMA value determination for clinical staging of endometrial cancer. *International Journal of Laboratory Medicine*, **40**(3): 304-307.
 21. Leombroni M, Dessole M, Lucidi A (2022) Reproductive and pregnancy outcomes of fertility-sparing treatments for early-stage endometrial cancer or atypical hyperplasia: A systematic review and meta-analysis. *Eur J Obstet Gynecol Reprod Biol*, **273**: 90-97.
 22. Dai J and Yang B (2021) Current status and problems of fertility preservation treatment for endometrial cancer. *Sichuan Medicine*, **42**(3): 313-317.