

Meta-analysis and literature review on MRI diagnosis of cartilage invasion in laryngeal neoplasms

Z.D. Wang[#], Y. Zhan[#], H. Cao, X.D. Shan, X.H. Tai^{*}

Department of Otolaryngology, The Air Force Hospital of the Northern Theater Command of the Chinese People's Liberation Army, Shenyang, Liaoning, China

► Original article

*Corresponding author:

XuHui Tai, M.D.,

E-mail:

13324042800@163.com

Received: October 2024

Final revised: December 2024

Accepted: December 2024

Int. J. Radiat. Res., April 2025;
23(2): 455-460

DOI: 10.61186/ijrr.23.2.455

Keywords: IMRT, Laryngeal neoplasms, cartilage invasion, magnetic resonance imaging, meta-analysis.

[#]These authors contributed equally to this work and should be considered as co-first authors.

ABSTRACT

Background: To analyze the sensitivity and specificity of magnetic resonance imaging (MRI) in diagnosing cartilage invasion in laryngeal neoplasms. **Materials and Methods:** A comprehensive search for relevant studies was conducted in PubMed, Web of Science, China National Knowledge Infrastructure (CNKI), and the Cochrane Trials Registry, with the search period extending until September 1, 2024. Sensitivity, specificity, and diagnostic likelihood ratio (DLR) were combined. Symmetrical Receiver Operating Characteristic (SROC) curves and Fagan nomograms were plotted. Meta-regression and subgroup analyses were performed to identify heterogeneity sources. **Results:** A total of seven studies involving 418 participants were included. MRI demonstrated a sensitivity of 0.93 [95% CI: 0.89–0.96, $I^2=0.00$] and a specificity of 0.88 [95% CI: 0.81–0.92, $I^2=70.36$] for detecting cartilage invasion. The negative diagnostic likelihood ratio (DLR-) was 0.08 with a 95% confidence interval of 0.05 to 0.13. The Area Under Curve (AUC) of the SROC curve was 0.95 with a 95% confidence interval of 0.85 to 0.99. Leave-one-out sensitivity analysis validated the robustness of the results concerning heterogeneity, as subgroup analysis did not mitigate it. Deek's funnel plot showed a symmetrical distribution of studies around the regression line, indicating no significant publication bias ($t=0.92$, $P=0.40$). **Conclusion:** MRI provides a reliable diagnostic performance for cartilage invasion in Laryngeal Neoplasms.

INTRODUCTION

Laryngeal Neoplasms, a common malignant tumor in the head and neck region, is classified into four types: supraglottic, subglottic, glottic, and transglottic (1, 2). Approximately two-thirds of patients with laryngeal neoplasms have the glottic type, while the supraglottic type accounts for about 30%. Fewer cases are identified as subglottic or transglottic (3, 4). Laryngeal neoplasms constitute 1–5% of overall cancer cases (5) and represents 8%–35% of malignant tumors in otolaryngology (6), being a multifactorial disease. Risk factors such as smoking and a laryngeal neoplasmsohol consumption are significantly associated with the onset of laryngeal neoplasms, alongside other potential contributors including microbiological and genetic factors (7). Studies indicate a higher incidence of laryngeal neoplasms in males (8). Symptoms include hoarseness, throat pain, a sensation of foreign body presence, and halitosis, severely affecting patients' breathing, communication, and eating, thereby imposing a considerable burden on their quality of life (9). Early diagnosis and prognostic prediction of laryngeal neoplasms facilitate the selection of appropriate treatment strategies, ultimately improving patient

survival quality. Cartilage invasion in laryngeal neoplasms is a prognostic factor (10-13). Research indicates that cartilage invasion correlates with reduced success rates for radiotherapy, often necessitating complex procedures such as total laryngectomy, which exacerbates dysphagia and speech difficulties (14) and increases the likelihood of tumor recurrence (15). With the widespread adoption of computed tomography (CT), it has become the most frequently utilized method for pre-treatment and staging of laryngeal neoplasms (16). However, the intricate structure of the neck, which includes soft tissues of the airway, blood vessels, muscles, cartilage, irregular bones, and numerous other components, limits CT's ability to accurately determine the extent of cartilage invasion (17). Studies have shown that magnetic resonance imaging (MRI) has significant potential in diagnosing and treating Laryngeal Neoplasms, particularly in assessing tumor cartilage invasion (18). This advantage is partly attributed to MRI's ability to measure the density of hydrogen protons in different structures (19), thereby differentiating tumor tissue from normal tissue. Physiological and spatial structures provide crucial information, offering a clearer perspective than CT. Additionally, MRI's multiparametric and

multisequence characteristics yield clearer anatomical details⁽²⁰⁾ and visually represent local physiological and spatial structures. Furthermore, MRI can utilize various pulse sequences to display different tissue types, avoiding artifacts caused by radiation and cortical interactions⁽²¹⁾, thus enhancing the accuracy of tumor boundary detection. However, the diagnostic value of MRI in detecting cartilage invasion in laryngeal neoplasms remains controversial, especially concerning sensitivity, specificity, and accuracy, with inconsistent findings across related studies. A systematic review and meta-analysis are essential to consolidate current evidence and thoroughly evaluate MRI's diagnostic value for cartilage invasion in laryngeal neoplasms, thereby offering a more dependable foundation for clinical diagnosis. This study aims to systematically evaluate the diagnostic efficacy of MRI for cartilage invasion in laryngeal neoplasms through meta-analysis, exploring its sensitivity, specificity, and overall diagnostic accuracy, while analyzing heterogeneity among studies and potential influencing factors. In this study, the sensitivity and specificity of MRI in the diagnosis of laryngeal cancer cartilage infiltration were evaluated for the first time by systematic Meta-analysis, which synthesized the data from seven high-quality studies and filled the research gap in the existing literature on the application of MRI in this field. In addition, this study quantified the diagnostic efficacy of MRI through statistical methods such as SROC curves and Fagan column line plots, and explored the sources of study heterogeneity through sensitivity analysis and subgroup analysis, which provided a more comprehensive and reliable evidence support for further clinical applications and research.

MATERIALS AND METHODS

Literature selection

A comprehensive search was performed across various databases, such as PubMed, Web of Science (WOS), Embase, Cochrane Library, CNKI, Wanfang, VIP, and the Chinese Biomedical Literature Database, with a cutoff date of September 1, 2024.

Inclusion criteria required: (1) patients with laryngeal neoplasms who developed cartilage infiltration, where cartilage invasion was clearly diagnosed by MRI, and patients with laryngeal neoplasms without cartilage infiltration, where the MRI results did not show cartilage invasion; (2) all patients in the study underwent a standardized MRI examination and the MRI images were able to show detailed information about cartilage structures. The MRI examination included conventional sequences (e.g., T1-weighted, T2-weighted, enhanced scans, etc.) as well as relevant specific techniques (e.g., DWI, dynamic contrast-enhanced imaging, etc.) to assess the infiltration of cartilage; (3) the MRI examination

results were complete; and (4) the selected studies had to provide, or were able to be computed from other data in the literature, four key data: the number of true-positive (TP), false-negative (FN), false-positive (FP), and true-negative (TN) cases, which were used to calculate statistical measures such as sensitivity, specificity, and positive and negative likelihood ratios; (5) no age, sex, or ethnicity restrictions; (6) no language restrictions. Exclusion criteria were: (1) studies on animals; (2) studies that were not case-control; (3) studies with incomplete data, duplicate publications, reviews, or abstracts; (4) studies with inconsistent inter-group differences or baseline data hindering comparison; (5) Studies that did not describe MRI diagnostic tests or were unable to provide MRI-specific data (e.g., TP, FN, FP, TN).

Data extraction

Two researchers independently gathered demographic and treatment information from the studies through *Endnote* software (EndNote X9, Duke University, USA), with a third author consulted to resolve any discrepancies. Baseline data were collected from seven studies, detailing the first author's name, publication year, study type, participant count, and demographics including age and sex ratios. The main outcomes comprised the counts of FN, TN, TP, and FP. Literature quality assessment was based on the QUADAS-2 quality assessment tool.

A meta-analysis was performed using *Stata* 15.0 software (Stata Corp, College Station, TX, USA) to calculate pooled sensitivity, specificity, and positive/negative DLR. SROC curves were plotted to estimate the overall diagnostic accuracy. A comparison of post-test probabilities with pre-test probabilities was conducted to evaluate whether the diagnostic results increased or decreased diagnostic probabilities, with pre-test probabilities derived from routine data, clinical data, or clinical judgment. Heterogeneity was assessed using the Cochrane Q statistic (chi-square) and inverse variance (I^2). A fixed-effects model was applied when I^2 was less than 50% and P was greater than 0.10, indicating substantial homogeneity among studies. Conversely, a random-effects model was utilized for the meta-analysis when I^2 was 50% or higher and P was less than 0.10. A P-value less than 0.05 was deemed statistically significant.

RESULTS

Literature selection process: The initial search identified 498 articles, comprising 127 from PubMed, 78 from Embase, and 292 from WOS. By reviewing clinical research reports and references from high-impact reviews, we identified an additional 14 studies for inclusion. Following the elimination of 145 duplicate articles, we reviewed the titles and abstracts of the subsequent 353 papers. We excluded

210 articles that did not meet the inclusion or exclusion criteria, leaving 143 articles for full-text review. After excluding articles with incomplete information and data, seven studies were ultimately included for analysis.

Key features of the studies included

Of the seven articles included in this analysis, with publication dates ranging from 1995 to 2021, a total

of 418 patients with Laryngeal Neoplasms who underwent MRI and pathologic examination were included. Table 1 presents the fundamental attributes of the included literature. All patients with Laryngeal Neoplasms underwent MRI and histopathologic testing, with some studies additionally including laryngoscopic testing. Six studies were prospective and one was retrospective. MRI models with different instruments are shown in table 1.

Table 1. Table presents the fundamental attributes of the selected studies.

	Author	Publication Date	nation	Age [M, (Q1, Q3)]	No	Male	Female	Type	MRI
1	P Zbären ⁽²²⁾	1997	Switzerland	60(44-87)	45	44	1	prospective study	Signa 1.5 T Perf. Plus unit (GE Medical Systems, Milwaukee, Wis., USA)
2	Mohamed S Taha ⁽²³⁾	2014	Egypt	58(49.8-63.8)	26	24	2	prospective study	Ain Shams University Hospitals (1.5 T, Philips, Healthcare)
3	Jonas A. Castelijns ⁽²⁴⁾	1988	Netherlands	46-87	42	38	4	prospective study	0.6-T superconductive system (Teslacon I; Technicare, Cleveland, Ohio)
4	Minerva Becker ⁽²⁵⁾	1995	Switzerland	61(44-85)	53	51	2	prospective study	Signa 1.5-T unit (GE Medical Systems, Milwaukee, Wis)
5	Eugenia Allegra ⁽²⁶⁾	2014	Italy	63.6(52-79)	20	20	0	prospective study	Philips Achieva 1.5 T MR system
6	Lv ⁽²⁷⁾	2021	China	60.06±8.63	35	35	0	retrospective study	GE Excite II Signa 3.0 Superconducting MRI Scanner
7	Li ⁽²⁸⁾	2017	China	60(39-84)	197	188	9	prospective study	GE Excite II Signa 3.0 Superconducting MRI Scanner

Note: The age data in table 1 are presented as median (M) and interquartile range (Q1, Q3), where M is the median, Q1 is the first quartile, and Q3 is the third quartile.

Figure 1 presents the bias risk assessment results for the included studies, evaluating the quality of the literature. Three studies⁽²⁶⁻²⁸⁾ did not clearly specify case selection criteria, while two studies^(22, 23) did not perform inappropriate exclusions. One study⁽²³⁾ did not mention whether the interpretation of MRI results was conducted without knowledge of the gold standard test results. All studies clearly indicated whether the implementation and interpretation of the gold standard could introduce bias. Furthermore, two studies^(24, 27) failed to indicate if an adequate time interval existed between the evaluated test and the gold standard.

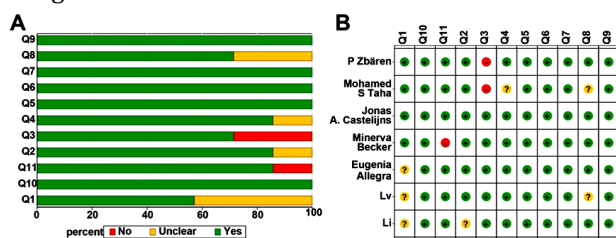


Figure 1. charts show assessing article quality (A. The risk of bias chart presents the review authors' assessment of bias risk for each item, shown as a percentage across all included studies. B. Summary of risk of bias assessment for each included study as evaluated by the review authors).

Sensitivity and specificity analysis

The overall sensitivity of MRI in diagnosing cartilage invasion was 0.93 [95% CI (0.89–0.96), $Q=5.76$, $I^2=0.00$] (figure 2A), indicating that MRI is highly effective in accurately identifying patients with cartilage invasion. Additionally, an I^2 value of 0.00

suggests no significant heterogeneity among the included studies, indicating good reliability. The specificity of MRI in excluding patients without cartilage invasion was 0.88 [95% CI (0.81–0.92), $Q=20.24$, $I^2=70.36$] (figure 2B), demonstrating its effectiveness in accurately identifying most patients without cartilage invasion.




Figure 2. Sensitivity and specificity analysis (A. Sensitivity analysis; B. Specificity analysis).

Positive/negative diagnostic likelihood ratios

The Positive DLR (DLR+) was 7.49 [95% CI (4.76–11.81)] (figure 3A), suggesting moderate diagnostic strength of MRI when the results for cartilage invasion are positive. The Negative DLR (DLR-) of 0.08 [95% CI (0.05–0.13)] (figure 3B) demonstrates MRI's strong ability to exclude cartilage invasion when results are negative.




Figure 3. Forest plots illustrating both positive and negative DLR outcomes. (A). Positive diagnostic likelihood ratio forest plot; (B). Negative diagnostic likelihood ratio forest plot.

SROC curve analysis

The SROC curve analysis revealed no threshold effects, as evidenced by the absence of a typical 'shoulder arm.' Figure 4 demonstrates a moderate predictive value with an SROC curve AUC of 0.95 [95% CI (0.85–0.99)].

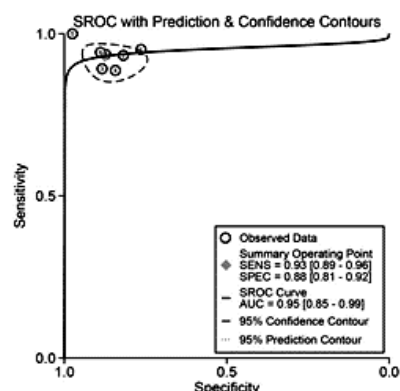


Figure 4. SROC curve for MRI identification of cartilage infiltration.

Prior probability, likelihood ratios, and posterior probability

A Fagan plot was created to depict the relationship between prior probability, likelihood ratios (LR), and posterior probability (figure 5). The prior probability of MRI was 50%, and the posterior probability was 88%. The positive likelihood ratio (LRP) was 7, and the negative likelihood ratio (LRN) was 0.08, suggesting that negative MRI results strongly indicate a low probability of cartilage invasion in Laryngeal Neoplasms. Thus, MRI serves as an excellent exclusionary test, effectively used to rule out cartilage invasion in laryngeal neoplasms, thereby reducing unnecessary further examinations or treatments.

Sensitivity analysis

A leave-one-out sensitivity analysis was performed to identify sources of heterogeneity. Each study was sequentially excluded to observe its effect on the overall specificity estimates. Although the high I^2 value for specificity suggests heterogeneity, the

sensitivity analysis showed that no individual study significantly influenced the overall findings (figure 6, table 2). Therefore, despite the presence of heterogeneity, the overall specificity results remain robust and are not driven by any single study.

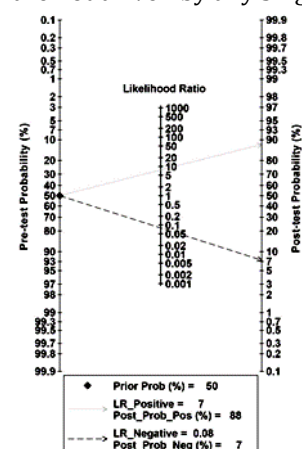


Figure 5. Fagan plot of MRI diagnosis of laryngeal neoplasms cartilage infiltration.

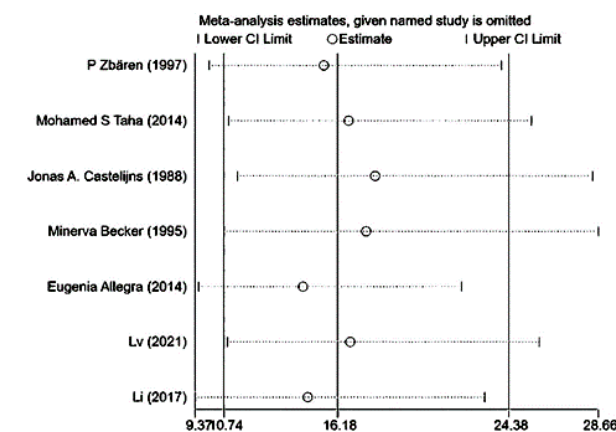


Figure 6. Sensitivity analysis plot for leave-one-out analysis.

Table 2. Sensitivity analysis chart for leave-one-out analysis.

No	Study omitted	Estimate	95% Conf	Interval
1	P Zbären (1997) ⁽²²⁾	15.519701	10.028879	24.016752
2	Mohamed S Taha (2014) ⁽²³⁾	16.703642	10.962196	25.452166
3	Jonas A. Castelijns (1988) ⁽²⁴⁾	17.974634	11.3811	28.388071
4	Minerva Becker (1995) ⁽²⁵⁾	17.543158	10.739847	28.656124
5	Eugenia Allegra (2014) ⁽²⁶⁾	14.520616	9.5348215	22.113499
6	Lvu (2021) ⁽²⁷⁾	16.784416	0.908212	25.826105
7	Li (2017) ⁽²⁸⁾	14.746093	9.3671894	23.213715
	Combined	16.182287	10.740729	24.380692

Subgroup analysis

Subgroup analyses were conducted on factors that might contribute to heterogeneity in study specificity. The elements of the subgroup analysis included study type (prospective/retrospective), gender (whether females were included), publication year (whether published before 2000), and sample size (whether greater than 50). Results across all subgroups showed high consistency, suggesting robustness.

Publication bias analysis

Deek's funnel plot showed a symmetrical distribution around the regression line, indicating no significant publication bias ($t=0.92, P=0.40$).

DISCUSSION

Laryngeal neoplasms are a global public health problem of concern, characterized by clinical features such as high rates of recurrence and metastasis and poor prognosis ⁽²⁹⁾. Accurate MRI-based staging and assessment of cartilage invasion aid healthcare providers in treatment planning, thereby improving patient outcomes and quality of life for patients and their families.

Our meta-analysis offers novel insights into the predictive value of MRI for cartilage invasion in laryngeal neoplasms. We included 418 patients from seven studies, a larger cohort than most existing imaging studies on laryngeal neoplasms. The overall effectiveness and sensitivity of MRI in diagnosing cartilage invasion were both above 0.85, underscoring its high diagnostic value. The negative likelihood ratio for MRI in this context was 0.08, indicating that when MRI results are negative, the likelihood of cartilage invasion is very low. Thus, MRI serves as an excellent exclusionary test, effectively ruling out cartilage invasion and minimizing unnecessary further examinations or treatments. Other studies have reached consistent conclusions ^(30, 31).

Research by Mohamad *et al.* indicates that MRI can effectively diagnose T4a stage laryngeal neoplasms, with accuracy in identifying cartilage invasion related to both primary and secondary tumors, reporting accuracy rates exceeding 90% for identifying invasion of the arytenoid cartilage and base of tongue ⁽³²⁾. Zbären's research indicates that MRI, due to its heightened sensitivity yet reduced specificity relative to CT, might overstate the extent of tumor cartilage invasiveness ⁽²²⁾. Additionally, data from Park *et al.* A study involving 24 laryngeal neoplasms patients demonstrated MRI's diagnostic efficacy with a sensitivity of 0.75, specificity of 0.96, and an AUC of 0.963 ⁽³³⁾. Compared to CT and other imaging modalities, MRI demonstrates superior diagnostic accuracy ⁽³⁴⁾. However, the development of dedicated MRI protocols for early-stage laryngeal neoplasms assessment is still ongoing due to significant variability in scanning protocols ⁽³⁵⁾.

While our results indicate heterogeneity in specificity, our subgroup analysis did not pinpoint the source of this heterogeneity. Given the broad time span of the included studies, we speculate that differences in MRI equipment models may contribute to this variability. Research by Yu *et al.* ⁽³⁶⁾ indicates that DCE-MRI better differentiates and quantifies laryngeal cartilage lesions compared to standard MRI. Some scholars ⁽³⁷⁾ have analyzed key parameters in MRI for diagnosing cartilage invasion, noting that a low 95th percentile of the AUC60 is the only MRI variable. Heterogeneous characteristics among tumor patients may correlate with cartilage invasion ⁽³⁸⁾, which could also be a source of

variability in our study. Additionally, the staging of laryngeal neoplasms is a crucial factor influencing cartilage invasion risk ⁽³⁹⁾, yet the studies we included did not clearly define patient staging. Another study involving 358 laryngeal neoplasms patients suggests that changes in vocal fold (VF) mobility increase the risk of cartilage invasion ⁽³⁹⁾, but our subgroup analysis did not incorporate this metric due to its limited presence in the studies. We look forward to further research clarifying imaging characteristics of cartilage invasion in well-staged laryngeal neoplasms patients.

This study has certain limitations. Incomplete radiological reports may restrict our findings, as not all sub-sites of the larynx were reported, potentially omitting important details affecting result interpretation. Furthermore, variability in MRI technology and different scanners used for patient imaging may also contribute to the limitations of this study.

CONCLUSION

MRI is a valuable tool for predicting cartilage invasion in laryngeal neoplasms patients, potentially serving as an essential resource for preoperative planning and treatment decisions in this patient population.

ACKNOWLEDGEMENTS

The authors would like to express their sincere thanks to all the researchers and organisations that contributed to this study.

Conflicts of Interest:

All authors unanimously declare that there is no conflict of interest in this study.

Funding: This study was supported by no funding.

Ethical consideration: Not applicable.

Author contribution: Z-D.W. and Y.Z. contributed to the conceptualization and design of the study, as well as the literature search and data extraction. H.C. performed the statistical analysis and was responsible for the interpretation of the meta-analytic results. X-D.S. conducted the sensitivity analyses and assisted in drafting the manuscript. X-H.T. provided critical revisions to the manuscript, focusing on the methodology and clinical implications of the findings. All authors approved the final version of the manuscript and agreed to be accountable for all aspects of the work.

REFERENCES

1. Bibi K and Shah MH (2023) Investigation of imbalances in essential/toxic metal levels in the blood of laryngeal cancer patients in comparison with controls. *Biometals*, **36**: 111-127.
2. Iravani K, Monshizadeh L, Moeinjahromi E, *et al.* (2022) Is there any association between total laryngectomy and sexual disorders in men? *Iran J Otorhinolaryngol*, **34**: 233-237.

3. Gong XY, Chen HB, Zhang LQ, *et al.* (2022) NOTCH1 mutation associates with impaired immune response and decreased relapse-free survival in patients with resected T1-2N0 laryngeal cancer. *Front Immunol*, **13**: 920253.
4. Hu M and Zhang S (2022) Expression and clinical significance of FGFR1 and FGFR2 in laryngeal squamous cell carcinoma. *Transl Cancer Res*, **11**: 3222-3234.
5. Song G and Liu H (2017) Effect of hospital to home nutrition management model on postoperative clinical outcomes of patients with laryngeal carcinoma. *Oncol Lett*, **14**: 4059-4064.
6. Qiu HO, Wang H, Che N, *et al.* (2016) Identification and characterization of CD133(pos) subpopulation cells from a human laryngeal cancer cell line. *Med Sci Monit*, **22**: 1146-1151.
7. Pacella-Norman R, Urban MI, Sitas F, *et al.* (2002) Risk factors for oesophageal, lung, oral and laryngeal cancers in black South Africans. *Br J Cancer*, **86**: 1751-1756.
8. Zhu Y, Guo L, Wang S, *et al.* (2018) Association of smoking and XPG, CYP1A1, OGG1, ERCC5, ERCC1, MMP2, and MMP9 gene polymorphisms with the early detection and occurrence of laryngeal squamous carcinoma. *J Cancer*, **9**: 968-977.
9. Brook I (2021) "The Laryngectomy Guide" is available in 18 languages (Free eBooks). *World J Otorhinolaryngol Head Neck Surg*, **7**: 312-317.
10. Dankbaar JW, Oosterbroek J, Jager EA, *et al.* (2017) Detection of cartilage invasion in laryngeal carcinoma with dynamic contrast-enhanced CT. *Laryngoscope Invest Otolaryngol*, **2**: 373-379.
11. Dulguerov P, Broglie MA, Henke G, *et al.* (2019) A review of controversial issues in the management of head and neck cancer: a Swiss multidisciplinary and multi-institutional patterns of care study-part 1 (head and neck surgery). *Front Oncol*, **9**: 1125.
12. Atula T, Markkola A, Leivo I, *et al.* (2001) Cartilage invasion of laryngeal cancer detected by magnetic resonance imaging. *Eur Arch Otorhinolaryngol*, **258**: 272-275.
13. Rao D, K P, Singh R, *et al.* (2022) Automated segmentation of the larynx on computed tomography images: a review. *Biomed Eng Lett*, **12**: 175-183.
14. Wiegand S (2016) Evidence and evidence gaps of laryngeal cancer surgery. *GMS Curr Top Otorhinolaryngol Head Neck Surg*, **15**: Doc03.
15. Tang ZX, Gong JL, Wang YH, *et al.* (2018) Efficacy comparison between primary total laryngectomy and nonsurgical organ-preservation strategies in treatment of advanced stage laryngeal cancer: A meta-analysis. *Medicine (Baltimore)*, **97**: e10625.
16. Jiang P, Gu L, Zhou Y, *et al.* (2018) Synchronous laryngeal squamous cell carcinoma and intrahepatic cholangiocarcinoma present in an obese male with poor prognosis. *Anticancer Res*, **38**: 5547-5550.
17. Shang DS, Ruan LX, Zhou SH, *et al.* (2013) Differentiating laryngeal carcinomas from precursor lesions by diffusion-weighted magnetic resonance imaging at 3.0 T: a preliminary study. *PLoS One*, **8**: e68622.
18. Itamura K, Hsue VB, Barbu AM, *et al.* (2023) Diagnostic assessment (imaging) and staging of laryngeal cancer. *Otolaryngol Clin North Am*, **56**: 215-231.
19. Si G, Du Y, Tang P, *et al.* (2024) Unveiling the next generation of MRI contrast agents: current insights and perspectives on ferumoxytol-enhanced MRI. *Natl Sci Rev*, **11**: nwae057.
20. Zhang LJ and Lu GM (2023) To promote the clinical application of PET/MRI in oncology. *Zhonghua Yi Xue Za Zhi*, **103**: 2543-2545.
21. Aboussaleh I, Riffi J, Mahraz AM, *et al.* (2021) Brain tumor segmentation based on deep learning's feature representation. *J Imaging*, **7**: 269.
22. Zbären P, Becker M, Läng H (1997) Staging of laryngeal cancer: endoscopy, computed tomography and magnetic resonance versus histopathology. *Eur Arch Otorhinolaryngol*, **254** (Suppl 1): S117-122.
23. Taha MS, Hassan O, Amir M, *et al.* (2014) Diffusion-weighted MRI in diagnosing thyroid cartilage invasion in laryngeal carcinoma. *Eur Arch Otorhinolaryngol*, **271**: 2511-2516.
24. Castelijns JA, Gerritsen GJ, Kaiser MC, *et al.* (1988) Invasion of laryngeal cartilage by cancer: comparison of CT and MR imaging. *Radiology*, **167**: 199-206.
25. Becker M, Zbären P, Laeng H, *et al.* (1995) Neoplastic invasion of the laryngeal cartilage: comparison of MR imaging and CT with histopathologic correlation. *Radiology*, **194**: 661-669.
26. Allegra E, Ferrise P, Trapasso S, *et al.* (2014) Early glottic cancer: role of MRI in the preoperative staging. *Biomed Res Int*, **2014**: 890385.
27. Lyu Y, Qu J, He B, *et al.* (2021) The value of dual-energy CT and MRI in the diagnosis of pre-invasive laryngeal neoplasms. *Journal of Clinical Radiology*, **40**: 1486-1490.
28. Li H and Chen X (2017) The diagnostic value of enhanced MRI combined with DWI sequences for malignant tumor invasion of the thyroid cartilage. *Chinese Journal of Otorhinolaryngology, Head and Neck Surgery*, **23**: 333-337+341.
29. Bagherzadeh S, Shahbazi-Gahrouei D, Torabinezhad F, *et al.* (2022) The effects of (chemo) radiation therapy on the voice and quality of life in patients with non-laryngeal head and neck cancers: a subjective and objective assessment. *International Journal of Radiation Research*, **20**: 397-402.
30. Ahn SH, Hong HJ, Kwon SY, *et al.* (2017) Guidelines for the surgical management of laryngeal cancer: Korean society of thyroid-head and neck surgery. *Clinical and experimental otorhinolaryngology*, **10**: 1-43.
31. Lam S, Gupta R, Kelly H, *et al.* (2015) Multiparametric evaluation of head and neck squamous cell carcinoma using a single-source dual-energy CT with fast kVp switching: State of the art. *Cancers (Basel)*, **7**: 2201-2216.
32. Mohamad I, Hejleh TA, Qandeel M, *et al.* (2023) Concordance between head and neck MRI and histopathology in detecting laryngeal subsite invasion among patients with laryngeal cancer. *Cancer Imaging*, **23**: 99.
33. Park CJ, Kim JH, Ahn SS, *et al.* (2021) Preoperative MRI evaluation of thyroid cartilage invasion in patients with laryngohypopharyngeal cancer: comparison of contrast-enhanced 2D spin-echo and 3D T1-weighted radial gradient recalled-echo techniques. *AJNR Am J Neuroradiol*, **42**: 1690-1694.
34. Pucetàitè M, Farina D, Ryškiene S, *et al.* (2024) The diagnostic value of CEUS in assessing non-ossified thyroid cartilage invasion in patients with laryngeal squamous cell carcinoma. *J Clin Med*, **13**: 891.
35. Schleder S, May M, Habicher W, *et al.* (2022) additional diffusion-weighted imaging with background body signal suppression (DWIBS) improves pre-therapeutic detection of early-stage (pT1a) glottic cancer: A feasibility and interobserver reliability study. *Diagnostics (Basel)*, **12**: 3200.
36. Yu J, Xu W, Wang L, *et al.* (2023) The clinical value of DCE-MRI for differentiating secondary laryngeal cartilage lesions. *Medicine (Baltimore)*, **102**: e33352.
37. Smits HJG, Vink SJ, de Ridder M, *et al.* (2024) Prognostic value of pretreatment radiological MRI variables and dynamic contrast-enhanced MRI on radiotherapy treatment outcome in laryngeal and hypopharyngeal tumors. *Clin Transl Radiat Oncol*, **49**: 100857.
38. Bini F, Pica A, Azzimonti L, *et al.* (2021) Artificial intelligence in thyroid field-A comprehensive review. *Cancers (Basel)*, **13**: 4740.
39. Hartl DM, Landry G, Hans S, *et al.* (2010) Organ preservation surgery for laryngeal squamous cell carcinoma: low incidence of thyroid cartilage invasion. *Laryngoscope*, **120**: 1173-1176.