

# Investigation of interfractional esophageal motions and its dosimetric effect in patients who underwent radiochemotherapy with esophageal carcinoma

E.S. Akovalı<sup>1,2\*</sup>, G. Can<sup>3</sup>, S. Karaçam<sup>1</sup>, D.Ç. Öksüz<sup>1</sup>

<sup>1</sup>Istanbul University-Cerrahpaşa, Cerrahpaşa Medical Faculty, Department of Radiation Oncology, Istanbul, Turkey

<sup>2</sup>Sakarya University Research and Training Hospital, Department of Radiation Oncology, Sakarya, Turkey

<sup>3</sup>Istanbul University-Cerrahpaşa, Cerrahpaşa Medical Faculty, Department of Public Health, Istanbul, Turkey

## ABSTRACT

### ► Original article

#### \*Corresponding author:

Emine Sedef Akovalı, M.D.,

#### E-mail:

[eminesedef88@gmail.com](mailto:eminesedef88@gmail.com)

Received: September 2024

Final revised: July 2025

Accepted: August 2025

Int. J. Radiat. Res., January 2026;  
24(1): 129-134

DOI: 10.61186/ijrr.24.1.20

**Keywords:** Esophageal cancer, interfractional esophageal motion, CBCT.

**Background:** The aim of this study was to evaluate interfractional esophageal motions using kilovoltage cone-beam computed tomography (kV-CBCT) in patients who underwent chemoradiotherapy for esophageal cancer. **Materials and Methods:** Sixteen patients treated with intensity modulated radiation therapy or volume modulated arc therapy were included. For each patient, one kV-CBCT per week was used for the assessments. Upper, middle, distal thoracic esophagus and abdominal esophagus was contoured on planning CT (pCT) and each kV-CBCT images. Each kV-CBCTs was fused with the pCT after automatic vertebrae-matching rigid registration, thus only esophageal motion was taken into account. The displacement of the esophageal center points was calculated on the left-right (LR), anterior-posterior (AP), cranio-caudal (CC) directions. It was investigated whether the outer contour of the esophagus remained within the 95% isodose line in the treatment plan. **Results:** The interfractional displacement of the abdominal esophagus in all directions was found statistically significantly higher than other part of the esophagus. The minimum PTV margin of 1.03 cm for AP, 1.03 cm for CC and 1.05 cm for LR direction was required. The minimum margin needed for covering 95% of the tumor motion in LR, AP, CC directions, respectively, were 0.8, 0.8 and 0.7 cm for the abdominal esophagus. Isodose coverage of 95% were similar for all esophageal segments in pCT and combined kV-CBCT volume. **Conclusion:** Interfractional position changes were largest in all directions in the abdominal esophagus. Reducing of PTV margin for the distal thoracic and abdominal esophagus may not be suitable for clinical practice.

## INTRODUCTION

Esophageal carcinoma is one of the most common malignancies in the world (1, 2). Early stage esophageal cancer are treated with surgery, while the standard management of locally advanced esophageal cancer is neoadjuvant radiochemotherapy followed by surgical resection or radical radiochemotherapy (RT-CH). Recently, some immunotherapy trials combined with radical radiochemotherapy have shown promising results on survival (3-5).

Three dimensional conformal radiotherapy (3D-CRT) with computed tomography (CT)-based treatment planning is commonly used for esophageal carcinoma treatment. With technological advancements, the use of intensity modulated radiation therapy (IMRT) or volume modulated arc therapy (VMAT) for treatment of these patients is recommended to maximize the control of the tumor and minimize the dose to organs at risk, including the lung, heart, and medulla spinalis. For esophageal cancer, the available clinical data showed similar or possibly more favorable outcomes with IMRT or VMAT compared with 3D-CRT (6-9). However, IMRT

requires careful attention to target delineation along with intrafractional and interfractional organ and tumor motion to avoid the possibility of a marginal miss. Therefore, image guided radiotherapy (IGRT) is required for confirming accurate irradiation (10, 11). In particular, esophageal tumors have a large and complex shape and have larger displacements induced by peristaltic, respiratory, and cardiac motions. The location of esophageal tumors and organs at risk during fractionated radiotherapy can change substantially from the planning CT scan. Cone beam computed tomography (CBCT) is the most preferable IGRT imaging modality since it allows verification based on both the bony and the soft tissue anatomy. Previous studies showed that tumor shifts are larger in the distal thoracic esophagus and are mostly cranio-caudal (CC) direction (12-15). However, there is a paucity of data on the actual dose distribution to tumor and normal tissues during radiotherapy.

The main goal of this study was investigating interfractional motion variations of different esophagus segments remaining within the planning target volume (PTV) during kilovoltage (kV) CBCT-

guided radiotherapy. In addition, we assessed setup strategies and errors and PTV margin. Also, we investigated whether reducing the PTV margin, which is widely researched and supported, is suitable for clinical practice.

## MATERIALS AND METHODS

Between 2010 and 2019, 44 patients with esophageal cancer were treated with neoadjuvant or primary RT-CH. 16 participants were treated with IMRT or VMAT with kV-CBCT for image guidance were included in this study. The study had the approval of the local institutional ethics committee (IUC 09/01/2019-5045).

### CT simulation and treatment planning

Each patient fasted for 3 hours during planning CT (pCT) acquisition and radiotherapy. The scanner used in this study was the GE Discovery RT scanner (GE Healthcare, Waukesha, WI, USA). All patients were in the supine position and a thorax board (CIVCO Radiotherapy, Coralville, IA, USA) was used for patient immobilisation.

All pCT images were imported into Velocity Workstation version 4.0 (Varian Medical Systems, Palo Alto, CA, USA) for contouring. The tumor and the involved regional lymph nodes (GTV-T and GTV-N) was delineated as identified by endoscopy, CT, and positron emission tomography (PET-CT). The clinical target volume for the tumor (CTV-T) was generated with 1 cm radial and 3 cm cranio-caudal margins along the esophagus. The CTV for the lymph nodes was generated with isotropic margins of 0.5 cm and elective lymph node areas were included<sup>(16, 17)</sup>. An isotropic 1 cm expansion of the CTV was used to generate the PTV. Treatment was planned and optimised using the Eclipse treatment planning system, version 15.6 (Varian Medical Systems, Palo Alto, CA, USA) and the dose was computed using the Analytical Anisotropic Algorithm (AAA). RT planning was generated with dynamic IMRT or VMAT. The main goal of treatment planning was to obtain appropriate dose coverage of the target volume in accordance with International Commission on Radiation Units and Measurements 83 recommendations. Patients were treated with a Varian RapidArc linear accelerator (Varian Medical Systems, Palo Alto, CA, USA) using 6 MV X-rays. One example of treatment planning was shown in figure 1.

Before each fraction of radiotherapy, kV-CBCT obtained over On-Board Imaging system (OBI - Varian Medical Systems, Palo Alto, CA, USA) for daily IGRT setup. The kV-CBCT scans were manually matched online with pCT based on firstly bone (vertebrae) structures, then target and adjacent soft tissue. To eliminate interobserver variability, superimposition of the kV-CBCT with pCT and interpretation of images was carried out by the same

physician for all patients. Online couch shifts were noted for every fraction. After applying online couch shift, the patients' treatment was started. All patients completed the planned radiotherapy.

### Esophageal displacement, setup errors, and calculation of PTV margin

A total of 80 kV-CBCT images, one per week, were selected to assess esophageal motion. The esophagus was contoured on each kV-CBCT and pCT image according to anatomical location, namely proximal thoracic, middle thoracic, and distal thoracic esophagus and abdominal esophagus. The esophagus was contoured along the segment within PTV and adjacent segments. The proximal stomach was excluded from the abdominal part of the esophagus. All contours were created by the same radiation oncologist and under mediastinal window settings (window width: 350 Hounsfield Unit, window level: 40 Hounsfield Unit). After contouring, each kV-CBCT image was fused with pCT using automatic bone-matching rigid registration with reference to the vertebrae alone, and volumes on kV-CBCTs were copied on pCT structure set to assess esophageal motion. Esophageal volume center positions were acquired by the treatment planning system on both kV-CBCTs and pCT. Displacement of the esophageal center points was measured in the left-right (LR), anterior-posterior (AP), and cranio-caudal (CC) directions according to centers on pCT. The negative values that indicated direction of motions were not considered, therefore all values were positive.

A total of 392 kV-CBCT images and online couch shift values obtained on the basis of bone and the soft tissue matching were evaluated to assess the PTV margin. The PTV margin was computed with the van Herk formula ( $2.5\Sigma + 0.7\sigma$ ;  $\Sigma$ =standart deviation,  $\sigma$ =random error)<sup>(18)</sup>. Each esophageal segments that were contoured on kV-CBCTs were combined into one structure that contained all interfractional displacements. The dose was recalculated for this structure on treatment planning and whether the outer esophageal wall was covered by 95% isodose line was observed.

### Statistical analysis

Three-dimensional shifts at different esophageal segments were analyzed with Kruskal-Wallis H and Mann-Whitney U tests. The displacements of same segments in a different direction were analyzed using Friedman and Wilcoxon signed-ranked tests. Results were deemed to be significant at  $p < 0.05$ .

## RESULTS

Tumor characteristics and treatment details are shown in table 1. The median displacement of center of abdominal esophageal segment was found 0.33 cm in LR, 0.31 cm in AP, and 0.23 cm in CC directions. For

the distal thoracic esophagus, the displacement was 0.16 cm in LR, 0.12 cm in AP, and 0.20 cm in CC directions. The maximum displacement in the distal thoracic and abdominal esophagus increased to 1 cm. For the other segments, both maximum and median values were lower compared with the distal thoracic and abdominal esophagus (table 2).

**Table 1.** Patient characteristics. (CDDP+5-FU=cisplatin + 5-fluorouracil, CH=chemotherapy, RT=radiotherapy, SCC=squamous cell carcinoma).

	n	%		n	%		
<b>Sex</b>			<b>Tumor localization</b>				
	Men	13		81.2	Middle thoracic	6	37.6
	Women	3		18.8	Distal thoracic	5	31.3
<b>Pathology</b>			<b>RT</b>				
	SCC	10		62.5	Primary	10	62.5
	Adenocarcinoma	6		37.5	Neoadjuvant	6	37.5
<b>T stage</b>			<b>RT dose</b>				
	T2	3		18.8	41.4 Gy	3	18.8
	T3	6		37.5	45 Gy	4	25
	T4a	5		31.3	50.4 Gy	9	56.3
	T4b	2		12.5			
<b>N stage</b>			<b>Concurrent CH</b>				
	N0	2		12.5	CDDP + 5-FU	9	56.3
	N1	6		37.5	Carboplatin + paclitaxel	7	43.8
	N2	7		43.8			
	N3	1		6.3			

**Table 2.** Displacements of esophageal segment center positions in left-right, anterior-posterior and craniocaudal directions according to centers on pCT. (AP=anterior-posterior, CC=cranio-caudal, LR=left-right, IQR 25-75=interquartile range 25-75%).

	Direction	Median (cm)	IQR 25-75 (cm)		Min-max (cm)
Proximal thoracic esophagus	LR	0.16	0.09	0.30	0-0.5
	AP	0.10	0.05	0.18	0-0.4
	CC	0.17	0.12	0.22	0-0.4
Middle thoracic esophagus	LR	0.19	0.11	0.29	0-0.7
	AP	0.10	0.05	0.20	0-0.4
	CC	0.11	0.04	0.24	0-0.6
Distal thoracic esophagus	LR	0.16	0.04	0.31	0-0.9
	AP	0.12	0.04	0.27	0-1
	CC	0.20	0.09	0.34	0-0.8
Abdominal esophagus	LR	0.33	0.14	0.54	0-0.9
	AP	0.31	0.12	0.46	0-0.9
	CC	0.23	0.12	0.39	0-0.9

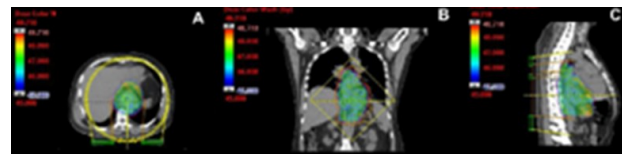
The shift of the abdominal esophagus in all directions was statistically significantly higher than other segments. The mean displacements of abdominal esophagus were 0.35 cm, 0.34, and 0.29 cm in LR, AP, and CC directions, respectively (table 3 and figures 1-3). When we compared the thoracic esophageal segments between each other, only the distal thoracic esophagus displacement, a mean of 0.24 cm, was statistically significantly higher in the CC direction (p:0.006).

When the displacements of the same segments in different directions were compared, the shift directions of the abdominal esophagus and proximal thoracic esophagus were not significantly different. The LR and AP movements of the abdominal esophagus were 0.33 and 0.31 cm, respectively,

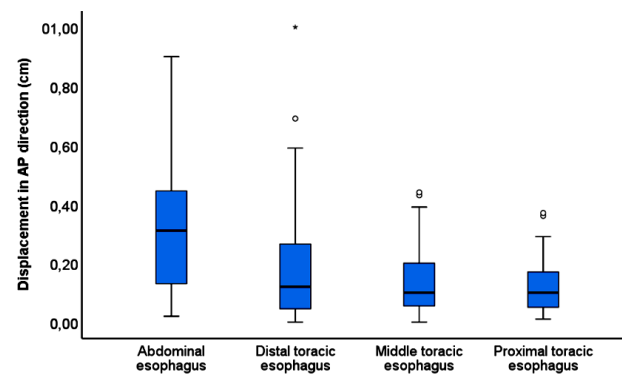
which are higher than those in the CC direction (p:0.43). For the distal thoracic esophagus, CC shift, a median of 0.20 cm, was greater and close to statistical significance (p:0.06). In the middle thoracic esophagus, the LR displacement was significantly higher than CC and AP displacements (p:0.001; table 4). No statistically significant variations were identified between shift values observed at first and last treatment week even when considering tumor shrinkage.

**Table 3.** The displacements of different segments of the esophagus in the same direction. (LR: left-right, AP: anterior-posterior, CC: craniocaudal, SD: standard deviation).

	Abdominal	Distal thoracic	Middle thoracic	Proximal thoracic	p value
	Mean ± SD (cm)				
LR	0.35±0.23	0.21±0.19	0.23±0.17	0.20±0.14	0.02
AP	0.34±0.24	0.19±0.20	0.13±0.11	0.13±0.10	<0.001
CC	0.29±0.21	0.24±0.18	0.16±0.15	0.17±0.10	0.001



**Figure 1.** Radiotherapy planning of a patient with middle thoracic esophageal cancer **A:** 100 % to 108 % of prescribed dose in the axial plane as color wash. Yellow circle represents volumetric arc treatment. **B:** 100 % to 108 % of prescribed dose in the coronal plane as color wash. The position of the multileaf collimators at the tumor center is shown. **C:** 100 % to 108 % of prescribed dose in the sagittal plane as color wash.

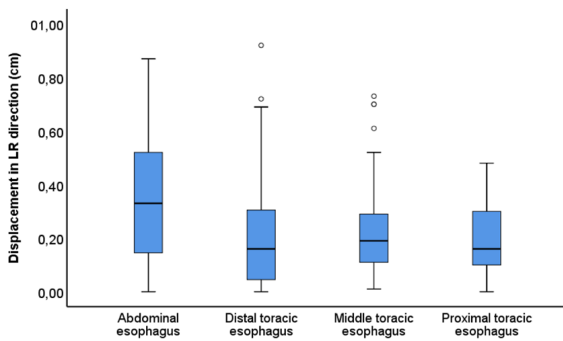


**Figure 2.** Interfractional displacement of esophageal segments in anterior-posterior (AP) direction (Horizontal lines in the middle of rectangle boxes represent the median value, rectangle boxes represent IQR 25-75, whiskers represent minimum and maximum values except outliers. Outliers are shown as circles and stars. Circles indicate mild outlier; stars indicate extreme outlier).

According to this study, the margin needed for covering 95% of motion was 0.5-0.6-0.6-0.8 cm in the LR direction, 0.3-0.4-0.6-0.8 cm in the AP direction and 0.4-0.5-0.6-0.7 cm in the CC direction for the proximal thoracic, middle thoracic, distal thoracic and abdominal esophagus respectively.

Median and standard deviation values of setup errors based on online matching were 0.07±0.33 cm in LR, -0.21±0.34 cm in AP, and -0.03±0.33 cm in CC

directions. When the couch shifts were considered as numeric values, mean and maximum values were 0.28–1.6 cm in the lateral, 0.29–1.6 cm in the vertical, and 0.26–1.9 cm in longitudinal axes. Among the treatment fractions, a ratio with  $\geq 1$  cm setup shifts were 4.3% in LR, 7.9% in AP, and 7.9% in CC axes. Standard deviations and random errors of setup errors were given in Table 5. The PTV margin was calculated as 1.05 cm in LR, 1.03 cm in AP, and 1.03 cm in CC directions (table 5).



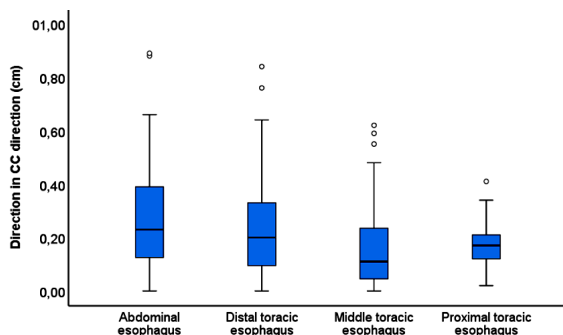
**Figure 3.** Interfractional displacement of esophageal segments in left-right (LR) direction (Horizontal lines in the middle of rectangle boxes represent the median value, the rectangle boxes represent IQR 25-75, whiskers represent the minimum and maximum values except outliers. Outliers are shown as circles and stars. Circles indicate mild outlier; stars indicate extreme outlier).

**Table 4.** The displacements in different directions within the same segment of the esophagus. (LR: left-right, AP: anterior-posterior, CC: craniocaudal).

	Abdominal	Distal thoracic	Middle thoracic	Proximal thoracic
	<b>Median (min–max; cm)</b>			
<b>LR</b>	0.33 (0–0.9)	0.16 (0–0.9)	0.19 (0–0.7)	0.16 (0–0.5)
<b>AP</b>	0.31 (0–0.9)	0.12 (0–1)	0.10 (0–0.4)	0.10 (0–0.4)
<b>CC</b>	0.23 (0–0.9)	0.20 (0–0.8)	0.11 (0–0.6)	0.17 (0–0.4)
<b>p value</b>	0.43	0.06	0.001	0.1

**Table 5.** Setup errors in all three directions (cm). (LR: left-right, AP: anterior-posterior, CC: craniocaudal).

	LR	AP	CC
<b>Σ (systematic error)</b>	0.33	0.34	0.33
<b>δ (random error)</b>	0.31	0.26	0.43
<b>2.5 Σ + 0.7 δ (van Herk formula)</b>	1.05	1.03	1.03



**Figure 4.** Interfractional displacement of esophageal segments in crano-caudal (CC) direction (Horizontal lines in the middle of rectangle boxes represent the median value, rectangle boxes represent IQR 25-75, whiskers represent minimum and maximum values except outliers. Outliers are shown as circles and stars. Circles indicate mild outlier; stars indicate extreme outlier).

Evaluation of dose volume histograms showed that a dose of 95% was similar for all volumes of esophageal segments in pCT and combined kV-CBCT volume. The outer wall of esophagus remaining in PTV were covered by 95% of the isodose line.

## DISCUSSION

Currently, combination of RT-CH and surgery is the predominant therapeutic modality for patients with locally advanced, potentially operable esophagus cancer. The radiotherapy for esophageal tumor poses a significant challenge for radiation oncologists since treatment volumes are typically large and surrounded by radiosensitive normal tissue, including the heart, lungs, medulla spinalis, intestines, liver, and kidneys. Considering these, we investigated interfractional motions and setup errors in patients diagnosed with esophagus cancer who have undergone RT-CH.

In the literature, some studies have evaluated different PTV margins or setup verification according to bone structures, carina, soft tissues, or markers placed in the tumor. In a recent study, authors compared different PTV margins of 0.3 to 1.0 cm. They studied patients with upper or middle esophageal cancer and indicated strict radial margin provided less dose to organs at risk (19). Yamashita *et al.* reported PTV margins according to bone structure-based setup as 5 mm for lateral direction and 8 mm each in anterior-posterior and crano-caudal directions (20). Likewise, other authors noted that marker shifts according to bone-based matching were 0.89, 0.73, and 0.95 cm in LR, AP, and CC directions, respectively, and 2-3 mm greater than soft tissue-based matching (14). In another study, which investigated position variation according to the marker placed in the tumor, the PTV margin in the crano-caudal direction was 1.21 cm and larger than the other directions.(21) In our study, we did not prefer to use intra-tumoral fiducial markers due to additional cost to the patient and invasive procedure. During online matching, soft tissue and carina in appropriate cases were taken into account in addition to vertebral-based matching. Therefore, the maximum values of our online couch shift were higher compared with other studies. According to our study, it was calculated that the PTV margin should be at least 1 cm as contouring guidelines have suggested.

There are a number of studies that investigate motions in each segment of the esophagus. Jin *et al.* reported respiration induced motion in the distal thoracic esophagus was 0.16–1 cm in transverse and 0.37–1.17 cm in longitudinal axes (22). In gastroesophageal junction tumors, the greatest motion of GTV was observed in the CC direction during respiratory cycle (23). Li *et al.* researched the effect of pneumatic abdominal compression belt on tumor motion in the GEJ, and noted distal marker

motion of 0.7 cm in LR, 0.7 cm in AP, and 0.5 cm in CC (15). Hoffmann *et al.* reported a 0.84 cm respiratory motion in CC direction (14). In another study reporting motion of GTV centroid position, the median displacement was calculated as 0.1/0.13/0.15 cm in LR, 0.08/0.09/0.2 cm in AP, 0.14/0.32/0.44 cm in CC directions in the upper, middle, and distal thoracic esophagus, respectively (24). We observed that the maximum movement in the distal thoracic and abdominal esophagus was significantly greater compared with other esophageal segments, which corroborates the literature. In addition, although many studies have found that the highest displacement was observed in the craniocaudal direction, we found the movement of the abdominal esophagus was similarly high in all directions. Additionally, proximal thoracic esophageal movements were more limited, similar to the literature.

Wang *et al.* noted that margin extension of 0.40, 0.58, and 0.82 cm in the LR, AP, and CC directions, respectively, would cover 95% of respiratory-related displacement for distal thoracic esophagus cancer.(24) In a study involving patients who had undergone treatment with 3D-CRT, the authors recommended 1 cm LR and 1.1 cm AP margin to cover more than 95% motion of the esophagus (20). The margin expansion to compensate more than 95% motion of the abdominal esophagus was higher than other segments, in all directions in our study.

Tumor stage is other component that affects motion. In particular, smaller tumors show greater motion. Also, the amplitude of motion can change during radiotherapy due to tumor shrinkage. Wang *et al.* found that the internal GTV centroid displacements at the 20th fraction appeared greater than at the 10th fraction (not statistically significant) (12). In our study, most of the patients had T4 tumors, which might have been the reason why we could not find statistically significant interfractional shift of esophageal segments between CBCTs obtained in the first and last treatment weeks.

We investigated esophageal motion by contouring the outer esophageal wall instead of GTV. Delineation of GTV in CBCT was not preferred due to possible mistakes caused by the restricted soft-tissue contrast resolution in CBCT, image artifacts, and increased thickness of esophageal mucosa due to radiation esophagitis. Furthermore, considering target volumes of esophageal cancer are large and complex shape, we contoured the esophagus along the segment involved containing the PTV and adjacent segments. Thus, the motion of the esophagus, which is outside the GTV tumor but inside the PTV, was taken into account and it is a highlight of our study. However, this study has certain limitations. We did not account for intrafractional motion. Although the number of kV-CBCT is high, the number of patients is small and we could not contour the tumor itself

because of technical reasons as mentioned above.

In conclusion, we observed that interfractional position changes in the esophagus were more pronounced in the abdominal esophagus. However, unlike other studies, the movement magnitude was similarly high in all directions. Also, the magnitude of displacement did not differ due to tumor shrinkage. Reducing the PTV margin for the distal thoracic and abdominal esophagus might not be suitable for clinical practice. PTV margin should be large enough to cover interfractional and intrafractional motions. Even if daily kV-CBCT is not available, weekly kV-CBCT online evaluation seems to be sufficient for these regions. However, in the middle and proximal thoracic esophagus, daily CBCT in online evaluation might be more significant. Daily CBCT in online evaluation with soft tissue matching besides bone matching could reduce PTV margins and allow more accurate treatment. In addition, adaptive planning requirements can be detected early.

**Acknowledgements:** We all thank our colleagues and patients.

**Ethical consideration:** The study had the approval of the local institutional ethics committee.

**AI Usage:** AI is not used.

**Conflicts of interest:** There is no conflict of interest.

**Funding:** This study was not funded or co-sponsored.

**Authors' contributions:** ESA and DCO designed the study. ESA carried out the data collection and data analysis. GC accomplished statistical analysis of the data. ESA, SK, and DCO wrote the article. ESA reviewed the article. All authors confirmed the final manuscript.

## REFERENCES

1. Bray F, Laversanne M, Sung H, *et al.* (2024) Global cancer statistics 2022: GLOBOCAN estimates of incidence and mortality worldwide for 36 cancers in 185 countries. *CA Cancer J Clin*, **74**(3): 229-263.
2. Uhlenhopp DJ, Then EO, Sunkara T, Gaduputi V (2020) Epidemiology of esophageal cancer: update in global trends, etiology and risk factors. *Clin J Gastroenterol*, **13**(6): 1010-1021.
3. Cooper JS, Guo MD, Herskovic A, *et al.* (1999) Chemoradiotherapy of locally advanced esophageal cancer: long-term follow-up of a prospective randomized trial (RTOG 85-01). Radiation Therapy Oncology Group. *JAMA*, **281**(17): 1623-1627.
4. Shapiro J, van Lanschot JJB, Hulshof M, *et al.* (2015) Neoadjuvant chemoradiotherapy plus surgery versus surgery alone for oesophageal or junctional cancer (CROSS): long-term results of a randomised controlled trial. *Lancet Oncol*, **16**(9): 1090-1098.
5. Wang FM, Mo P, Yan X, Lin XY, Fu ZC (2024) Present situation and prospect of immunotherapy for unresectable locally advanced esophageal cancer during peri-radiotherapy. *World J Gastrointest Oncol*, **16**(1): 1-7.
6. Lan K, Zhu J, Zhang J, *et al.* (2020) Propensity score-based comparison of survival and radiation pneumonitis after definitive chemoradiation for esophageal cancer: Intensity-modulated radiotherapy versus three-dimensional conformal radiotherapy. *Radiother Oncol*, **149**: 228-235.
7. Lin WC, Chang CL, Hsu HL, Yuan KS, Wu ATH, Wu SY (2019) Three-dimensional conformal radiotherapy-based or intensity-modulated radiotherapy-based concurrent chemoradiotherapy in patients with thoracic esophageal squamous cell carcinoma. *Cancers (Basel)*, **11**(10): 1529.

8. Xu C, Xi M, Komaki R, *et al.* (2017) Dosimetric and clinical outcomes after volumetric modulated arc therapy for carcinoma of the thoracic esophagus. *Adv Radiat Oncol*, **2**(3): 325-332.
9. Rao V, Singh S, Zade B (2025) Advances in radiotherapy in the treatment of esophageal cancer. *World J Clin Oncol*, **16**(3): 102872.
10. Luh JY, Albuquerque KV, Cheng C, *et al.* (2020) ACR-ASTRO Practice Parameter for Image-guided Radiation Therapy (IGRT). *Am J Clin Oncol*, **43**(7): 459-468.
11. de Crevoisier R, Lafond C, Mervoyer A, *et al.* (2022) Image-guided radiotherapy. *Cancer Radiother*, **26**(1-2): 34-49.
12. Wang JZ, Li JB, Wang W, *et al.* (2015) Changes in tumour volume and motion during radiotherapy for thoracic oesophageal cancer. *Radiother Oncol*, **114**(2): 201-205.
13. Thomas M, De Roover R, van der Merwe S, Lambrecht M, Defraene G, Haustermans K (2021) The use of tumour markers in oesophageal cancer to quantify setup errors and baseline shifts during treatment. *Clin Transl Radiat Oncol*, **26**: 8-14.
14. Hoffmann L, Poulsen PR, Ravkilde T, *et al.* (2019) Setup strategies and uncertainties in esophageal radiotherapy based on detailed intra- and interfractional tumor motion mapping. *Radiother Oncol*, **136**: 161-168.
15. Li N, Li T-T, Xiang X-Y *et al.* (2023) Effectiveness of oesophageal gastric junction tumour motion with and without a pneumatic abdominal compression belt in the era of precise image-guided radiation therapy. *International Journal of Radiation Research*, **21** (1): 147-151.
16. Matzinger O, Gerber E, Bernstein Z, *et al.* (2009) EORTC-ROG expert opinion: radiotherapy volume and treatment guidelines for neoadjuvant radiation of adenocarcinomas of the gastroesophageal junction and the stomach. *Radiother Oncol*, **92** (2): 164-175.
17. Wu AJ, Bosch WR, Chang DT, *et al.* (2015) Expert consensus contouring guidelines for intensity modulated radiation therapy in esophageal and gastroesophageal junction cancer. *Int J Radiat Oncol Biol Phys*, **92**(4): 911-920.
18. van Herk M (2004) Errors and margins in radiotherapy. *Semin Radiat Oncol*, **14**(1): 52-64.
19. Tian X, Shen Z, Wang S, Liu X, Luo H, Jin F (2024) Dosimetric comparison of different radial and longitudinal margins for tomotherapy in esophageal cancer. *International Journal of Radiation Research*, **22**(2): 387-393.
20. Yamashita H, Haga A, Hayakawa Y, *et al.* (2010) Patient setup error and day-to-day esophageal motion error analyzed by cone-beam computed tomography in radiation therapy. *Acta Oncol*, **49**(4): 485-490.
21. Jin P, van der Horst A, de Jong R, *et al.* (2015) Marker-based quantification of interfractional tumor position variation and the use of markers for setup verification in radiation therapy for esophageal cancer. *Radiother Oncol*, **117**(3): 412-418.
22. Jin P, Hulshof MC, de Jong R, van Hooft JE, Bel A, Alderliesten T (2016) Quantification of respiration-induced esophageal tumor motion using fiducial markers and four-dimensional computed tomography. *Radiother Oncol*, **118**(3): 492-497.
23. Liu F, Ng S, Huguet F, Yorke ED, Mageras GS, Goodman KA (2016) Are fiducial markers useful surrogates when using respiratory gating to reduce motion of gastroesophageal junction tumors? *Acta Oncol*, **55**(8): 1040-1046.
24. Wang W, Li J, Zhang Y, *et al.* (2014) Comparison of patient-specific internal gross tumor volume for radiation treatment of primary esophageal cancer based separately on three-dimensional and four-dimensional computed tomography images. *Dis Esophagus*, **27**(4): 348-354.