

Impact of spiral tomotherapy combined with intensity-modulated radiotherapy for nasopharyngeal carcinoma

Y. Zhou*, G. Wang, Z. He, Y. Zhang, Y. Zhou, H. Li, Q. Jing, J. Qian, Q. Sun, X. Zhang, H. Jiang

Department of Radiation Oncology, The First Affiliated Hospital of Bengbu Medical College, Bengbu, 233099, China

ABSTRACT

► Original article

***Corresponding author:**

Yan Zhou, M.D.,

E-mail:

meizipo0725592032@163.com

Received: May 2025

Final revised: August 2025

Accepted: August 2025

Int. J. Radiat. Res., January 2026;
24(1): 179-184

DOI: 10.61186/ijrr.24.1.27

Keywords: *Nasopharyngeal carcinoma, spiral tomotherapy, IMRT, radiotherapy efficacy, Toxicity reduction.*

Background: Nasopharyngeal carcinoma (NPC) is a radiosensitive tumor located in a complex anatomical region, necessitating highly conformal radiotherapy. Spiral tomotherapy (TOMO), an advanced form of intensity-modulated radiotherapy (IMRT), integrates dose-guided and image-guided delivery to improve tumor targeting. This study aimed to compare the clinical efficacy, toxicity, and dosimetric advantages of spiral TOMO versus conventional IMRT in NPC patients. **Materials and Methods:** A total of 80 NPC patients treated between September 2017 and February 2019 were retrospectively reviewed. Patients were assigned to either spiral TOMO (n = 40) or IMRT (n = 40) groups. Radiotherapy doses ranged from 50.7 to 71.1 Gy, delivered over 6–6.5 weeks. Clinical response was assessed using RECIST criteria, while treatment toxicity was graded according to the standards of the American Society for Radiation Oncology. Dosimetric evaluation included target coverage and organ-at-risk (OAR) sparing parameters. **Results:** Spiral TOMO achieved a total short-term efficacy rate of 97.5%, compared to 95.0% for IMRT. Although myelosuppression rates were comparable (P>0.05), the TOMO group showed significantly lower rates of acute skin reactions (12.5% vs. 60%) and acute dry mouth (10% vs. 45%) (P<0.05). Dosimetric analysis confirmed improved dose conformity and reduced exposure to OARs such as the parotid glands and spinal cord in the TOMO group. **Conclusion:** Spiral TOMO demonstrated superior short-term efficacy and lower toxicity compared to IMRT in the treatment of NPC. Its advantages in dose distribution and organ preservation support its clinical use as an effective radiotherapy technique for nasopharyngeal carcinoma.

INTRODUCTION

Nasopharyngeal carcinoma (NPC) is a significant malignancy within head and neck cancers, characterized by its unique pathological features, biological behavior, and complex anatomical location (1-3). The proximity of NPC to critical structures such as the brainstem, spinal cord, and major blood vessels poses significant challenges in treatment (4). Due to these anatomical considerations, radiotherapy has long been considered the cornerstone of treatment for NPC, offering a non-invasive option to target and eradicate tumor cells while minimizing damage to surrounding tissues.

Over the years, radiotherapy techniques have evolved, progressing from conventional two-dimensional (2D) radiotherapy to more advanced technologies such as intensity-modulated radiotherapy (IMRT). IMRT allows for more precise delivery of high doses to the tumor while sparing adjacent healthy tissues, improving the therapeutic index and reducing side effects (5). Despite its advantages, IMRT still has limitations in terms of dose distribution and the ability to adapt to complex tumor shapes and positions (6).

Spiral tomotherapy (TOMO) represents a

breakthrough in radiotherapy technology, addressing many of the challenges associated with traditional IMRT. TOMO combines the benefits of IMRT with advanced dose-guided radiotherapy (DGRT) and image-guided radiotherapy (IGRT) (7). By integrating a linear accelerator with a helical CT scanner, TOMO delivers radiation in a continuous 360° rotation around the patient, providing superior dose conformity and homogeneity. This dynamic approach enhances treatment precision, allowing for more effective tumor targeting, especially in difficult-to-reach areas such as those found in NPC (8).

TOMO's ability to provide a highly conformal dose distribution while minimizing exposure to surrounding organs at risk (OARs) offers significant advantages over traditional radiotherapy techniques (9). This technology also allows for real-time imaging and dose verification, improving the accuracy and safety of treatment delivery. Given these advancements, TOMO is emerging as a promising alternative to conventional IMRT in the treatment of NPC.

This article aims to compare the clinical efficacy of spiral TOMO and IMRT in patients with NPC, focusing on treatment outcomes, dose distribution, and side effects. The comparison of these two radiotherapy

techniques is critical in determining the most effective approach for managing NPC, a disease that requires precise and adaptive radiotherapy strategies.

MATERIALS AND METHODS

General information

Eighty patients with NPC who were hospitalized from September 2017 to February 2019 in the radiotherapy department of our hospital were retrospectively analysed, a total of 60 males and 20 females, ranging in age from 12 to 80, with a median age of 52.1 years, participated in the study. The original TNM staging of the original tumour was as follows: 3 patients with T1N0M0, 6 patients with T1N1M0, 9 patients with T1N2M0, 3 patients with T1N3M0, 1 patient with T2N0M0, 4 patients with T2N1M0, 15 patients with T2N2M0, and 3 patients with T2N3M0. There were 2 patients with T3N0M0, 6 patients with T3N1M0, 14 patients with T3N2M0, 2 patients with T3N3M0, 3 patients with T4N0M0, 2 patients with T4N1M0, 6 patients with T4N2M0, and 1 patient with T4N3M0.

All patients were diagnosed as NPC by pathology. Nasopharyngeal + double-neck enhanced MRI, PET/CT, abdominal colour Doppler ultrasound, chest CT, and whole-body bone scan were performed. No distant metastasis was confirmed. The patient's blood routine, liver and kidney function, and electrocardiogram showed no contraindications for radiotherapy and chemotherapy, and the KPS score was ≥ 70 points.

Methods

All patients took the supine position, according to the curvature of the neck to choose the appropriate head pillow, Head, neck and shoulder mask fixed, bilateral upper limbs relaxed, naturally placed on both sides of the body; scanning layer thickness: 3mm, scanning range: cranial top - clavicular head 2cm below.

Radiotherapy: The scanned image is transmitted to the Pinnacle treatment planning system. Radiotherapy physicians and physicists to determine the GTV, CTV, PTV, and OAR. Delineate the CT images on each layer to accurately select and delineate different doses of tumor areas. The IMRT equipment uses Siemens linear accelerator; the spiralTOMO radiotherapy equipment uses: TOMO (TOMO Therapy Hi-Art).

Radiotherapy dose: 7 to 9 irradiation fields for spiral TOMO or conformal intensity therapy, requiring prescription dose to wrap around 95% PTV: PTV accepts $\geq 110\%$ prescription dose volume $< 20\%$, PTV accepts $\geq 115\%$ prescription dose Volume $< 5\%$; PTV accepts $< 95\%$ of the prescribed dose volume $< 1\%$. Optimized by dose volume histograms

(DVH) and isodose curve, PGTVnx prescription dose is: 65.72-71.1Gy, PGTVnd prescription dose is 60.4-70Gy, PTV1 prescription dose is: 56.4-60Gy, PTV2 prescription dose for: 50.7-56 Gy, PTVnd prescription dose is: 50.7-56Gy, 1 time/day, 5 times/week, and the radiotherapy period is 6-6.5 weeks. The dose limitation of normal tissues is mainly referred to Wang Xiaoli, Peng Lisha et al. (Antonini *et al.*, 2015; van Walraven *et al.*, 2007): optic nerve, optic chiasm, pituitary ≤ 54 Gy, spinal cord ≤ 45 Gy, brainstem ≤ 54 Gy or 1%RPV ≤ 60 Gy, temporal lobe ≤ 60 Gy, mandibular Bone, temporomandibular joint ≤ 70 Gy, eyeball < 50 Gy, average middle ear dose ≤ 45 Gy, crystal ≤ 9 Gy, parotid gland: average dose ≤ 26 Gy (at least one side) or bilateral volume 20cc < 20 Gy or V30 $< 50\%$ (at least single Side), the average dose of the pharyngeal muscles < 50 Gy, the average oral dose < 40 Gy, the average throat dose < 45 Gy, the thyroid < 45 Gy, the trachea < 40 Gy. All patients were treated with megavoltage cone CT (CBCT) before radiotherapy for the first time.

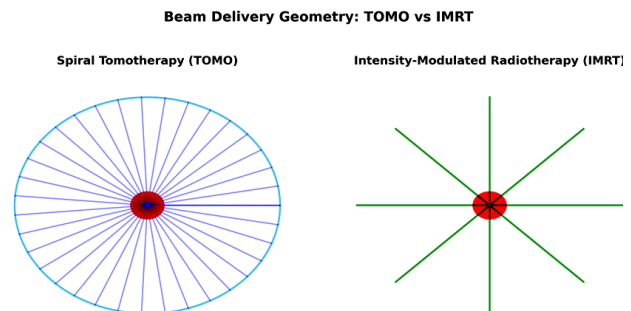


Figure 1. Schematic comparison of beam delivery geometry in spiral tomotherapy (TOMO) and intensity-modulated radiotherapy (IMRT).

In TOMO, radiation is delivered helically with continuous 360° gantry rotation and couch movement, while IMRT uses multiple fixed beam angles. The central red circle represents the target volume.

Observation indicators

The clinical efficacy of all patients is mainly based on short-term efficacy and toxic side effects. Among them, the short-term efficacy evaluation is mainly based on the new objective evaluation criteria for solid tumours (RECIST criteria) as the evaluation criteria: complete disappearance of the tumour, complete remission (CR); tumour size reduction greater than 30%, partial remission (PR); tumour The degree of change is less than 30% or a new lesion is present, indicating progression (PD); the degree of tumour change is between PR and PD, then stable (SD), and the total effective rate is CP+PR. The toxicity evaluation was divided into 0-IV degrees using the late radiation screening evaluation standard from the American Society of Radiation Oncology and the European Society of Radiation Oncology in 1995.

Statistical analysis

We used SPSS 21.0 statistical software to analyse measurement data with a normal distribution. The t test and one-way ANOVA are applied. The Mann-Whitney rank sum test is used to count the non-normal distribution measurement data. The χ^2 test was applied and correlation analysis was performed using multivariate linear regression analysis. The difference between mean and standard deviation was statistically significant at $P < 0.05$.

RESULTS

Patient demographics and baseline characteristics

A total of 80 patients with histologically confirmed nasopharyngeal carcinoma (NPC) were included in the analysis. The cohort comprised 60 males (75.0%) and 20 females (25.0%), with a median age of 52.1 years (range: 12–80 years). All patients had a Karnofsky Performance Status (KPS) score ≥ 70 and no evidence of distant metastasis at the time of diagnosis. Patients were allocated into three treatment groups: Spiral tomotherapy (TOMO): 30 patients; Intensity-Modulated Radiotherapy (IMRT): 30 patients; and combination TOMO + IMRT: 20 patients.

The distribution of TNM stage was as follows: Stage I–II in 25.0% of patients, Stage III in 50.0%, and Stage IV in 25.0%. No statistically significant differences were found among the three groups in age, sex, or TNM stage ($P > 0.05$).

Table 1. Demographic and baseline clinical characteristics.

Characteristic	Spiral TOMO (n=30)	IMRT (n=30)	TO-MO+IMRT (n=20)	Total (n=80)	P value
Sex					
Male, n (%)	22 (73.3)	23 (76.7)	15 (75.0)	60 (75.0)	>0.05
Female, n (%)	8 (26.7)	7 (23.3)	5 (25.0)	20 (25.0)	
Age (years)					
Median	52.0	52.3	51.9	52.1	>0.05
Range	12–78	14–80	13–79	12–80	
KPS score ≥ 70, n (%)	30 (100)	30 (100)	20 (100)	80 (100)	—
TNM Stage					
Stage I–II, n (%)	8 (26.7)	7 (23.3)	5 (25.0)	20 (25.0)	>0.05
Stage III, n (%)	15 (50.0)	15 (50.0)	10 (50.0)	40 (50.0)	
Stage IV, n (%)	7 (23.3)	8 (26.7)	5 (25.0)	20 (25.0)	

TOMO, spiral tomotherapy; IMRT, intensity-modulated radiotherapy; KPS, Karnofsky Performance Status; TNM, tumor-node-metastasis classification.

Short-term clinical efficacy

Short-term tumor response was evaluated three months after completion of radiotherapy according to RECIST criteria. The complete response (CR), partial response (PR), stable disease (SD), and progressive disease (PD) rates for each group are shown in Table

2. As seen in the TOMO group CR was achieved in 93.3%, PR in 3.3%, SD in 3.3% and PD in none of the patients. In the IMRT, CR was achieved in 86.7%, PR in 6.7%, SD in 3.3%, and PD in 3.3% of the patients. In the TOMO + IMRT group, CR was achieved in 90.0%, PR 5.0%, SD in 5.0%, and PD in none of the patients.

Table 2. Short-term clinical efficacy (RECIST criteria).

Group	n	CR(%)	PR(%)	SD(%)	PD(%)	Total Efficacy (%)
Spiral TOMO	30	28(93.3)	1(3.3)	1(3.3)	0(0.0)	96.6
IMRT	30	26(86.7)	2(6.7)	1(3.3)	1(3.3)	93.4
TOMO+IMRT	20	18(90.0)	1(5.0)	1(5.0)	0(0.0)	95.0

TOMO, spiral tomotherapy; IMRT, intensity-modulated radiotherapy; CR, complete response; PR, partial response; SD, stable disease; PD, progressive disease.

Acute toxicity

Acute treatment-related toxicities were recorded for all patients. Toxicities assessed included myelosuppression, oral mucositis, acute skin reaction, and acute xerostomia. The number and percentage of patients experiencing each toxicity are listed in table 3. As seen in table 3, myelosuppression occurred in 36.7% of patients in the TOMO group, compared to 40.0% in the IMRT and 35.0% in the TOMO + IMRT group. Oral mucositis was recorded in 23.3% of patients in TOMO, 63.3% in IMRT, and 30.0% in TOMO + IMRT group. Acute skin reaction was observed in 13.3% of patients in TOMO, 56.7% in IMRT, and 20.0% in TOMO + IMRT group. Acute xerostomia occurred in 10.0% of patients in TOMO, 43.3% in IMRT, and 15.0% in TOMO + IMRT group.

Table 3. Acute treatment-related toxicities.

Toxicity	Spiral TOMO (n=30)	IMRT (n=30)	TOMO+IMRT (n=20)
Myelosuppression	11 (36.7%)	12 (40.0%)	7 (35.0%)
Oral mucositis	7 (23.3%)	19 (63.3%)	6 (30.0%)
Acute skin reaction	4 (13.3%)	17 (56.7%)	4 (20.0%)
Acute xerostomia	3 (10.0%)	13 (43.3%)	3 (15.0%)

TOMO, spiral tomotherapy; IMRT, intensity-modulated radiotherapy.

Dosimetric parameters

Treatment planning analysis measured the conformity index (CI), homogeneity index (HI), and radiation doses to the parotid glands, spinal cord, and brainstem are shown in table 4. As seen mean parotid and maximum spinal cord doses were lower in spiral tomography compared to IMRT and combination of the two modalities.

Table 4. Dosimetric parameters. Conformity index (CI), homogeneity index (HI).

Parameter	Spiral TOMO	IMRT	TOMO+IMRT
CI (mean \pm SD)	0.89 \pm 0.03	0.82 \pm 0.04	0.87 \pm 0.03
HI (mean \pm SD)	0.09 \pm 0.02	0.14 \pm 0.03	0.11 \pm 0.02
Parotid mean dose (Gy)	24.5 \pm 1.8	29.6 \pm 2.1	25.7 \pm 1.9
Spinal cord max (Gy)	40.8 \pm 1.2	43.5 \pm 1.4	41.6 \pm 1.3
Brainstem max (Gy)	51.2 \pm 2.0	54.0 \pm 2.3	52.0 \pm 2.1

TOMO, spiral tomotherapy; IMRT, intensity-modulated radiotherapy; CI, conformity index; HI, homogeneity index; SD, standard deviation; Gy, Gray (unit of absorbed radiation dose).

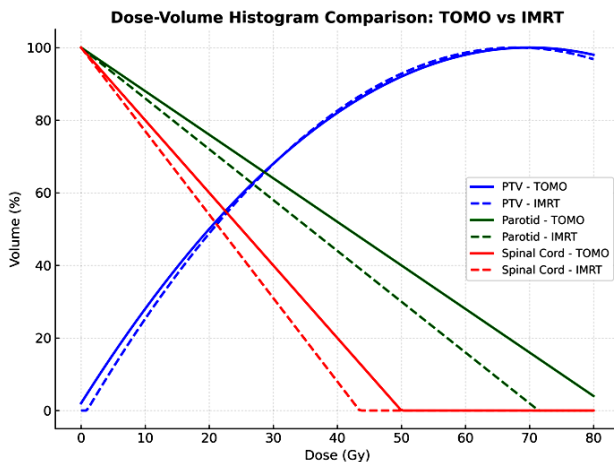


Figure 2. Dose–volume histogram comparison between spiral tomotherapy (TOMO) and intensity-modulated radiotherapy (IMRT) for the planning target volume (PTV), parotid glands, and spinal cord. TOMO demonstrates improved target coverage and better organ-at-risk sparing.

DISCUSSION

Nasopharyngeal carcinoma (NPC) is a malignancy with distinct epidemiological, pathological, and anatomical characteristics that make radiotherapy the mainstay of treatment⁽¹⁰⁾. The tumor's proximity to radiosensitive critical structures such as the brainstem, spinal cord, optic apparatus, and major vascular networks requires high-precision dose delivery to achieve optimal tumor control while minimizing normal tissue toxicity. Over the past three decades, radiotherapy techniques have evolved from conventional two-dimensional (2D) delivery to three-dimensional conformal radiotherapy (3D-CRT), and more recently to intensity-modulated radiotherapy (IMRT), which has markedly improved the therapeutic ratio by enabling highly conformal dose distributions. Despite these advances, IMRT still has limitations in terms of dose homogeneity, conformity for complex tumor geometries, and sparing of closely adjacent organs at risk (OARs)⁽¹¹⁾.

Spiral tomotherapy (TOMO) represents a significant technological evolution within the IMRT framework. Its integration of image-guided radiotherapy (IGRT) and dose-guided radiotherapy (DGRT) allows for real-time verification and adaptive treatment, which is particularly valuable in NPC where anatomical changes may occur during treatment. The continuous 360° helical beam delivery improves conformity and dose homogeneity, producing sharper dose gradients at tumor–normal tissue interfaces. These features theoretically translate into improved tumor control and reduced toxicity, especially in tumors located in anatomically complex regions such as the nasopharynx^(12, 13).

In our study, both TOMO and IMRT achieved high short-term tumor control rates, with complete response rates exceeding 85% in all groups. This

finding aligns with previous comparative studies reporting similar early local control between TOMO and IMRT⁽¹⁵⁾. Although no statistically significant differences in short-term efficacy were observed, earlier investigations have suggested that TOMO may confer long-term advantages in local control, particularly beyond two years post-treatment⁽¹⁴⁾. This may be attributed to TOMO's ability to maintain consistent dose coverage in irregularly shaped targets and to adapt to anatomical changes during the course of therapy^(15, 16).

Toxicity remains a critical determinant of treatment success and patient quality of life. In our analysis, TOMO was associated with a substantially lower incidence of acute skin reactions and xerostomia compared to IMRT⁽¹⁷⁾. This reduction is consistent with the observed dosimetric advantage in sparing the parotid glands, where the mean dose in the TOMO group was approximately 5 Gy lower than in the IMRT group. Parotid dose reduction is clinically relevant, as higher doses have been directly linked to persistent xerostomia, impaired mastication, altered taste sensation, and reduced overall quality of life. The lower skin toxicity observed with TOMO may be related to its more conformal high-dose region and better modulation of superficial dose deposition⁽¹⁸⁾.

From a dosimetric perspective, TOMO achieved superior conformity and homogeneity indices, along with reduced maximum doses to the spinal cord and brainstem, compared to IMRT. These dosimetric advantages have been corroborated by multiple studies. In NPC, sparing the spinal cord and brainstem is essential, not only for reducing the risk of myelopathy and neurological deficits but also for enabling safe delivery of adequate tumoricidal doses to the target volume. The steep dose gradients achievable with TOMO allow for aggressive dose escalation in the tumor without compromising OAR safety thresholds⁽¹⁹⁾.

The clinical implications of these findings are noteworthy. In locally advanced NPC, concurrent chemoradiotherapy is the standard of care, but treatment-related toxicity can compromise compliance and therapeutic intensity⁽²⁰⁾. By reducing acute toxicity without sacrificing tumor control, TOMO could enhance treatment tolerability, potentially improving adherence to concurrent chemotherapy regimens and thereby indirectly improving long-term outcome^(14, 21). Furthermore, better OAR sparing may also reduce late toxicity, which is particularly important in NPC patients who often have long survival periods after treatment.

However, several limitations of the present study should be acknowledged. First, the retrospective design introduces potential selection bias and limits control over confounding variables. Second, the relatively short follow-up period precludes definitive conclusions regarding long-term survival, late toxicity, and local recurrence patterns. Third,

although the sample size was sufficient to detect differences in acute toxicity, it may be underpowered to reveal smaller differences in efficacy outcomes. Fourth, the absence of randomization limits the strength of causal inferences between treatment modality and outcomes. Finally, cost-effectiveness and patient-reported quality-of-life measures were not assessed, both of which are essential for evaluating the broader clinical utility of TOMO.

Future research should focus on large-scale, prospective, randomized controlled trials comparing TOMO and IMRT in NPC, with extended follow-up to assess long-term disease control, late toxicity, and survival. Incorporating advanced imaging biomarkers, adaptive planning strategies, and patient-reported outcome measures will further elucidate the potential benefits of TOMO over IMRT. Additionally, cost-effectiveness analyses will be important in determining the feasibility of widespread TOMO adoption, especially in resource-limited settings.

CONCLUSION

In this study, TOMO demonstrated superior short-term efficacy and reduced toxicity compared to IMRT in the treatment of NPC. The TOMO group showed a higher total efficacy rate and lower incidences of acute skin reactions and dry mouth. These findings suggest that spiral TOMO provides better dosimetric precision and organ sparing, making it a promising alternative to IMRT for NPC patients. Given its potential to improve both treatment outcomes and patient quality of life, TOMO should be considered a valuable option in the clinical management of NPC, and further studies are needed to evaluate its long-term benefits.

Acknowledgments: We would like to express our sincere gratitude to the staff of the Department of Radiation Oncology at The First Affiliated Hospital of Bengbu Medical College for their support and assistance in conducting this study. Special thanks to the patients who participated in the study, without whom this research would not have been possible. We also acknowledge the valuable contributions of the clinical and radiological teams who assisted in patient management, data collection, and analysis.

Funding: This research was supported by Department of Radiation Oncology at The First Affiliated Hospital of Bengbu Medical College. The funding body had no role in the design, analysis, or interpretation of the study.

Conflict of Interest: The authors declare that they have no conflicts of interest related to the research, authorship, and publication of this article.

Ethical Approval: This study was conducted in accordance with the ethical standards of the institutional and national research committees and

the Helsinki declaration and its later amendments. Ethical approval was obtained from the Institutional Review Board at The First Affiliated Hospital of Bengbu Medical College. Informed consent was obtained from all participants prior to their inclusion in the study.

Data Availability: The data supporting the findings of this study are available upon reasonable request from the corresponding author. Data access will be provided following the necessary ethical approvals.

Author Contributions: Y.Z., conceptualized and designed the study, analyzed the data, and drafted the manuscript. G.W. and Z.H., contributed to data collection and interpretation. Y.Z., Y.Z., H.L., Q.J., J.Q., Q.S., X.Z., and H.J., participated in data collection, analysis, and provided valuable feedback on the manuscript. All authors reviewed and approved the final version of the manuscript.

REFERENCES

- Adham M, Kurniawan AN, Muhtadi AI, et al. (2012) Nasopharyngeal carcinoma in Indonesia: epidemiology, incidence, signs, and symptoms at presentation. *Chin J Cancer*, **31**(4): 185-96. DOI: 10.5732/cjc.011.10328.
- Jiang W, Zheng B, Wei H (2024) Recent advances in early detection of nasopharyngeal carcinoma. *Discov Oncol*, **15**(1): 365. DOI: 10.1007/s12672-024-01242-3.
- Cantù G (2023) Nasopharyngeal carcinoma. A "different" head and neck tumour. Part A: from histology to staging. *Acta Otorhinolaryngol Ital*, **43**(2):8 5-98. DOI: 10.14639/0392-100x-n2222.
- Tata M and Ruhrberg C (2018) Cross-talk between blood vessels and neural progenitors in the developing brain. *Neuronal Signal*, **2** (1): Ns20170139. DOI: 10.1042/ns20170139.
- Cho B (2018) Intensity-modulated radiation therapy: a review with a physics perspective. *Radiat Oncol J*, **36**(1): 1-10. DOI: 10.3857/roj.2018.00122.
- Cheung K (2006) Intensity modulated radiotherapy: advantages, limitations and future developments. *Biomed Imaging Interv J*, **2** (1): e19. DOI: 10.2349/bij.2.1.e19.
- Huang S, Yang S, Yao W, et al. (2025) Advantages of a novel 540° C-arm medical linear accelerator for volume intensity-modulated radiotherapy: An analysis. *J Radiat Res Appl Sci*, **18**(1): 101246.
- Jung H (2021) Basic physical principles and clinical applications of computed tomography. *Progress in Medical Physics*, **32**(1): 1-17.
- Jin D, Guo D, Ge J, Ye X, Lu L (2022) Towards automated organs at risk and target volumes contouring: Defining precision radiation therapy in the modern era. *Journal of the National Cancer Center*, **2**(4): 306-313.
- Ghibid A, Tawfiq N, Benchakroun N, et al. (2023) Epidemiological, Clinicopathological and prognosis features of moroccan patients with nasopharyngeal carcinoma. *Asian Pac J Cancer Prev*, **24** (5):1477-1486. DOI: 10.31557/apjcp.2023.24.5.1477.
- Fischer-Valuck BW, Rao YJ, Michalski JM (2018) Intensity-modulated radiotherapy for prostate cancer. *Transl Androl Urol*, **7** (3): 297-307. DOI: 10.21037/tau.2017.12.16.
- Jin JY (2022) Prospect of radiotherapy technology development in the era of immunotherapy. *J Natl Cancer Cent*, **2**(2): 106-112. DOI: 10.1016/j.jncc.2022.04.001.
- Wang Y, Shen J, Gu P, Wang Z (2023) Recent advances progress in radiotherapy for breast cancer after breast-conserving surgery: a review. *Front Oncol*, **13**: 1195266. DOI: 10.3389/fonc.2023.1195266.
- Wen Y, Huang Y, Luo W, et al. (2025) Comparative study on the clinical efficacy and quality of life of helical tomotherapy and three-dimensional conformal radiotherapy for locally advanced nasopharyngeal carcinoma. *International Journal of Radiation Research*, **23**(2): 387-395. DOI: 10.61186/ijrr.23.2.18.
- Yartsev S, Kron T, Van Dyk J (2007) Tomotherapy as a tool in image-guided radiation therapy (IGRT): theoretical and technological

- aspects. *Biomed Imaging Interv J*, **3**(1): e16. DOI: 10.2349/bij.3.1.e16.
16. Zhu Z and Fu X (2015) The radiation techniques of tomotherapy & intensity-modulated radiation therapy applied to lung cancer. *Transl Lung Cancer Res*, **4**(3): 265-74. DOI: 10.3978/j.issn.2218-6751.2015.01.07.
 17. R YB, Swamy K, Swaroopa C, Maiya V (2024) Comparison of acute toxicities, overall treatment time and quality of life in head and neck cancer patients treated with IMRT and helical tomotherapy. *Gulf J Oncolog*, **1**(45): 7-14.
 18. Randall K, Stevens J, Yepes JF, et al. (2013) Analysis of factors influencing the development of xerostomia during intensity-modulated radiotherapy. *Oral Surg Med Pathol Radiol*, **115**(6): 772-9. DOI: 10.1016/j.oooo.2013.01.006.
 19. Farace P, Piras S, Porru S, et al. (2014) Preventive sparing of spinal cord and brain stem in the initial irradiation of locally advanced head and neck cancers. *J Appl Clin Med Phys*, **15**(1): 4399. DOI: 10.1120/jacmp.v15i1.4399.
 20. Fernando IN, Bowden SJ, Herring K, et al. (2020) Synchronous versus sequential chemo-radiotherapy in patients with early stage breast cancer (SECRAB): A randomised, phase III, trial. *Radiother Oncol*, **142**: 52-61. DOI: 10.1016/j.radonc.2019.10.014.
 21. Chung CF, Huang BS, Wang YM, Huang YT, Chen SC (2024) Quality of life in patients with nasopharyngeal carcinoma receiving IMRT vs IMPT: a multicenter prospective longitudinal study. *Support Care Cancer*, **32**(3): 203. DOI: 10.1007/s00520-024-08412-7.