

Value of quantitative MRI combined with blood CTC in predicting the prognosis of neoadjuvant chemotherapy for breast cancer

W. Junwu^{1*}, L. Yi², T. Lidong³, L. Qichao⁴

¹Department of Breast Surgery, Chengdu Xinhua Hospital, Chengdu, Sichuan, China

²Ultrasound Department, Air Force Hospital of Western Theater Command, PLA, Chengdu, Sichuan, China

³Department of Radiology, Air Force Hospital of Western Theater Command, PLA, Chengdu, Sichuan, China

⁴Department of Radiology, Jinhua Maternal and Child Health Hospital, Jinhua, China

ABSTRACT

► Original article

*Corresponding author:

Wang Junwu, M.D.,

E-mail: wangjunwudf@163.com

Received: November 2024

Final revised: June 2025

Accepted: July 2025

Int. J. Radiat. Res., January 2026;
24(1): 193-198

DOI: 10.61186/ijrr.24.1.29

Keywords: Breast neoplasms, neoadjuvant therapy, magnetic resonance imaging, circulating tumor cell.

Background: To analyze the value of quantitative parameters of magnetic resonance imaging (MRI) combined with circulating tumor cells (CTC) in predicting the prognosis of neoadjuvant chemotherapy (NAC) for breast cancer. **Materials and Methods:** Ninety-eight breast cancer patients treated with NAC from January 2022 to January 2024 at our institution were collected. Pathological complete remission (pCR) was evaluated 2 weeks after the end of NAC. According to pCR, the patients were divided into pCR group (n=34) and non-pCR group (n=64). The volume transfer constant (Ktrans), extravascular extracellular space volume ratio (Ve), rate constant (Kep), and positive rate of CTC were compared between the two groups before and after treatment. The area under the receiver operating characteristic (ROC) curve (AUC) was used to express the prognostic value. **Results:** Among the 98 patients, 34 patients achieved pCR, with a rate of 34.69%. After treatment, Ktrans, Kep, and positive rate of CTC were lower than those before treatment (P<0.05), and were lower in the pCR group than in the non-pCR group (P<0.05). Ktrans, Kep, and positive rate of CTC were positively correlated with TNM staging (P<0.05). The AUCs of Ktrans, Kep, and positive rate of CTC joint prediction for predicting pCR after NAC for breast cancer was 0.847, which was larger than separate prediction. The sensitivity and specificity of joint prediction were 67.65% and 90.38%. **Conclusion:** The quantitative MRI indexes combined with blood CTC can effectively predict NAC prognosis in breast cancer patients.

INTRODUCTION

Breast cancer is one of the most common malignant tumors in women worldwide, with high morbidity and mortality rates, especially increasing in low- and middle-income countries⁽¹⁾. Neoadjuvant chemotherapy (NAC) is a core part of breast cancer treatment, NAC has been in clinical practice. Through NAC treatment, tumor volume can be reduced before surgery, thus providing the possibility for breast-conserving surgery, and the sensitivity of the tumor to chemotherapy can be evaluated, further helping to guide treatment strategies⁽²⁾. Pathologic complete response (pCR) is considered an important marker of NAC efficacy and is closely related to the patient's survival rate and risk of recurrence^(3, 4). The evaluation of pCR is crucial for the treatment decision-making of breast cancer patients. Magnetic resonance imaging (MRI), as a non-invasive imaging technology, has become an important method of breast cancer diagnosis and efficacy evaluation due to its better soft tissue resolution and multi-parameter imaging capabilities. Studies have shown that quantitative MRI parameters, such as volume transfer

constant (Ktrans), extravascular extracellular space volume ratio (Ve) and rate constant (Kep), can reflect tumor blood flow, vascular permeability and extracellular space volume, and provide valuable biological indicators for predicting chemotherapy efficacy⁽⁵⁾. In addition, circulating tumor cells (CTCs), as cells that shed from primary tumors or metastatic lesions and enter peripheral blood, have attracted much attention in tumor prognosis evaluation in recent years⁽⁶⁾. Studies have shown that CTC is closely related to the invasiveness and metastasis risk of tumors, and can serve as a potential biomarker to assist in predicting the efficacy of NAC and the long-term survival of patients^(7, 8). However, relying solely on MRI or CTC to evaluate the efficacy of NAC still has certain limitations. Therefore, combining MRI quantitative parameters with CTC to predict the efficacy of NAC may provide a more accurate and personalized prognostic assessment for breast cancer patients. We aim to explore the value of MRI quantitative parameters combined with blood CTC detection in predicting the efficacy of NAC in breast cancer patients, and to provide a new evaluation tool for personalized treatment of breast cancer.

MATERIALS AND METHODS

Objective

Ninety eight patients who were first diagnosed with breast cancer and received NAC treatment at the researcher's hospital between January 2022 and January 2024 were collected. This study was approved by the Ethics Committee of the Jinhua Maternal and Child Health Hospital (2021 Lunar Review KY No. 018). Informed consent was obtained from all the participants. All methods were carried out in accordance with Declaration of Helsinki.

Inclusion criteria: (1) Pathologically confirmed as primary breast cancer without distant metastasis. (2) Received NAC treatment. (3) Aged between 18 and 75 years old. (4) All underwent at least two MRI imaging examinations. (5) With well-recorded clinical data.

Exclusion criteria: (1) Patients who had received other breast cancer-related treatments before NAC treatment, such as radiotherapy, targeted therapy, or surgery. (2) Patients with severe comorbidities or who were not suitable for chemotherapy, such as patients with severe damage to the heart, liver, kidney and other organ functions. (3) Allergic to the chemotherapy drugs in the study. (4) History of other malignant tumors. All 98 patients were female, aged 23-74 years, with an average age of (47.51 ± 10.36) years. 62 patients were postmenopausal, with a BMI range of 18.5-30.5 kg/m² and an average BMI of (24.6 ± 2.13) kg/m². Before NAC, TNM stage II-III, 23 patients in stage II, and 75 patients in stage III. Tumor pathology types included 89 patients with invasive ductal carcinoma, 7 patients with invasive lobular carcinoma, and 2 patients with mucinous breast carcinoma. There were 14 patients with a family history of breast cancer.

NAC treatment methods and efficacy assessment

Fifty-five patients received AC (doxorubicin + cyclophosphamide), 33 received TCbHP (docetaxel + carboplatin + pertuzumab), 6 received TC (docetaxel + cyclophosphamide), and 4 received TAC (paclitaxel + doxorubicin + cyclophosphamide). Each course lasts 21 days, and 4 to 6 courses were given. MRI examination was performed 4 weeks after the end of the NAC cycle, and the patient received modified radical mastectomy in this hospital. The pathological efficacy was evaluated according to the RECIST 1.1 standard. Complete remission (CR) and partial remission (PR) were included in the effective treatment group, and stable disease (SD) and progressive disease (PD) were included in the ineffective treatment group. CR definition: all measurable tumor lesions disappeared. And the condition lasted for at least four weeks. PR definition: at least 30% of tumor lesions shrank, and the duration was at least four weeks. SD definition: no obvious tumor shrinkage and no disease progression, the change of tumor lesions was between -29% and

+20%, and the condition lasted for at least four weeks. PD definition: tumor lesions increased by at least 20% or new lesions appeared, and the duration was at least four weeks⁽⁶⁾.

MRI methods

Before the examination, the patient's general information was checked and all metal objects (such as jewelry, watches, etc.) were asked to be removed to avoid affecting the scan. The SIGNA Pioneer 3.0 T superconducting MRI instrument and breast-specific coil of GE Company were used. The subjects were supinely lying on the MRI scanner, with their hands raised and placed above their heads. The single-shot spin echo (SS-EPI) sequence was used, and the diffusion sensitivity coefficient (b) was set to 0 and 800 s/mm². The scanning parameters were as follows: time of echo (TE) 85 ms, repetition time (TR) 5587 ms, matrix 128×128, layer thickness is 4 mm, and layer interval is 1 mm. Gadopentetate dimeglumine 0.1 mmol/kg was injected at a rate of 2-3 ml/s, and the patient was rinsed with 20-30 mL of normal saline. T1-weighted imaging (T1WI) and T2-weighted imaging (T2WI) were performed. A mask was scanned before contrast agent injection, and then continuous scanning without interval was performed, for a total of 35 phases. Scanning parameters: TE 2.23 ms, TR 5.128 ms, layer thickness 2 mm, matrix 512×512, flip angle 10°, and the entire dynamic scanning time is generally 15 min. After the examination, the MRI images were imported into GE's post-processing software GenIQ for perfusion image reconstruction. The region of interest was outlined around the ducts and chest wall infiltration range around the main body of the lesion, avoiding the necrotic area and blood vessels of the lesion. The K_{trans} , V_e , and K_{ep} of the tumor were calculated based on the DCE-MRI time-signal intensity curve (TIC), and background-removed images and maximum intensity projection (MIP) images were generated in the 15th to 20th phase of the enhancement. The imaging results were analyzed by two radiologists with more than 8 years of experience. If there were different opinions, the senior physicians would read the films together until they reach a consensus. Sample DCE-MRI images studied is shown as figure 1.

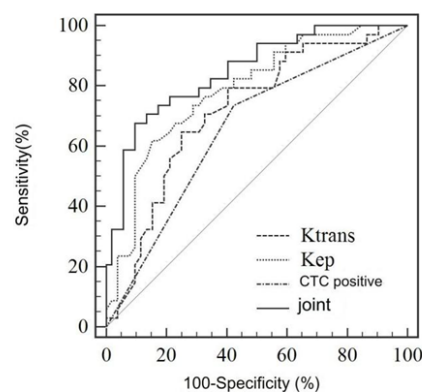


Figure 1. ROC curve of MRI quantitative index combined with CTC positivity in predicting the efficacy of NAC in breast cancer.

Blood CTC detection methods

1.5 mL peripheral blood sample was collected from the patient's vein using a blood collection tube containing an anticoagulant, 20 μL of immunomagnetic balls were added and shaken. It was incubated at 37°C at 150 rpm for 30 min, the sample was placed on a magnetic stand for 5 min. The supernatant was removed, 400 μL of 4% paraformaldehyde was added for resuspending. The sample was placed at room temperature for 10 min. The supernatant was removed after 3 min of aspiration. The sample was added with a permeabilization blocking solution for resuspending. The sample was placed at room temperature for 20 min, the supernatant was removed after 3 min of aspiration. The staining solution [composed of 4',6-diamidino-2-phenylindole (DAPI), cytokeratin antibody (cytokeratin 19, CK19), and anti-leukocyte common antigen antibody (Leukocyte common antigen, CD45)] was added, and the sample was incubated at 37°C in the dark for 30 min. The supernatant was removed after 3 min of aspiration. 200 μL of 4% paraformaldehyde was added for resuspending. It was resuspended in 200 μL phosphate buffer and washed 3 times. Transfer the sample to a 96-well plate and observe it under an inverted fluorescence microscope after magnetic enrichment to the bottom. DAPI+/CK19+/CD45- were CTC positive. The kit is provided by Wuhan Jiayuan Quantum Dot Technology Development Co., Ltd.

Pathological evaluation of breast cancer

Data such as patient age, TNM Classification, tumor pathological type, and whether axillary lymph nodes were positive were collected and observed. Immunohistochemistry was used to detect ER, PR, and HER-2. Fresh tumor tissues from breast cancer patients were obtained through pathological examination, fixed in 10% neutral buffered formaldehyde for 24 h, and then embedded in paraffin after dehydration to make paraffin blocks. The paraffin-embedded tissue blocks were cut into thin slices with a thickness of 3-5 μm using a microtome and transferred to a microscope slide with a slide. The slices were heated in an oven at 60°C, then dewaxed twice with xylene, rehydrated with different concentrations of alcohol (such as 100%, 95%, and 70%), and washed with distilled water. The sections were treated with a blocking agent. Then we diluted the primary antibodies for ER, PR, and HER-2 and applied them evenly on the sections. And they were incubated overnight at 4°C. We washed the sections with phosphate buffer, add the secondary antibody, and wash the sections again. Use diaminobenzidine to develop color, observe the sections under a microscope, and set up positive and negative control sections. ER monoclonal antibody was provided by Wuhan Sanying Biotechnology Co.,

Ltd., PR and HER-2 monoclonal antibodies were provided by Fuzhou Maixin Biotechnology Development Co., Ltd. Result judgment: According to the proportion of positive cells, ER and PR \geq 1% are positive, according to the staining intensity and the distribution of brown-yellow particles on the cell membrane, HER-2 3+ is positive, and all results with 2+ were further confirmed by fluorescence *in situ* hybridization.

Observation indicators

The positive rates of K_{trans} , V_e , K_{ep} , and CTC in breast cancer patients before and after NAC treatment were compared, and the positive rates of K_{trans} , V_e , K_{ep} , and CTC in the effective group and the ineffective group at the last treatment were compared. Correlation analysis (Pearson and Spearman correlation coefficients) was used to evaluate the relationship between K_{trans} , K_{ep} , and CTC positivity and clinical pathological factors at the last treatment. The receiver operating characteristic (ROC) curve of K_{trans} , K_{ep} , and CTC positivity in predicting the efficacy of NAC for breast cancer was drawn, and the predictive efficacy of K_{trans} , K_{ep} , and CTC positivity was evaluated by the area under curve (AUC), sensitivity, and specificity.

Statistical analysis

Data analysis was performed using SPSS 26.0. Enumeration data were expressed as n (%), and the χ^2 test was used for inter-group comparison. Measurement data were expressed as mean \pm standard deviation ($\bar{x} \pm s$), and the two groups were compared using an independent sample *t*-test. ROC curves and AUCs were used to evaluate the predictive efficacy of MRI quantitative parameters combined with blood CTC for the efficacy of NAC in breast cancer. $P < 0.05$ was considered statistically significant.

RESULTS

Patient prognosis

47 out of 98 patients were effectively treated, with a treatment efficacy rate of 47.96 %.

2.2 Comparison of MRI quantitative indicators and blood CTC before and after treatment

After treatment, K_{trans} and K_{ep} were 2.46 ± 0.26 and $3.28 \pm 0.14 \text{ min}^{-1}$, respectively, which were lower than before treatment (3.97 ± 0.34 and $5.57 \pm 0.21 \text{ min}^{-1}$, $P < 0.05$). The CTC positive rate after treatment was 45.35%, which was lower than before treatment (68.60%, $P < 0.05$) (table 1).

Comparison of MRI quantitative indicators and blood CTC between the two groups

The K_{trans} and K_{ep} of the pCR group were 0.87 ± 0.21 and $0.39 \pm 0.16 \text{ min}^{-1}$, respectively, which were lower than those of the Non-pCR group

(3.93±1.27 and 0.86±0.19 min⁻¹, P<0.05). The CTC positive rate of the pCR group was 26.47%, which was lower than that of the Non-pCR group (57.69%, P<0.05) (table 2).

Table 1. Comparison of MRI quantitative indicators and blood CTC before and after treatment.

Group	K _{trans} (min ⁻¹)	V _e	K _{ep} (min ⁻¹)	CTC positive
Before treatment (n=98)	3.97±0.34	5.57±0.12	0.81±0.21	59(68.60)
After treatment (n=98)	2.46±0.26	3.28±0.14	0.63±0.17	39(45.35)
t	5.705	1.509	18.453	9.487
P	<0.001	0.133	<0.001	0.002

Table 2. Comparison of MRI quantitative indicators and blood CTC between the two groups.

Group	K _{trans} (min ⁻¹)	V _e	K _{ep} (min ⁻¹)	CTC positive
Effective treatment group (n= 47)	0.87±0.21	2.59±0.31	0.39±0.06	9(26.47)
Ineffective treatment group (n= 51)	3.93±1.27	3.92±1.13	0.86±0.19	30(57.69)
t	16.308	7.800	16.224	8.086
P	<0.001	0.154	<0.001	0.004

The relationship between MRI quantitative indicators, blood CTCs and clinical pathological factors

K_{trans}, K_{ep}, and CTC positive rates were all positively correlated with TNM staging (P<0.05), but had no significant correlation with age, tumor pathological type, axillary lymph node positivity, ER positivity, PR positivity, and HER-2 positivity (P >0.05) (table 3).

Table 3. Relationship between MRI quantitative indicators, blood CTCs and clinical pathological factors.

Clinicopathological factors	K _{trans}		K _{ep}		CTC	
	r	P	r	P	r	P
age	0.105	0.432	0.095	0.410	0.102	0.412
TNM staging	0.372	0.027	0.423	<0.001	0.395	0.020
Tumor pathology type						
Invasive ductal carcinoma	0.182	0.210	0.114	0.350	0.143	0.290
Invasive lobular carcinoma	0.058	0.670	0.067	0.610	0.079	0.530
Mucinous breast carcinoma	0.149	0.295	0.152	0.270	0.186	0.170
Positive axillary lymph nodes						
ER-positive	0.086	0.500	0.128	0.320	0.095	0.460
PR positive	0.140	0.310	0.078	0.520	0.120	0.340
HER-2 positive	0.220	0.095	0.194	0.150	0.175	0.210

Predictive efficacy of MRI quantitative indicators combined with CTC positivity for the efficacy of NAC in breast cancer

The AUC values of K_{trans}, K_{ep}, and CTC positivity for predicting the efficacy of NAC in breast cancer patients were 0.717, 0.785, and 0.656, respectively. The sensitivities were 64.71%, 61.76%, and 73.53%, and the specificities were 75.00%, 84.62%, and 57.69%, respectively. The AUC value of combined

prediction was 0.847, which was higher than that of a single indicator. The sensitivity and specificity were 67.65% and 90.38%, respectively (table 4 and figure 2).

Table 4. Predictive efficacy of MRI quantitative indexes combined with CTC positivity for NAC efficacy in breast cancer.

project	AUC	95% CI	Cutoff value	Sensitivity (%)	Specificity (%)
K _{trans}	0.717	0.609~0.809	0.94	64.71	75.00
K _{ep}	0.785	0.683~0.866	0.45	61.76	84.62
CTC positive	0.656	0.546~0.755	-	73.53	57.69
Joint Forecast	0.847	0.754~0.916	-	67.65	90.38

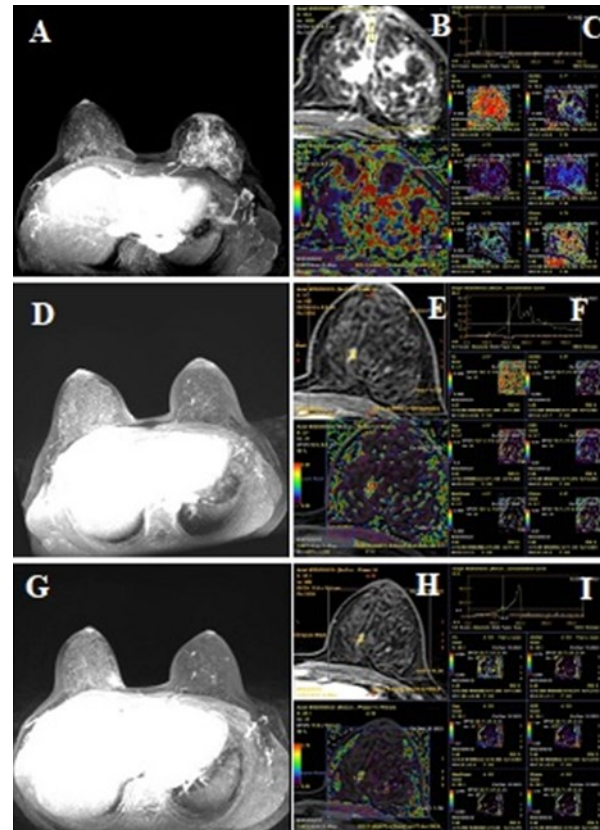


Figure 2. DCE-MRI images of patients with effective breast cancer treatment. 1A-1C: T1WI enhanced images and MRI quantitative parameters before NAC treatment; 1D-1F: T1WI enhanced images and MRI quantitative parameters after the first NAC treatment; 1G-1I: T1WI enhanced images and MRI quantitative parameters after the last NAC treatment.

DISCUSSION

NAC has been an important means of the treatment strategy for patients with breast cancer. By reducing the size of the tumor, it enables patients who are not suitable for surgery or cannot preserve their breasts to choose breast-conserving surgery, thereby improving their quality of life and psychological state (9). The efficacy of NAC is closely related to the patient's long-term survival rate. Patients with better efficacy usually have better long-term survival rate and recurrence rate. MRI is one of the important means to evaluate the efficacy of NAC.

It can provide detailed imaging information of the tumor, including tumor size, morphology, boundaries and surrounding tissues. It can also objectively evaluate the tumor's response to NAC through quantitative indicators, thereby accurately evaluating the treatment effect and tumor response, and guiding subsequent treatment^(10,11). CTC is a cancer cell that has developed from the primary tumor or metastatic tumor then entered the circulation system. It has been reported that CTC positivity is a risk factor for poor efficacy of NAC for breast cancer⁽¹²⁾. Improving the treatment efficacy is one of the key goals of NAC treatment for breast cancer, so finding accurate predictive factors becomes crucial⁽¹³⁾.

In this study, 47 out of 98 patients achieved effective treatment, with an effective rate of 47.96%, which has a large room for improvement. K_{trans} , V_e , and K_{ep} are important quantitative parameters in DCE-MRI. K_{trans} refers to the rate at which contrast agents in blood vessels are transferred to tumor tissues, reflecting tumor vascular permeability. Higher K_{trans} values are usually associated with high blood flow and high metabolic activity in tumors, and are often used to predict tumor aggressiveness and chemotherapy response. V_e refers to the volume ratio of extracellular space outside blood vessels in tumor tissues, reflecting tumor interstitial properties. Higher V_e values are related to edema or increased extracellular matrix in tumor tissues. K_{ep} refers to the rate at which contrast agents return from tumor tissues to blood vessels, reflecting the rate of drug excretion. Lower K_{ep} values indicate that tumors have higher drug uptake and retention, which is usually associated with the malignancy of the tumor and chemotherapy sensitivity⁽¹⁴⁾. The study also found that the positive rates of K_{trans} , K_{ep} and CTC in the effective group were lower than those in the ineffective group. The K_{trans} in the effective group was significantly reduced, indicating that the transfer rate of tumor contrast agent from blood vessels to tumor tissue was reduced, indicating that the tumor volume was reduced and Tumor cells were reduced, and the K_{ep} of the treatment-effective group was also significantly reduced, reflecting the slowdown in the return rate of contrast agent from tumor tissue to blood vessels, which means that tumor cells retain chemotherapy drugs longer, thereby promoting the treatment effect. The reduction in the CTC positivity rate indicates a decrease in the number of CTCs in the blood, further supporting the reduction of tumor burden and the effectiveness of treatment. The results of this study are consistent with previous studies. Du *et al.*⁽¹⁵⁾ also found that the proportion of CTC-negative patients in the pCR-acquired group of breast cancer patients was higher than that in the pCR-unacquired group. The results of this study are consistent with them.

This study further explored the relationship

between MRI quantitative indicators, blood CTC and clinical pathological factors, and found that K_{trans} , K_{ep} , CTC positivity rate and TNM classification were all positively correlated. The increase in K_{trans} value reflects that tumor vascular permeability and activity increase with the progression of tumor stage, suggesting that advanced tumors may have higher metabolic requirements and blood supply. The increase in K_{ep} value indicates that the reflux rate of tumor contrast agent also increases with the increase of tumor stage, which may be related to changes in the tumor microenvironment and vascular remodeling. The increase in CTC positivity rate reflects that with the improvement of TNM classification, the number of circulating tumor cells increases, which may be related to the enhancement of tumor invasiveness and metastasis ability⁽¹⁶⁾. Zhang *et al.*'s⁽¹⁷⁾ study also showed that CTC positivity rate has a significant correlation with TNM Classification. The ROC curve results of this study show that the AUC values of K_{trans} , K_{ep} , and CTC for positively predicting the effectiveness of NAC treatment in breast cancer patients are 0.717, 0.785, and 0.656 respectively. The AUC value of joint prediction is 0.847, and the sensitivity and specificity are 67.65% and 90.38%. the predictive value is greatly improved, indicating that MRI quantification combined with blood CTC detection has significant value in predicting the prognosis of breast cancer NAC, which is similar to the results of studies such as Yang *et al.*⁽¹⁸⁾. The shortcomings of this study are that it was only conducted in a single hospital, and the results may be affected by the specific population and treatment plan of the hospital. There is a lack of multicenter data verification, and the follow-up time is relatively short, which cannot fully evaluate the long-term efficacy and survival rate after NAC. Future studies require larger sample sizes and multicenter designs, and consider more comprehensive clinical factors to further verify the value of MRI quantitative indicators and CTC in the prognostic evaluation of breast cancer NAC.

Acknowledgment: Not applicable

Data Availability: The experimental data used to support the findings of this study are available from the corresponding author upon request.

Conflicts of Interest: The authors declared that they have no conflicts of interest regarding this work.

Funding: This study was supported by the Jinhua Key Science and Technology Program Project (No.2021-3-134) also Jinhua Science and Technology Research Program Project (No.2012-4-234).

Authors' contribution: All authors contributed equally to all aspects of this work. Also all authors read and approved the final manuscript submitted for publication.

REFERENCES

1. Benitez Fuentes JD, Morgan E, de Luna Aguilar A, et al. (2024) Global stage distribution of breast cancer at diagnosis: A systematic review and meta-analysis. *JAMA Oncol*, **10**(1): 71-78.
2. Aldrich J, Canning M, Bhawe M (2023) Monitoring of triple negative breast cancer after neoadjuvant chemotherapy. *Clin Breast Cancer*, **23**(8): 832-834.
3. Houvenaeghel G, de Nonneville A, Cohen M, et al. (2024) Neoadjuvant chemotherapy for breast cancer: Pathologic response rates but not tumor size, has an independent prognostic impact on survival. *Cancer Med*, **13**(3): e6930.
4. Nanda R, Liu MC, Yau C, et al. (2020) Effect of pembrolizumab plus neoadjuvant chemotherapy on pathologic complete response in women with early-stage breast cancer: An analysis of the ongoing phase 2 adaptively randomized I-SPY2 trial. *JAMA Oncol*, **6**(5): 676-684.
5. Zhang Q, Dai S, Shao Y (2023) Relationship between DCE-MRI quantitative parameters Ktrans, Kep, Ve values and molecular classification and prognosis of breast cancer. *Journal of Clinical Pathology*, **43**(10): 1778-1785.
6. Park HA, Brown SR, Kim Y (2020) Cellular mechanisms of circulating tumor cells during breast cancer metastasis. *Int J Mol Sci*, **21**(14): 5040.
7. Alkhafaji S, Wolf DM, Magbanua MJM, et al. (2024) Circulating tumor cells in early lobular versus ductal breast cancer and their associations with prognosis. *NPI Breast Cancer*, **10**(1): 17.
8. Fabisiewicz A, Szostakowska-Rodzons M, Zaczek AJ, et al. (2020) Circulating tumor cells in early and advanced breast cancer; biology and prognostic value. *Int J Mol Sci*, **21**(5): 1671.
9. Wang P, Peng Y, Wang X, et al. (2021) Effects of neoadjuvant chemotherapy CAF regimen combined with breast-conserving surgery on immune function and short-term prognosis in patients with breast cancer. *Journal of Hunan Normal University (Medical Edition)*, **18**(4): 201-204.
10. Zhao Q, Su T, Dai T, et al. (2024) Prediction of sensitivity of neoadjuvant therapy for breast cancer based on multi-parameter MRI radiomics combined with clinical pathological variables. *Magnetic Resonance Imaging*, **15**(6): 79-86.
11. Li M, Liu Y, Zhao F, et al. (2023) Predictive value of IVIM-DWI combined with DCE-MRI for Nottingham index of breast cancer. *Radiological Practice*, **38**(12): 1548-1553.
12. Yang Q and Di G (2024) The predictive value of serum circulating tumor cells combined with clinical characteristics for the effect of neoadjuvant therapy for breast cancer. *Chinese Journal of Experimental Surgery*, **41**(3): 627.
13. Xiang A, Zhou T, Ding J, et al. (2021) Evaluation of clinical pathological features based on logistic regression and nomogram to predict the clinical value of pathological complete remission of breast cancer after neoadjuvant chemotherapy. *Chinese Journal of Endocrine Surgery*, **15**(2): 122-127.
14. Wang W, Liu Y, Li Y, et al. (2024) Feasibility study of DCE-MRI in predicting pathological complete remission after NAC treatment of breast cancer. *Chinese Journal of CT and MRI*, **22**(7): 114-117.
15. Du X, Ma X, Zhou H, et al. (2023) The predictive value of serum CTC combined with clinical characteristics for the effect of neoadjuvant therapy for breast cancer. *Chinese Journal of Modern Medicine*, **33**(5): 1-8.
16. Lian J, Xi Y, Ma H, et al. (2021) Correlation between circulating tumor cells/cell populations and clinical pathological characteristics of breast cancer patients and prognostic analysis. *Chinese Journal of Drugs and Clinics*, **21**(21): 3629-3631.
17. Zhang J, Yang M, Peng W, et al. (2021) Relationship between circulating tumor cell positive rate and prognosis in breast cancer patients. *Journal of China-Japan Friendship Hospital*, **35**(1): 24-27.
18. Yang S, Zhang D, Han X, et al. (2024) Analysis of the diagnostic value and prognostic prediction value of dynamic enhanced MRI quantitative parameters combined with CA15-3 and peripheral blood CTC for breast cancer. *Progress in Modern Biomedicine*, **24**(8): 1468-1472.