

Sinonasal Teratocarcinosarcoma; Report of a case

A. Kazemian^{*}, H.R. Dehghan Manshadi, M. Sardari Kermani

Department of Radiation Oncology, Cancer Institute, Tehran University of Medical Sciences, Tehran, Iran

ABSTRACT

Sinonasal teratocarcinosarcoma (SNTCS) is a rare tumor characterized by mixture architecture of epithelial and mesenchymal components. SNTCS is a highly malignant tumor displaying progressive and aggressive growth with poor prognosis. Only about 40% of all patients survive after five years. It seems the combination of surgery and radiotherapy currently is the most effective treatment. In this report we are presenting a 24-year-old Iranian male with SNTCS of right nasal cavity and paranasal sinuses who was referred to our radiotherapeutic Oncology department, Tehran cancer institute, for post operative radiation treatment. The patient is treated with combination of surgical excision, postoperative radiation therapy and then followed for 10 months. The clinical and pathologic features, as well as its clinical course are presented. SNTSC is a rare condition and rapid progressive tumor. So far, the most widely accepted therapeutic plan for its treatment has been surgical excision with postoperative radiation therapy. *Iran. J. Radiat. Res., 2004; 2 (3): 159-162*

Keywords: *Sinonasal teratocarcinosarcoma, teratoid carcinosarcoma.*

INTRODUCTION

Sinonasal teratocarcinosarcoma (SNTSC) is a rare condition and rapid progressive tumor that displays combined features of an immature or malignant teratoma and carcinosarcoma of histological complexity, admixed with diverse levels of maturity and atypia (Endo *et al.* 2001). A morphologically distinct but histogenetically obscure malignant neoplasm of the sinonasal tract was described by Shanmugaratnam *et al.* in 1983, under the term of teratoid carcinosarcoma (Chao *et al.* 2004).

Heffner and Hyams later reported a series of similar cases (Heffner and Hyams 1984). Both papers, however, pointed out that similar tumors had been documented before in the literature un-

der different names, such as *blastoma*, *malignant teratoma*, and *teratocarcinoma*. This highly malignant tumor possesses an aggressive, rapid growing nature. So far about 50 cases have been reported in the literature (Chao *et al.* 2004), under the label *teratocarcinosarcoma*, a term which is generally accepted today.

CASE PRESENTATION

A new case of teratocarcinosarcoma with its pathological, radiologic and clinical behavior confirmation is presented. The case is a 24-year-old Iranian male with one year history of chronic sinusitis and nasal obstruction; he also had two months history of right sided proptosis, headache and also, 3-4 episodes of epistaxis during three months prior to his admission. On physical examination the patient was found to have no cranial nerve deficit and his eye movements has been normal, but right eye papilledema and exophthalmia has been detected. Besides,

*** Corresponding author:**

Dr. A. Kazemian, Department of Radiation Oncology, Cancer Institute, Tehran University of Medical Sciences, Tehran, Iran.

Fax: +98 21 6933005

E-Mail: kazemian@sina.tums.ac.ir

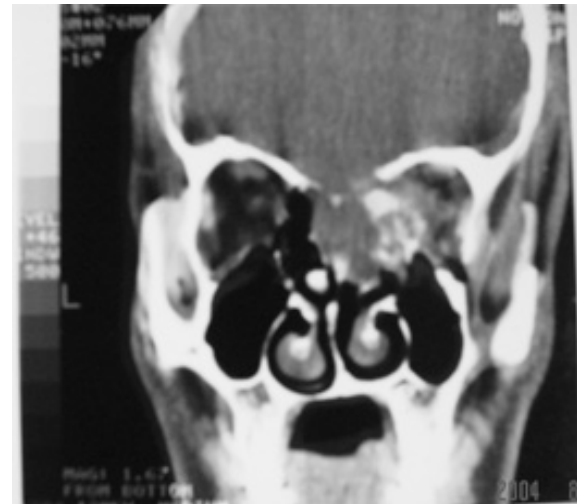the patient had new symptoms of blurred vision. Palpation of the neck showed no lymphadenopathy. Testicles were normal in sonography. The patient's past history showed no history of alcohol and drug consumption, or cigarette smoking with a severe ailment before the onset of proptosis. Family history was negative for cancer disease. Patient's MRI revealed a mass lesion in his right ethmoid and maxillary sinuses extending to the right orbit and extradural space (figures 1 and 2). Moreover, the bone erosion notified in CT scan images. The first pathological report of a needle biopsy performed on the tumor, read as "Chondrosarcoma" but following double revision on immunohistochemical staining in the Cancer Institute, Tehran University, revealed as follows "The staining was **positive** for: *cytokeratin, human chorionic gonadotropin, synotophysin, S-100, Mic 2*; and **negative** for: *placental alkaline phosphatase, epithelial membrane antigen, alpha fetoprotein*".

The latter report was accepted in favor of *Teratocarcinoma*.

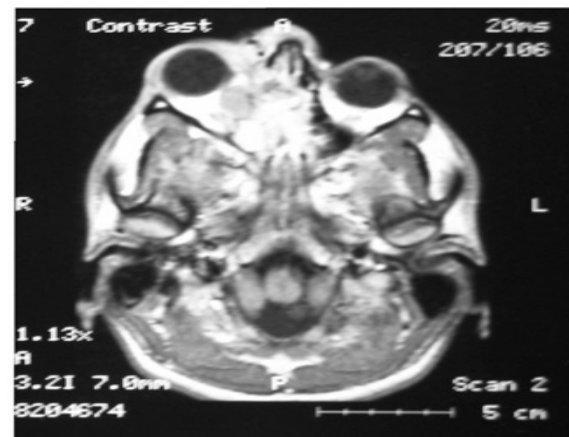
Subsequently, the patient underwent an en-block surgical resection of the lesion, producing a large tumor mass admixed with bony erosion measured about 8×8 cm (two pieces from ethmoid and nasopharynx area).

Pathologic report of which read as following:

1. Section from entire specimen reveals pieces of an infiltrative malignant neoplasm composed of mostly small back to back glands with well-defined lumen, containing secretion. The neoplastic cells are small and exhibit clear or vesicular nuclei. Some glands have close proximity to bone. Minimal chondroid and mixoid tissue with atypical nuclei are also seen.
2. Sections reveal fragments of upper respiratory mucosa with ciliated columnar lining in which variety of histologic patterns is seen. There are sheets of densely-packed small cells with scanty cytoplasm and uniform rounded nuclei resembling primitive neural



A



B

Figure 1. The coronal (A) and axial (B) views before surgical resection.

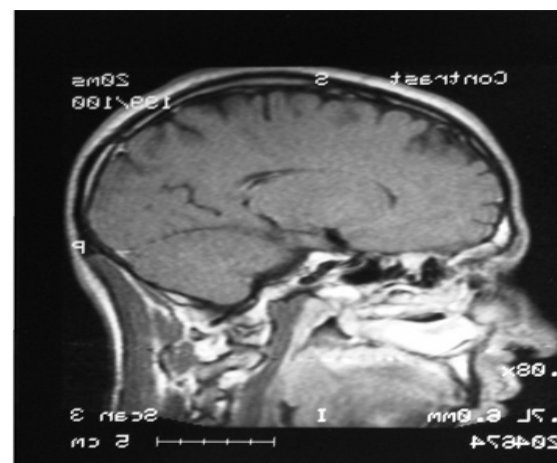


Figure 2. Sagittal view, after surgical resection.

tissue surrounded by rather myxoid area with elongated or rounded nuclei intervening with bundles of fibroblastic cells. In other sections the neoplastic cells from well-developed neoplastic glands with secretory activity.

Portion of this fragment also shows squamous differentiation with pearls formation. In addition to neoplastic chondroid tissue, there are also foci of osteoblastic and osteoid formation.

Dx: Rt. Periorbital (1) *nasal septum and ethmoid* (2) *Teratocarcinosarcoma*

Hence, he was then referred to the department of radiotherapeutic oncology, cancer institute, Imam Khomeini hospital, Tehran for post operative radiation treatment, his treatment by Co 60 unit was planned, and the patient received a tumor dose of 5600cGy radiation, from two wedged lateral fields, plus one anterior open with 4/1 weighting anteriorly with conventional treatment modality in radiotherapy (200 cGy daily tumor dose and five days per week). During the radiotherapy course the patient was checked for routine paraclinical profiles (CBC, LFT, BUN & Creatinine, and FBS) and all of which had been in control. During the treatment course, his proptosis regressed, his headache diminished. The patient was rechecked one month after radiation completion. He had no special symptoms except nasal dryness, but no corneal dryness detected. No episodes of epistaxis were reported by the patient during and after radiation treatment. He was followed routinely every two months, after his final radiotherapy session. He had no complaint of any special symptoms and normal CT-Scan (figure 2). He resumed his course of studies for M.Sc degree.

DISCUSSION

Sinonasal-teratocarcinosarcoma (SNTCS) is a high grade polymorphous tumor (Christensen *et al.* 1992). Its unusual histological features make management difficult (Shanmugaratnam *et al.* 1983, Heffner and Hyams 1984, Terasaka *et al.* 1998, Chao *et al.* 2004) so that these neo-

plasms had been labeled either as malignant teratoma, blastoma, or teratocarcinoma previously. There is indeed a marked variation and histological overlap in these lesions, accounting for the plethora of names suggested for this phenomenon. Poorly differentiated carcinoma, sarcoma, and olfactory neuroblastoma are considered in differential diagnosis. The teratoid nature is most prominent and is reflected in the presence of epithelial, mesenchymal, and neuroectodermal tissue, some of which is organized as in this case. Hence, the terms *teratocarcinosarcoma* or *teratoid carcinosarcoma* appear to be appropriate for the neoplasm.

Thorough sampling is only possible if an excision has been performed. A high index of suspicion is perhaps the best way to approach the histological differential diagnosis of SNTCS, from poorly differentiated carcinomas, including, sinonasal undifferentiated carcinoma, adenocarcinoma, neuroendocrine carcinoma, rhabdomyosarcoma, synovial sarcoma, olfactory neuroblastoma to malignant mixed salivary gland tumors. Malignant teratomas, however, unlike their benign counterparts, are rarely seen in the sinonasal tract. Furthermore, unlike malignant teratomas of germ cell origin, including those of extragonadal origin, SNTCS has never been reported to display areas of embryonal carcinoma, germinoma, yolk sac tumor, or choriocarcinoma. By this definition, every teratoma showing plural somatic differentiation has the potential to differentiate into yolk sac and trophoblastic structures. This has been amply demonstrated at gonadal and extragonadal sites, where teratomas are commonly diagnosed.

Therefore; pluripotentiality, even organized pluripotentiality, when it crosses embryonal-somatic boundaries, *viz* ectoderm, mesoderm and endoderm, is not a sufficient criterion for labeling a tumor as teratoma. By such a conceptual definition, it is possible to differentiate tumors such as teratoid nephroblastomas, hepatoblastomas, Sertoli-Leydig cell tumors with heterologous differentiation, and some unusual forms of mullerian tumors

from "true" teratomas of totipotential germ cell origin.

Although epistaxis and nasal obstruction are the most common presenting symptoms, other manifestations do occur, usually related to the degree of tumor extension. Headaches, dizziness, somnolence, apathy, and nausea have been noted as well as focal neurological manifestations such as compression of the ophthalmic nerve due to proptosis and visual field deficits as the case. Additionally, papilledema, exophthalmos, and weight loss have also been reported.

Hypонатremia was reported in the patient presenting with SIADH. SNTCS is a very malignant tumor. Recurrence is common. According to the literatures prognosis is poor, about 40% of patients survive beyond 5 years, with an average survival of less than 2 years (Chao et al. 2004, Ogawa et al. 2000).

Higher histology anaplasia is suggestive to increase tumor aggressiveness, although no apparent correlation has been verified. Metastases have been documented in the regional lymph nodes as well as in the lungs. A 10 months follow-up of our patient has revealed no evidence of recurrence. Although numerous modality combinations have been suggested to treat this disease, surgical excision with postoperative radiation therapy has become the most widely accepted therapeutic plan. According to the papers, that combination surgery/radiotherapy provides about 50% 5-year survival rate, just slightly better than surgery alone (47%). Few patients have been treated with chemotherapy (approximately 15%) (Chao et al. 2004, Ogawa et al. 2000, Sharma et al. 1998).

Sharma et al. have reported effective control of tumor recurrence under control (for a short period) with adjuvant chemotherapy (Sharma et al. 1998). Accurate estimation of survival

outcome, however, will not be conclusive until sufficient cases have been reported. With the rarity of this tumor, such knowledge may require some patience.

REFERENCES

- Chao K., Kenneth M.D., Tony Y., Barnes J., Dahiya R. (2004). Sinonasal Teratocarcinoma. A case report. *Am. J. Clin. Oncol.*, **27**: 29-32.
- Christensen E.C., Fu Y.S., Wilson L.J., Hoover L.A. (1992). Teratoid carcinosarcoma of the nasal and paranasal cavities: A case report. *Am. J. Rhinol.*, **6**: 169-172.
- Endo H. and Takanori H. (2001). Sinonasal teratocarcinoma. A case report. *Pathol. Int.*, **51**: 107-112.
- Endo H., Hiroset T., Kawamura K.I., Sano T. (2001). A case report. Sinonasal teratocarcinoma. *Patholo-endo.*, **10**: 7- 12.
- Heffner D.K. and Hyams V.J. (1984). Teratocarcinoma (malignant teratoma) of the nasal cavity and paranasal sinuses, a clinicopathologic study of 20 cases. *Cancer*, **53**: 2140-2154.
- Ogawa T., Ikeda K., Watanabe M., Satake M., Oshima T., Suzuki N., Nakano H., Matsuura K., Sato M., Takasaka T. (2000). A case report of sinonasal teratocarcinoma. *Tohoku. Exp. Med.*, **190**: 51-9.
- Sharma H.S., Abdullah J.M., Othman N.H., Mohmamad M. (1998). Pathology in focus. Teratocarcinoma of the nasal cavity and ethmoid. *J. Laryngo. Otol.*, **112**: 682-6.
- Terasaka S., Medary M.B., Whiting D.M., Fukushima T., Espejo E.J., Nathan G. (1998). Prolonged survival in a patient with sinonasal teratocarcinoma with cranial extension. *J. Neurosurg.*, **88**: 753-756.