

• **Case report**

## Detection of chordoma recurrence by F-18 FDG-PET/CT

A. Sabet<sup>1\*</sup>, H. Ahmadzadehfar<sup>1</sup>, F.J. Huertos Lopez<sup>1</sup>, M. Muckle<sup>1</sup>,  
A. Schmiedel<sup>2</sup>, H.J. Biersack<sup>1</sup>, S. Ezziddin<sup>1</sup>

<sup>1</sup>Department of Nuclear Medicine, University Hospital Bonn, Germany

<sup>2</sup>Department of Radiology, University Hospital Bonn, Germany

**Background:** Despite the relative success of surgical resection followed by proton, proton/photon, or conventional radiotherapy in terms of recurrence-free survival, chordomas are still associated with a high rate of recurrence. To our knowledge there are only very few reported cases of this rare tumor detected by F-18 FDG-PET. **Materials and Methods:** In this case we show the significance of F-18 FDG-PET/CT in detection of recurrent Chordoma in a 38 year old man with a history of the disease and a newly detected cervical lymphatic mass. **Results:** The fused PET/CT images manifested the presence of two abnormal foci of tracer uptake corresponding to a retroclavicular and an infrajugular Lymph node proved to be metastases of the previous chordoma in histopathology. **Conclusion:** Further employment of F-18 FDG-PET/CT in this rare tumour type might eventually define and establish its value in staging of chordoma. *Iran. J. Radiat. Res., 2012; 10(2): 109-110*

**Keywords:** Chordoma, FDG-PET/CT, 18F-FDG, bone tumors.

### CASE PRESENTATION

A 38 year old man with a history of chordoma was referred to our department with a newly detected cervical lymphatic mass in MRI to be further investigated with 18F-FDG-PET/CT. The primary tumour, involving C3-C5, had been treated surgically 2 years earlier by tumour resection and laminectomy, followed by a course of proton beam irradiation. The PET/CT scan (Biograph; Siemens Medical Solutions Inc, Hoffman Estates, IL) was acquired 100 min after intravenous application of 328 MBq 18F-FDG. The fused PET/CT images manifested the presence of two abnormal foci of tracer uptake. The first one was in

the left retroclavicular region (SUV max: 5.2, mean 3.5, figure 1 a, b) corresponding to a 2.7×1.7 cm lymph node (figure 1c) and being consistent with the MRI finding. The other one was in the infrajugular region (figure 1 d, e), projecting on a 1.3×1.3 cm lymph node (figure 1f) which was remained unsuspected in the previous MRI investigation. Both lymph nodes were reported as lymph node metastases by PET/CT. As a consequence the patient underwent excision of both cervical nodes which proved to be metastases of the previous chordoma in histopathology.

### DISCUSSION

Chordomas are uncommon, slow-growing yet highly destructive malignant tumors of the bone, thought to be derived from the remnants of the embryonic notochord (1-2). Although surgical resection followed by proton, proton / photon, or conventional radiotherapy has been relatively successful in terms of recurrence-free survival these tumors are still associated with a high rate of recurrence, mostly local (3-4). In recent years, 18F - FDG - PET / CT imaging has gained increasing acceptance as a standard examination modality for the non-invasive diagnosis of occult cancers and restaging as well as monitoring therapeutic efficacy (5-7). However to our knowledge there are only

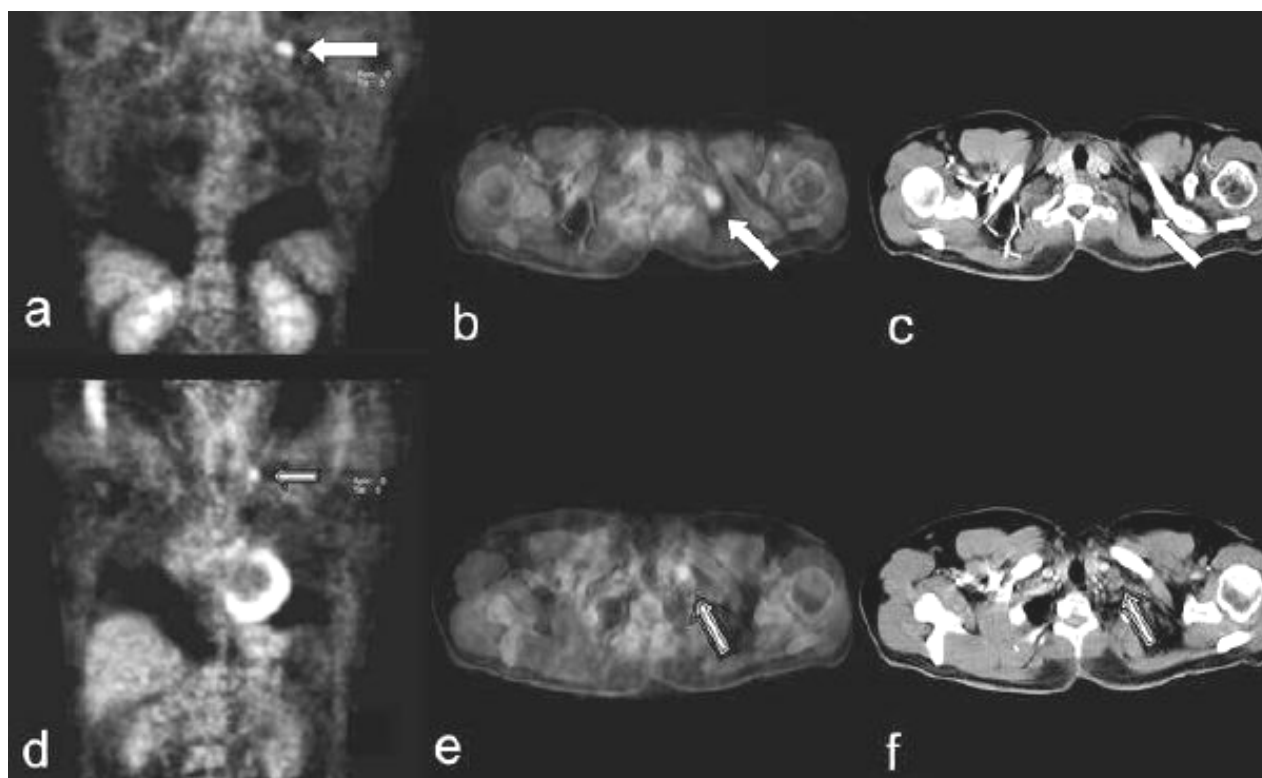
#### \*Corresponding author:

Dr. Amir Sabet,

Department of Nuclear Medicine, University of Bonn,  
Sigmund-Freud, Strasse 25, 53127 Bonn, Germany.

Fax: +49 228 287 90 15184

E-mail: [amir.sabet@ukb.uni-bonn.de](mailto:amir.sabet@ukb.uni-bonn.de)



**Figure 1.** Focal tracer uptakes in the left retroclavicular region (**a**: coronal and **b**: transversal) corresponding to a 2.7×1.7 cm lymph node in CT (**c**) and in the infrajugular region (**d**: coronal and **e**: transversal), projecting on a 1.3×1.3 cm lymph node in CT (**f**). The latter remained unsuspected in the previous MRI investigation.

very few reported cases of chordoma detected by 18F-FDG-PET<sup>(8)</sup>. Further employment of 18F-FDG-PET/CT in this rare tumour type might eventually define and establish its value in staging of chordoma.

## REFERENCES

1. Murad TM and Murthy MS (1970) Ultrastructure of a chordoma. *Cancer*, **25**:1204-15.
2. Pena CE, Horvat BL, Fisher ER (1970) The ultrastructure of chordoma. *Am J Clin Pathol*, **53**:544-51.
3. Austin JP, Urie MM, Cardenosa G, Munzenrider JE (1993) Probable causes of recurrence in patients with chordoma and chondrosarcoma of the base of skull and cervical spine. *Int J Radiat Oncol Biol Phys*, **25**: 439-44.
4. Austin-Seymour M, Munzenrider JE, Goitein M, Gentry R, Gragoudas E, Koehler AM, et al. (1985) Progress in low-LET heavy particle therapy: intracranial and paracranial tumors and uveal melanomas. *Radiat Res Suppl*, **8**: S219-26.
5. Takahashi T, Hagiwara A, Shimotsuma M, Sawai K, Yamaguchi T (1995) Prophylaxis and treatment of peritoneal carcinomatosis: intraperitoneal chemotherapy with mitomycin C bound to activated carbon particles. *World J Surg*, **19**:565-9.
6. Yun M and Kim BI (2006) Roles of F-18 FDG PET or PET/CT for the evaluation of gastrointestinal malignancies. *Korean J Gastroenterol*, **48**:378-87.
7. Schoder H and Gonen M (2007) Screening for cancer with PET and PET/CT: potential and limitations. *J Nucl Med*, **48 Suppl 1**:4S-18S.
8. Park SA and Kim HS (2008) F-18 FDG PET/CT evaluation of sacrococcygeal chordoma. *Clin Nucl Med*, **33**:906-8.