

Small cell carcinoma of the uterine cervix with cerebellar metastasis: A special case report with literature review

J.H. Zhu^{1,2}, Q.C. Hu², K. Gu^{1,2*}, C. Shen³, R. Yang³, S.J. Ji², Q.Q. Che²

¹Department of Oncology, Nanjing Medical University, Nanjing, China

²Department of Radiation Oncology, the Affiliated Suzhou Hospital of Nanjing Medical University, Suzhou Municipal Hospital (East Branch)

³Department of Obstetrics and Gynecology, the Affiliated Suzhou Hospital of Nanjing Medical University, Suzhou Municipal Hospital (East Branch)

ABSTRACT

► Case report

*Corresponding authors:

K. Gu, PhD,

Fax: + 86 051 2672 94553

E-mail: drguke@163.com

Revised: January 2018

Accepted: September 2018

Int. J. Radiat. Res., April 2019;
17(2): 345-353

DOI: 10.18869/acadpub.ijrr.17.2.345

Background: Small cell carcinoma of the uterine cervix is a highly malignant form of cancer in women, characterized by its high propensity for rapid extra-pelvic distant metastasis and poor prognosis. The best treatment strategy for this type of cancer is still controversial. **Case presentation:** We report here a case of small cell carcinoma of the uterine cervix treated by extensive total hysterectomy followed by adjuvant chemoradiotherapy. A 45-year-old Chinese woman was diagnosed with stage IIA small cell carcinoma of the uterine cervix. The patient suffered from head metastasis following a diagnosis made fifteen months prior. **Conclusion:** We describe the optimal treatment and prognostic factors of this tumour. The stage of the tumour, main treatment, prognostic factors and outcome of this disease are presented with a review of the related literature.

Keywords: Cerebellar metastasis, small cell carcinoma, uterine cervix, treatment, prognostic factor.

INTRODUCTION

Small cell carcinoma of the uterine cervix (SCCC) is a highly malignant form of uterine cervix cancer. It has a low incidence rate that only comprises 1%-3% cervical carcinomas ⁽¹⁾. The mean annual incidence for small cell carcinoma was 0.06 per 100,000 women compared to 6.6 and 1.2 for squamous cell carcinoma and adenocarcinoma, respectively ⁽²⁾. Because of the rarity of this disease, there is a paucity of information about the prognostic factors associated with survival. Moreover, optimal treatment strategies have not yet been clarified.

Similar to small cell carcinoma of the lung (SCLC), SCCC has a high propensity for rapid extra-pelvic distant metastasis to the lung, liver, brain, bone and lymph nodes, even in early

stages. Thus, compared with other common histological types such as squamous cell carcinoma or adenocarcinoma, the outcome for patients with SCCC is poor. For all stages, 5-year survival rates range from 11% to 54%. Five-year survival for patients with disease limited to the pelvis is estimated to be 30%, in contrast to survival for patients with extensive disease, who rarely survive beyond 2 years following diagnosis ⁽³⁾. In 1957, Reagan *et al.* first described small cell undifferentiated (neuroendocrine) carcinoma of the uterine cervix, an extrapulmonary variant of small cell cancer ⁽⁴⁾.

CASE PRESENTATION

A 45-year-old Chinese woman presenting

with a 3-week history of pelvic discomfort visited our hospital in June 2015. Gynaecological examination showed an endocervical mass, 3 cm × 2 cm × 2 cm in size. Pelvic MRI showed an irregular soft tissue mass, 2.8 cm × 2.5 cm × 2.7 cm, at the internal orifice of the cervix. This tumour extended upward towards the lower body of the uterus, and multiple enlarged lymph nodes could be seen in the pelvic cavity. Human papillomavirus detection was positive for HPV-18. A chest CT scan revealed no lung metastasis. According to the clinical and radiological findings, the tumour was assigned to stage IIA according to the International Federations of Gynaecology and Obstetrics. The patient was treated with extensive total hysterectomy plus bilateral adnexectomy and high ligation of the bilateral infundibulopelvic ligament combined with pelvic cavity lymph node dissection on June 11, 2015 (figure 1). Pathology confirmed the tumour was SCCC. The wall of the cervix was involved, and tumour thrombus was found in the veins. Eleven lymph nodes were metastasized, including two left common iliac lymph nodes, four right pelvic lymph nodes and five left pelvic lymph nodes. Immunohistochemically, SCLC was positive and NSE, Syn, ck18, CGA, CD56, and P63 were partly positive. Moreover, P53 was positive intermittently and Ki67 was 60% (figure 2). The

patient received external radiotherapy on July 10, 2015. The specific plan of the treatment is described as follows: intensity-modulated radiation therapy (IMRT) 6 MV X-ray PTV (pelvic lymph node) 5000cGy/25f/36d. She also underwent the first cycle of concurrent adjuvant chemotherapy using a regimen of etoposide (0.17 g/day, days 1-3) and cisplatin (0.4 g/day, days 1-3) on July 12, 2015. During the first period of chemotherapy, bone marrow depression (grade IV) occurred, but the syndrome was relieved after symptomatic treatment. Then, on July 24, 2015, the second cycle of concurrent adjuvant chemotherapy in a regimen of etoposide (0.17 g/day, days 1-5) and cisplatin (0.35 g/day, days 1-3) was administered. The patient still suffered from bone marrow depression. Therefore, in the third, fourth, fifth and last cycle of chemotherapy, a regimen of etoposide (0.15 g/day, days 1-3) and cisplatin (0.35 g/day, days 1-3) was used. The patient received 6 cycles of chemotherapy in total. However, cerebellar metastasis occurred fifteen months after the SCCC diagnosis. The cerebellar metastasis detected by CT was located in the left cerebellum, approximately 3 cm in diameter (figure 3). There was no other metastasis in this patient, particularly in the lungs (figure 4).

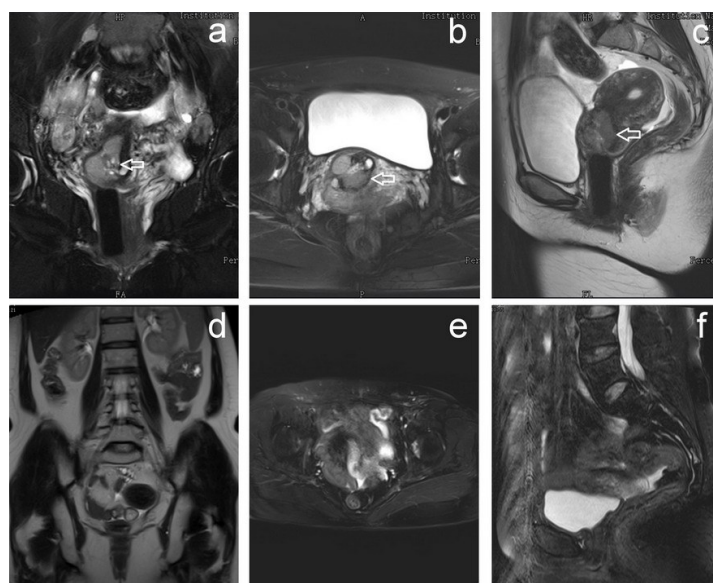


Figure 1. MRI showed a mass in the left cerebellum, about 3 cm in diameter a in the coronal position with contrast, b in the sagittal position with contrast, c in the axial position with contrast. d and e diffusion-weighted transverse MR image of the mass.

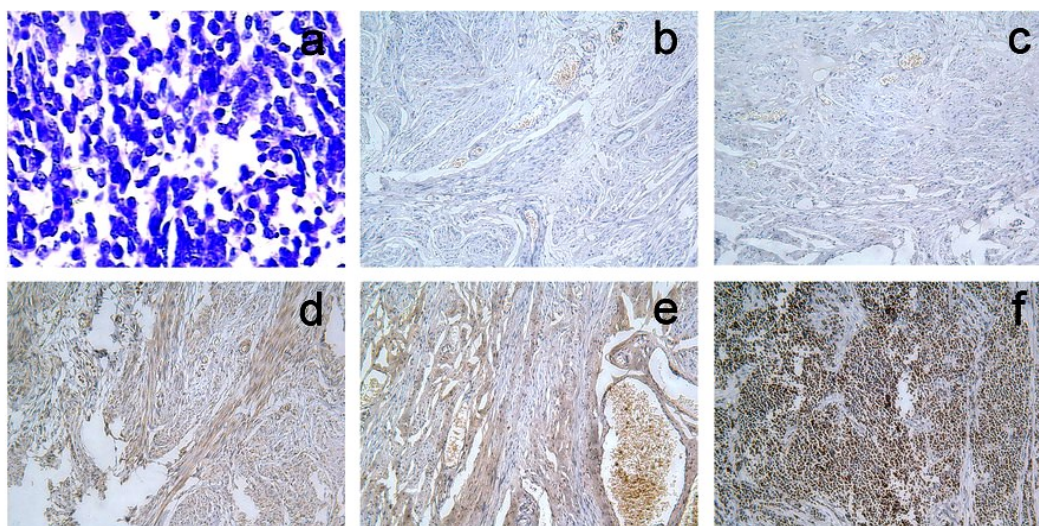


Figure 2. Neuroendocrine carcinoma of the cervix. Pathologically, small hyperchromatic cells with scant cytoplasm and typical brisk mitotic a. Immunohistochemically, b. NSE, c. Syn, d. CGA, e. CD56 are partly positive and f. Ki67 is 60%.

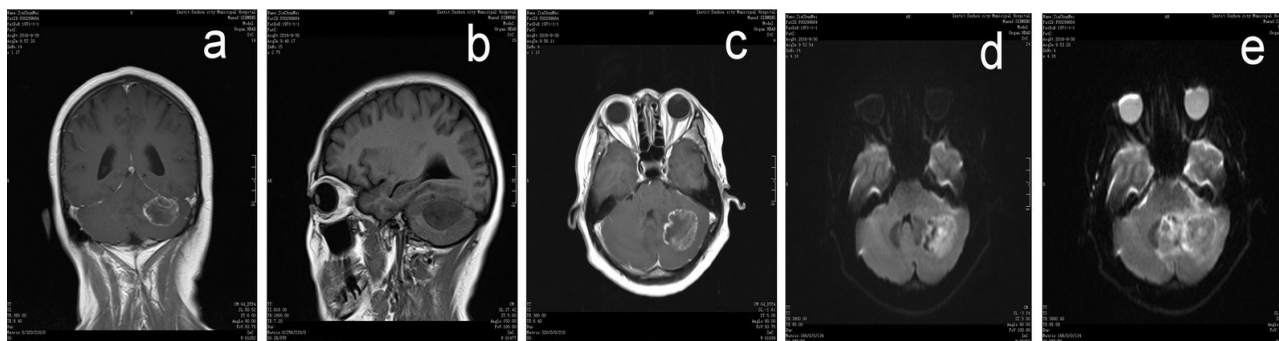


Figure 3. Pelvic MRI Intensifying showed irregular soft tissue mass, 2.8 cm * 2.5 cm * 2.7 cm, in internal orifice of cervix a in the coronal position, b in the axial position, c in the sagittal position. MR imaging of the SCCC patient at 15 months after surgery d in the coronal position, e in the axial position, f in the sagittal position.

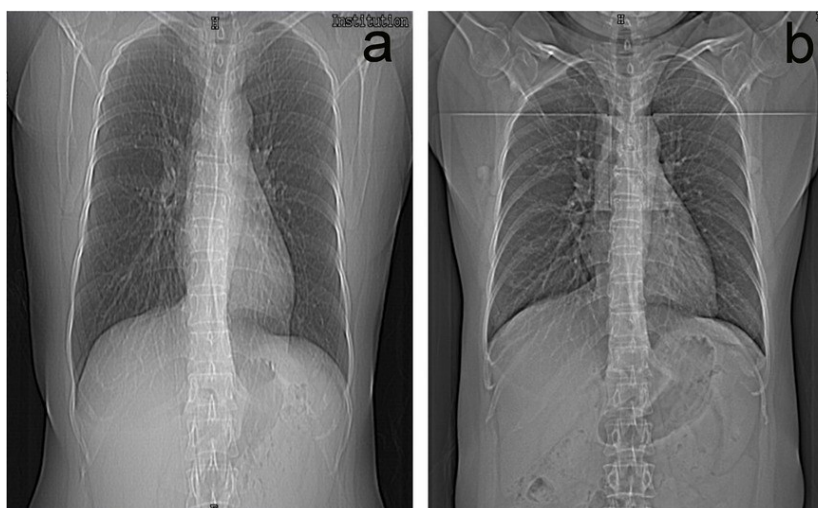


Figure 4. CT scan showed no abnormality in the lung a before the operation, b after the metastasis of cerebellum.

DISCUSSION

To improve the rate of definitive diagnosis of SCCC, the pathologic diagnostic criteria for neuroendocrine tumours of the uterine cervix have changed over time. In 1994, the World Health Organization (WHO) classified the criteria into two categories: carcinoid and small cell carcinoma. In 1997, Albores-Saavedra et al. proposed a classification of neuroendocrine tumours of the uterine cervix based on classifications for lung cancer. These included small cell carcinoma, large cell neuroendocrine carcinoma, typical carcinoid tumour and atypical carcinoid tumour. In the 2003 WHO classification, like the 1997 classification, 4 categories were listed for neuroendocrine tumours of the uterine cervix: carcinoid, atypical carcinoid, small cell carcinoma, and large cell neuroendocrine carcinoma, based on the pattern of lung neuroendocrine carcinoma. However, all the classifications did not detail the morphology within the categories. Thus, detailed descriptions of the morphology of these categories needed further exploration⁽⁵⁾.

SCCC is a very rare and aggressive disease that has a high propensity for haematologic and lymphatic metastasis even at an early stage. Between 40% and 60% of patients in early stages experience lymph node metastasis and haematogenous metastasis; recurrence often occurs in the liver, lung, bone, brain, or lymph node within 1 year after diagnosis, leading to treatment failure for most patients with SCCC. SCCC is a rare tumour with a mean annual incidence of 0.06 per 100,000 women, accounting for 1 to 6% of all cervical cancer⁽⁶⁾. Due to its rarity and a paucity of knowledge about this disease, there are no identical diagnoses, treatment guidelines, or optimal treatment strategies for this malignancy. Therefore, SCCC remains a therapeutic challenge for clinicians.

The Gynaecologic Oncology Group did not study SCCC between 1982 and 1986 due to insufficient patients to recruit. Then, Abeler *et al.* found histological similarities between SCCC and SCLC (small cell lung cancer) and proposed

2 hypotheses regarding these similarities. First, a malignant change of argyrophilic cells in the normal uterine cervix turns into SCNEC that secretes polypeptide hormones. Second, multipotential stem cells differentiate into neuroendocrine cells⁽⁷⁾. As a result, the treatment regimen was mainly extrapolated from that for SCLC, owing to the histological similarity between the two diseases. However, current studies found that although this malignancy resembles SCLC, the two diseases exhibit varying degrees of immunohistochemical reactivity and respond diversely to the same multimodal regimen⁽⁸⁾. Consequently, clinical trials and investigations on a larger scale are still needed to identify optimal treatments for patients with SCCC.

According to the management algorithm for NEC of the cervix, radical surgery is recommended for early-stage disease either primarily or after neoadjuvant chemotherapy. For patients with advanced-stage disease, chemoradiation or systemic chemotherapy is suggested⁽⁹⁾.

Radical surgery, including radical hysterectomy and pelvic lymph node dissection, is recommended first for patients with resectable, limited-stage disease. In a clinical document on small cell neuroendocrine carcinoma issued by the Society of Gynaecologic Oncologists, the recommendation for surgical therapy is based on tumour size (figure 5):

- Tumours ≤ 4 cm (stages I-IIA): Radical hysterectomy with pelvic lymphadenectomy. Followed by adjuvant chemotherapy (etoposide with cisplatin) with or without radiation therapy.
- Tumours >4 cm (stage I-IIA): Either a combination of chemotherapy and radiation therapy or neoadjuvant chemotherapy (platinum-based), followed by surgery if the disease is localized.

However, survival rates using the current therapies are poor after treatment by radical hysterectomy because of the lack of optimal treatment strategies for these patients with early-stage disease⁽¹⁰⁾.

Some authors recommend the use of

chemotherapy following radical surgery for patients with early-stage SCCC (11). Treatment regimens with vincristine, doxorubicin, and cyclophosphamide alternating with cisplatin and etoposide (VAC/PE) are commonly used, like in the treatment of SCLC. Given the increased toxicity of the former regimens, EP regimens are preferred because of their better tolerance (12). In the study by Zivanovic *et al.*, patients treated with chemotherapy as part of their treatment regimen have a better 3-year distant recurrence-free survival (13). Kuji *et al.* (14) demonstrated significantly better progression-free survival by addition of chemotherapy after radical surgery compared with patients who did not receive chemotherapy. One Korean study showed that primary radical surgery followed

by adjuvant chemotherapy is the preferred treatment modality for patients with early-stage SCCC. However, the report of Tian *et al.* (15) suggested that no improved outcomes were found in patients with stage IB1-IIA SCCC after radical hysterectomy followed by adjuvant chemotherapy. Similar findings were reported by Lee *et al.* The 25.3% 5-year OS rate suggested that radical hysterectomy followed by adjuvant therapy, the usual treatment for other types of cervical carcinoma, is not sufficiently effective for the treatment of SCCC. Therefore, the use of adjuvant chemotherapy for patients with this type of carcinoma may have a sufficient effect; however, adding chemotherapy after radical hysterectomy is controversial at present.

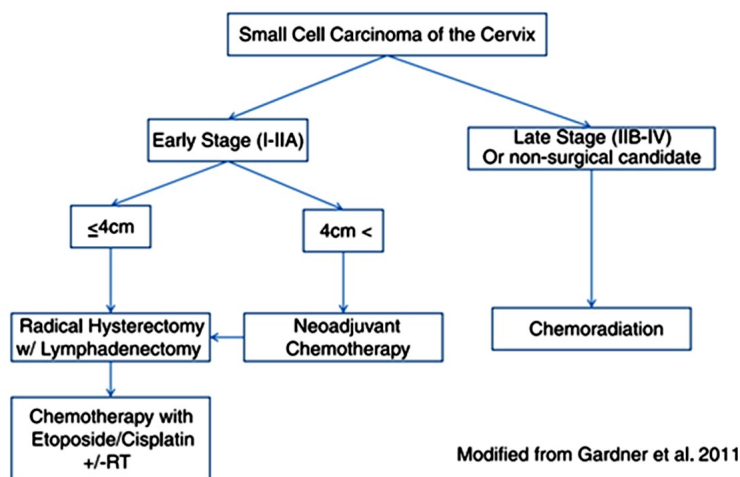


Figure 5. Management scheme for neuroendocrine cervical carcinoma.

Radiation therapy may play an important role in the treatment of early-stage SCCC. Hoskins *et al.* reported a 3-year FFS of 80% using chemoradiotherapy in the treatment of 16 patients with SCCC at stages I–II (16). A report by Chen *et al.* showed a 78% 3-year FFS rate for 14 patients at stages I–II treated with primary radiation therapy and at least 5 cycles of platinum-based chemotherapy (17). Meanwhile, Lee *et al.* (18) demonstrated that postoperative radiotherapy was harmful. The 5-year survival rate for patients with early-stage SCCC treated with radiotherapy decreased by 13.7%. Two reasons may account for this phenomenon. On one hand, radiotherapy might boost the toxic

and adverse effects, hinder the effect of chemotherapy and lower the survival rate. On the other hand, those patients treated with chemoradiotherapy always had one or more high-risk factors. Therefore, given that small cell carcinoma was sensitive to radiotherapy, radiotherapy for SCCC patients with postoperative risk factors is recommended to improve their local control rate.

Currently, prophylactic whole-brain radiation therapy is not recommended routinely in the management of patients with early-stage disease (19). According to the literature, the brain-metastatic rate of SCCC was definitely lower than that of SCLC. Additionally,

Viswanathan *et al.* concluded that lung metastases may be a necessary precursor to developing brain metastases. In this report, there were no tumours in the brain as the only site of recurrence, and the two patients with brain metastases concurrently had lung metastases. Consequently, cranial imaging examination is recommended only for those SCCC patients with lung metastases. Given the extremely rare incidence of the brain as the sole first metastasis site, prophylactic whole-brain radiation therapy was not conducted following primary tumor treatment. Interestingly, in our case, brain metastasis did serve as the first sole metastasis site ⁽¹⁸⁾.

For patients with advanced-stage SCCC, combination chemotherapy with radiation may be recommended. Multidisciplinary treatment therapy is suggested for patients with either widespread metastatic or recurrent SCCC. Regimens using EP or VAC/EP should be considered and selected depending on patients' presentations ⁽⁹⁾.

As shown in table 1, several prognostic factors influence the survival rates of SCCC as demonstrated in different studies. In Cohen's study of 188 patients, stage and use of chemotherapy or chemoradiation were independent predictors of survival among patients with stage I-IIA SCCC ⁽¹⁰⁾. Independent prognostic factors identified by Chen *et al.* included stage, age, race and hysterectomy alone ⁽⁶⁾. Wang *et al.* reported two factors: stage and lymph node metastasis, as prognostic ⁽²⁸⁾. Smoking and stage are shown to be prognostic factors for survival in patients with SCCC by Chan *et al.* ⁽²⁹⁾. The stage is the only common prognostic factor among these studies. Nevertheless, optimal treatment therapy for patients with SCCC remains to be determined, and we often refer to the clinical pattern of pulmonary small cell carcinomas.

In our case, the size of the tumour in the patient with stage IIA was less than 4 cm. The tumour was assigned to stage IIA based on the guidelines of the International Federation of Gynaecology and Obstetrics. She was first given radical surgery treatment; then she received

postoperative concurrent chemoradiotherapy. She was treated with 6 cycles of chemotherapy containing etoposide and cisplatin, as in the most commonly used regimen. Fifteen months later, this patient was diagnosed with head metastasis located in the left cerebellum as detected by CT, sized approximately 3 cm in diameter.

CONCLUSION

In conclusion, SCCC is a rare, aggressive carcinoma with a poor prognosis, especially for those diseases at an advanced stage and having distant metastasis. Radical surgery is recommended for early-stage disease. For patients with advanced-stage disease, chemoradiation or systemic chemotherapy is suggested ⁽³⁰⁾. The best treatment strategy of SCCC is still unclear and needs further study for exploration and clarification. The case we reported is intended to increase awareness of this rare SCCC metastasis and reinforce the need for more studies and cases, to develop new and more effective treatment for patients with SCCC.

DECLARATIONS

Ethics approval and consent to participate

The patient we report approved the paper research and volunteered to participate the study. Ethical Committee of Suzhou Municipal Hospital (East Branch) supported the study.

ACKNOWLEDGEMENT

This study was subsidized by Research and development program of Jiangsu Province (Grant BE2015645) and in part by Grant Z201413 from Scientific Research Project of Health Department of Jiangsu Province.

Conflicts of interest: Declared none.

Table1. Review of the literature published for small cell carcinoma of the uterine cervix.

Authors	cases	Median age(year)	Stage (FIGO)	Main treatment (study period)	Prognostic factor	Survival outcome
Chen et al. ⁽¹⁹⁾	290	45.0	I -IV b	S±RT (1977-2003)	Age, stage, race, hysterectomy alone	5-year survival rate: 35.7%
Lee SW et al. ⁽²⁰⁾	32	45.0	I a-IV	S±CT±RT (1996-2008)	Haematogenous metastasis	5-year survival rate: 30.5% for early stage 31.3% for advanced stage
Cohen et al. ⁽¹⁰⁾	188	42.0	I -IV b	S±CT±RT (1979-2005)	Stage, use of CT or RT	5-year survival rate: 36.8% for stage I - II a 9.8% for stage II b-IV a 0% for stage IV b
L. Lan-Fang et al. ⁽²¹⁾	43	45.0	I b-IV	S±CT±RT (1985-2007)	Clinical stage Nodal and hematogenous metastasis	5-year OS: 29% Median survival: 89.6 M for early stage 34.4 M for advanced stage
TIAN et al. ⁽¹⁵⁾	96	40.0	I b1- II a	S±CT±RT (1990-2010)	Stage, lymph node status, deep stromal invasion	5-year survival rate: 58.0% for stage I b1 34.0% for I b2- II a
Wang et al. ⁽²²⁾	13	37.0	I b-IV	S±CT±RT (2006-2010)	Early diagnosis, prompt combination treatment	Median survival: 17.5M
Wang et al. ⁽²⁸⁾	179	47.0	I -IV	S, S+CT or RT or CCRT, RT/CCRT (1987-2009)	Stage, lymph node status	5-year survival rate: 51.1% for stage I 50.4% for stage II 13.0% for stage III 6.1% for stage IV
ToKunaga et al. ⁽²³⁾	9	42.0	I b1, I b2, II b, IV b	S+CCRT, CCRT (2001-2009)	use of CCRT(VAC/PE)	5-year OS: 52.0% 5-year PFS: 56.0%
Kuji et al. ⁽¹⁴⁾	52	40.0	I b-IV b	S±CT, S±CCRT, CCRT (1997-2007)	local therapy + systemic chemotherapy	4-year survival rate: 63.0% for stage I b1 67.0% for stage I b2 30.0% for stage II b 29.0% for stage III b 25.0% for stage IV b
Yuan et al. ⁽²⁴⁾	38	40.4	I a2- II a1	S±CT (2004-2013)	Parametrial invasion and chemotherapy regimen	2-year OS: 54.7% DFS: 44.2% 5-year OS: 43.0% DFS: 49.3%
Wang et al. ⁽²⁵⁾	32	37.0	I b- II a	S+CT, S+RT (2005-2013)	Tumor size, stage	2-year OS: 56.1% 5-year OS: 38.1%
Chen et al. ⁽¹⁷⁾	144	45.0	I a- II b	S±CT, CT±RT (1987-2009)	Early stage with tumor ≤2 cm and no LVSI	5-year survival rate: 54.0% for stage I a- I b1 43.0% for stage I b2- II b
Lee SW et al. ⁽²⁶⁾	102	50.0	I a-IV	Preop CT + Postop CT, Postop CT, Postop RT, Postop CCRT (1991-2010)	Stage and use of CT	4-year survival rate: 63% for stage I b1 67% for stage I b2 30% for II b 29% for stage III b 25% for stage IV b
Zhou et al. ⁽²⁷⁾	208	40.5	I - II	S±RT, RT (1988-2012)	Stage, age, treatment, lymph node status	5-year survival: OS: 46.4% 64.9% for treatment of S 46.2% for treatment of S+RT 28.8% for treatment of RT

REFERENCES

1. Viswanathan AN, Deavers MT, Jhingran A, et al. (2004) Small cell neuroendocrine carcinoma of the cervix: outcome and patterns of recurrence. *Gynecologic Oncology*, **93(1)**: 27-33.
2. Crowder S and Tuller E. (2007) Small cell carcinoma of the female genital tract. *Seminars in Oncology*, **34(1)**: 57.
3. D'Antonio A, Adesso M, Caleo A, et al. (2015) Small cell neuroendocrine carcinoma of the endometrium with pulmonary metastasis: A clinicopathologic study of a case and a brief review of the literature. *Annals of Medicine & Surgery*, **5(S1)**: 114.
4. Wentz WB and Reagan JW (1959) Survival in cervical cancer with respect to cell type. *Cancer*, **12(2)**: 384-388.
5. Zhou J, Wu SG, Sun JY, et al. (2017) Clinicopathological features of small cell carcinoma of the uterine cervix in the surveillance, epidemiology, and end results database. *Oncotarget*, **8(25)**: 40425.
6. Ishikawa M, Kasamatsu T, Tsuda H, et al. (2018) Prognostic factors and optimal therapy for stages I-II neuroendocrine carcinomas of the uterine cervix: A multi-center retrospective study. *Gynecologic Oncology*, **2018**, **148(1)**: 139-146.
7. Abeler VM, Holm R, Nesland JM et al. (1994) Small cell carcinoma of the cervix. A clinicopathologic study of 26 patients[J]. *Cancer*, **1994**, **73(3)**: 672-677.
8. Dongol S, Tai Y, Shao Y, et al. (2014) A retrospective clinicopathological analysis of small-cell carcinoma of the uterine cervix. *Molecular & Clinical Oncology*, **2(1)**: 71.
9. Gardner GJ, Reidylagunes D, Gehrig PA (2011) Neuroendocrine tumors of the gynecologic tract: A Society of Gynecologic Oncology (SGO) clinical document. *Gynecologic Oncology*, **122(1)**: 190-198.
10. Cohen JG, Kapp DS, Shin JY, et al. (2010) Small cell carcinoma of the cervix: treatment and survival outcomes of 188 patients. *American Journal of Obstetrics & Gynecology*, **203(4)**: 347.e1-347.e6.
11. Lee JM, Lee KB, Nam JH, et al. (2008) Prognostic factors in FIGO stage IB–IIA small cell neuroendocrine carcinoma of the uterine cervix treated surgically: results of a multi-center retrospective Korean study. *Annals of Oncology*, **19(2)**: 321-326.
12. Fukuoka M, Furuse K, Saijo N, et al. (1991) Randomized trial of cyclophosphamide, doxorubicin, and vincristine versus cisplatin and etoposide versus alternation of these regimens in small-cell lung cancer. *Journal of the National Cancer Institute*, **83(12)**: 855.
13. Zivanovic O, Jr LM, Park KJ, et al. (2009) Small cell neuroendocrine carcinoma of the cervix: Analysis of outcome, recurrence pattern and the impact of platinum-based combination chemotherapy. *Gynecologic Oncology*, **112(3)**: 590-593.
14. Kuji S, Hirashima Y, Nakayama H, et al. (2013) Diagnosis, clinicopathologic features, treatment, and prognosis of small cell carcinoma of the uterine cervix; Kansai Clinical Oncology Group/Intergroup study in Japan. *Gynecologic Oncology*, **129(3)**: 522-527.
15. Tian WJ, Zhang MQ, Shui RH (2012) Prognostic factors and treatment comparison in early-stage small cell carcinoma of the uterine cervix. *Oncology Letters*, **3(1)**: 125.
16. Hoskins PJ, Swenerton KD, Pike JA, et al. (2003) Small-cell carcinoma of the cervix: fourteen years of experience at a single institution using a combined-modality regimen of involved-field irradiation and platinum-Based combination chemotherapy. *Journal of Clinical Oncology*, **21(18)**: 3495-501.
17. Chen TC, Huang HJ, Wang TY, et al. (2015) Primary surgery versus primary radiation therapy for FIGO stages I-II small cell carcinoma of the uterine cervix: A retrospective Taiwanese Gynecologic Oncology Group study. *Gynecologic Oncology*, **137(3)**: 468.
18. Viswanathan AN, Deavers MT, Jhingran A, et al. (2004) Small cell neuroendocrine carcinoma of the cervix: outcome and patterns of recurrence. *Gynecologic Oncology*, **93(1)**: 27-33.
19. Chen J, Macdonald OK, Gaffney DK (2008) Incidence, mortality, and prognostic factors of small cell carcinoma of the cervix. *Obstetrics & Gynecology*, **111(6)**: 1394.
20. Lee SW, Nam JH, Kim DY, et al. (2010) Unfavorable prognosis of small cell neuroendocrine carcinoma of the uterine cervix: a retrospective matched case-control study. *International Journal of Gynecological Cancer*, **20(3)**:411-6.
21. Lan-Fang L, Hai-Yan S, Zuo-Ming Y, et al. (2012) Small cell neuroendocrine carcinoma of the cervix: analysis of the prognosis and role of radiation therapy for 43 cases. *European Journal of Gynaecological Oncology*, **33(1)**:68.
22. Wang Y, Mei K, Xiang MF, et al. (2013) Clinicopathological characteristics and outcome of patients with small cell neuroendocrine carcinoma of the uterine cervix: case series and literature review. *European Journal of Gynaecological Oncology*, **34(4)**: 307-310.
23. Tokunaga H, Nagase S, Yoshinaga K, et al. (2013) Small cell carcinoma of the uterine cervix: clinical outcome of concurrent chemoradiotherapy with a multidrug regimen. *Tohoku Journal of Experimental Medicine*, **229(1)**: 75-81.
24. Yuan L, Jiang H, Lu Y, et al. (2015) Prognostic factors of surgically treated early-stage small cell neuroendocrine carcinoma of the cervix. *International Journal of Gynecological Cancer*, **25(7)**.
25. Wang Z, Wu L, Yao H, et al. (2015) Clinical analysis of 32 cases with neuroendocrine carcinoma of the uterine cervix in early-stage disease. *Zhonghua Fu Chan Ke Za Zhi*, **50(3)**: 198.
26. Lee SW, Lim KT, Bae DS, et al. (2015) A multicenter study of the importance of systemic chemotherapy for patients with small-cell neuroendocrine carcinoma of the uterine cervix. *Gynecologic & Obstetric Investigation*, **79(3)**: 172-178.
27. Zhou J, Yang HY, Wu SG, et al. (2016) The local treatment modalities in FIGO stage I-II small-cell carcinoma of the cervix are determined by disease stage and lymph node status. *Cancer Medicine*, **5(6)**: 1108-1115.
28. Wang KL, Chang TC, Jung SM, et al. (2012) Primary treatment and prognostic factors of small cell neuroendocrine carcinoma of the uterine cervix: a Taiwanese Gynecologic

- Oncology Group study. *European Journal of Cancer*, **48**(10): 1484-1494.
29. Chan JK, Loizzi V, Burger RA, et al. (2003) Prognostic factors in neuroendocrine small cell cervical carcinoma: a multivariate analysis. *Cancer*, **97**(3): 568.
30. Satoh T, Takei Y, Treilleux I, et al. (2014) Gynecologic Cancer InterGroup (GIG) consensus review for small cell carcinoma of the cervix. *International Journal of Gynecological Cancer*, **24**(9-3): S102.

