

# Axillary irradiation in breast cancer; does meticulous contouring make a difference?

S. Talima\*, M. Al-Daly, E. Alhogaraty

Clinical Oncology department, Kasr Al-Ainy Center of Clinical Oncology and Nuclear Medicine (NEMROCK), Kasr Al-Ainy School of Medicine, Cairo University

## ABSTRACT

**Background:** Due to the current trends towards replacing axillary dissection with radiotherapy, the need for more precise definition for different nodal stations becomes a must to ensure safe and adequate dose coverage. So, our study aimed to evaluate the coverage of axillary nodal volumes based on Project on Cancer of the Breast (PROCAB) guidelines, for cases previously treated with our standard tangential approach. **Materials and Methods:** Ten cases of previously treated patients diagnosed with breast cancer were included in this study. All patients were treated with three dimensional (3D) conformal radiotherapy. For each patient, a new contouring based on PROCAB guidelines were done for each lymph node (LN) station. An adequate dose coverage was assessed for all volumes using our Eclipse version 11 planning system. **Results:** From Jan. 2016 and March. 2016, ten patients who were pathologically confirmed to have breast cancer and treated at Kasr Alaini Centre of Clinical Oncology and Nuclear Medicine, Cairo University, Egypt were included. The mean volumes of axillary levels I, II, and III were 33.29 cm<sup>3</sup> (range 18.6 – 54.8cm<sup>3</sup>), 13.27 cm<sup>3</sup> (range 9.4–16.8 cm<sup>3</sup>), and 12.84 cm<sup>3</sup> (range 7.9–18.2 cm<sup>3</sup>), respectively. Level I, II and III lymph nodes received a median D98% of 7.82 Gy, 9.54 Gy, and 22.54 Gy, respectively. The mean dose was 34.94 Gy, 33.64 Gy, and 39.79 Gy, respectively. **Conclusion:** PROCAB guidelines present a method for standardization of axillary LN delineation. More advanced radiotherapy planning is needed to improve coverage of axilla in post-operative treatment of breast cancer.

**Keywords:** Breast cancer, radiation therapy, PROCAB guidelines, axillary lymph node.

## ► Short Report

**\*Corresponding authors:**

Soha Talima, PhD.,

**E-mail:**

soha\_talima@hotmail.com

Revised: July 2018

Accepted: August 2018

Int. J. Radiat. Res., July 2019;  
17(3): 473-478

DOI: 10.18869/acadpub.ijrr.17.3.473

## INTRODUCTION

In breast cancer, the role of post-operative radiotherapy has shown a clear survival advantage in node-positive disease. This has been confirmed in multiple randomized clinical trials, which have long been regarded as a corner stone in different clinical guidelines<sup>(1-3)</sup>.

Recently, the goal of avoiding axillary lymph nodal dissection (ALND) to reduce later lymphedema has been confirmed by two clinical trials, the AMAROS and ACOSOG trials (The American College of Surgeons Oncology Group Z0011 trial). Both studies confirmed the safety

of replacing ALND with regional nodal radiotherapy in selected early-stage breast cancer patients (those with limited sentinel node involvement)<sup>(4-6)</sup>. As a result of these practice-changing studies, proper coverage of axillary lymph nodes (ALN) has become more important.

Moreover, due to the advancement of treatment techniques, such as intensity modulated radiation therapy (IMRT) and volumetric modulated arc therapy (VMAT), more meticulous delineation of regional lymphatics has become inevitable. Clear volume definitions are needed to reach the optimum

goal of maximum target coverage without exceeding the risk tolerance for nearby organs.

PROCAB is a precise vessel-based contouring atlas <sup>(7)</sup> that perfectly describes each ALN station based on an axillary vessel course, and it uses blood vessels as a surrogate marker for draining lymphatics, such as the head and neck atlas <sup>(6)</sup>. Muscles, such as the sternomastoid, trapezius and pectoralis minor, are also used to define the anatomical boundaries of lymph node stations. PROCAB presents a new way of defining peripheral lymphatics delineation and allows precise dose prescription for cancer breast <sup>(7)</sup>.

The aim of this study was to evaluate the coverage of different axillary stations using PROCAB definitions for previously treated patients and to re-evaluate axillary coverage using our high tangential fields approach.

## MATERIALS AND METHODS

### *Patient's population*

The study was approved by our institutional ethical committee in September 2015 (No: 20159165). Ten cases of previously treated patients diagnosed with breast cancer were included in this study. The patient population included both right and left breast cancers of different stages that were treated via both conservative surgery and modified radical mastectomy. All patients were treated with three dimensional (3D) conformal radiotherapy. The treatment protocol at our department is to irradiate the clinical target volume (CTV) of the supraclavicular lymph node (LN) as well as the chest wall or breast based on Radiation Therapy Oncology Group (RTOG) guidelines without axillary LN irradiation on a daily basis.

### *Study design*

For each patient, contouring of the axillary LN based on PROCAB guidelines was performed and recalculated using ECLIPSE version 11 to assess the coverage of different axillary lymph node stations without any adjustment of the baseline plan. Each group of axillary lymph nodes was

contoured as a separate CTV and named as I, II, or III as well as the new supraclavicular station according to the definitions of the PROCAB to allow separate dose description per station.

### *PROCAB definition of the ALN volumes*

The PROCAB guidelines for delineation of target volumes were used, including <sup>(7)</sup>:

#### *level I:*

Superior border: Starting at the cross of axillary artery to the lateral border of pectoralis minor.

Inferior border: opposite to the level of the 4<sup>th</sup> or 5<sup>th</sup> ribs.

Anterior border: the lateral border of pectoralis major.

Posterior border: the lateral border of deltoid muscle (superiorly) and latissimus dorsi (inferiorly).

#### *level II:*

Superior border: the group lies in a more horizontal ending upwards with the cross of axillary artery to medial border of pectoralis minor.

Inferior border: inferior to axillary vein by 5mm located at the lateral border of pectoralis minor.

#### *Level III:*

It starts cranially when the subclavian artery exists the thorax to become axillary artery. Its caudal end at 5mm below the axillary vein where it crosses the medial border of the pectoralis minor muscle.

All axillary volumes were contoured by two senior radiation oncologists and reviewed by an expert radiologist.

### *Planning*

All selected patients were previously treated with 3D CRT using a single isocenter that included the breast and/or chest wall with two tangential fields and added forward planned segments. The supraclavicular field was treated with an anterior oblique field and with a posterior field when needed. A dose of 45 Gy was delivered in 20 fractions to the entire breast or chest wall and ALN.

### Data evaluation and statistical analysis

Dose-volume histograms (DVH) for the PROCAB target volumes were used to calculate the doses for the CTV of the axillary nodal levels. Additionally, the DVH for the breast or chest wall and heart and ipsilateral lung were used. Mean doses for doses received by 95% and 90% of the axillary levels I, II, and III were calculated.

DVH data to assess the coverage of each axillary station, levels I, II, and III and the breast and/or chest wall doses to the organs at risk were also obtained.

Data were analyzed using IBM SPSS advanced statistics version 20 (SPSS Inc., Chicago, IL). Numerical data of scores were expressed as mean and range or median and range as appropriate. Qualitative data were expressed as number and percentage.

## RESULTS

From Jan. 2016 and March. 2016, ten patients who were pathologically confirmed to have breast cancer and treated at Kasr Alaini Centre

of Clinical Oncology and Nuclear Medicine (NEMROCK), Cairo University, Egypt were included. Age of the included patients ranged from 39 to 66 years, and the study included both right and left side presentation. Additionally, the cases included both post mastectomy and conservative breast surgeries.

The mean breast CTV volume was 657 cm<sup>3</sup> (range of 335.4–992.4 cm<sup>3</sup>). Median D95% was 42.06 Gy (range 41– 42.88 Gy) that received by 95% of CTV breast as showed in table (1). Median dose to 98% of the CTV of the breast was 41.44 (40.36-42.07).

The mean volumes for axillary levels I, II, and III were 33.29 cm<sup>3</sup> (range of 18.6–54.8 cm<sup>3</sup>), 13.27 cm<sup>3</sup> (range of 9.4–16.8 cm<sup>3</sup>) and 12.84 cm<sup>3</sup> (range of 7.9–18.2 cm<sup>3</sup>), respectively.

Dose coverage for 95% of the prescribed dose for each axillary LN CTV volume was assessed separately as presented in table (1). Level I, II and III lymph nodes received a median D98% of 7.82 Gy, 9.54 Gy, and 22.54 Gy, respectively. The mean dose was 34.94 Gy, 33.64 Gy, and 39.79 Gy, respectively.

**Table 1.** Coverage of axillary levels I, II, III and CTV breast for the 10 patients plans.

Targets	Dose-volume parameters	Median (Range)
Level I	Mean dose (Gy)	34.94 (0.27-38.52)
	D98% (Gy)	7.825 (0-24.79)
	D95% (Gy)	12.44 (0.04-29.11)
	D90% (Gy)	20 (0.09-32.53)
Level II	Mean dose (Gy)	33.64(1.26-40.27)
	D98% (Gy)	9.54 (0.36-20.88)
	D95% (Gy)	18.45 (0.25-28.76)
	D90% (Gy)	17.50 (0.45-32.44)
Level III	Mean dose (Gy)	39.79 (0.86-44.50)
	D98% (Gy)	22.54 (0.4-40.95)
	D95% (Gy)	28.38 (0.45-42.39)
	D90% (Gy)	32.71 (0.49-43.06)
CTV breast	Mean dose (Gy)	45.13 (44.86-45.58)
	D98% (Gy)	41.44 (40.36-42.07)
	D95% (Gy)	42.06 (41-42.88)
	D90% (Gy)	43.07 (42.61-43.42)

CTV, clinical target volume; D98%: dose delivered to 98% of the target; D95%: dose delivered to 95% of the target; D90%: dose delivered to 90% of the target

## DISCUSSION

As a result of using ALN irradiation instead of ALN dissection in sentinel lymph node-positive breast cancer and the new era of three dimensional CT-based radiotherapy, the precise definition of level I, II and III axillary nodal volumes has become more important, especially when IMRT is indicated.

Different data confirmed that standard tangential fields failed to cover levels I and II adequately. In a study performed by Krasin et al, only 1 out of 25 patients had adequate coverage of the level I region and none of the patients had adequate coverage of level II <sup>(8)</sup>. Similarly, Alco, *et al.* showed that covering the axillary volumes with high tangential fields result in inadequate coverage with a wide range of mean doses delivered to levels I and II (16.7–50.4Gy and 4.5–50.27Gy, respectively) <sup>(9)</sup>. Also, Belkacemi *et al.*, showed that mean doses ranged from 1 to 57 Gy (median 22 Gy) to level I and 0–46 Gy (median 4 Gy) to level II <sup>(10)</sup>.

Another study by Zunino *et al.*, who reported the coverage of the sentinel node volume during tangential irradiation in 31 patients. They showed that 95% of the sentinel node volume received only 6.9–27.5 Gy of the prescribed dose of 50 Gy <sup>(11)</sup>.

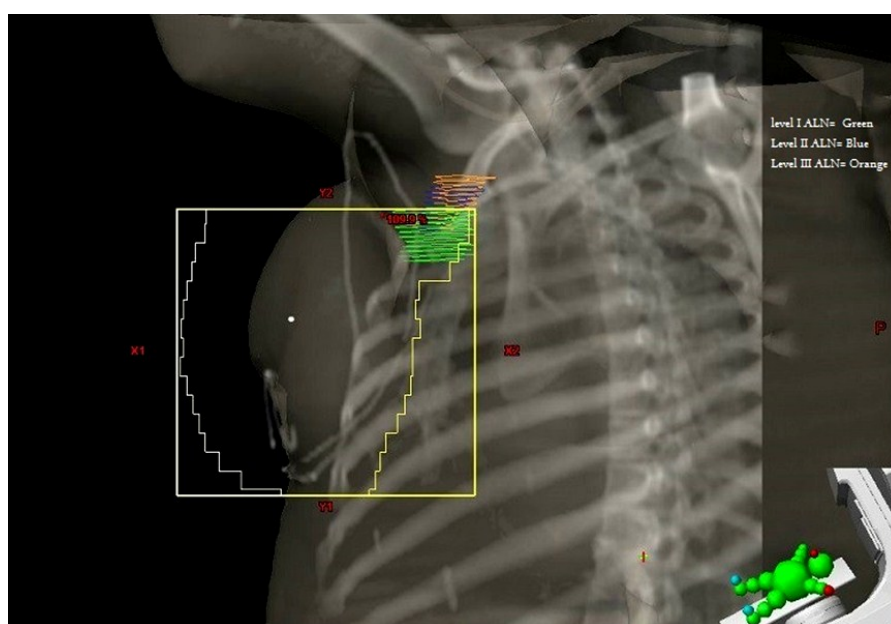
Even with high tangential fields where the upper border up to the head of the humerus, there is still inadequate coverage of level I, II ALN. A study by Reznik et al which used HTF concluded that it can increase the average dose to level I, II ALN from 66%

and 44% to 86% and 71%, respectively but still isn't adequate <sup>(12)</sup>.

In our study, we evaluated the dose distribution and coverage of previously treated cases, using the definitions of PROCAB for different axillary levels, using our standard practice of forward planning and field-in-field technique. Evaluation of the doses received by axillary nodal regions and normal risk structures were done. The mean D95% was only 11.6 Gy for level I, 11.9 Gy for level II and 25.8 Gy for level III indicating markedly insufficient axillary coverage of the tangential field as shown in figures 1 and 2.

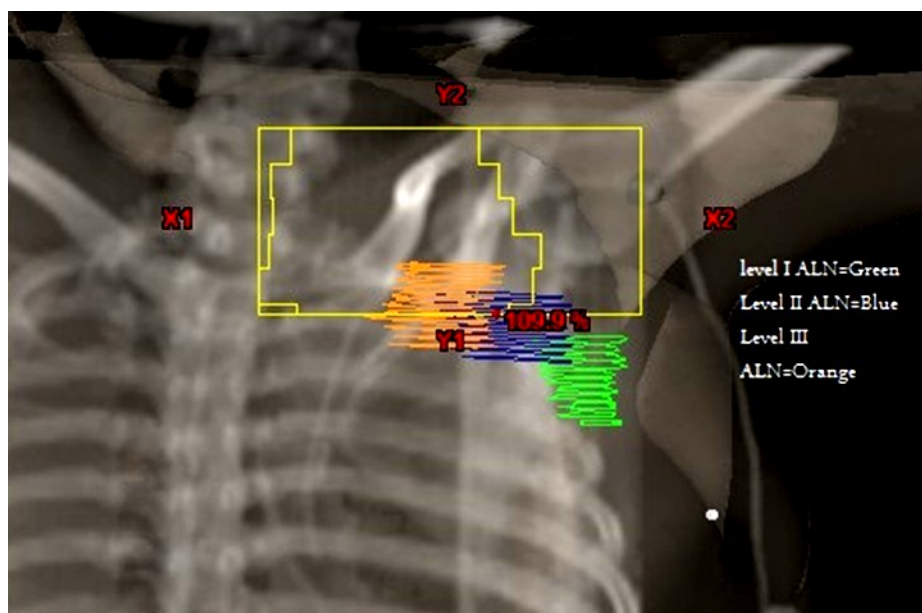
As for other anatomical subsites eg. Head and Neck cancer, endometrial carcinoma, nodal CTV atlas <sup>(6,13)</sup> allowed for more standardization of clinical practice, minimizing interobserver delineation variability, and lastly improving treatment outcomes. PROCAB is similar to other CT based contouring guidelines <sup>(7)</sup> relying on axillary and subclavian veins such as a surrogate for lymphatics rather than relying on muscles course and bony landmarks, this allows more individualized treatment fields based on each patient vessels anatomy regardless to the treatment position.

Comparing PROCAB-based delineation to other delineation guidelines, such as the RTOG should be done. This would assess whether the more generous RTOG volumes would have better coverage when compared to PROCAB with the standard fields, and consequently assess the need for future fields' modification or addition when it is used.



**Figure 1.** Digitally reconstructed radiograph showing the high tangential field: the cranial border of the tangential field is set 2 cm below the humeral head. Axillary nodal levels are shown.





**Figure 2.** Conventional supraclavicular field of the same patient showing the under coverage of different axillary levels and the incoherence between ordinary skeletal based fields and vessel based contouring.

## CONCLUSION

Because of the need for a more precise irradiation of axillary LN stations, even high tangential fields failed to cover whole axilla properly, and the PROCAB guidelines present a method for standardizing the axillary LN delineation. In addition, more advanced radiotherapy planning is needed to improve the coverage of axilla in post-operative treatment of breast cancer.

**Conflicts of interest:** Declared none.

## REFERENCES

- Overgaard M, Hansen PS, Overgaard J, Rose C, Andersson M, Bach F, et al. (1997) Postoperative radiotherapy in high-risk premenopausal women with breast cancer who receive adjuvant chemotherapy. Danish Breast Cancer Cooperative Group DBCG 82b Trial. *N Engl Med*, **337**: 949-55.
- Overgaard M, Jensen MB, Overgaard J, Hansen PS, Rose C, Andersson M, et al. (1999) Postoperative radiotherapy in high-risk postmenopausal breast-cancer patients given adjuvant tamoxifen. Danish Breast Cancer Cooperative Group DBCG 82c randomized trial. *Lancet*, **353**: 1641-8.
- Ragaz J, Jackson SM, Le N, Plenderleith LH, Spinelli JJ, Basco VE, et al. (1997) Adjuvant radiotherapy and chemotherapy in node-positive premenopausal women with breast cancer. *N Engl Med*, **337**: 956-62.
- Giuliano AE, Hunt KK, Ballman KV, Beitsch PD, Whitworth PW, Blumencranz PW, et al. (2011). Axillary dissection vs no axillary dissection in women with invasive breast cancer and sentinel node metastasis. A randomized clinical trial. *JAMA*, **305**: 569-75.
- Donker M, van Tienhoven G, Straver ME, Meijnen P, van de Velde CJ, Mansel RE, et al. (2014) Radiotherapy or surgery of the axilla after a positive sentinel node in breast cancer (EORTC 10981-22023 AMAROS): a randomized, multicenter, open label, phase 3 non-inferiority trial. *Lancet Oncol*, **15**: 1303-10.
- Gregoire V, Ang K, Budach W, Grau C, Hamoir M, Langendijk JA, Lee A, et al. (2013). Delineation of the neck node levels for head and neck tumors: A 2013 update. DAHANCA, EORTC, HKNPCSG, NCIC CTG, NCRI, RTOG, TROG consensus guidelines. *Radiotherapy and Oncology*, **110**: 172-181. doi: 10.1016/j.radonc.2013.
- Verhoeven K, Weltens C, Remouchamps V, Mahjoubi K, Veldeman L, Lengele B, et al. (2015) Vessel based delineation of guidelines for the elective lymph nodes regions in breast cancer radiation therapy-PROCAB guidelines. *Radiother Oncol*, **114**: 11-16.
- Krasin M, McCall A, King S, Olson M, Emami B (2000) Evaluation of a standard breast tangent technique: a dose-volume analysis of tangential irradiation using three-dimensional tools. *Int J Radiat Oncol Biol Phys*, **47**: 327-33.
- Alco G, I'lgdem S, Ercan T, Dinçer M, Sentürk R, Atilla S, et al. (2010) Coverage of axillary lymph nodes with high tangential fields in breast radiotherapy. *The British Journal of Radiology*, **83**: 1072-1076.

10. Belkacemi Y, Bigorie V, Pan Q, Bouaita R, Pigneur F, Itti E, *et al.* (2014) Breast radiotherapy (RT) using tangential fields (TgF): a prospective evaluation of the dose distribution in the Sentinel Lymph Node (SLN) area as determined intraoperatively by clip placement. *Annals of Surgical Oncology*, **21**: 3758–3765.
11. Zunino SB, Garrigo ER, Garelo NC, *et al.* (2007). Dose received by the sentinel node volume during tangential radiation therapy to the breast. *Radiat Oncol*, **82**: 329–31.
12. Reznik J, Cicchetti MG, Degaspe B, Fitzgerald TJ (2005) Analysis of axillary coverage during tangential radiation therapy to the breast. *Int J Radiat Oncol Biol Phys*, 61:163–8.
13. Small W, Bosch WR, Strauss JB, Albuquerque K, Beriwal S, Creutzberg CL, *et al.* (2014) Consensus Guidelines for Delineation of Clinical Target Volume for Intensity-Modulated Pelvic Radiation Therapy in Postoperative Treatment of Endometrial and Cervical Cancer- An Update. *Int J Radiat Oncol Biol Phys*, 90(1) S109.