

Spironolactone ameliorates the radiation-induced late fibrosis in salivary glands in a rat model

C. Elsurer¹, Z.E. Celik², G. Yavas^{3*}, C. Yavas³

¹Selcuk University, Department of Ear, Nose and Throat, Konya, Turkey

²Selcuk University, Department of Pathology, Konya, Turkey

³Selcuk University, Department of Radiation Oncology, Konya, Turkey

ABSTRACT

► Original article

*Corresponding authors:

Guler Yavas, MD.,

Fax: + 90 332 241 6065

E-mail:

guler.aydinyavas@gmail.com

Revised: January 2018

Accepted: February 2018

Int. J. Radiat. Res., January 2020;
18(1): 149-155

DOI: 10.18869/acadpub.ijrr.18.1.149

Background: Management of head and neck cancer includes surgical resection, chemotherapy and radiotherapy (RT). We hypothesized that pre-radiation treatment with a mineralocorticoid receptor (MR) antagonist, spironolactone (S), may have radioprotective effect on salivary glands. **Materials and Methods:** Study included 30 adult female Wistar albino rats. Rats were divided into four groups (G); G1, control group; G2, RT-only group, G3, S-only group; G4, RT plus S group. Rats were sacrificed at 6th hour; 21st and 100th days after RT. Salivary gland samples were taken for microscopical examination. **Results:** Periductal-perivascular inflammation scores in 21st and 100th days tended to be higher in G2 than in G4, but the difference was not statistically significant. Periductal-perivascular fibrosis score was significantly different between the groups in 100th day (P: 0.010). Pairwise comparisons revealed that periductal-perivascular fibrosis scores were different between G1 and G2 (P: 0.014), G2 and G3 (P: 0.014), G2 and G4 (P: 0.034). **Conclusions:** MR blockade with S, when initiated before RT, ameliorates late radiation-induced fibrosis in the submandibular glands.

Keywords: Inflammation, fibrosis, salivary gland, submandibular gland, radiotherapy, rat.

INTRODUCTION

Head and neck cancer is the 6th most common cancer in the world ⁽¹⁾. Worldwide, head and neck cancer accounts for more than 550,000 cases annually. The 5-year survival rate of these patients is approximately 50% for non-metastatic locally advanced disease ⁽²⁾. The standard care includes surgical resection of the tumor, and a combination of chemotherapy and radiotherapy (RT) ⁽¹⁾. While RT significantly improves survival, exposure to ionizing radiation usually results in unavoidable co-irradiation of the normal tissues surrounding the tumor ⁽²⁾. Salivary glands are small organs in the head and neck region and have a high impact on the quality of life. Salivary glands are among these normal tissues affected by ionizing radiation, since the ionizing beams have to pass

the salivary glands to reach the tumor ^(2,3).

Xerostomia and mucosal damage are well-known radiation-induced complications in patients with head and neck cancer ⁽⁴⁾. Reduced salivary gland function and oral health-related quality of life are typical complications of RT. These complications may be acute (reversible) or chronic (sometimes may be lifelong) ⁽³⁾. Current methods to prevent salivary gland damage are; (i) radiation techniques to reduce radiation injury to the salivary gland tissue, (ii) surgical techniques to relocate salivary glands to a region receiving a lower cumulative radiation dose, and (iii) techniques to make salivary gland cells more resistant to radiation injury. These preventive techniques are not applicable in all cases. Moreover, such techniques may reduce the tumor sensitivity or may be insufficient in the amelioration of the dryness-related

complaints. Therefore, alternative methods are explored to salvage salivary glands from radiation injury ⁽²⁾. Many prophylactic modalities have been suggested to increase the tolerance of salivary glands to radiation; including depletion of secretory granula by muscarinic alkaloid pilocarpine, pretreatment with the free-radical scavenger amifostine, increasing proliferation of acinar and intercalated ductal cells by pilocarpine, and stem cell therapy to replace damaged cells. Additionally, aquaporin-1 gene transfer, which led to increased fluid secretion from surviving duct cells, has been tested ⁽⁵⁾.

Aldosterone is a steroid hormone with mineralocorticoid activity. Beyond this well-known action, various animal models have demonstrated that aldosterone exerts other effects in kidney, blood vessels and heart, which may have pathophysiological consequences including inflammation, tissue remodeling and fibrosis. Aldosterone mediates its effects mainly by the mineralocorticoid receptor (MR) ⁽⁶⁾. The MR is a member of the steroid receptor family and regulates systemic blood pressure by mediating the effects of aldosterone on renal sodium handling. Recent studies showed that the MR also regulates systemic vascular function, through mechanisms independent of its actions on the kidney. Mineralocorticoid receptor activation may alter vascular function via genomic mechanisms, in which MR functions as a ligand-activated transcription factor to modulate vascular gene expression, and via nongenomic mechanisms that intersect with multiple important vascular signaling pathways such as those of epidermal growth factor (EGF), platelet-derived growth factor (PDGF), insulin-like growth factor (IGF)-1, and angiotensin II. Mineralocorticoid receptor is expressed in the endothelial cells and in the vascular smooth muscle cells, where it promotes proliferation and fibrosis after injury. Mineralocorticoid receptor also promotes generation of reactive oxygen species and vascular oxidative stress, which in turn stimulate cell proliferation ⁽⁷⁾. The proinflammatory and profibrotic effects of aldosterone are prevented by MR antagonism in

most models ^(8,9). Spironolactone was first developed over 50 years ago as a potent MR antagonist ⁽¹⁰⁾.

In the current study, we hypothesized that pre-radiation treatment with a potent MR antagonist, spironolactone, may have protective effects on the salivary glands in a rat model.

MATERIALS AND METHODS

Study design

The study had an experimental design and was approved by the Necmettin Erbakan University Animal Care and Use Committee. Totally, 30 adult female Wistar albino rats (250–300 g) were included. The care and handling of the animals were in accord with the guidelines for ethical animal research. Animals were housed four per cage in a controlled animal holding room with a 12-h light/12-h dark cycle; temperature and relative humidity were continuously monitored to provide standard laboratory conditions. Food and water were provided ad libitum. Rats were divided into four groups (G). G1 (n: 8) was defined as control group. G2 (n: 6) and G3 (n: 7) were RT and S-only groups, respectively. G4 (n: 9) was RT plus S group (table 1). As an end point, periductal-perivascular inflammation and periductal-perivascular fibrosis were quantified with image analysis of histological sections of the submandibular glands.

Table 1. The abbreviations used for the study groups.

Group (G)	Description	N
G1	Control group	8
G2	15 Gy RT group	6
G3	Spironolactone group	7
G4	15 Gy RT + spironolactone group	9

Radiotherapy protocol

RT was applied under general anesthesia with intraperitoneally administered 90 mg/kg ketamine hydrochloride (Ketalar®, EWL Eczacibasi Warner Lambert Ilaç Sanayi ve Ticaret A.S., Istanbul, Turkey) and 10 mg/kg xylazine (Rompun® 2%, Bayer Kimya San. Ltd. Sti., Istanbul, Turkey). The animals were

stabilized in the supine position, and the head and neck region of each rat was defined by simulation. A single dose of 15 Gy, with 6-MV photon beams, was applied to the head and neck region via two parallel opposed fields with source-axis distant technique.

Spironolactone protocol

Spironolactone (Aldakton-AÖ, Ali Raif İlaç San. A.Ş., İstanbul, Türkiye) was administered by oral gavage at a dose of 80 mg/kg in rats in G3 and G4. We began to administer spironolactone 1 week before the RT started and continued until the rats were sacrificed.

Histopathological examination

Animals were sacrificed by cervical dislocation at 6th hour, 21st day and 100th day of the RT. The submandibular gland samples were obtained from each rat. The glandular samples were fixed in 10% formaldehyde solution and embedded in paraffin for light microscopic examination. The slices obtained were stained with hematoxylin eosin to evaluate periductal-perivascular inflammation and with masson trichrome to evaluate periductal-perivascular fibrosis. On each slice, five different areas were examined on light microscope at 100X magnification. As a quantitative end point, periductal-perivascular inflammation and periductal-perivascular fibrosis were graded as follows; Score 0, absent; Score 1, mild; Score 2, moderate; Score 3, severe. The pathologist was blinded to the treatment groups. After histopathological examination was completed, the mean values for periductal-perivascular inflammation and periductal-perivascular fibrosis were calculated for each group.

Statistical analysis

Statistical analysis was performed using SPSS 15.0 for Windows (SPSS Inc., IL, USA). As the pathological scores were ordinal in nature, the differences in pathological findings between the study groups were analyzed using the Kruskal–Wallis test. When an overall statistically significant difference was observed, pairwise comparisons were performed using the

Mann–Whitney U test.

RESULTS

Periductal-perivascular inflammation

In the 6th hour specimens, inflammation was observed in only one rat in G1. The other rats did not have any histopathological evidence of inflammation. In the 21st day, inflammation was observed in two rats in G2 and two rats in G4. Although the inflammation score tended to be higher in G2 than in G4, the difference was not statistically significant. In the 100th day, inflammation was observed in 1 rat in G1, in all the three rats in G2, in one rat in G3 and in 2 rats in G4. Although the inflammation score tended to be higher in G2 than in G4, the difference was not statistically significant. Figures 1 and 2 demonstrate the periductal-perivascular inflammation in the 100th day specimens. In summary, the inflammation scores in 6th hour, 21st day and 100th day specimens were not different between the four groups (P values; 0.112, 0.172, 0.118, respectively). Table 2 demonstrates the periductal-perivascular inflammation scores of the study groups.

Periductal-perivascular fibrosis

In the 6th hour specimens, none of the samples within four groups showed any histopathological evidence of periductal-perivascular fibrosis. Therefore, a comparison analysis was not performed. In the 21st day specimens, periductal-perivascular fibrosis was observed in all rats in G2 and in all rats, except for one, in G4. The periductal-perivascular fibrosis scores were not different between the study groups in 21st day (P: 0.151). In the 100th day, the periductal-perivascular fibrosis score was significantly different between the groups (P: 0.010). Table 3 demonstrates the periductal-perivascular fibrosis scores of the study groups. Pairwise comparisons revealed that the periductal-perivascular fibrosis scores were different between G1 and G2 (P: 0.014), G2 and G3 (P: 0.014), G2 and G4 (P: 0.034). Figure 3 and figure 4 demonstrate the

periductal-perivascular fibrosis in the 100th day specimens. Since none of the rats in G1 and G3 demonstrated periductal-perivascular fibrosis in the 100th day, a comparison analysis was not

performed between G1 and G3. Table 4 demonstrates the results of pairwise comparison analysis.

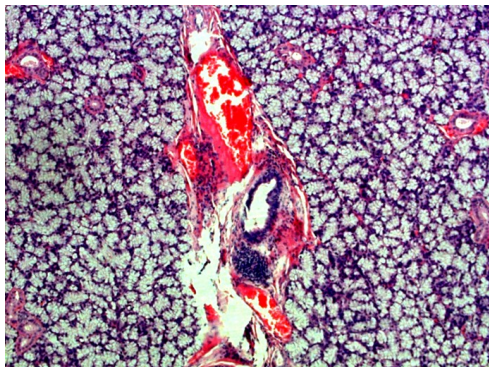


Figure 1. Severe (score 3) periductal-perivascular inflammation in the 100th day in G2. (Hematoxylin eosin ×100).

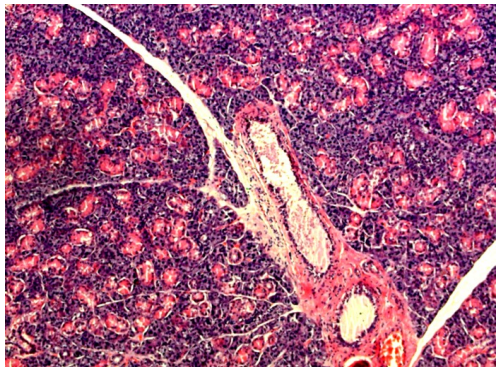


Figure 2. Mild (score 1) periductal-perivascular inflammation in the 100th day in G4. (Hematoxylin eosin ×100).

Table 2. The periductal-perivascular inflammation scores of the study groups.

Group	Mean	Median	Minimum	Maximum	P value
6 th hour					
G1	0	0	0	0	0.112
G2	1	1	1	1	
G3	0	0	0	0	
G4	0	0	0	0	
21 st day					
G1	0	0	0	0	0.172
G2	1.5	1.5	1	2	
G3	0	0	0	0	
G4	0.5	0.5	0	1	
100 th day					
G1	0	0	0	0	0.118
G2	1.5	1.5	1	2	
G3	0	0	0	0	
G4	0.5	0.5	0	1	

Table 3. The periductal-perivascular fibrosis scores of the study groups.

Group	Mean	Median	Minimum	Maximum	P value
6 th hour					
G1	0	0	0	0	-
G2	0	0	0	0	
G3	0	0	0	0	
G4	0	0	0	0	
21 st day					
G1	0	0	0	0	0.151
G2	1	1	1	1	
G3	0	0	0	0	
G4	0.75	1	0	1	
100 th day					0.010
G1	0	0	0	0	
G2	1	1	1	1	
G3	0	0	0	0	
G4	0.75	1	0	1	

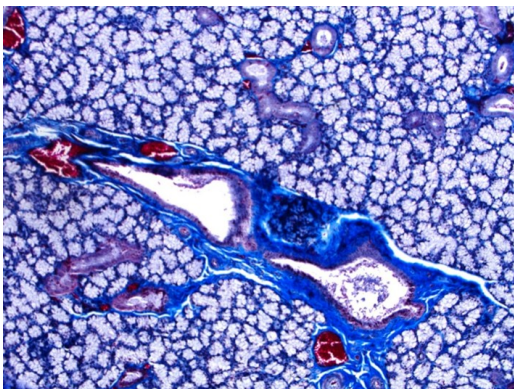


Figure 3. Severe (score 3) periductal-perivascular fibrosis in the 100th day in G2. (Masson trichrome ×100).

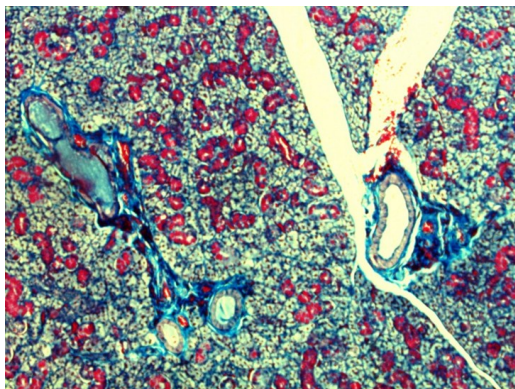


Figure 4. Mild (score 1) periductal-perivascular fibrosis in the 100th day in G4. (Masson trichrome ×100).

Table 4. Pairwise comparison analysis of the four groups regarding the periductal-perivascular fibrosis scores.

Group 1	Group 2	P
G1	G2	0.014
G1	G3	-
G1	G4	0.074
G2	G3	0.014
G2	G4	0.034
G3	G4	0.074

DISCUSSION

Head and neck cancers account for approximately 5% of all cancers in the United States. In patients who undergo head and neck RT, significant damage to the salivary glands may occur ⁽¹¹⁾. In this study, we investigated the effect of MR antagonism, via a potent MR antagonist, spironolactone, on the radiation-induced inflammation and fibrosis in the salivary glands in a rat model. Although we observed a trend for higher scores of inflammation in 21st and 100th days for G2 (RT only group) than for G4 (RT plus S group), the difference was not statistically significant. In the 100th day, the periductal-perivascular fibrosis score was higher for G2 than all other groups. Interestingly, in the 100th day, the periductal-perivascular fibrosis score for G2 (RT only group) was significantly higher than for G4 (RT plus S group), indicating a preventive effect of MR blockade when initiated before RT, on radiation-induced fibrosis in the salivary glands. This is the first study in the literature demonstrating that MR blockade ameliorates the radiation-induced late fibrosis in salivary glands in rats.

Aldosterone is a steroid hormone and a role for aldosterone has been implicated in the inflammatory response. The hormone increases the expression of intercellular adhesion molecule 1 (ICAM-1), a key adhesion molecule that is involved in inflammation and also increases the expression of inflammatory cytokines, such as interleukin (IL)-1 β and IL-6, C-C motif chemokine 2 (CCL2, also known as MCP

-1), osteopontin and connective tissue growth factor (CTGF) ⁽⁶⁾. Administration of aldosterone induces collagen synthesis via actions on the MR and cell signaling involving ERK1/2. The profibrotic action of aldosterone is partly mediated by transforming growth factor β -1 (TGF β -1). TGF β -1 enhances collagen synthesis, reduces matrix metalloproteinase expression and promotes fibroblast proliferation ⁽⁸⁾. Aldosterone mediates its effect mainly by the MR ⁽⁶⁾. Studies have shown that MR antagonism may prevent the proinflammatory and profibrotic effects of aldosterone ^(8,9). In this study, we firstly tested the effect of the potent MR antagonist, spironolactone, on radiation-induced inflammation and fibrosis in a rat model.

Dysfunction of the salivary glands following radiation occurs in two stages; acute and chronic. Clinically, acute salivary gland dysfunction occurs within days following radiation and is characterized by loss of salivary flow, loss of acinar cells, glandular shrinkage and changes in saliva composition. Chronic salivary gland dysfunction occurs months to years following radiation and is characterized by reduced salivary flow and changes in saliva composition ⁽¹⁾. The submandibular glands continuously secrete mixed serous and mucous saliva and the volume accounts for >60% of unstimulated daily secretions. These glands are responsible for resting saliva secretion and providing night-time moisture for the oral cavity ⁽³⁾. The radiation creates a "3 H" effect on the tissue; hypovascular, hypocellular and hypoxic ⁽¹²⁾. In humans, an acute inflammatory reaction occurs in the serous acini within hours of radiation. Gland atrophy continues after the radiation has ceased, leading to replacement with fibrosis within the parenchyma of the submandibular glands. Despite the presence of periductal inflammation and interlobular dilation, the ductal system appears to remain intact ⁽¹³⁾. Late radiation-induced salivary gland damage is pathologically characterized by the loss of epithelial saliva-producing acinar cells, dilated vasculature, altered neuronal innervation, and all or not combined with various grades of fibrosis resulting in

irreversible hyposalivation ^(14,15). Liping *et al.* showed that pathological fibrosis of the submandibular glands, marked by excessive deposition of extracellular matrix proteins in response to tissue injury, was associated with pronounced over expression of TGF- β 1 ⁽¹²⁾.

A number of drugs have been used to reduce the sensitivity of the salivary glands to radiation among which are amifostine, tempol, pilocarpine, keratinocyte growth factor, IGF-1, roscovitine and basic fibroblast growth factor ⁽²⁾. Unfortunately, none of the radioprotective drugs currently available has all the requisite qualities of an ideal radioprotector. Their use encounters two great difficulties; their dose-limiting toxicity and the short period during which they are active, which limited their clinical administration ⁽¹⁶⁾. In this study, we introduced a well-known MR antagonist, spironolactone, as a novel radioprotector. We demonstrated that spironolactone had favorable effects on late radiation-induced fibrosis in rats. In this study, we found that spironolactone ameliorated late (100th day) radiation-induced periductal-perivascular fibrosis in the submandibular gland tissue in rats. Although there was a trend for less inflammation with sprinolactone administration, the difference was not significant. We suggest there may be at least three explanations for this; ⁽¹⁾ the sample size was small to reach a statistical significance, since a general favorable trend was observed, ⁽²⁾ the inflammatory pathway involved in radiation-induced inflammation in rats was not MR-dependent or ⁽³⁾ the dose used was insufficient to inhibit inflammation. Although an association between spironolactone use and reduced fibrosis was demonstrated, we cannot explain the exact mechanism(s). However, speculations can be made; both radiation and MR activation may have intersecting pathways such as IGF-1 and TGF β -1, which may be responsible for the effect observed in our study.

Our study has limitations that deserve mention. We did not assess salivary flow rate, therefore we cannot speculate whether decreased late radiation-induced fibrosis associated with spironolactone administration actually translates into decreased salivary gland dysfunction. We did not match our results with

simultaneous aldosterone levels. However, what we focused on was the MR blockade; MR can be activated by ligands other than aldosterone and therefore reducing aldosterone concentrations are not necessarily followed by reduced inflammation. Finally, we bear in mind that there are interspecies differences in responses to radiation-induced damage and as all preclinical studies; our study bears the limitation that animal models may not recapitulate human disease.

In conclusion, our study demonstrated that MR blockade with spironolactone, when initiated before RT, ameliorates late radiation-induced fibrosis in the submandibular glands. This is the first study in the literature demonstrating the radioprotective effect of MR blockade in salivary glands in rats. Whether reduced salivary gland fibrosis induced by spironolactone translates into decreased salivary gland dysfunction remains to be elucidated.

Funding source

This work was supported by Selcuk University. There is no role of study sponsors in the study design, in the collection, analysis and interpretation of data; in the writing of the manuscript and in the decision to submit the manuscript for publication.

Conflicts of interest: Declared none.

REFERENCES

1. Martin KL, Hill GA, Klein RR, Arnett DG, Burd R, Limesand KH (2012) Prevention of radiation-induced salivary gland dysfunction utilizing a CDK inhibitor in a Mouse model. *PLoS One*, **7(12)**: e51363.
2. Vissink A, van Luijk P, Langendijk J, Coppes R (2014) Current ideas to reduce or salvage radiation damage to salivary glands. *Oral Dis*, ??-??: ?? [Epub ahead of print].
3. Kałużny J, Wierzbicka M, Nogala H, Milecki P, Kopeć T (2014) Radiotherapy induced xerostomia: mechanisms, diagnostics, prevention and treatment—evidence based up to 2013. *Otolaryngol Pol*, **68(1)**: 1-14.
4. Bölling T, Weege J, Eich HT, *et al.* (2014) Acute and late side effects to salivary glands and oral mucosa after head and neck radiotherapy in children and adolescents. Results of the registry for the evaluation of side effects after radio-

- therapy in childhood and adolescence. *Head Neck*, Apr 25. [Epub ahead of print].
5. Su YX, Benedek GA, Sieg P, et al. (2013) Radioprotective effect of lidocaine on neurotransmitter agonist-induced secretion in irradiated salivary glands. *PLoS One*, **8**(3): e60256.
6. Briet M and Schiffrin EL (2010) Aldosterone: effects on the kidney and cardiovascular system. *Nat Rev Nephrol*, **6**(5): 261-73.
7. Preston IR, Sagliani KD, Warburton RR, Hill NS, Fanburg BL, Jaffe IZ (2013) Mineralocorticoid receptor antagonism attenuates experimental pulmonary hypertension. *Am J Physiol Lung Cell Mol Physiol*, **304**(10): L678-88.
8. Gilbert KC and Brown NJ (2010) Aldosterone and inflammation. *Curr Opin Endocrinol Diabetes Obes*, **17**(3): 199-204.
9. Brown NJ (2013) Contribution of aldosterone to cardiovascular and renal inflammation and fibrosis. *Nat Rev Nephrol*, **9**(8): 459-69.
10. Funder JW (2013) Mineralocorticoid receptor antagonists: emerging roles in cardiovascular medicine. *Integr Blood Press Control*, **6**: 129-38.
11. Hadley T, Song C, Wells L, et al. (2013) Does hyperbaric oxygen therapy have the potential to improve salivary gland function in irradiated head and neck cancer patients? *Med Gas Res*, **3**(1): 15.
12. Xu L, Yang X, Cai J, et al. (2013) Resveratrol attenuates radiation-induced salivary gland dysfunction in mice. *Laryngoscope*, **123**(11): E23-9.
13. O'Connell AC (2000) Natural history and prevention of radiation injury. *Adv Dent Res*, **14**: 57-61.
14. Nanduri LS, Lombaert IM, van der Zwaag M, Faber H, Brunsting JF, van Os RP, Coppes RP (2013) Salisphere derived c-Kit+ cell transplantation restores tissue homeostasis in irradiated salivary gland. *Radiother Oncol*, **108**(3): 458-63.
15. Hai B, Yang Z, Shangguan L, Zhao Y, Boyer A, Liu F (2012) Concurrent transient activation of Wnt/ β -catenin pathway prevents radiation damage to salivary glands. *Int J Radiat Oncol Biol Phys*, **83**(1): e109-16.
16. Medina VA, Prestifilippo JP, Croci M, Carabajal E, Bergoc RM, Elverdin JC, Rivera ES (2011) Histamine prevents functional and morphological alterations of submandibular glands induced by ionising radiation. *Int J Radiat Biol*, **87**(3): 284-92.

