

## Management of bulky high-grade pleomorphic sarcoma using grid therapy technique

S. Tajiki<sup>1</sup>, S. Gholami<sup>1,2\*</sup>, A. Kazemian<sup>1</sup>, P. Haddad<sup>1</sup>, M. Esfahani<sup>1</sup>,  
R. Ghalehtaki<sup>1</sup>, A. Rastjoo<sup>1</sup>, F. Pakniyat<sup>2</sup>, A.S. Meigooni<sup>3</sup>

<sup>1</sup>Radiation Oncology Research Center, Tehran University of Medical Sciences, Tehran, Iran

<sup>2</sup>Department of Medical Physics and Biomedical Engineering, Tehran University of Medical Sciences, Tehran, Iran

<sup>3</sup>Comprehensive Cancer Centers of Nevada, Las Vegas, Nevada, United States

### ► Case Report

**\*Corresponding authors:**

Somayeh Gholami, PhD.,

**E-mail:**

s-gholami@sina.tums.ac.ir

Revised: January 2020

Accepted: February 2020

Int. J. Radiat. Res., January 2021;  
19(1): 239-242

DOI: 10.29252/ijrr.19.1.135

### ABSTRACT

In the present study, a case was reported concerning a patient with a bulky extremity soft tissue sarcoma treated with spatially fractionated Grid therapy and then followed by standard external beam radiotherapy. Treatment was performed using a Grid block to deliver 15 Gy in one fraction. There was one week interval break before EBRT treatment with 50 Gy in 25 fractions for the neoadjuvant external beam radiotherapy. The surgery was performed 4 weeks after the completion of radiotherapy. The follow-up time was considered as 24 months. The patient's general condition was good during this period without the presence of tumor recurrence or grade 3 or 4 treatment-related toxicities. Combining different treatment techniques like grid therapy is feasible and may improve the outcomes in the management of bulky high-grade soft-tissue sarcomas of the extremities.

**Keywords:** Sarcoma, radiotherapy, Grid therapy.

### INTRODUCTION

The appropriate oncologic managements of bulky malignant tumors (>8 cm) in the limbs are challenging, particularly for those surrounded by different organ at risks, resulting from the relative radio-resistance of the poorly vascularized tumors, dose constraints of healthy organs, and the need for preserving the function of the affected organ <sup>(1)</sup>. Conventional treatment strategies may not be appropriate as curative modality in all patients with massive tumors and those harboring along with some side effects like functional deficits and impaired quality of life. Thus, we should try our best to escalate the efficacy of prescribed radiation doses for these tumors while protecting healthy surrounding organs.

The delivery of radiation in the neoadjuvant regime is one of the proposed methods used for augmenting the efficacy of radiation. This technique is able to boost the impact of radiation

following a curative resection with maximal organ functional preservation <sup>(2)</sup>. Traditionally, 3D conformal radiation therapy was the most common modality to deliver the appropriate dose to tumor by shielding the organs at risk from radiation. However, due to its inherent limitations, this technique has not been successful in treatment of the bulky malignant tumors, even with different time and fractionation strategies<sup>(3, 4)</sup>. Thus, the local control of bulky tumors with External Beam Radiotherapy (EBRT) is still a challenge <sup>(5)</sup>. As a result, it is essential to use a new treatment technique for management of bulky tumor.

Different studies have confirmed the benefit of using modern radiotherapy techniques with a larger fraction size (hypo-fractionated radiotherapy) as simultaneous integrated boost IMRT, VMAT or SABR/SRS in radio-resistant tumors <sup>(1, 6-8)</sup>. Another technique, known as Spatially Fractionated Grid Radiotherapy (SFGRT) is also a safe method delivering high

dose to the site of bulky tumors (>8 cm). SFGRT is applied by creating a checkerboard pattern using a multi-leaf collimator (9-11) or a previously designed block (9,12,13). In this way, the target is irradiated with a special pattern of beam along with a non-homogenous radiation dose. In this technique, radiation passes through hole-block patterns of the Grid and is converted to a set of pencil beam type radiation fields (9). Prior studies have shown that, the combination of SFGRT and standard external beam irradiation can improve the local control of bulky and radio-resistant tumors especially when the EBRT had low chances of a successful treatment (1). In the present study, a case was reported concerning a patient with a bulky extremity soft tissue sarcomas treated with SFGRT and then followed by a full course of standard EBRT.

### Case presentation

Our patient was a 42-year-old male with left posterior thigh mass which had rapid growth in the past few months. The patient was examined initially. The tumor was a firm, fixed and bulky with 22×11×10 cm<sup>3</sup> in its largest dimensions. The skin was too incontinent. The examination showed negative metastatic activity. The core needle biopsy specimen of the tumor revealed a high grade spindle/pleomorphic sarcoma, consistent with liposarcoma. Since the tumor was not resectable and had cell adhesion to surrounding structures, neoadjuvant external beam radiotherapy combined with SFGRT was considered along with administration of concurrent doxorubicin 20 mg/m<sup>2</sup> weekly/iv/bolus at the discretion of the attending radiation oncologist. SFGRT was given at the first day of chemotherapy and followed the next week by initiating the EBRT considering a total dose of 50 Gy. The CT simulation and magnetic resonance imaging were used to identify the GTV as the target of SFGRT with the volume of 903.10 cm<sup>3</sup>. All efforts were made to spare normal tissues from SFGRT dose. A 3cm proximal -distal margin and a 1.5 cm radial margin were applied to GTV to create the CTV. The volume of CTV was equal to 2165.39 cm<sup>3</sup> concerning setup error and organ motion. An 8 -mm margin at all sides of CTV was applied to create the PTV with the

volume of 2702.71 cm<sup>3</sup>. This PTV was considered for EBRT treatment planning. There was no critical organ at risks to be spared but all efforts were made to shield uninvolved normal tissues. As shown in figure 1, the patient was treated and simulated in the supine semi frog-leg position. CT scan was performed without contrast and with a slice thickness of 3 mm, through the region of interest from iliac crest to below the knee. Target volume delineation and planning were done by Eclipse™ (version 8.8) Treatment Planning System (figure 2).

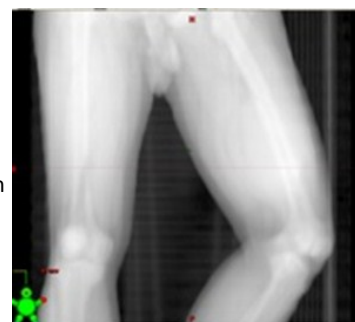

Figure1. The supine semi frog-leg position for the patient.

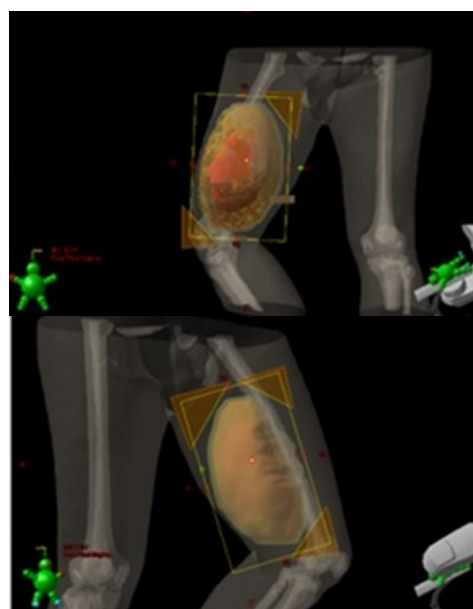


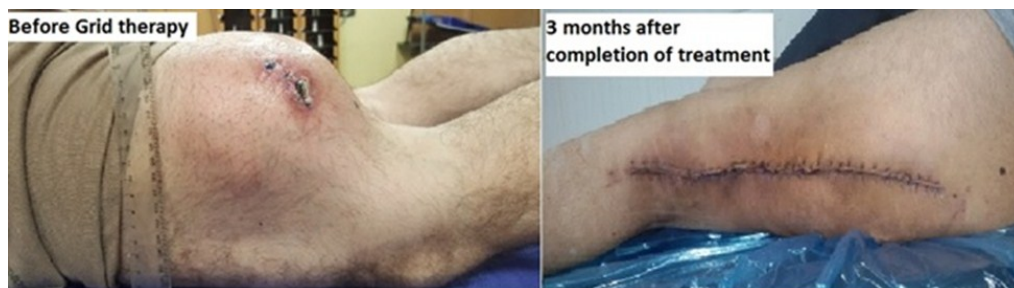Figure 2. Treatment plan and PTV contouring for EBRT.

The Grid block was previously constructed in our department and its dosimetric characteristics were verified (14,15). Treatment was performed using a 6 MV photon beam at SSD=100 cm to deliver 15 Gy dose in one fraction to the maximum depth (d<sub>max</sub>). The Grid

had an open to closed-block area ratio of 50%. After this treatment, there was one week interval break before EBRT treatment with 50 Gy in 25 fractions for the neoadjuvant external beam radiotherapy. An anterior-posterior and oblique field arrangements were used combined with applying 18 and 6 MV photon beams with a good PTV coverage (95%) and hot spot less than 110%.

The surgery was performed 4 weeks after the completion of radiotherapy; the pathology exam revealed a tumor with a size of 22 cm in the greatest dimensions, and distance of lesion from medial, lateral, proximal, distal, skin and bone was equal to 1, 0.5, 0.6, 1, 2, and 0.4 cm, respectively. The residual tumor was of high grade spindle/pleomorphic sarcoma in a myxoid background. Tumor necrosis was observed as

30%, and there were no early post-op wound complications following the surgery. In addition, more than 50% of radiological response was detected from the MRI before the surgery. All surgical margins were free from tumor. During radiotherapy and after the surgery, patient was evaluated weekly for response, side effects, and overall clinical condition. Patients' baseline symptoms were identified based on patients report included: pain, mass effect, decreased range of motion after treatment. The follow-up time was considered as 24 months. The patient's general condition was good during this period without the presence of tumor recurrence or normal tissues complications. Figure 3 illustrates the 3-month post-op status of the patient after removing the entire tumor with a successful surgical resection.



**Figure 3.** A bulky extremity soft tissue sarcomas before treatment (left), and 3-month post-op status of patient after a successful surgical resection (right)

## DISCUSSION

In this study, a case was reported concerning a patient with soft tissue sarcoma treated with combined SFGRT and conventional EBRT along with administration of Doxorubicin 20 mg/m<sup>2</sup> per week as an IV bolus; the tumor was bulky and radio-resistant. A combination of different treatment strategies have been used in treatment of patients with bulky tumors<sup>(16)</sup>. For this case, it seemed that the traditional dose regimen and treatment technique could not be beneficial. To achieve successful outcomes, the results of our treatment were enhanced utilizing the SFGRT technique newly introduced and confirmed in several studies<sup>(9, 12, 17)</sup>.

In this study, a combination of SFGRT based on Grid block was used in conjunction with ordinary radiotherapy regimes as proposed in the study by Mohiuddin et al.<sup>(1)</sup>. In our study,

combination of Grid therapy and conventional RT led to more than 50% radiological response and made the tumor resectable with a 30% necrosis in the surgical specimen. Additionally, a complete response occurred after the surgery. In comparison, in studies which have not used a Grid for treatment of high-grade sarcoma, less than 1% shrinkage in the tumor volume and 50% pathological treatment response have been reported. Moreover, after Grid therapy, there was no distance metastatic according to our examinations. Kaiser *et al*<sup>(17)</sup> showed a dramatic response of bulky soft-tissue tumors as a result of applying SFGRT as a superior treatment technique compared to the ordinary radiotherapy regimes. Zhang *et al.*<sup>(18)</sup> demonstrated the effect of dose fraction in hypo-fraction Grid therapy, and they mentioned that a fraction dose of 15 Gy in one fraction could be utilized in hypo-fractionated Grid therapy. In

addition, the therapeutic ratio depends on different factors like dose fraction, tumor size, and depth of treatment<sup>(18)</sup>, so according to our treatment response for this patient, Grid therapy seems to be an effective and promising approach as a part of neoadjuvant radiation therapy for bulky soft-tissue tumors. The results of the study revealed that, Grid therapy could be an option for treatment of radio-resistant and bulky tumors as was shown earlier by Gholami et al.<sup>(19, 20)</sup>. It is recommended to develop a Treatment Planning System for this technique, especially for some tumor sites which are near to the critical volumes like spinal cord. This approach helps to improve the response of the surgery and total response of the treatment.

## ACKNOWLEDGEMENTS

*This research has been supported by Tehran University of Medical Sciences and Health Services with grant number 96-02-207-35544 and ethical committee approval number IR.TUMS.VCR.REC.1396.4157. (Date of approval: 1396).*

**Conflicts of interest:** Declared none.

## REFERENCES

- Mohiuddin M, Fujita M, Regine WF, Meigooni AS (1999) Ibbott GS, Ahmed MM. High-dose spatially-fractionated radiation (GRID): a new paradigm in the management of advanced cancers. *Int J Radiat Oncol Biol Phys*, **45(3)**: 721-7.
- Kudrimoti M, Mohiuddin M, Ahmed M, Meigooni A, Hanna N, Regine W, et al. (2004) Use of high dose spatially fractionated radiation (GRID therapy) in management of large, poor prognostic stage III (> 10cms) soft tissue sarcomas. *Int J Radiat Oncol Biol Phys*, **60(1)**: S575.
- Johnson CR, Khandelwal SR, Schmidt-Ullrich RK, Ravalese J, Wazer DE (1995) The influence of quantitative tumor volume measurements on local control in advanced head and neck cancer using concomitant boost accelerated superfractionated irradiation. *Int J Radiat Oncol Biol Phys*, **32(3)**: 635-41.
- Dubben H-H, Thames HD, Beck-Bornholdt HP (1998) Tumor volume: a basic and specific response predictor in radiotherapy. *Radiotherapy and oncology*, **47(2)**: 167-74.
- Reddy SP, Mohideen N, Marra S, Marks JE (1998) Effect of tumor bulk on local control and survival of patients with T1 glottic cancer. *Radiotherapy and Oncology*, **47(2)**: 161-6.
- Zelevsky MJ, Fuks Z, Hunt M, Lee HJ, Lombardi D, Ling CC, et al. (2001) High dose radiation delivered by intensity modulated conformal radiotherapy improves the outcome of localized prostate cancer. *The Journal of urology*, **166(3)**: 876-81.
- Yamada Y, Bilsky MH, Lovelock DM, Venkatraman ES, Toner S, Johnson J, et al. (2008) High-dose, single-fraction image-guided intensity-modulated radiotherapy for metastatic spinal lesions. *Int J Radiat Oncol Biol Phys*, **71(2)**: 484-90.
- Blomgren H, Lax I, Näslund I, Svanström R (1995) Stereotactic high dose fraction radiation therapy of extracranial tumors using an accelerator: clinical experience of the first thirty-one patients. *Acta Oncologica*, **34(6)**:861-70.
- Peñagaricano JA, Moros EG, Ratanatharathorn V, Yan Y, Corry P (2010) Evaluation of spatially fractionated radiotherapy (GRID) and definitive chemoradiotherapy with curative intent for locally advanced squamous cell carcinoma of the head and neck: initial response rates and toxicity. *Int J Radiat Oncol Biol Phys*, **76(5)**: 1369-75.
- Almendral P, Mancha PJ, Roberto D (2013) Feasibility of a simple method of hybrid collimation for megavoltage grid therapy. *Medical Physics*, **40(5)**: 051712.
- Neuner G, Mohiuddin MM, Vander Walde N, Goloubeva O, Ha J, Cedric XY, et al. (2012) High-dose spatially fractionated GRID radiation therapy (SFGRT): a comparison of treatment outcomes with Cerrobend vs. MLC SFGRT. *Int J Radiat Oncol Biol Phys*, **82(5)**: 1642-9.
- Zhang H, Wang JZ, Mayr N, Kong X, Yuan J, Gupta N, et al. (2008) Fractionated grid therapy in treating cervical cancers: Conventional fractionation or hypofractionation? *Int J Radiat Oncol Biol Phys*, **70(1)**: 280-8.
- Zwicker RD, Meigooni A, Mohiuddin M (2004) Therapeutic advantage of grid irradiation for large single fractions. *Int J Radiat Oncol Biol Phys*, **58(4)**: 1309-15.
- Gholami S, Nedaie HA, Longo F, Ay MR, Dini SA, Meigooni AS (2017) Grid block design based on monte carlo simulated dosimetry, the linear quadratic and Hug-Kellerer radiobiological models. *Journal of Medical Physics*, **42(4)**: 213.
- Gholami S, Nedaie HA, Meigooni AS (2019) Precise EB3 Gafchromic film dosimetry for Grid therapy. *Radiation Measurements*, **121**: 69-76.
- Zagars GK, Ballo MT, Pisters PW, Pollock RE, Patel SR, Benjamin RS, et al. (2003) Prognostic factors for patients with localized soft-tissue sarcoma treated with conservation surgery and radiation therapy. *Cancer*, **97(10)**: 2530-43.
- Kaiser A, Mohiuddin MM, Jackson GL (2013) Dramatic response from neoadjuvant, spatially fractionated GRID radiotherapy (SFGRT) for large, high-grade extremity sarcoma. *Journal of Radiation Oncology*, **2(1)**: 103-6.
- Zhang H, Traeger J, Li K, Lu L, Wang J, Gupta N (2009) Impact of Fraction Dose in Hypo-Fractionated Megavoltage Grid Therapy for Melanoma. *Int J Radiat Oncol Biol Phys*, **75(3)**: S619-S20.
- Gholami S, Nedaie HA, Longo F, Ay MR, Wright S, Meigooni AS (2016) Is grid therapy useful for all tumors and every grid block design? *Journal of Applied Clinical Medical Physics*, **17(2)**: 206-19.
- Gholami S, Nedaie H, Meigooni A, Longo F (2015) Grid therapy: impact of radiobiological models on calculation of therapeutic ratio. World Congress on Medical Physics and Biomedical Engineering, Toronto, Canada; Springer.