

# Rescue potency of *Eucalyptus* oil against gamma-rays induced gastric ulceration

S. Tawfik<sup>1\*</sup>, A. Elkady<sup>1</sup>, S. Salama<sup>2</sup>

<sup>1</sup>Health Radiation Research Department, National Centre for Radiation Research and Technology (NCRRT), Egyptian Atomic Energy Authority, P.O. Box: 29, Nasr City, Cairo, Egypt

<sup>2</sup>Radiation Biology Department, National Centre for Radiation Research and Technology (NCRRT), Egyptian Atomic Energy Authority, P.O. Box: 29, Nasr City, Cairo, Egypt

## ► Original article

### \*Corresponding author:

Dr. Sameh Soliman Tawfik

### E-mail:

samosoliman@gmail.com

Received: May 2020

Final revised: March 2021

Accepted: April 2021

Int. J. Radiat. Res., January 2022;  
20(1): 21-27

DOI: 10.52547/ijrr.20.1.4

**Keywords:** *Eucalyptus* oil, gastric ulceration, gamma-rays, rats, radioprotector.

## ABSTRACT

**Background:** *Eucalyptus* oil often used for medicinal purposes. **Aims:** The *Eucalyptus* oil gastro protective impact investigated against gamma-rays-exposure-induced gastric ulceration in rats. **Materials and Methods:** Thirty-two rats were divided equally into 4 groups; control, *Eucalyptus* oil (100mg/ kg), gamma-rays (7Gy) and *Eucalyptus* oil plus gamma-rays treated groups. The stomach histopathology samples were examined. The levels of malondialdehyde, reduced glutathione, superoxide dismutase, tumour necrosis factor- $\alpha$  and the interleukin-1 $\beta$  were assessed. **Results:** The stomach histopathological examination revealed that pre-treatment with *Eucalyptus* oil enhanced regeneration of mucosal crypt cells. The results revealed a decreased level of stomach malondialdehyde, inflammatory markers, increased levels of stomach antioxidants markers in *Eucalyptus* oil plus gamma-rays treated group. **Conclusion:** *Eucalyptus* oil ameliorates gamma-rays-induced gastric ulceration that could attribute to its antioxidant, anti-apoptotic and radioprotective activities.

## INTRODUCTION

Ionizing radiation induces acute damage to epithelial cells of the gastric tract <sup>(1)</sup>, mediating toxicities restricting the therapeutic efficacy of radiation in cancer and morbidity and mortality in nuclear disasters. No approved prophylaxis or therapy exists for these toxicities <sup>(2)</sup>. Considering the high toxicity of the radiation treatment to the gastrointestinal tract, studies revealing natural radio protectors that regulate the gastrointestinal tract response to injury following irradiation are extremely beneficial <sup>(3-5)</sup>. The genus *Eucalyptus* L'Heritier comprises about 300 species contains volatile essential oil in their leaves <sup>(6)</sup>. *Eucalyptus* oil (EO) has amazing widespread biological activities including antimicrobial, antiseptic, antioxidant, chemotherapeutic <sup>(7, 8)</sup>, respiratory and gastrointestinal effects <sup>(9,10)</sup> as well as wound healing <sup>(11)</sup>. No research article has yet assessed the radioprotective role of EO against gamma-rays induced gastric ulceration in rats. In the current research we attempted to evaluate the biological role of EO, as a natural medicine for mitigation of radiation-induced tissue injury. Biochemical assessment and histopathological examination of gastric tissues was performed.

## MATERIAL AND METHODS

### Animals

Male albino rats (240–260g, 12± 1 weeks) were obtained from the Egyptian organization for biological product and vaccines Giza, Egypt. Animals were acclimatized for a week before experimentation and received a standard diet and water *ad libitum* and were maintained under standard conditions of humidity, temperature (20-22°C), and 12-h light-dark cycle. Animals were deprived of food, but not water, overnight before samples collection. The study was approved by the National Centre for Radiation Research and Technology, Research Ethics Committee, REC-NCRRT. The serial number of the protocol was: 16A /18, 16/7/2018.

### Radiation processing

This procedure was performed using a gamma cell -40 (cesium-137), Atomic Energy of Canada Limited, Ottawa, Canada, located at NCRRT, Cairo, Egypt. Animals were irradiated with a single dose level of 7Gy of gamma-rays, delivered at a dose rate of 0.42 Gy/ min at the time of experimentation. The selected dose of gamma-rays can induce necessitated stomach radiation damage <sup>(12, 13)</sup>.

### Chemicals

Pure *Eucalyptus* oil (100%), was extracted by steam distilled from leaves and small branches, purchased from (NOW *Eucalyptus* Essential Oil-NOW Foods, Bloomingdale, USA). The used dosage (100mg/ kg) was an effective and reasonably protective antioxidant had no side effects on rats <sup>(14)</sup>. All other chemicals and solvents used were of the highest purity grade available.

### Animal groups

Rats were randomly distributed into four groups, each consisting of 8 rats. They included a control group: animals received normal saline (N/S); 2 mL/ kg body weight as a vehicle for 7 successive days, given via intra gastric (ig) route. EO group: animals received EO (100 mg/ kg body weight, ig) for the same period of time. Gamma-rays group: animals received N/S for the same dose and period of time; then irradiation (7 Gy gamma-rays) was carried out. EO + gamma-rays group: EO for the same dose and period of time was given before irradiation. The examination was carried out 7 days after the end of the experiment. The animals were anaesthetized, sacrificed and their stomachs were dissected.

### Biochemical analysis

Detection of inflammatory markers; tumour necrosis factor- $\alpha$  (TNF- $\alpha$ ) and interleukin-1 $\beta$  (IL-1 $\beta$ ) in the stomach homogenate of the different groups were performed by ELISA technique (BioSource International, Camarillo, CA, USA), according to the manufacturer's instructions. Each sample assay was repeated three times. Estimation of oxidative stress markers; malondialdehyde (MDA) and reduced glutathione (GSH) levels as well as superoxide dismutase (SOD) activity in the stomach homogenate were measured using commercial kits (Zellbio GmbH, Germany) according to the manufacturer's instructions. The absorbance was read at 420 nm, 412 nm and 535 nm, respectively. Biochemical kits (Abcam, UK) were used to measure myeloperoxidase activity in the gastric homogenates according to the manufacturer's instructions.

### Histopathological analysis

Stomach specimens from all experimental groups were fixed in 10% formalin saline solution for 24 hours. Washing was done by tap water then serial dilutions of alcohol (methyl, ethyl and absolute ethyl) were used for dehydration. Specimens were cleared in xylene and embedded in paraffin at 56°C in a hot air oven for 24 hours. Sections were embedded in paraffin and sliced into 4-micron thick sections. The tissue sections fixed on glass slides. Then, the

sections were deparaffinized and stained with hematoxylin and eosin (H&E) dye (H&E Staining Kit, abcam245880, USA), then examined by Olympus BX43 light microscope, Tokyo, Japan <sup>(15)</sup>.

### Statistical analysis

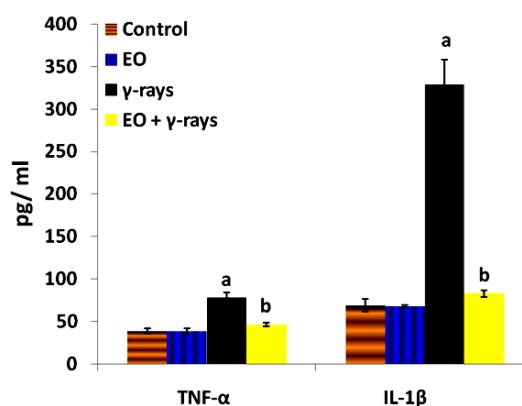
Data were using one-way analysis of variance (ANOVA) followed by LSD post hoc test. The results obtained were expressed by mean  $\pm$  standard error (S. E.). Differences were considered significant at  $p \leq 0.05$  <sup>(16)</sup>.

## RESULTS

### Results of inflammatory and oxidative stress markers

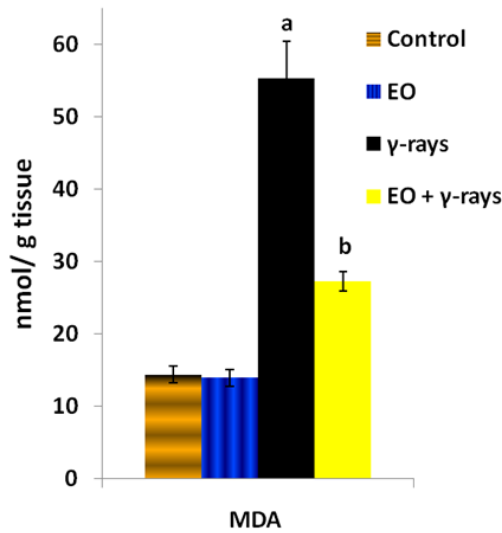
As presented in figure 1-5, the animal group treated with EO only showed non-significant changes in all estimated parameters compared to the control group.

As shown in figure 1, significant augmentation in some inflammatory markers were represented in the stomach tissues; TNF- $\alpha$  and IL-1 $\beta$  levels were well observed in the gamma-irradiated group compared to corresponding values of the control group. The administration of EO before exposure to gamma-rays significantly limited the elevation in those inflammatory markers levels compared to the irradiated group.

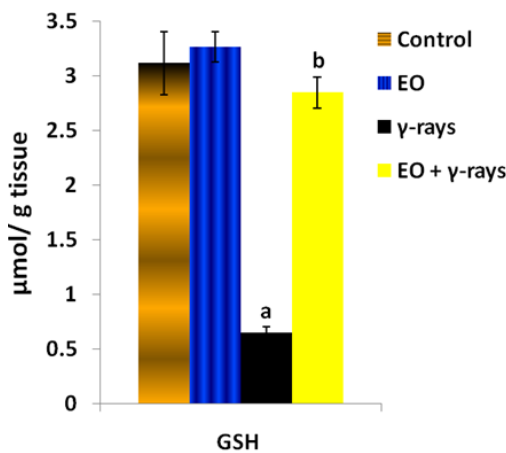


**Figure 1.** The level of TNF- $\alpha$  and IL-1 $\beta$  in stomach tissues of different animal groups (mean  $\pm$  S. E., n=8). EO = *Eucalyptus* Oil.  $\gamma$ -rays = Gamma-rays. Note: <sup>a</sup>Significant difference from control group, <sup>b</sup>Significant difference from gamma-rays group.

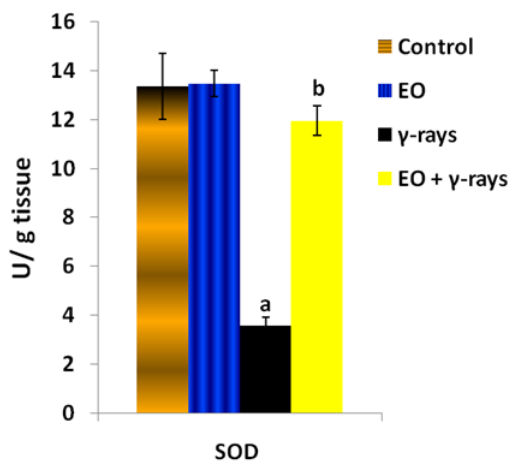
The gamma-rays induced a significant augmentation in MDA content and myeloperoxidase activity (figure 2,5) and a significant diminution in the gastric GSH content and SOD activity (figure 3,4), compared to the control group.



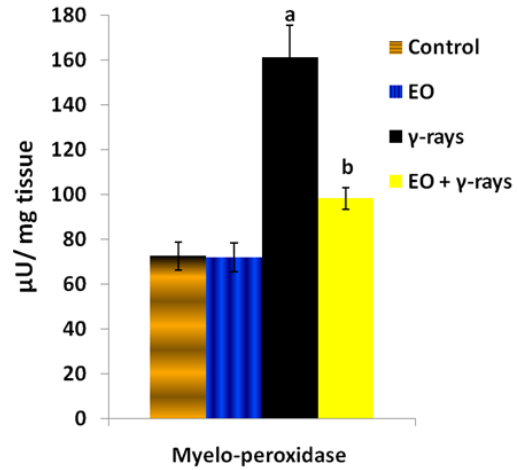
**Figure 2.** The level of MDA in stomach tissues of different animal groups (mean± S. E., n=8). EO = *Eucalyptus* Oil. γ-rays = Gamma-rays. Note: <sup>a</sup>Significant difference from control group, <sup>b</sup>Significant difference from gamma-rays group.



**Figure 3.** The content of GSH in stomach tissues of different animal groups (mean± S. E., n=8). EO = *Eucalyptus* Oil. γ-rays = Gamma-rays. Note: <sup>a</sup>Significant difference from control group, <sup>b</sup>Significant difference from gamma-rays group.



**Figure 4.** The activity of SOD in stomach tissues of different animal groups (mean± S. E., n=8).EO = *Eucalyptus* Oil. γ-rays = Gamma-rays. Note: <sup>a</sup>Significant difference from control group, <sup>b</sup>Significant difference from gamma-rays group.



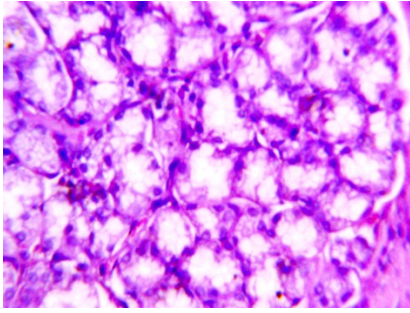
**Figure 5.** The activity of myeloperoxidase in stomach tissues of different animal groups (mean± S. E., n=8). EO = *Eucalyptus* Oil. γ-rays = Gamma-rays. Note: <sup>a</sup>Significant difference from control group, <sup>b</sup>Significant difference from gamma-rays group.

Administration of EO prior to gamma-rays-exposure resulted in a significant reduction in MDA and myeloperoxidase levels and significant increases in the activity of stomach SOD and myeloperoxidase and content of GSH, compared to the gamma-irradiated group, (figure 2-5).

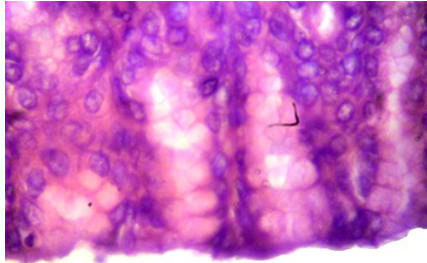
#### Results of histopathological examination

In stomach sections from control rats and EO groups, the surface of the stomach was covered by a single layer of the columnar epithelium; the loose irregular connective tissue of the lamina propria filled the narrow spaces between the tightly packed gastric glands and extended from the surface epithelium to the muscularis mucosa (figure 6). The gastric glands layer was simple or simple-branched tubular glands formed of different types of cells (figure 7).

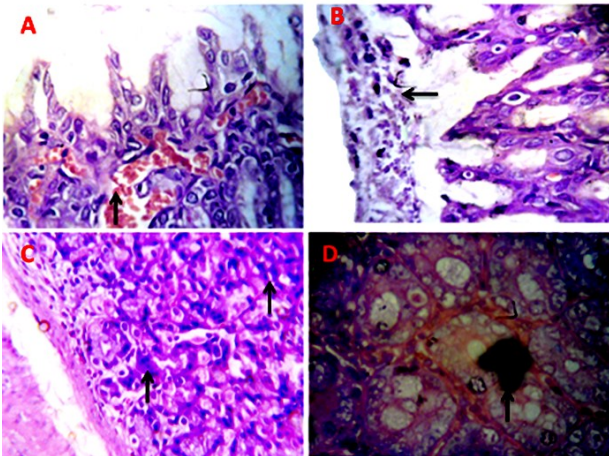
In the gamma-rays group, severe congestion of the mucosal blood vessels with mucous secretion inside such glands was observed (figure 8A). On the other hand, the stomach showed desquamation of mucosa glands assorted with mucous on the surface of mucosa layer (figure 8B) and in few cases, the gastric mucosa showed necrotic debris and leukocytic infiltration revealing ulcerative gastritis. Some of these ulcers developed due to the necrosis of the mucosa glands or the hyperplastic changes in the lining epithelium of the mucosa glands which is engorged with secretions (figure 8C and D). On the other hand, stomach of EO + gamma-rays group, showed normal gastric mucosa (figure 9A) except in a few cases where apoptosis with necrosis of gastric glands may be detected (figure 9B).



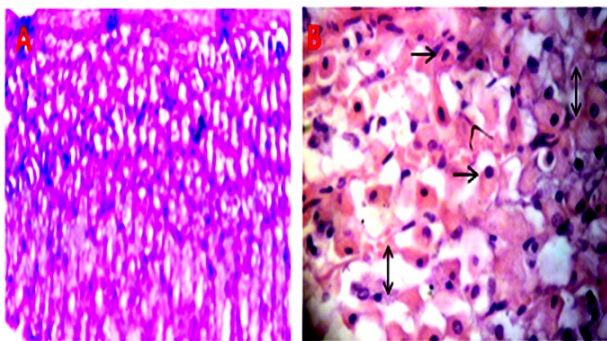
**Figure 6.** Stomach of the control rat group showing normal structure (H&E x400).



**Figure 7.** Stomach of the EO group showing normal gastric glands (H&E x400).



**Figure 8.** A) Stomach of the gamma-rays group showing congested mucosal blood vessels ( $\uparrow$ ) with mucous secretion inside some glands. B) Desquamation of the lining epithelium mixed with mucous on the surface of mucosa ( $\leftarrow$ ). C) Necrosis of gastric glands ( $\uparrow$ ). D) Hyperplastic mucosal glands containing retained and concentrated secretion ( $\uparrow$ ) (H & E x400).



**Figure 9.** A) Stomach of the EO + gamma-rays group showing normal gastric mucosa. B) Apoptosis ( $\rightarrow$ ) with necrosis of gastric gland ( $\leftrightarrow$ ) (H&E x400).

## DISCUSSION

The present study is the first one to provide evidence that EO has a potent gastro protective effect against gamma-rays-induced gastric ulcer, which was demonstrated by reduced gastric ulcerated area and adjusted antioxidant and anti-inflammatory markers. In addition, the possible mechanisms underlying the gastro protective effect were explored including the antioxidant as well as the anti-inflammatory effects that were further supported by histopathological observations of stomach tissues.

A dose of 11 Gy total-body gamma-rays induced hematopoietic syndrome and gastrointestinal injury in mice <sup>(17)</sup>. In the present study, gamma-rays-exposure at a dose of 7 Gy-induced marked histopathological alterations, where severe focal ulceration, haemorrhage, degeneration and necrosis were detected in the stomach mucosa. Also, severe submucosal oedema and inflammatory cells infiltration were observed. Likewise, that rat group receiving abdominal 15 Gy gamma-rays revealed significant jejunal mucosal damages <sup>(18)</sup>. Similarly, in the mice model, gamma rays-exposure induced intestinal damages <sup>(19)</sup>, whole abdominal irradiation-induced crypt-villus structural and small intestine damages <sup>(20)</sup>, whole-body doses of 1, and 2 Gy MeV proton radiation caused gastrointestinal lesions <sup>(21)</sup>, and the exposure to a toxic dose of gamma-rays-induced injuries to intestinal-crypt cells <sup>(22)</sup>. Outstandingly, in the present study, the pre-treatment of rats with 100 mg/kg of EO conferred marked protection from gamma-rays induced gastric ulceration as evidenced by the intact mucosal layer, absence of haemorrhage and necrosis. The EO at the doses (50 and 100 mg/kg) for 14 days protected against Aflatoxin B1-induced injuries in stomach and intestinal tissues that could be used in the management of gastrointestinal syndromes in rats <sup>(9)</sup>.

Plants and their constituents possess a wide spectrum of biological activities such as anti-inflammatory, antioxidant and gastro-protection effects. The EO has been used to treat inflammation-associated diseases, such as those causing gastrointestinal dysfunction, arthritis or respiratory system affection <sup>(23)</sup>. Its antioxidant capacity is due to the occurrence of polyphenols, gallic and ellagic acids, oenothain B, and hydrolysable tannins, specially ellagitannin in its essential oil <sup>(24)</sup>. Furthermore, the radical scavenging capacity of the EO is enhanced by increasing the concentration <sup>(25)</sup>.

Generation of reactive oxygen species (ROS) and oxidative stress is critically involved in the pathogenesis of gamma-rays-induced gastric damage <sup>(20)</sup>. The results of the present study were in line with a previous study that showed that gamma-rays-induced marked oxidative stress, as evidenced by increased lipid peroxidation; MDA in the gastric

tissue<sup>(26)</sup>. Likewise, the GSH content and the activity of SOD in the gamma-rays group were decreased significantly and those results were parallel to a related study<sup>(27)</sup>. Furthermore, the antioxidant capacity was markedly reduced, where the GSH content and the SOD activity were significantly depleted and lipid peroxidation was significantly augmented and this was the case in a similar study<sup>(28)</sup>.

In contrast, pre-treatment with EO, at a dose of 100 mg/kg, significantly ameliorated gamma-rays-induced oxidative stress, increased GSH and SOD till they reached to normal values, which confirmed the strong antioxidant capacity of EO. Experimental evidence has indicated that antioxidant compounds can be used as gastro-protective agent<sup>(29)</sup> in order to protect against radiation-induced stomach ulcer<sup>(30)</sup>. Thus, the remarkable gastro protective effect of EO could be partially mediated by attenuating gamma-rays-induced oxidative stress<sup>(31)</sup>. Moreover, rats treated with gamma-irradiation showed a significant increase in the rate of ulceration and MDA levels, which were accompanied by a significant decrease in the stomach GSH content and SOD activity<sup>(32)</sup>. In addition, El-Batal and Ahmed<sup>(33)</sup> found that EO exhibited marked antioxidant activity in both chemical- and cellular-based antioxidant assays and suggested that it would be promising natural antioxidants in pharmaceutical and industries.

Myeloperoxidase activity is an indicator of quantitative inflammation and the infiltration of the mucosa of the gastro intestinal tract with leukocytes<sup>(34)</sup>. In a recent study, the gastric injury was assessed by an increase in myeloperoxidase activity in gastric homogenate indicating the gastrointestinal tract damage in rat irradiated group<sup>(35)</sup>. Besides, the anti-inflammatory nonsteroidal drugs (NSAIDs) caused gastric mucosal ulcers in rats and the exposed animals showed significant lesions in the gastric mucosa-associated with a significant augmentation in the levels of myeloperoxidase activity in stomach tissue<sup>(36)</sup>. The EO pre-treatment significantly ameliorated enteritis-radiation injury, made evident by a decrease in myeloperoxidase activity. Eucalyptol (1,8-cineol), the major ingredient in the EO treated pulmonary inflammation, diminished leukocyte infiltration, production of inflammatory markers and myeloperoxidase activity in mice<sup>(37)</sup>. Moreover, EO has established a protective activity against Aflatoxin B1-induced injury in gastrointestinal tissues and can thus be used for the treatment of gastrointestinal disorders<sup>(9)</sup>.

Inflammation plays a noticeable causative role in the pathogenesis of gamma-rays-induced ulceration and the use of anti-inflammatory agents to ameliorate the gastric mucosal damage are showed to be encouraging<sup>(38)</sup>. In the present study, the gamma-rays group showed a marked increase in inflammatory markers evidenced by a significant increase in stomach tissue levels of TNF- $\alpha$  and IL-1 $\beta$ .

The acute single dose of 5 Gy gamma-rays-induced intestinal injury in rats, deteriorated the intestinal oxidative stress indices, and augmented the contents of inflammatory cytokines; TNF- $\alpha$  and IL-1 $\beta$  compared to the control group and these results were comparable to a similar previous study<sup>(39)</sup>. Besides, an acute dose of gamma-irradiation raised inflammation and the magnification of colitis histopathological findings and increased the inflammatory mediators; TNF- $\alpha$  and IL-1 $\beta$  compared to the control group as in a previous work<sup>(40)</sup>.

On the other hand, the pre-treatment of rats with EO exhibited marked anti-inflammatory effects, which was evident from the reduction of the stomach tissue contents of the tested inflammatory markers, in the present study. An ellagitannin fraction attained from EO has been examined against an ethanol-induced acute gastric ulcers in rats. Its gastric protective influence could be intermediated by ameliorating ethanol-induced gastric oxidative stress<sup>(41)</sup>. Ellagitannin-pre-treatment protected against gastric ulcers, significantly augmented the exhausted GSH and SOD levels and reduced the raise in MDA in gastric tissue. The results confirmed a preceding study which stated that ellagitannin exerted a prevailing anti-inflammatory power as showed by a decline in the inflammatory cytokines; TNF- $\alpha$  and IL-1 $\beta$ <sup>(41)</sup>.

## CONCLUSION

EO enhanced the cellular antioxidant defense status and reduced the elevated MDA tissue levels induced by gamma-rays-exposure. Moreover, EO exerted a powerful anti-inflammatory activity as demonstrated by the reduction in pro-inflammatory markers; TNF- $\alpha$  and IL-1 $\beta$ . Additionally, EO conferred marked protection from gamma-rays-induced ulcers as evidenced by intact gastric mucosal layer, absence of haemorrhage and necrosis.

## ACKNOWLEDGEMENTS

*We are thankful to our colleagues at the Health Radiation Research Department and the Radiation Biology Department, NCRRT for providing laboratory conveniences, and members of the National Center for Radiation Research and Technology (NCRRT), Egyptian Atomic Energy Authority for providing the necessary irradiation facilities. This work was done at NCRRT, Egypt.*

**Ethical considerations:** All experiments were performed in accordance with the Research Ethics Committee (REC, NCRRT) Number: 16A /18, valid from 16/7/2018.

**Funding:** This research received no particular funding.

**Declaration of Competing Interest:** We confirm that no conflict of interest present for this manuscript and

all of the authors have agreed with the manuscript submitted. All authors contributed to the design and implementation of the research, the analysis of the results and the writing of the manuscript.

**Conflict of interest statement:** The authors declare that they have no conflicts of interest. The authors alone are accountable for the content and script of the article.

**Authors' contribution:** (A.E) conceived, designed the study, analyzed the data and performed pathological studies. (S.T) and (S.S) performed biochemical studies and analyzed the data. All authors prepared and revised the manuscript.

## REFERENCES

- Venkateswaran K, Shrivastava A, Agrawala PK, Prasad AK, Devi SC, Manda K, Parmar VS, Dwarakanath BS (2019) Mitigation of radiation-induced gastro-intestinal injury by the polyphenolic acetate 7, 8-diacetoxy-4-methylthiocoumarin in mice. *Sci Rep*, **9** (1): 14134.
- Yumusak N, Sadic M, Akbulut A, Aydinbelge FN, Koca G, Korkmaz M (2019) Beneficial effects of vitamin E on radioiodine induced gastrointestinal damage: an experimental and pathomorphological study. *Bratisl Lek Listy*, **120**(4): 263-269.
- Gil-Avilés MDR, Montes-Avila J, Díaz-Camacho SP, Picos-Salas MA, López-Angulo G, Reynoso-Soto EA, Osuna-Martínez LU, Delgado-Vargas F (2019) Soluble melanins of the *Randia echinocarpa* fruit - Structural characteristics and toxicity. *J Food Biochem*, **43**(12): e13077.
- Shabeeb D, Keshavarz M, Shirazi A, Hassanzadeh G, Hadian MR, Nowrouzi A, Najafi M, Musa AE (2019) Evaluation of the radioprotective effects of melatonin against ionizing radiation-induced muscle tissue injury. *Curr Radiopharm*, **12**(3): 247-255.
- Xu J, Long Y, Ni L, Yuan X, Yu N, Wu R, Tao J, Zhang Y (2019) Anti-cancer effect of berberine based on experimental animal models of various cancers: a systematic review and meta-analysis. *BMC Cancer*, **19**(1): 589.
- Dhakad AK, Pandey VV, Beg S, Rawat JM, Singh A (2018) Biological, medicinal and toxicological significance of *Eucalyptus* leaf essential oil: a review. *J Sci Food Agric*, **98**(3): 833-848.
- Braga Paiano R, Bonilla J, Moro de Sousa RL, Micke Moreno A, Sampaio Baruselli P (2020) Chemical composition and antibacterial activity of essential oils against pathogens often related to cattle endometritis. *J Infect Dev Ctries*. **14**(2): 177-183.
- Nasr A, Saleem Khan T, Zhu GP (2019) Phenolic compounds and antioxidants from *Eucalyptus camaldulensis* as affected by some extraction conditions, a preparative optimization for GC-MS analysis. *Prep Biochem Biotechnol*. **49**(5): 464-476.
- Akinrinde AS, Adebisi OE, Asekun A (2019) Amelioration of Aflatoxin B1-induced gastrointestinal injuries by *Eucalyptus* oil in rats. *J Complement Integr Med*, **17**(1).
- Kheder, DA, Al-Habib, OAM, Gilardoni, G and Vidari, G (2020) Components of volatile fractions from *Eucalyptus camaldulensis* leaves from Iraqi-Kurdistan and their potent spasmolytic effects. *Molecules*, **25**(4). pii: E804.
- Alam P, Shakeel F, Anwer MK, Foudah AI, Alqarni MH (2018) Wound healing study of eucalyptus essential oil containing nanoemulsion in rat model. *J Oleo Sci*, **67**(8):957-968.
- Abdel Salam OM1, Hadajat I, Bayomy AR, El-Shinawy S, Arbid MS (2005) Acute effect of gamma irradiation on gastric acid secretion and gastric mucosal integrity in the rat. *Scientific World J*, **5**: 195-204.
- Khayyal MT, Abdel-Naby DH, El-Ghazaly MA (2019) Propolis extract protects against radiation-induced intestinal mucositis through anti-apoptotic mechanisms. *Environ Sci Pollut Res Int*, **26** (24): 24672-24682.
- Shao J, Yin Z, Wang Y, Yang Y, Tang Q, Zhang M, Jiao J, Liu C, Yang M, Zhen L, Hassouna A, White WL, Lu J (2020) Effects of different doses of eucalyptus oil from *Eucalyptus globulus* Labill on respiratory tract immunity and immune function in healthy rats. *Front Pharmacol*. **11**: 1287.
- Gamble M (2008) Theory and practice of histological techniques. 6th ed. Philadelphia; Churchill Livingstone, pp: 121-134.
- Snedecor GW and Cochran WG (1989) Statistical Methods, 8th ed. Wiley-Blackwell, p: 503.
- Kim JY, Park JH, Seo SM, Park JI, Jeon HY, Lee HK, Yoo RJ, Lee YJ, Woo SK, Lee WJ, Choi CM, Choi YK (2019) Radioprotective effect of newly synthesized toll-like receptor 5 agonist, KMRC011, in mice exposed to total-body irradiation. *J Radiat Res*, **60**(4): 432-441.
- Orhon ZN, Uzal C, Kanter M, Erboga M, Demiroglu M (2016) Protective effects of *Nigella sativa* on gamma radiation-induced jejunal mucosal damage in rats. *Pathol Res Pract*. **212**(5): 437-43.
- Li M, Lang Y, Gu MM, Shi J, Chen BPC, Yu L, Zhou PK, Shang ZF (2020) Vanillin derivative VND3207 activates DNA-PKcs conferring protection against radiation-induced intestinal epithelial cells injury in vitro and in vivo. *Toxicol Appl Pharmacol*. **387**: 114855.
- Lu L, Jiang M, Zhu C, He J, Fan S (2019) Amelioration of whole abdominal irradiation-induced intestinal injury in mice with 3,3'-Diindolylmethane (DIM). *Free Radic Biol Med*, **130**: 244-255.
- Purgason A, Zhang Y, Hamilton SR, Gridley DS, Sodipe A, Jejelowo O, Ramesh GT, Moreno-Villanueva M, Wu H (2018) Apoptosis and expression of apoptosis-related genes in mouse intestinal tissue after whole-body proton exposure. *Mol Cell Biochem*, **442**(1-2): 155-168.
- Chacko T, Menon A, Majeed T, Nair SV, John NS, Nair CKK (2017) Mitigation of whole-body gamma radiation-induced damages by Clerodendron infortunatum in mammalian organisms. *J Radiat Res*, **58**(3): 281-291.
- Miguel MG, da Silva CI, Farah L, Castro Braga F, Figueiredo AC (2020) Effect of Essential Oils on the Release of TNF- $\alpha$  and CCL2 by LPS-Stimulated THP1 Cells. *Plants (Basel)*, **10**(1): E50.
- Tahara K, Nishiguchi M, Funke E, Miyazawa SI, Miyama T, Milkowski C (2020) Dehydroquinase dehydratase/shikimate dehydrogenases involved in gallate biosynthesis of the aluminum-tolerant tree species *Eucalyptus camaldulensis*. *Planta*, **253**(1): 3.
- Parham S, Kharazi AZ, Bakhsheshi-Rad HR, Nur H, Ismail AF, Sharif S, RamaKrishna S, Berto F (2020) Antioxidant, antimicrobial and antiviral properties of herbal materials. *Antioxidants (Basel)*, **9**(12): 1309
- Hasan HF, Elgazzar EM, Mostafa DM (2020) Diminazene aceturate attenuate the renal deleterious consequences of angiotensin-II induced by  $\gamma$ -irradiation through boosting ACE2 signaling cascade. *Life Sci*, **253**: 117749.
- Jiang DW, Wang QR, Shen XR, He Y, Qian TT, Liu Q, Hou DY, Liu YM, Chen W, Ren X, Li KX (2017) Radioprotective effects of cimetidine on rats irradiated by long-term, low-dose-rate neutrons and 60Co  $\gamma$ -rays. *Mil Med Res*, **4**: 7.
- Suman S, Kumar S, Fornace AJ Jr, Datta K (2018) The effect of carbon irradiation is associated with greater oxidative stress in mouse intestine and colon relative to  $\gamma$ -rays. *Free Radic Res*, **52**(5): 556-567.
- Lajili S, Ammar HH, Mzoughi Z, Amor HBH, Muller CD, Majdoub H, Bouraoui A (2019) Characterization of sulfated polysaccharide from *Laurencia obtusa* and its apoptotic, gastroprotective and antioxidant activities. *Int J Biol Macromol*. **126**: 326-336.
- Li P, Wuthrick E, Rappaport JA, Kraft C, Lin JE, Marszałowicz G, Snook AE, Zhan T, Hyslop TM, Waldman SA (2017) GUCY2C Signaling opposes the acute radiation-induced GI syndrome. *Cancer Res*, **77**(18): 5095-5106.
- Abdel-Magied N and Shedid S (2019) The effect of naringenin on the role of nuclear factor (erythroid-derived 2)-like2 (Nrf2) and haem oxygenase 1 (HO-1) in reducing the risk of oxidative stress-related radiotoxicity in the spleen of rats. *Environ Toxicol*, **34**(7): 788-795.
- Fahmy HA and Ismail AF (2015) Gastroprotective effect of kefir on ulcer induced in irradiated rats. *J Photochem Photobiol. B*, **144**: 85-93.
- El-Batal AI and Ahmed SF (2018) Therapeutic effect of Aloe vera and silver nanoparticles on acid-induced oral ulcer in gamma-irradiated mice. *Braz Oral Res*, **32**: e004.
- Watanabe PDS, Trevizan AR, Silva-Filho SE, Góis MB, Garcia JL, Cuman RKN, Breithaupt-Faloppa AC, Sant Ana DMG, Nogueira de Melo GA (2018) Immunocompetent host develops mild intestinal inflammation in acute infection with *Toxoplasma gondii*. *PLoS One*, **13**(1): e0190155.
- Pathak R, Wang J, Garg S, Aykin-Burns N, Petersen KU, Hauer-Jensen M (2016) Recombinant Thrombomodulin (Solulin) ameliorates early intestinal radiation toxicity in a preclinical rat model. *Radiat Res*, **0186**(2): 112-120.
- Goulart da Silva G, de Oliveira Braga LE, Souza de Oliveira EC,

- Valério Tinti S, de Carvalho JE, Goldoni Lazarini J, Rosalen PL, Dionísio AP, Tasca Gois Ruiz AL (2020) Cashew apple byproduct: Gastroprotective effects of standardized extract. *J Ethnopharmacol*, **269**: 113744.
37. Caceres AI, Liu B, Jabba SV, Achanta S, Morris JB, Jordt SE (2017) Transient receptor potential cation channel subfamily M Member 8 channels mediate the anti-inflammatory effects of eucalyptol. *Br J Pharmacol*, **174**(9): 867-879.
38. Yang L and Pan J (2019) Therapeutic effect of ecdysterone combine paeonol oral cavity direct administered on radiation-induced oral mucositis in rats. *Int J Mol Sci*, **20**(15): e3800.
39. Radwan RR and Karam HM (2020) Resveratrol attenuates intestinal injury in irradiated rats via PI3K/Akt/mTOR signaling pathway. *Environ Toxicol*. **35**(2): 223-230.
40. Demirci H, Polat Z, Uygun A, Kadayifci A, Sager O, Oztutk K, Sahiner F, Caliskan B, Karslioglu Y, Ozler M, Ozel M, Ergun H, Ozturk O, Beyzadeoglu M, Bagci S (2016) The Effect of the iNOS inhibitor S-Methylisothiourea and hyperbaric oxygen treatment on radiation colitis in rats. *Acta Gastroenterol Belg*, **79**(1): 8-13.
41. Al-Sayed E and El-Naga RN (2015) Protective role of ellagitannins from *Eucalyptus citriodora* against ethanol-induced gastric ulcer in rats: impact on oxidative stress, inflammation and calcitonin-gene related peptide. *Phytomedicine*, **22**(1): 5-15.

