

Therapeutic mechanism of ^{32}P application combined with timolol maleate for infantile superficial hemangioma

R.X. Ma¹ and Z.L. Li^{*2}

¹Department of Pharmacy, Xingtai People's Hospital, Xingtai, 054001, China
²Department of Nuclear Medicine, Xingtai People's Hospital, Xingtai, 054001, China

► Original article

*Corresponding author:

Dr. Zongliang Li

E-mail:

13730133835@163.com

Received: August 2020

Final revised: February 2021

Accepted: March 2021

Int. J. Radiat. Res., January 2022;
20(1): 157-162

DOI: 10.52547/ijrr.20.1.24

ABSTRACT

Background: This study aims to explore the therapeutic mechanism of ^{32}P application combined with timolol maleate for infantile superficial hemangioma. **Materials and Methods:** In this study, 60 nude mice were enrolled to establish the transplantation model of infantile hemangioma in nude mice. They were randomly divided into control group, administration group and combined administration group, with 20 mice in each group. The expressions of EGFL7 and VEGF were detected by RT-PCR, and the expressions of renin and ang II were detected by Western blot. **Results:** After the administration of timolol maleate, the expression of EGFL7, VEGF, renin and Ang II decreased ($P < 0.05$). The levels of EGFL7, VEGF, renin and Ang II were further down regulated by combined scheme of ^{32}P application and timolol maleate ($P < 0.05$). **Conclusion:** ^{32}P application combined with timolol maleate can improve the therapeutic effect of infantile superficial hemangioma by inhibiting the expression of vascular endothelial growth factor, renin and angiotensin II.

Keywords: Hemangioma, timolol maleate, ^{32}P , angiotensin II, vascular endothelial growth factor.

INTRODUCTION

Pediatric hemangioma (IH) is a neoplasia of endothelial cells that grows after birth and often regresses spontaneously (1). IH is a benign tumor of endothelial cells, characterized by proliferation in infancy and then spontaneous aging in the following 5-10 years, often leaving fibrous fat residue, atrophic scar formation or telangiectasia (2). The incidence of IH in infants ranges from 4% to 10%. Common sites for hemangiomas include the periorbital, oropharyngeal, preauricular, or parotid regions. These hemangiomas require early and effective treatment to prevent permanent sequelae (3). The proportion of hemangiomas is associated with its incidence in infants and children (4). At present, there are few treatment options, and corticosteroids have always been the first-line drugs for IH system treatment (5). More recently, oral propranolol, a nonselective beta blocker, has become an alternative drug for the treatment of IH (6). Both corticosteroids and propranolol may cause significant systemic adverse reactions (7). Recently, timolol maleate, a nonselective beta blocker, has been reported as a potential novel topical agent for the treatment of IH (8-10).

This study investigates the effect of thiomolol

maleate combined with ^{32}P application on the levels of circulating Vascular endothelial growth factor (VEGF) and Basic fibroblast growth factor (bFGF) in infants with cutaneous hemangioma, and then therapeutic effect of ^{32}P application combined with timolol maleate on superficial hemangioma in infants was revealed. The objective of this study us to explore the therapeutic mechanism of ^{32}P application combined with timolol maleate for superficial hemangioma in infants and young children. The novelty of this study lies in the combined application of non-selective β -blocker timolol maleate eye drops and ^{32}P application in the treatment of infantile hemangioma, to explore the synergistic therapeutic effect of the combination of the two drugs.

MATERIALS AND METHODS

Experimental materials and, experimental animals

60 healthy SPF grade BALB/c-nu female nude mice, aged 15-20 days and weighing 15-20g were purchased from Beijing Vital River Co., Ltd. All experimental animals were fed in a constant-temperature laminar flow ward under the condition of 25°C and 75%RH. This study has been approved by the Animal Ethics Committee of our unit

(2019-1205A).

Source of hemangioma tissue

The hemangioma tissue samples were derived from proliferative hemangioma tissues of infants and young children resected by oral and maxillofacial surgery at the Affiliated Stomatological Hospital of China Medical University from February 15 to 18, 2019. None of the patients offering the sample had undergone other treatments before the surgery, and the samples were obtained after obtaining the approval of the patients' family and the Medical Experimental Ethics Committee of China Medical University. A small portion of the experimental sample was resected for pathological examination, which was confirmed to be infantile superficial hemangioma in the proliferative period (refer to Mulliken classification criteria). The collected samples were transported to the laboratory in a low-temperature and sterile environment.

METHOD

Establishment of hemangioma model in nude mice and experimental grouping

After processing the hemangioma tissues with normal saline, the damaged part of the tumor edge and fibrous adipose tissue was removed, and cut into tissue pieces of uniform dimension (4mm×4mm×3mm), and then transplanted to the back of nude mice under sterile environment, followed by conventional suture. Estradiol benzoate injection at a dose of 0.2 mg was given every 2 days, for 24 consecutive days.

After the construction of hemangioma model in nude mice, 60 female rats were randomly divided into control group, timolol maleate administration group (administration group), ³²P application and timolol maleate co-administration group (co-administration group), 20 animals in each group. In the drug group, 0.5% timolol maleate eye drops (Wuhan Tiantianming Pharmaceutical Co., Ltd., approval number: National Drug Approval H20045947, specification: 12.5mg/5ml) were applied locally to the lesion area of hemangioma, once in the morning and once in the evening, at an interval of 12h. For the co-administration group, apply ³²P (provided by the pharmacy department of our hospital) to the affected area, calculate application dose according to the concentration of 0.925MBq/cm², remove the patch after 3 weeks, and apply 0.5% timolol maleate once in the morning and evening for 3 consecutive weeks. The control group was smeared with normal saline every day at the same frequency as the administration group.

Observation of the general situation of nude mice

The general situations of nude mice in the control group, administration group and co-administration group were observed every day. The hemangioma

size was measured. The maximum diameter a and the minimum diameter b of the tumor body were measured after 6 weeks to calculate the tumor volume.

Observation of histopathological morphology of hemangioma in nude mice

Nude mice were sacrificed by cervical dislocation. The transplanted tissue pieces were cut and fixed with 95% ethanol (Beyotime Biotechnology) for at least 1 day. Then, the tissues were subjected to processes of dehydration, paraffin embedding, sectioning, and baking at 68°C. After that, it was treated by dewaxing and hydration, that is, soaking the slices in xylene solution (Beyotime Biotechnology) for 10 min, in absolute ethanol solution for 10 min, in 95% and 90% ethanol solution for 5 min each), followed by soaking in distilled water, washing with hematoxylin aquacolor (Beyotime Biotechnology). Subsequently, it was immersed in hydrochloric acid (1% concentration) and alcohol for 10s, stained with eosin solution for 25s, and placed in 80% ethanol for 2min, 95% ethanol for 5min, and absolute ethanol for 5min. After transparency by xylene solution (Beyotime Biotechnology), it was sealed with a neutral gum and dried. The seal sheet was placed under a microscope to observe the pathological changes of cortical structure of the mice in each group.

Detection of the changes in EGFL7 and VEGF gene expression using RT-PCR method

Total RNA of hemangioma tissue was extracted using conventional method (Trizol solution) (The kit was purchased from Shanghai Beyotime Biotechnology). Taking mRNA as a template, the product cDNA was obtained via amplification and reverse transcription reaction system and stored at -20°C. Expression levels of EGFL7 and VEGF genes were detected by RT-PCR method. The PCR amplification conditions were: pre-denaturation at 94°C for 3 min, denaturation at 92°C for 25 s, annealing at 60°C for 35 s, extension at 70°C for 30 s, for 40 cycles, and finally extension at 71°C for 50 s. The sample was loaded with 10 μL of the amplification product and 6 μL of DGL-200 Maker at the same time, subject to 2.5% agarose gel electrophoresis, followed by analysis of amplification results by the ultraviolet gel imaging system and taking pictures. The primer sets used in the study are shown in table 1.

Table 1. Primer sequence design during PCR.

primername	Former primer	Back primer	Length (bp)
EGFL7	5'-GGAAGAGCTT CGACCAGCTG-3'	5'-GAGCCTGT TAGTTTACAG-3'	132
VEGF	5'-AACCGAGCTT AGGCCAGCTG-3'	5'-AAGCCTGA CGCGTTTACAG-3'	128
GAPDH	5'-CAGCATTGGA AGTGCTATGG-3'	5'-TAGAGCGAG TATGCATGACA-3'	138

Analysis of Renin and Ang II expression levels by Western blot

The hemangioma tissue was homogenized and transferred to a centrifuge at 8000 rpm, centrifuged at 4°C for 15 min to collect the supernatant and store it in an ultra-low temperature refrigerator at -80°C.

After preparing 10% SDS-polyacrylamide separation gel, the gel was placed on the electrophoresis tank, and protein was extracted from the hemangioma tissue cells of each group for electrophoresis. After electrophoresis, it was transferred to a polyvinylidene fluoride film, and sealed with 5% skim milk powder at room temperature for 2 h. Then, the sample was washed, followed by addition of diluted (1:1000) protein antibody for reaction overnight at 4°C. After that, the solution was washed twice with TBST, each time lasted for 8min; then HRP-labeled secondary antibody (1:500) was added (The kit was purchased from Shanghai Beyotime Biotechnology) for reacting at 37°C for 2h, then washed twice again with TBST for 8min each time. In contrast, a negative control group was established, with GAPDH monoclonal antibody as the primary antibody and HRP labeled IgG as the secondary antibody.

Statistical analysis

The data in this study were all processed by SPSS20.0 statistical analysis software; the measurement data were expressed by "mean ± standard deviation"; analysis of variance was taken for comparison between multiple groups, LSD-t test was used for comparison between two groups; the count data were expressed by percentage (%); $P < 0.05$ means statistically significant difference.

RESULTS

Changes in mice body weight before and after administration

The effects of ^{32}P application and timolol maleate on the body weight of nude mice are shown in table 2. It can be seen from table 1 that the body weight of nude mice increased to a certain extent after timolol maleate administration compared with the control group, and the body weight gain was more obvious after co-administration of ^{32}P application combined with single application of timolol maleate. Compared with the control group and single administration group, the difference was statistically significant ($P < 0.05$). The comparison results of body weight of nude mice indicate that both single application of timolol maleate and combine scheme of ^{32}P application and timolol maleate produced a certain inhibitory effect on mice weight loss caused by hemangioma (table 2).

Table 2. Comparison of body weight of mice in each group (n=20).

Group	Weight (g)
Control group	18.32±2.65
Timolol maleate administration group	22.35±2.86
^{32}P application + timolol maleate co-administration group	26.61±2.12
F value	13.263
P value	0.001

The effect of ^{32}P application combined with timolol maleate on hemangioma volume

The effect of ^{32}P application and timolol maleate on hemangioma volume of nude mice is shown in table 3. As can be seen from table 3, compared with the control group, the administration group of timolol maleate had significantly reduced tumor volume ($P < 0.05$). After co-administration of ^{32}P application and timolol maleate, the tumor volume was further reduced, showing significant difference compared with that of single administration group ($P < 0.05$). The results suggest that topical use of timolol maleate eye drops significantly reduced hemangioma volume of nude mice. Co-administration of ^{32}P application and timolol maleate produced better therapeutic effect on hemangioma (table 3).

Table 3. The effect of ^{32}P application and timolol maleate on hemangioma volume of nude mice (n=20).

Group	a(mm)	b(mm)	tumor volume (mm ³)
Control group	8.46	4.89	105.46±4.79
Timolol maleate administration group	6.32	4.01	52.84±3.48
^{32}P application + timolol maleate co-administration group	4.03	3.14	20.87±2.23
F value	13.245	12.612	26.735
P value	0.001-	0.001	0.001

Observation of histopathological structure of hemangioma in nude mice

Observation of histopathological structure of hemangioma under the microscope after HE staining revealed that the blank control nude mice had proliferative changes in hemangioma, showing accumulation of a large number of vascular endothelial cells, darker cell nucleus, dense capillaries in the tumor, and complete wall structure. In the administration group of timolol maleate, endothelial cells in hemangioma of nude mice were sparse, the cell nucleus was flat, the structure of blood vessel wall was deficient, and fibrous adipose tissue was visible in the lumen. In co-administration group of ^{32}P application and timolol maleate, the number of endothelial cells in hemangioma of nude mice was significantly reduced, the staining of cell nucleus became lighter, and the blood vessels were mainly dominated by fibrous connective tissue. It

suggests that topical timolol maleate produced certain therapeutic effect on infantile superficial hemangioma, co-administration of ^{32}P application and timolol maleate was more effective in treating infantile superficial hemangioma.

Effects of ^{32}P application and timolol maleate on the expression of EGFL7 and VEGF genes

Real-time PCR gene test results indicate that, compared with the control group, single administration of timolol maleate significantly reduced the expression levels of EGFL7 and VEGF ($P=4.49$). After co-administration of ^{32}P application and timolol maleate, the expression levels of EGFL7 and VEGF were further down-regulated. Compared with single administration group, the difference was significant ($P<0.05$), as shown in table 4. The results suggest that timolol maleate can significantly inhibit the expression of hemangioma epidermal growth factor-like domain EGFL7 and endothelial growth factor VEGF, thereby achieving the purpose of inhibiting the growth and proliferation of tumor cells and treating hemangioma; After co-administration of ^{32}P application and timolol maleate, EGFL7 and VEGF were further inhibited, showing better therapeutic effect on hemangioma.

Table 4. RT-PCR detection of EGFL7, VEGF gene expression (n=20).

Group	EGFL7 (Gray value)	VEGF (Gray value)
Control group	3.24±0.40	3.74±0.32
Timolol maleate administration group	2.36±0.41	2.59±0.52
^{32}P application + timolol maleate co-administration group	1.06±0.06	1.05±0.12
F value	10.377	13.762
P value	0.001	0.001




Figure 1. RT-PCR detection of EGFL7, VEGF gene expression.

The effect of ^{32}P application combined with timolol maleate on Renin expression

The effect of ^{32}P application and timolol maleate on Renin expression in hemangioma of nude mice tissues is shown in table 5 and figure 2. Western blot test results indicate that, compared with the control group, the single application of timolol maleate significantly reduced the expression level of Renin ($P<0.05$). After co-administration of ^{32}P application and timolol maleate, the expression level of renin was further down-regulated, showing significant

difference compared with single administration group ($P<0.05$), as shown in table 5.

Table 5. The effect of ^{32}P application and timolol maleate on Renin expression in hemangioma of nude mice (n=20).

Group	Renin (Gray value)
Control group	3.62±0.06
Timolol maleate administration group	2.13±0.05
^{32}P application + timolol maleate co-administration group	1.08±0.04
F value	15.736
P value	0.001

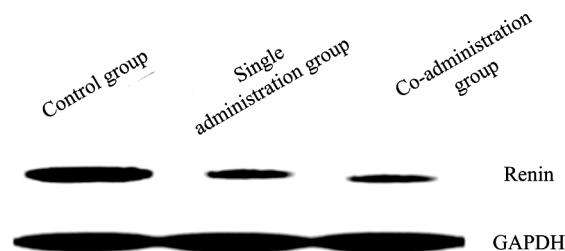


Figure 2. Western Blot detection of Renin expression.

The effect of ^{32}P application combined with timolol maleate on Ang II expression

The effect of ^{32}P application and timolol maleate on Ang II expression in hemangioma of nude mice is shown in table 6 and figure 3. The results of Western blot detection show that, compared with the control group, Ang II expression level was significantly reduced after administration of timolol maleate ($P=4.49$). After co-administration of ^{32}P application and timolol maleate, Ang II expression level was further down-regulated, showing significant difference compared with single administration group ($P<0.05$), as shown in table 6.

Table 6. The effect of ^{32}P application and timolol maleate on Ang II expression in hemangioma of nude mice (n=20).

Group	Ang II (gray value)
Control group	3.46±0.16
Timolol maleate administration group	2.37±0.21
^{32}P application + timolol maleate co-administration group	1.12±0.04
F value	18.215
P value	<0.05




Figure 3. Western Blot detection of Ang II protein expression.

DISCUSSION

Clinical treatments of infantile hemangioma include surgery, injection or application of β -receptor blockers, glucocorticoids, lasers, etc. However, there is no particular method that can treat all children

with hemangioma, and different treatment methods all have certain side effects⁽⁸⁻¹⁰⁾. The combination of multiple treatment methods can overcome the defects of low efficiency and side effects of single medication to a certain extent, which is of great clinical treatment significance^(11,12).

Timolol maleate eye drop is a non-selective β -receptor blocker with high safety, which has a good effect in treating infantile hemangioma^(13,14). Studies have shown that ³²P application has high efficiency and good prognosis in treatment of infantile hemangioma and scar removal⁽¹⁵⁾; the combination of the two drugs is expected to achieve excellent therapeutic effect in synergistic treatment of hemangioma⁽¹⁶⁾. Epidermal growth factor-like domain 7 (EGFL7) is an endothelial cell-specific secreted factor that is selectively expressed in tumor neovascularization and proliferative tissues, which plays a key role in angiogenesis⁽¹⁷⁾. As the most important regulator of vascular production, vascular endothelial growth factor (VEGF) can induce vascular production, change the extracellular mechanism, thus playing a key role in the pathogenesis of hemangioma⁽¹⁸⁾. Studies have confirmed that renin-angiotensin can inhibit the apoptosis of hemangioma endothelial cells, which plays an important role in the occurrence and development of infantile hemangioma^(19, 20). However, the curative effect of combined use of ³²P and timolol maleate on infantile superficial hemangioma remains unclear, which limits its application as clinical drugs.

In this study, it was found that the hemangioma tissue volume of nude mice treated with timolol maleate decreased compared with the control group, and the body weight increased to a certain extent. Compared with the single administration group, the hemangioma tissue volume was smaller in the ³²P application and timolol maleate combined administration group, and the weight gain was more significant in the nude mice. This indicates that timoprolol maleate had a certain therapeutic effect on hemangioma in nude mice, and the combined administration of timoprolol maleate with ³²P application had a better effect. To further explore the possible mechanism of ³²P application combined with timolol maleate in the treatment of hemangioma in nude mice, the expressions of EGFL7, VEGF, renin, and Ang II were further detected using RT-PCR and Western Blot. RT-PCR gene detection showed that after administration of timolol maleate, EGFL7 and VEGF expressions were significantly reduced; after co-administration of ³²P application + timolol maleate, EGFL7 and VEGF levels were further reduced, showing significant difference compared with the single administration group ($P < 0.05$). Western Blot analysis indicated that after administration of timolol maleate, the expression levels of renin and Ang II were down-regulated; after co-administration of ³²P application + timolol maleate, the expressions of renin and Ang II were further decreased, showing

statistically significant difference compared with single administration group ($P < 0.05$). The results suggest that ³²P application combined with timolol maleate has good therapeutic effect on hemangioma in nude mice, which downregulates the expressions of renin and angiotensin Ang II and mediates low expression of epidermal growth factor domain EGFL7, vascular endothelial growth factor VEGF in hemangioma, thereby inhibiting angiogenesis, constricting blood vessels, and inducing tumor cell apoptosis.

In our analysis, Timoprolol maleate is a nonselective β -adrenoceptor antagonist with partial lipophilic properties that enhances transdermal absorption and reduces periocular IH with minimal side effects. These results and the work of Kukida *et al.* both indicate that the mechanism of action of timoprolol maleate is thought to be similar to the action of IH, namely, reducing the expression of vascular endothelial growth factor and angiogenesis in hypoxic retina via inhibiting HIF-1 and nitric oxide synthase⁽²¹⁾. On the other hand, the Nuclide ³²P Easy Pack is made from the radionuclide ³²P, which emits pure beta rays. Radionuclides have strong ionization ability, weak penetration, and a range of only a few millimeters within tissue, and can improve the therapeutic effect of infant superficial hemangioma, which may be related to the inhibition of vascular endothelial growth factor, renin and Angiotensin II expression. This result is consistent with the studies of Wang *et al.*, which all confirmed that ³²P application combined with thiomolol maleate significantly improved the cure rate and therapeutic effect in children with cutaneous hemangioma. In other words, as a kind of external irradiation, a certain dose of radionuclide is close to the lesion site, and the biological effect of ionizing radiation on the lesion site through radiation can reduce the rate of cell division, prolong the interval of nuclear division and occlusion of microvessels, so as to achieve the therapeutic purpose^(22,23).

One method should not be insisted on to treat any complication or disease, and several methods need to be tested^(24,25). Sometimes new technologies such as biotechnology or nanotechnology⁽²⁶⁻²⁸⁾, in many cases, antibiotics^(29,30) or genetic or⁽³¹⁻³³⁾ chemical⁽³⁴⁾ approaches are used. In this regard, most experiments have been performed on rats⁽³⁵⁾ and ultra-high performance liquid chromatography tandem mass spectrometry had an important equipment and machine learning for detection⁽³⁶⁾ and prediction⁽³⁷⁾, respectively.

In conclusion, ³²P application combined with timolol maleate has good therapeutic effect on hemangioma in nude mice, whose mechanism may be related to the inhibition of the expression of vascular endothelial growth factor, renin and angiotensin II. However, its specific mechanism of action remains unclear and further research is needed. According to the current research results, co-administration of ³²P

patch and timolol maleate has good therapeutic effect on hemangioma in nude mice, which provides certain experimental data and theoretical support for clinical application of such drug in treatment of infantile hemangioma.

ACKNOWLEDGEMENT

The research is supported by Hebei Youth Science and technology project (No. 20201580), application research of 32P applicator brachytherapy combined timolol in the treatment of infantile hemangioma.

Ethical compliance: Research experiments conducted in this article with animals or humans were approved by the Ethical Committee and responsible authorities of our research organization (s) following all guidelines, regulations, legal, and ethical standards as required for humans or animals.

Funding: Not applicable.

Conflicts of Interests: The authors declare no conflict of interests.

Author contribution: Rongxin Ma collected the samples. Zongliang Li analysed the data. Rongxin Ma and Zongliang Li conducted the experiments and analysed the results. All authors discussed the results and wrote the manuscript.

REFERENCES

- Takechi T, Kumokawa T, Kato R, Higuchi T, Kaneko T, Ieiri I (2018) Population Pharmacokinetics and Pharmacodynamics of Oral Propranolol in Pediatric Patients With Infantile Hemangioma. *J Clin Pharmacol*, **8**(10): 1361-1370.
- Duan L, Renzi S, Weidman D, Waespe N, Chami R, Manson D, Cada M, Carcao M (2020) Sirolimus Treatment of an Infant With Intrathoracic Kaposiform Hemangioendothelioma Complicated by Life-threatening Pleural and Pericardial Effusions. *J Pediatr Hematol Oncol*, **42**(1): 74-78.
- Wang XH, Feng W, Zhao XF, Liu ZY (2020) The Efficacy and Safety of Topical beta-Blockers in Treating Infantile Hemangiomas: A Meta-Analysis Including 11 Randomized Controlled Trials. *Dermatology*, **7**(10): 1-11.
- Duan L, Renzi S, Weidman D, Waespe N, Chami R, Manson D, Cada M, Carcao M (2020) Sirolimus treatment of an infant with intrathoracic kaposiform hemangioendothelioma complicated by life-threatening pleural and pericardial effusions. *J Pediatr Hematol Oncol*, **42**(1): 74-78.
- Revathy VN, Shefrin S, Akhil S, Anoop KR, Sreeja CN (2018) Sustained release timolol maleate loaded ocusert based on biopolymer composite. *Int J Biol Macromol*, **110**(8): 308-317.
- Haddy N, Andriamboavonjy T, Paoletti C, Dondon MG, Mousannif A, Shamsaldin A, et al. (2009) Thyroid adenomas and carcinomas following radiotherapy for a hemangioma during infancy. *Radiation Oncol*, **93**(2): 377-382.
- Koji K, Syoji U, Takashi Y, Yaeta E, Kozo O, Yuzuru T (2002) A RelA-SpT homolog (Cr-RSH) identified in Chlamydomonas reinhardtii generates stringent factor in vivo and localizes to chloroplasts in vitro. *Nucleic Acids Res*, **30**(22): 4985-4992.
- Kang MG, Kim KH, Park JY, Koo SW, Chin DK, Kim KS, Cho YE (2019) Intramedullary cavernous hemangioma with calcification of spinal cord. *World Neurosurg*, **130**: 298-303.
- Guo XN, Dong CX, Liu QY (2019) The sustained and targeted treatment of hemangiomas by propranolol-loaded CD133 aptamers conjugated liposomes-in-microspheres. *Biomed Pharmacotherapy*, **114**: 108823.
- Mukherjee B, Vijay V, Halbe S (2018) Combined approach to management of periocular arteriovenous malformation by interventional radiology and surgical excision. *Indian J Ophthalmol*, **66**(1): 151-154.
- Kolbe AB, Mellow AC, Eckel LJ, Kalina P, Ruano R (2019) Congenital hemangioma of the face-value of fetal MRI with prenatal ultrasound. *Radiol Case Rep*, **14**(11): 1443-1446.
- Zhu YL, Wan XF, Abliz P (2019) Effects of laser irradiation on growth factors and cell apoptosis of in vitro cultured infant hemangioma endothelial cells. *Life Sciences*, **233**(9): 116685.
- Shokry M, Hathout RM, Mansour S (2018) Exploring gelatin nanoparticles as novel nanocarriers for Timolol Maleate: Augmented in-vivo efficacy and safe histological profile. *Int J Pharm*, **545**(1-2): 229-239.
- Abou AAAM and Hendawy HAM (2019) Chemometrics-assisted voltammetric determination of timolol maleate and brimonidine tartrate utilizing a carbon paste electrode modified with iron (III) oxide nanoparticles. *Microchem J*, **145**: 313-329.
- Zhao ZS, Manser E (2006) Chapter 37: blot overlays with 32p-labeled gst-ras fusion proteins: application to mapping protein-protein interaction sites. *Cell Biol (Third Ed)*, **4**: 285-288.
- Goldberg I, Gil Pina R, Lanzagorta-Aresti A, Schiffman RM, Liu C, Bejanian M (2014) Bimatoprost 0.03%/timolol 0.5% preservative-free ophthalmic solution versus bimatoprost 0.03%/timolol 0.5% ophthalmic solution (Ganfort) for glaucoma or ocular hypertension: a 12-week randomised controlled trial. *Br J Ophthalmol*, **98**(7): 926-31.
- Richter A, Alexdottir MS, Magnus SH, Richter TR, Morikawa M, Zwijsen A, Valdimarsdottir G (2019) EGFL7 mediates BMP9-induced sprouting angiogenesis of endothelial cells derived from human embryonic stem cells. *Stem Cell Reports*, **12**(6): 1250-1259.
- Ribatti D (2019) The discovery of the fundamental role of VEGF in the development of the vascular system. *Mech Dev*, **160**: 103579.
- Kukida M, Sawada H, Daugherty A, Lu HS (2020) Megalin: A Bridge Connecting Kidney, the Renin-angiotensin System, and Atherosclerosis. *Pharmacol Res*, **151**(1): 104537.
- Wilkinson-Berka JL, Suphapolimol V, Jerome JR, Deliyanti D, Allingham MJ (2019) Angiotensin II and aldosterone in retinal vasculopathy and inflammation. *Exp Eye Res*, **187**: 107766.
- Ganti AK, Ray J, Mooney KL, Zambrano E, Hillard PJA, Fok W (2019) Unusual cause of pediatric vaginal bleeding: infantile capillary hemangioma of the cervix. *J Pediatr Adolesc Gynecol*, **32**(1): 80-82.
- Wang J, Li N, Fan YG, Yang NN, Xia L (2019) Primary Extranodal Natural Killer/T-Cell Nasal-Type Lymphoma of Spine: A Case Report. *Medicine (Baltimore)*, **98**(44): e17661.
- Bornfeld N and Kreusel KM (2007) Capillary hemangioma of the retina in cases of von hippel-lindau syndrome. New therapeutic directions. *Ophthalmologe*, **104**(2): 114-118.
- Wang S, Zhao Y, Li J, Lai H, Qiu C, Pan N, Gong Q (2020) Neurostructural correlates of hope: dispositional hope mediates the impact of the SMA gray matter volume on subjective well-being in late adolescence. *Soc Cogn Affect Neurosci*, **4**(4): 395-404.
- Feng Q, Li Y, Wang N, Hao Y, Chang J, Wang Z, Zhang X, Zhang Z, Wang L (2020) A biomimetic nanogenerator of reactive nitrogen species based on battlefield transfer strategy for enhanced immunotherapy. *Small (Weinheim an der Bergstrasse, Germany)*, **16**(25): 2002138.
- Su F, Jia Q, Li Z, Wang M, He L, Peng D, Song Y, Zhang Z, Fang S (2018) Aptamer-templated silver nanoclusters embedded in zirconium metal-organic framework for targeted antitumor drug delivery. *Microporous Mesoporous Mater*, **275**: 152-62.
- Jin Y, Zhu H, Jin F, Shi C, Yang L, Qian J, Zhang S (2020) Fluorouracil nanoliposomes promote apoptosis of human gastric cancer xenografts in nude mice. *Nanosci Nanotechnol Lett*, **12**(5): 690-5.
- Alkudhayri AA, Wahab R, Siddiqui MA, Ahmad J (2020) Selenium Nanoparticles Induce Cytotoxicity and Apoptosis in Human Breast Cancer (MCF-7) and Liver (HepG2) Cell Lines. *Nanosci Nanotechnol Lett*, **12**(3): 324-30.
- Liu G, Ren G, Zhao L, Cheng L, Wang C, Sun B (2017) Antibacterial activity and mechanism of bifidocin A against Listeria monocytogenes. *Food Control*, **73**: 854-61.
- Liu H, Liu X, Zhao F, Liu Y, Liu L, Wang L, Geng C, Huang P (2019-2020) Preparation of a hydrophilic and antibacterial dual function ultrafiltration membrane with quaternized graphene oxide as a modifier. *J Colloid Interface Sci*, **562**: 182-92.
- Zou Q, Xing P, Wei L, Liu B (2019) Gene2vec: gene subsequence embedding for prediction of mammalian N6-methyladenosine sites from mRNA. *RNA*, **25**(2): 205-18.
- Zhang J and Liu B (2019) A review on the recent developments of sequence-based protein feature extraction methods. *Current Bioinforma*, **14**(3): 190-9.
- Xu L, Jiang S, Zou Q (2020) An in silico approach to identification, categorization and prediction of nucleic acid binding proteins. *Brief Bioinform*, **22**(3): 171.
- Wang M, Hu M, Li Z, He L, Song Y, Jia Q, Zhang Z, Du M (2019) Construction of Tb-MOF-on-Fe-MOF conjugate as a novel platform for ultrasensitive detection of carbohydrate antigen 125 and living cancer cells. *Biosens Bioelectron*, **142**: 111536.
- Zhu S, Wang X, Zheng Z, Zhao XE, Bai Y, Liu H (2020) Synchronous measuring of triptolide changes in rat brain and blood and its application to a comparative pharmacokinetic study in normal and Alzheimer's disease rats. *J Pharm Biomed Anal*, **185**: 113263.
- Zhu S, Zheng Z, Peng H, Sun J, Zhao XE, Liu H (2019) Quadruplex stable isotope derivatization strategy for the determination of panaxadiol and panaxatriol in foodstuffs and medicinal materials using ultra high performance liquid chromatography tandem mass spectrometry. *J Chromatogr A*, **1616**: 460794.
- Wang XF, Gao P, Liu YF, Li HF, Lu F (2020) Predicting Thermophilic Proteins by Machine Learning. *Curr Bioinforma*, **15**(5): 493-502.