Volume 20, No 1 | International Journal of Radiation Research, January 2022

Multi-catheter interstitial brachytherapy for an advanced breast cancer patient with multiple complications: A case report

W. Yan, Y. Wang, X. Wang, J. Yang*, L. Liu*

Department of Radiotherapy, Second Hospital of Jilin University, Changchun, Jilin Province, 130021, China

► ***Case Report***

Corresponding authors:
Dr. Linlin Liu,
E-mail: *iruogu1234@163.com*

Dr. Jianzheng Yang,
E-mail: *chinawtj218@163.com*

Received: March 2020
Final revised: April 2021
Accepted: May 2021

Int. J. Radiat. Res., January 2022; 20(1): 253-256

DOI: 10.52547/ijrr.20.1.40

Keywords: *Breast cancer, brachytherapy, liver metastasis.*

ABSTRACT

Background*:** Multi-catheter interstitial brachytherapy (MIB) is one kind of accelerated partial breast irradiation, which applied only to local target breast tissue for patients with breast cancer. The objective of this case report was to report the therapeutic effect of interstitial brachytherapy for treating advanced breast cancer with multiple complications. ***Case summary: The patient was a 64-year-old woman with diagnosed stage IV breast cancer and multiple complications that included primary liver cancer, post-hepatitis cirrhosis, and hypertension. In October 2016, the patient was treated with chemoembolization for liver cancer, and chemotherapy and targeted molecular therapy in a series for advanced breast cancer at Jilin Province Cancer Hospital before admission to Second Hospital of Jilin University. The tumor in her right breast was about 13.0 cm × 11.0 cm, and the surface was red, swollen, and ulcerated. As the patient was not suitable for surgery and intolerant to further chemotherapy the tumor was treated with interstitial brachytherapy. The brachytherapy was performed once a week, overall three times as doses of 28 Gy in 3 fractions. She was then treated by external radiotherapy with a dose of 50 Gy in 25 fractions. The treatment was ended in December 2016. During the follow-up in January 2017, the original breast mass had necrosed and shrank. No overt bleeding or exudation was found. The patient has survived until now. ***Conclusions:*** For this patient with advanced breast cancer and multiple complications, interstitial brachytherapy was an effective treatment.

CORE TIP

Multi-catheter interstitial brachytherapy (MIB) is one kind of accelerated partial breast irradiation, which can effectively reduce irradiation of the skin, lung, and heart compared with whole-breast irradiation. The currently recognized indications of MIB concern patients who have undergone breast-conserving surgery and whole-breast irradiation, and experienced breast cancer recurrence. The present case supplies evidence that for patients with advanced breast cancer and multiple complications, interstitial brachytherapy is an effective treatment.

Clinical practice points

Multi-catheter interstitial brachytherapy (MIB) was initially introduced as a boost after breast-conserving surgery and whole-breast irradiation. It is an attractive therapy, as it can effectively reduce radiation of the skin, lung, and heart compared with whole-breast irradiation. According to this report, if neither the results of whole breast irradiation nor systemic chemotherapy is ideal, for patients with large local mass who cannot undergo surgery, MIB was an effective treatment. It indicates a useful therapy choice for patients with advanced breast cancer and multiple complications on clinical practice in the foreseeable future. Accelerated partial breast irradiation (APBI) is a type of radiotherapy applied only to local target breast tissue for patients with breast cancer [1]. The mortality rate of APBI for breast cancer patients is similar to that of whole breast irradiation, but the radiotherapy course is shorter [2].

The four types of APBI are multi-catheter interstitial brachytherapy (MIB), intracavitary brachytherapy, three-dimensional conformal external beam radiation therapy, and intra-operative radiotherapy. MIB was initially introduced as a boost after breast-conserving surgery and whole-breast irradiation [3]. It is an attractive therapy, as it can effectively reduce irradiation of the skin, lung, and heart compared with whole-breast irradiation. The currently recognized indications of MIB concern patients who have undergone breast-conserving surgery and whole-breast irradiation, and experienced breast cancer recurrence [3]. However, there are still a small number of patients with large local masses who cannot undergo surgery, and

[Downloaded from ijrr.com on 2026-11-27]

[DOI: 10.52547/ijrr.20.1.40]

neither the results of whole breast irradiation nor systemic chemotherapy is ideal [4].

In this case report, MIB was performed on a patient with advanced breast cancer and multiple complications. The report was exempted from an ethics review by the Jilin University Ethics Review Board. The result of this case suggests that MIB can be an appropriate treatment choice for large local breast masses.

Case presentation

Patient information

On 19 October 2016, a 64-year-old woman presented to the Department of Radiotherapy at Second Hospital of Jilin University with an 18-month history of breast cancer. She complained of continuous enlargement of the right breast mass since the right breast cancer was diagnosed at the Cancer Hospital of Jilin Province in April 2015. According to the breast color ultrasound examination (Philips iE33 Ultrasound Machine, USA) in the cancer hospital at that time, a 3.6 cm × 2.1 cm solid hypoechoic mass was found in the upper outer quadrant of her right breast. Another right breast lesion biopsy on 6 April 2015 indicated a diagnosis of primary breast invasive carcinoma with the following test results: negative estrogen receptor and progesterone receptor and canalicular immunostaining of neprilysin; positive receptor tyrosine-protein kinase erbB-2 (C-erbB-2), tumor protein 53, and cytokeratin 5/6; and 40% Ki-67 antibody. In April 2015, a 3.0 cm × 2.4 cm substantially non-uniform echo was found in the upper segment of the right posterior lobe of the liver on color Doppler ultrasound, and the boundary was not clear. A fine-needle aspiration biopsy showed a few atypical cells that were creatine kinase-positive, which was consistent with undifferentiated carcinoma. Hepatic arterial chemoembolization was performed twice in April and May 2015, respectively. The patient was then discharged from the hospital per her request, and the intervention was interrupted.

Due to the continuous enlargement of the right breast mass, she was admitted to First Hospital of Jilin University in September 2015. The breast Doppler examination (Philips iE33 Ultrasound Machine, USA) showed that the size of the right breast mass had increased to about 10.5 cm × 7.2 cm, with multiple swollen lymph nodes under the right armpit.

Positron emission tomography-computed tomography (SIEMENS Biograph 16 PET/CT, Germany) examination showed increased metabolism of the right breast mass, consistent with breast cancer signs. The other PET-CT findings included the following: (1) the right anterior medial pleural nodules also showed increased metabolism, which was considered pleural metastasis; (2) there was increased metabolism of the small lymph nodes in the posterior sternal space, judged as lymph node metastases; (3) there were liver lesions with the post -change after chemoembolization.

Because of the patient's metastatic condition and the vast primary breast lump, adjuvant chemotherapy was administered first. From October 2015 to June 2016, the patient was treated with several courses of chemotherapy (e.g., docetaxel, carboplatin, and paclitaxel) and molecular targeted therapy with Herceptin (trastuzumab). The chemotherapy doses of docetaxel injection (Jiangsu Hengrui Pharmaceutical), carboplatin (Qilu Pharmaceutical), and paclitaxel (Yangzijiang Pharmaceutical Group) were 75 mg/m^2, 500 mg, 135 mg/m^2, respectively. For Herceptin (Roche Holding AG, Switzerland), we adhered to the recommendation of an initial load of 8 mg/kg and a maintenance dose of 6 mg/kg. However, the breast mass showed no apparent shrinkage. On 29 June 2016, due to the continuous increase of the right breast mass, weekly treatment with albumin paclitaxel + single agent trastuzumab (Herceptin) was given for eight courses, during which the patient's blood calcium increased significantly, and parathyroid gland intervention was performed. After the blood calcium was controlled, she was referred to our hospital.

Clinical finding

Physical examination after admission found that the left breast was normal, while the right breast was swollen (figure 1). The right breast lump was about 13.0 cm × 11.0 cm and located in the upper outer quadrant without pain or nipple discharge. The surface of the lump was red and swollen. The activity of the lump was poor. The large lesion slightly restricted the right upper extremity. Also found was an isolated swollen axillary node of about 2.5 cm × 3.0 cm and weak activity.



Figure 1. Huge right breast cancer mass before treatment.

Diagnostic assessment

The patient had a history of hepatitis B for 20 years and a history of hypertension for three years. Intermittent oral antihypertensive drugs were used, and blood pressure control was acceptable. According to her physical examination and medical history, at admission, the clinical diagnosis was the following: stage IV right breast invasive carcinoma

[Downloaded from ijrr.com on 2026-11-27]

[DOI: 10.52547/ijrr.20.1.40]

with pleural and axillary lymph node metastases; stage B primary liver cancer after chemoembolization; type B post-hepatitis cirrhosis; post-parathyroid glandular intervention; and high-risk hypertension II.

Therapeutic intervention

Multi-catheter interstitial brachytherapy (Iridium-192 source for high dose rate brachytherapy, courtesy of Nucletron, Netherlands) was performed after the patient's admission. The design treatment plan was as follows. With the catheters equally and evenly (10 mm) placed within each implant plane, we performed a uniform dose in the target area by optimizing the dwell point and dwell time. [5] The skin, chest wall, and ribs received very little or no radiation. The brachytherapy was performed once a week, three times in total, with a dose of 28 Gy in three fractions (the insertion and position of the catheter are shown in figure 2, and the dose distribution in figure 3. The patient was then treated by external radiotherapy with a dose of 50 Gy in 25 fractions. She was discharged from our hospital in December 2016.

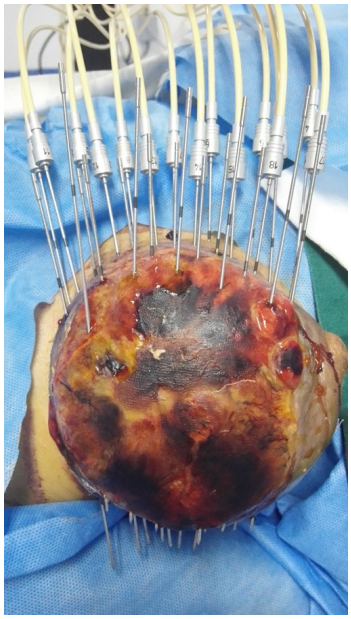

Figure 2. The position and number of catheter insertions for multi-catheter interstitial brachytherapy.

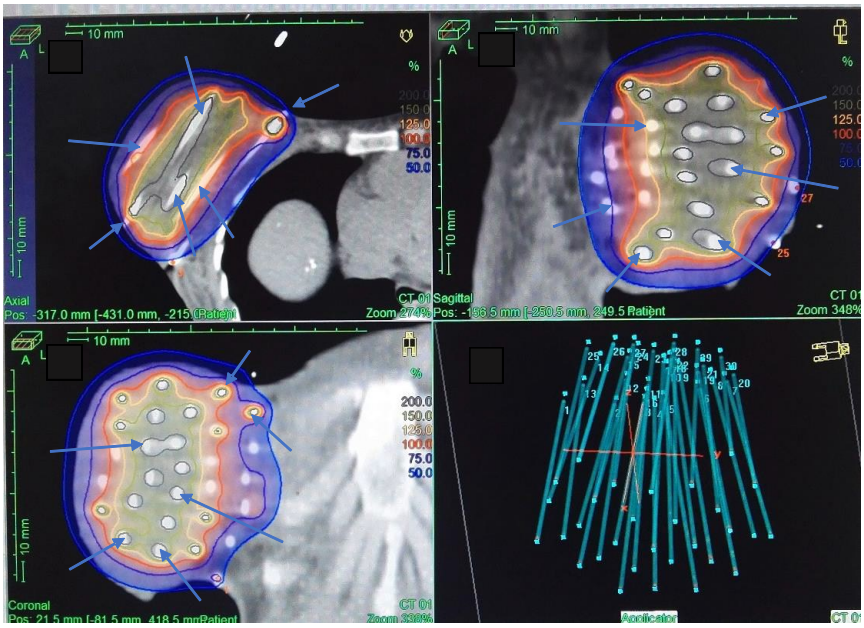

Figure 3. Location of the brachytherapy needles (some marked by arrows), dose distributions, and dose difference maps of high dose rate brachytherapy sampled onto a CT scan of the patient. **(A)** Location of the brachytherapy needles and dose distribution of brachytherapy. **(B)** Cross-sectional image of the needle location and dose distribution. **(C)** Cross-sectional image of the needle location and dose distribution. **(D)** The channel diagram of the brachytherapy needles.

Follow-up

The patient recovered well after the therapy. She was followed-up once per month for the first three months after her discharge, and then once every three months until January 2019. Figure 4 shows the breast mass condition in January 2017. The mass shrank, the ulcer wound had no overt bleeding or exudation, and no necrosis of the nipple was found. Liver cancer had not progressed. The patient has survived during the follow-up to this day.



Figure 4. The tumor condition after 2.5 months.

DISCUSSION

Breast cancer is the most common solid tumor in women [6]. Patients with early or operable breast cancer are routinely treated with neoadjuvant systemic therapy, loco-regional therapy (including surgery and radiation), and adjuvant systemic therapy (adjuvant chemotherapy, endocrine therapy, targeted therapy, and immunotherapy) [7-12]. However, for patients with inoperable advanced breast cancer, most cases require a combined treatment approach with neoadjuvant systemic and radiation therapy [6, 12, 13]. In the present case, this patient with advanced breast cancer had multiple complications that included primary liver cancer, post-hepatitis cirrhosis, and hypertension. Her condition was considered inoperable because the tumor lesions were massive (e.g., 13.0 cm × 11.0 cm) with skin ulcers, necrotic exudation, and adhesions to the chest wall, and she had distant metastases. Direct surgical resection may have led to early

[Downloaded from ijrr.com on 2026-11-27]

[DOI: 10.52547/ijrr.20.1.40]

recurrence and even further metastasis. According to her medical treatment history, neoadjuvant chemotherapy and targeted therapy were not effective. Her only other therapeutic option was radiation.

As a type of APBI, MIB has the advantage that the radioactive catheters are inserted directly into the tumor; the radiation does not pass through healthy tissues and organs, but through the target area of the tumor with a sufficiently high dose [14]. The tumor can shrink or disappear in a short period, and according to the inverse-square law, the exposure of surrounding normal tissues (such as endangered organs) is significantly reduced. In addition, the catheters are directly in contact with the target volume, and even if the target area moves, the catheters move in sync. Therefore, MIB can avoid the illumination errors caused by positional change.

MIB has been recognized worldwide for its dosimetric advantages, with an excellent curative effect for loco-regional control of early breast cancer [15-17]. Unlike early breast cancer, with existing treatments, advanced inoperative breast cancer is considered incurable. Although there is no available data regarding radiotherapy trials for clinical inoperable advanced breast cancer, additional radiation after surgery results in better local control and overall survival [4, 18]. The purpose of radiotherapy in inoperable advanced breast cancer is to achieve local control, shrink the tumor or prevent further growth, and thereby improve the quality of life of patients to some extent.

To our best knowledge, this report is the first to describe treating a patient with advanced breast cancer and multiple complications with MIB. However, MIB technology is challenging to implement and requires high professional skills and experience. According to the linear-quadratic formula, the single prescription dose is generally ≤ 10 Gy per fraction [19]. The prescription should take advantage of the high dose rate, but at the same time fully consider the patient's tolerance, tumor size, and long-term response.

MIB was administered to a patient with advanced breast cancer and multiple complications, and perfect clinical outcomes were achieved. We propose that MIB can be considered an option for this kind of patient. However, more clinical data are needed regarding a balance between optimal benefit and harm.

Ethical approval

The ethics committee of Second Hospital of Jilin University approved this study. All procedures performed in studies involving human participants were conducted in accordance with the ethical standards of the institutional and/or national research committee and with the 1964 Helsinki Declaration and its later amendments or comparable ethical standards.

Informed Consent

Written informed consent was obtained from individual participants.

ACKNOWLEDGMENT

None.

***Ethical consideration*:** Not applicable.
***Funding*:** None.
***Conflicts of interest*:** Declared none.
***Author contribution*:** Conception and design: (W.Y), (J.Y) and (L.L); Administrative support: (L.L); Provision of study materials or patients: (W.Y), (X.W); Collection and assembly of data: (W.Y), (Y.W); Data analysis and interpretation: (W.Y), (Y.W), (X.W).

REFERENCES

1. Deng X, Wu H, Gao F, Su Y, Li Q, Liu S, Cai J (2017) Brachytherapy in the treatment of breast cancer. *Int J Clin Oncol*, ***22***: *641-650*.
2. Polgar C, Major T, Fodor J, Nemeth G, Orosz Z, Sulyok Z, Udvarhelyi N, Somogyi A, Takacsi-Nagy Z, Lovey K, Agoston P, Kasler M (2004) High-dose-rate brachytherapy alone versus whole breast radiotherapy with or without tumor bed boost after breast-conserving surgery: seven-year results of a comparative study. *Int J Radiat Oncol Biol Phys*, ***60***: *1173-1181*.
3. Sumodhee S, Strnad V, Hannoun-Levi JM (2018) Multicatheter interstitial brachytherapy for breast cancer. *Cancer Radiother*, ***22***: *341-344*.
4. Yang TJ and Ho AY (2013) Radiation Therapy in the Management of Breast Cancer. *Surgical Clinics of North America*, ***93***: *455-471*.
5. Hepel JT, Arthur D, Shaitelman S, Polgar C, Todor D, Zoberi I, Kamrava M, Major T, Yashar C, Wazer DE (2017) American Brachytherapy Society consensus report for accelerated partial breast irradiation using interstitial multicatheter brachytherapy. *Brachytherapy*, ***16***: *919-928*.
6. Akram M, Iqbal M, Daniyal M, Khan AU (2017) Awareness and current knowledge of breast cancer. *Biol Res*, ***50***: *33*.
7. Untch M, Konecny GE, Paepke S, von Minckwitz G (2014) Current and future role of neoadjuvant therapy for breast cancer. *Breast*, ***23***: *526-537*.
8. Akyurek S and Yavas G (2013) Role of postmastectomy radiation therapy after neoadjuvant chemotherapy in locally advanced breast cancer. *Exp Oncol*, ***35***: *267-271*.
9. Muss HB (2001) Role of adjuvant endocrine therapy in early-stage breast cancer. *Semin Oncol*, ***28***: *313-321*.
10. McArthur HL and Page DB (2016) Immunotherapy for the treatment of breast cancer: checkpoint blockade, cancer vaccines, and future directions in combination immunotherapy. *Clin Adv Hematol Oncol*, ***14***: *922-933*.
11. Perez EA and Spano JP (2012) Current and emerging targeted therapies for metastatic breast cancer. *Cancer*, ***118***: *3014-3025*.
12. Waks AG, Winer EP (2019) Breast Cancer Treatment: A Review. *JAMA*, ***321***: *288-300*.
13. Ponzone R, Baum M (2013) Loco-regional therapy and breast cancer survival: searching for a link. *Breast*, ***22***: *510-514*.
14. Tryfonidis K, Senkus E, Cardoso MJ, Cardoso F (2015) Management of locally advanced breast cancer-perspectives and future directions. *Nat Rev Clin Oncol*, ***12***: *147-162*.
15. Lettmaier S, Kreppner S, Lotter M, Walser M, Ott OJ, Fietkau R, Strnad V (2011) Radiation exposure of the heart, lung and skin by radiation therapy for breast cancer: a dosimetric comparison between partial breast irradiation using multicatheter brachytherapy and whole breast teletherapy. *Radiother Oncol*, ***100***: *189-194*.
16. Perez CA, Taylor ME, Halverson K, Garcia D, Kuske RR, Lockett MA (1996) Brachytherapy or electron beam boost in conservation therapy of carcinoma of the breast: a nonrandomized comparison. *Int J Radiat Oncol Biol Phys*, ***34***: *995-1007*.
17. Guinot JL, Baixauli-Perez C, Soler P, Tortajada MI, Moreno A, Santos MA, Mut A, Gozalbo F, Arribas L (2015) High-dose-rate brachytherapy boost effect on local tumor control in young women with breast cancer. *Int J Radiat Oncol Biol Phys*, ***91***: *165-171*.
18. Kuske R (2014) Breast conservation therapy without capsular contracture in young augmented women using interstitial brachytherapy. *J Contemp Brachytherapy*, ***6***: *231-235*.
19. (2013) International Commission on Radiation Units and Measurements. *JICRU*, ***13***: NP.

[Downloaded from ijrr.com on 2026-11-27]

[DOI: 10.52547/ijrr.20.1.40]