

Tumor size impacts the performance of ultrasound BI-RADS classification in breast cancer patients

Q. Guo^{1*}, Z. Dong², L. Jiang³, L. Zhang⁴, Z. Li⁴, D. Wang⁴

¹Department of Ultrasound Medicine, Jinshan Branch of Shanghai Sixth People's Hospital Affiliated to Shanghai Jiaotong University, Shanghai, China

²Department of Laboratory Medicine, Jinshan Branch of Shanghai Sixth People's Hospital Affiliated to Shanghai Jiaotong University, Shanghai, China

³Department of Ultrasound in Medicine, Shanghai Jiao Tong University Affiliated Sixth People's Hospital, Shanghai Institute of Ultrasound in Medicine, Shanghai, China

⁴Department of Ultrasound Medicine, the Second Affiliated Hospital of Harbin Medical University, Harbin, China

► Original article

*Corresponding author:

Qiang Guo, M.D.,

E-mail:

qiangguo3303@163.com

Received: November 2020

Final revised: July 2021

Accepted: August 2021

Int. J. Radiat. Res., April 2022;
20(2): 341-346

DOI: 10.52547/ijrr.20.2.13

ABSTRACT

Background: This study aimed to evaluate the relationship of tumor size and ultrasound (US) Breast Imaging Reporting and Data System (BI-RADS), and further analyze if tumor size can impact the evaluation for US features in patients with breast cancer. **Materials and Methods:** In this retrospective study, preoperative US features and postoperative pathological results were collected from 498 patients with breast cancer. The association of BI-RADS classification with tumor size was analyzed, and the US features related to tumor size were determined. **Results:** A significant association was found between tumor size and BI-RADS category, and tumor with small size was classified into the low BI-RADS category ($p < 0.05$). Some US features including shape, growth orientation, microcalcification and color Doppler flow imaging (CDFI) were influenced by tumor size ($p < 0.001$). **Conclusion:** Tumor size can influence the diagnosis performance for US BI-RADS category in patients with breast cancer.

Keywords: BI-RADS, breast cancer, CDFI, diagnosis, tumor size, ultrasonography.

INTRODUCTION

Breast cancer has high mortality and morbidity rates in women ^(1, 2). However, many diagnostic methods are frequently limited due to their poor accuracy in the detection of early breast cancer. Ultrasound (US) is a sensitive examination method for newly diagnosed breast cancers ⁽³⁾. However, it strongly depends on the US operators and their experience in detecting, describing and interpreting the US features of breast mass ⁽³⁾. The visual effect of US image significantly influences their judgments while screening the breast mass, therefore, the mass size is an influential factor for operators in US examination. US has limitations related to small size, including limited field of view, high operator dependency and low accuracy ^(4, 5). However, the tumor size is rarely considered during US examination and evaluation of breast cancer.

Breast Imaging Reporting And Data System (BI-RADS) was first published in 2003, which provided three standardized US lexicons including shape, margin and growth orientation for the

classification of breast mass ⁽⁶⁻⁸⁾. With the development of US technology, the lexicons of BI-RADS have been greatly complemented by adding valuable features of echo pattern, posterior features, calcifications and elasticity in the fifth edition of BI-RADS released in 2013, which further improved the diagnostic performance of US ⁽⁹⁻¹¹⁾. In terms of the diagnosis of breast mass, the US examination primarily assesses the BI-RADS category to help the clinician to choose the appropriate treatment protocol ^(6, 12). However, the uncertain US features greatly affect the accuracy of BI-RADS category in a small mass compared to a larger mass ⁽¹³⁾. The size of breast mass is not considered as an influencing factor in the diagnosis of BI-RADS category. Moreover, few studies discussed the relationship of the mass size and BI-RADS in patients with breast mass ^(14, 15).

This is the first study to analyze tumor size as an influencing factor for US BI-RADS category. This novel idea can further improve the diagnostic performance of BI-RADS category in the patients with breast cancer.

MATERIALS AND METHODS

Ethics statement

This study involved non-invasive, anonymous and retrospective analysis, and was approved by the Ethics Committee of Jinshan Branch of Shanghai Sixth People's Hospital Affiliated to Shanghai Jiaotong University, after waiving written informed consent. A verbal informed consent was provided by all the patients for using their data in this study. Ethics committee approval was obtained before starting this study (Date: 24.1.2015, Registration number: 2015/12).

Patients

A retrospective analysis of the data from 498 female breast cancer patients aged 26-76 years was performed between November 2015 and May 2020. All the enrolled patients were evaluated by preoperative US and postoperative pathology examinations. According to the largest diameter (φ) of breast mass from US imaging examination prior to surgery, the patients were divided into four groups as follows: $\varphi \leq 10$ mm; $10 \text{ mm} < \varphi \leq 20$ mm; $20 \text{ mm} < \varphi \leq 30$ mm and $\varphi > 30$ mm, respectively. Patients who had received any treatments before operation were excluded.

Standard of ultrasound examination and BI-RADS analysis

Preoperative US examination was performed by two experienced sonographers with more than 5 years' experience in breast US using S2000 system (Siemens Medical Solutions, Mountain View, CA, USA) or HITACHI Vision 900 system (Hitachi Medical System, Tokyo, Japan) equipped with a linear-array transducer of 5-12 MHz. US image data including static image with the longitudinal and transverse axes, and cine clip through the mass on the models of the B-Mode and CDFI were collected. The US characteristics of the mass were described as follows: tumor shape (oval, round, irregular), growth orientation (parallel, not-parallel), margin (circumscribed, indistinct, microlobulated, angular, spiculated), posterior features (no features, enhancement, shadowing), calcifications (positive, negative), echogenicity (hypoechoic, isoechoic, heterogeneous) and CDFI (no flow, minimal, moderate and marked) based on the US lexicon of the fifth edition of BI-RADS (9) and the Adler's grading methods of CDFI (16).

All breast masses were divided into BI-RADS category 3, 4a, 4b, 4c and 5 according to the US features (6, 9, 17-19). BI-RADS category 1, 2 and 6 were omitted. A breast mass without any suspicious US feature was evaluated as BI-RADS 3, with 1-3 suspicious US features as BI-RADS 4 and with >3 suspicious US features as BI-RADS 5. BI-RADS 4 was divided into three subtypes as follows: a mass with

only one suspicious US feature was defined as category 4a, with two suspicious US features as category 4b and with three suspicious US features as category 4c.

In the interpretation of the features of US images and BI-RADS category, double-blind analysis was performed by two other sonographers with more than five years' experience in breast US. In case of disagreement, a consensus was achieved by consultation.

Methods for measurement of pathological factors

The type of pathology, histological grade of breast cancer and status of axillary lymph node metastasis were determined. Immunohistochemistry analyses using membrane and cytoplasm fractions were performed to determine the expression levels of estrogen receptor (ER), progesterone receptor (PR) and human epidermal growth factor receptor 2 (HER2). The cutoff point was 1% to distinguish between ER- and PR-positive and negative expression levels according to the immunohistochemical results (20). The 3+ immunohistochemical grade was considered as HER2 positive, and the grade 2+ was further classified into HER2 positive and negative by fluorescence in situ hybridization (FISH) (21). Breast cancer molecular subtypes of Luminal A type (LA), Luminal B type (LB), HER2 amplified type (HER2) and Triple-Negative type (TN) were analyzed from the immunohistochemistry results.

Statistical analyses

SPSS statistical software package (version 18.0; Chicago, IL, USA) was used to analyze all the data in this study. The correlation analysis of the diameter φ and BI-RADS category was performed by Chi-squared test or Fisher's exact test. The mean values of the diameter φ of masses were analyzed by the Mann-Whitney test and box plot graph. Further correlation analysis of the diameter, US features, and pathology results of tumor was performed by Chi-squared test. Inter-observer agreement was assessed with the Cohen's kappa statistics, kappa = 0.74. A $p < 0.05$ was considered to be statistically significant.

RESULTS

The mass size and BI-RADS category

According to the size of breast mass, a total of 498 patients were divided into four groups: ① in group one with the diameter ($\varphi \leq 10$ mm), 100 patients were classified into BI-RADS 3 (8, 8.0%), 4a (28, 28.0%), 4b (29, 29.0%), 4c (19, 19.0%) and 5 (18, 18.0%); ② in group two with the diameter ($10 \text{ mm} < \varphi \leq 20$ mm), 110 patients were classified into BI-RADS 3 (5, 4.5%), 4a (27, 24.5%), 4b (29, 26.4%), 4c (23, 20.9%) and 5 (26, 23.7%); ③ in group three

with the diameter ($20\text{ mm} < \phi \leq 30\text{ mm}$), 146 patients were classified into BI-RADS 3 (3, 2.1%), 4a (20, 13.7%), 4b (34, 23.3%), 4c (38, 26.0%) and 5 (51, 34.9%); ④ in group four with the diameter ($\phi > 30\text{ mm}$), 121 patients were classified into BI-RADS 3 (1, 0.7%), 4a (20, 14.1%), 4b (26, 18.3%), 4c (41, 28.9%) and 5 (41, 38.0%). Compared to group one, group two had no statistically significant difference ($p = 0.682$), while groups three ($p = 0.001$) and four ($p < 0.001$) had statistically significant differences (table 2). A bar chart was drawn to show the relationship between the percentage of number of masses with different diameters and BI-RADS categories (figure 1). It was observed that a small mass was more likely to be classified into the low BI-RADS category, whereas a large mass was more likely to be classified into the high category (figure 2).

Table 1. Comparing the size of breast cancer mass according to BI-RADS-US categories.

BI-RADS (n=498)			
3 (n=17)	4a (n=95)	4b (n=116)	4c (n=121)
8	28	27	19
5	27	29	23
3	20	34	38
1	20	26	41

Note: ϕ means the largest diameter of tumor measured by ultrasound;
* vs. $\phi \leq 10$

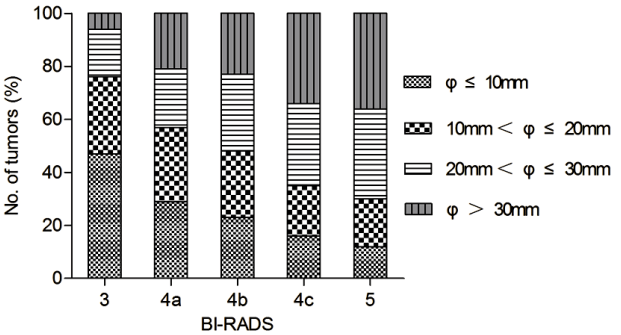


Figure 1. The percentage of the number of breast cancer masses with different sizes according to BI-RADS 3, 4a, 4b, 4c, and 5.

The average diameter of mass and BI-RADS category

Among the 498 patients with breast cancer, there were 17 (3.4%) patients with BI-RADS 3, 95 (19.1%) patients with BI-RADS 4a, 116 (23.3%) patients with BI-RADS 4b, 121 (24.3%) patients with BI-RADS 4c and 149 (29.9%) patients with BI-RADS 5. The average values of diameters of masses with BI-RADS 3, 4a, 4b, 4c or 5 were $14.51 \pm 8.03\text{ mm}$, $16.62 \pm 10.03\text{ mm}$, $20.26 \pm 11.44\text{ mm}$, $23.68 \pm 11.21\text{ mm}$ or $25.03 \pm 10.40\text{ mm}$, respectively ($p < 0.001$). The masses with large average diameter were more likely to be classified into the high BI-RADS category (figure 3).

Table 2. Correlation between ultrasound feature and size of breast cancer.

Features	Tumor size (mm)		P value
	$\phi \leq 20\text{ (n=210)}$	$\phi > 20\text{ (n=288)}$	
Tumor shape			
Round, oval	127	135	0.003
Irregular	83	153	
Growth orientation			
Parallel	131	146	0.010
not-parallel	79	142	
Margin			
Circumscribed	82	105	0.716
Indistinct	31	55	
Angular	33	39	
microlobulated	36	53	
spiculated	28	36	
Posterior features			
No features	58	75	0.152
Enhancement	86	99	
Shadowing	66	114	
Calcifications			
Positive	41	94	0.001
Negative	169	194	
Echogenicity			
Hypoechoic	150	180	0.115
Isoechoic	36	65	
Heterogeneous	24	43	
CDFI			
No flow, Minimal	121	114	<0.001
Moderate, Marked	89	174	

Note: ϕ means the largest diameter of tumor measured by ultrasound.

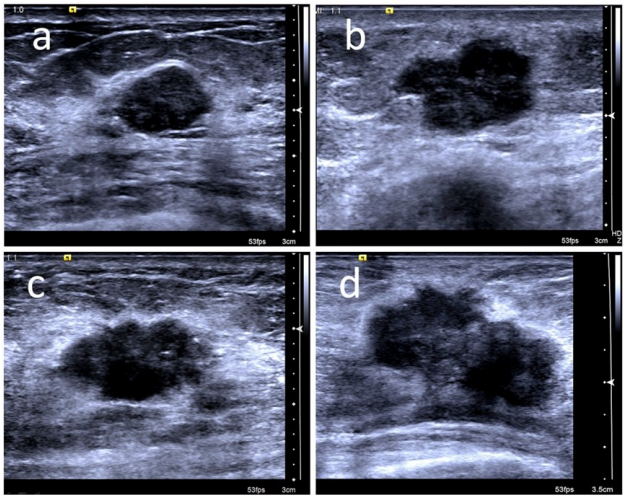


Figure 2. Comparison of the ultrasound features of breast cancer masses with different tumor sizes. The ultrasound image of a breast cancer mass of 11 mm diameter from a 40-year-old woman was diagnosed as BI-RADS 3 category according to the characteristics of hypoechoic, circumscribed margin, oval shape, parallel growth orientation and calcification negative (a). The ultrasound image of a larger breast cancer mass (diameter = 18 mm) in a 48-year-old woman was diagnosed as BI-RADS 4a category based on the positive characteristic of irregular shape (b). The ultrasound image of a breast cancer mass of 22 mm diameter from a 45-year-old woman was diagnosed as BI-RADS 4b category according to two positive characteristics of irregular shape and calcification (c). The ultrasound image of a larger breast cancer mass (diameter = 32 mm) in a 56-year-old woman was diagnosed as BI-RADS 4c category. according to three positive characteristics of irregular shape, calcification and spiculated margin (d).

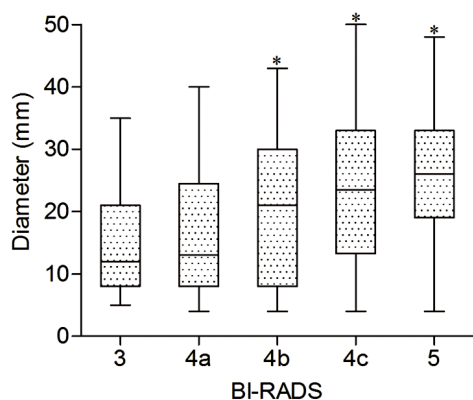


Figure 3. Comparison of the average value of the largest diameter of breast cancer masses based on the BI-RADS 3, 4a, 4b, 4c, and 5. * mean vs. 3, $p < 0.001$.

Correlation between US features and size of breast cancer mass

According to the size of breast mass, all the patients were divided into two groups, diameter $\phi \leq 20$ mm ($n=210$) and diameter $\phi > 20$ mm ($n=288$). The correlation analysis between the US features and the tumor size indicated that the shape, growth orientation, microcalcification and CDFI were significantly related to the tumor size. However, no statistically significant difference was found in margin, acoustic shadowing and echogenicity. Irregular shape was seldom displayed as compared to round or oval shape in the group of $\phi \leq 20$ mm (83/210 vs. 1153/288, $p=0.003$). Parallel growth orientation was more common in masses with $\phi \leq 20$ mm (131/210 vs. 146/288, $p<0.010$). Microcalcification was rarely observed in masses with $\phi \leq 20$ mm (41/210 vs. 94/194, $p=0.001$). In the group with $\phi \leq 20$ mm, CDFI was rarely present in high grades (121/210 vs. 114/288, $p < 0.001$). Small masses with $\phi \leq 20$ mm were unlikely to show the US features of irregular shape, not-parallel growth, microcalcification and high level CDFI grades as compared to large masses. However, margin ($p=0.716$), acoustic shadowing ($p=0.152$) and echogenicity ($p=0.115$) showed no significant differences between large and small masses (table 2).

Clinicopathological parameters, tumor size and BI-RADS of breast cancer

There was significant difference between the two groups of diameter $\phi \leq 20$ mm and $\phi > 20$ mm according to the BI-RADS categories of 3, 4a, 4b, 4c and 5 ($p<0.001$). Significant difference was also found in the patients with positive axillary lymph node metastasis compared to those with negative axillary lymph node metastasis ($p=0.005$). However, no significant differences were observed in age ($p = 0.738$), histological tumor types ($p=0.973$), ER ($p=0.601$), PR ($p=0.192$), HER2 ($p=0.765$) and molecular subtype ($p=0.518$) (table 3).

Table 3. Correlation between pathology feature, tumor size and size of breast cancer.

Characteristics	BI-RADS (n=498)					P value
	3 (n=17)	4a (n=95)	4b (n=116)	4c (n=121)	5 (n=149)	
Age(years)						
<50	8	49	52	51	69	0.738
≥ 50	9	46	64	70	80	
Diameter (mm)						
$\phi \leq 20$	13	55	56	42	44	<0.001
$\phi > 20$	4	40	60	79	105	
Tumor histologic type						
ID	12	64	79	88	108	0.973
IDC and DCIS	3	23	27	22	28	
Other	2	8	10	11	13	
Axillary lymph node						
Positive	2	33	41	59	72	0.005
Negative	15	62	75	62	77	
ER						
Positive	6	36	52	58	64	0.601
Negative	11	59	64	63	85	
PR						
Positive	9	69	68	79	91	0.192
Negative	8	26	48	41	58	
HER-2						
Positive	6	34	41	42	62	0.765
Negative	11	61	75	79	87	
Molecular subtype						
Luminal A	7	51	59	52	66	0.518
Luminal B	5	21	28	26	35	
HER2-enriched	3	17	25	29	30	
TN	2	6	4	14	18	

Abbreviations: IDC=invasive ductal carcinomas; DCIS=ductal carcinoma in situ; ER=estrogen receptor; PR=progesterone receptor; HER2=human epidermal growth factor receptor 2; TN=Triple negative breast cancer. Note: ϕ means the largest diameter of tumor measured by ultrasound.

Observer agreement

Cohen's kappa statistics were used to compare the results of the interpretations of the US features between two sonographers. Inter-observer agreement showed kappa=0.74, indicating substantial agreement.

DISCUSSION

US examination is an important clinical method for diagnosing breast lesions. The BI-RADS classification has great significance for predicting the possibility of malignant breast mass^(9, 12, 22, 23). The diagnosis of BI-RADS category for breast mass mainly depends on BI-RADS lexicon of US including shape, margin, orientation, echo pattern, posterior features, calcifications and vascularity⁽⁹⁾. However, the present study found that tumor size is a significant influencing factor for the diagnosis of BI-RADS classification, and a large breast mass is more likely to be diagnosed as higher BI-RADS category than a small mass. We analyzed the US characteristics of breast cancer masses of different sizes, and found that the

US features of shape, orientation, calcifications and vascularity are significantly correlated with the mass size. This finding is valuable for improving the diagnostic performance of BI-RADS category in breast cancer mass.

Tumors with a small size are difficult to estimate by sonographers due to a limited field of view in US image, which is the main reason for misdiagnosis or missed diagnosis. Therefore, the mass size is an important factor influencing judgment and evaluation in the US diagnosis ^(4, 5). Especially, the estimation of US characteristics including shape, margin, orientation, echo pattern, posterior features, calcifications and vascularity are highly dependent on the mass size.

In this study, breast cancer with small size was more likely to be classified into the low BI-RADS category. Furthermore, the ultrasound features of round or oval shape and parallel growth orientation were more common in small breast cancer masses. The reasons may be as follows: First, there is less restriction in surrounding tissues of tumors with small mass than large mass, which make the small mass grow in regular shape. Second, the parallel distribution of different tissues of breast lead to less limitation in the parallel orientation for small mass to grow. Third, small mass with unclear boundary with neighboring tissues affects the judgments for shape, which are likely to lead to a low BI-RADS category.

Microcalcification of breast mass is a significant US characteristic for the diagnosis of breast cancer and is also a reliable diagnostic basis for BI-RADS category ⁽⁹⁾. Microcalcification more commonly appeared in large breast cancer masses in this study, which was in accordance with many reports that microcalcification is associated with the size of breast cancer mass and is more likely to present in large breast mass ⁽²⁴⁻²⁶⁾. Therefore, the mass size influences the BI-RADS category and is the main reason for small breast cancer masses being classified into the low BI-RADS category.

Color Doppler flow was less likely to show in small breast cancer masses compared to large masses in this study, which may be because cells gain nutrients simply by diffusion from surrounding tissues instead of blood vessels in a small breast cancer mass ⁽²⁷⁾. A study showed that new capillaries rarely develop in breast cancer with volume less than 2 cubic millimeters ⁽²⁸⁾. However, with the growth of the mass, the increasing needs for nutrients and oxygen trigger new vessel formation and promote the growth of the mass. Vascular endothelial growth factor (VEGF), which can promote the formation of tumor vessels, is critical for the diagnosis of breast cancer ⁽²⁹⁾. In larger tumors, VEGF is continuously active, which leads to rapid growth of blood capillaries ⁽³⁰⁾. The increasing color Doppler flow is a valuable US feature for the diagnosis of breast cancer. However, there was significant

difference between large and small masses in this study.

The limitations of this study were as follows: first, the modified method to resolve the problem of size affecting BI-RADS category should be examined in a large number of patients with breast cancer, which is our future plan; second, the size of breast cancer from US image examination may have lower accuracy than histopathology; third, this was a retrospective and small sample size study. Further study is needed to address these limitations.

CONCLUSION

This study showed that tumor size can affect the diagnosis of BI-RADS category in patients with breast cancer, and small breast cancer mass was more likely to be assessed as low BI-RADS classification. The main reason is that some ultrasound features including shape, growth orientation, microcalcification and CDFI can be influenced by tumor size. Therefore, we should consider tumor size in the evaluation of BI-RADS category.

Disclosure: The authors declare no conflict of interests.

Ethical considerations: This study was performed in line with the principles of the Declaration of Helsinki. Approval was obtained from the ethics committee of Jinshan Branch of Shanghai Sixth People's Hospital. This article does not contain any studies with animals performed by any of the authors. Verbal informed consent was obtained from all individual participants included in the study.

Author contributions: Qiang Guo: Conception, design, Acquisition, analysis and interpretation of data, drafting the manuscript; Zhiwu Dong: conception, Interpretation of data, revising the manuscript critically; Lixin Jiang: Interpretation of data, revising the manuscript critically; Lei Zhang: Acquisition, analysis and interpretation of data, revising the manuscript critically; Ziyao Li: Acquisition and interpretation of data; Dongmo Wang: Acquisition, interpretation of data.

Financial support: This work was partially supported by the National Natural Science Foundation (No. 81630048, No. 81701705) and the Project of Shanghai Municipal Health Commission (201940189).

REFERENCES

1. Mubarik S, Malik SS, Wang Z, Li C, Fawad M, Yu C (2019) Recent insights into breast cancer incidence trends among four Asian countries using age-period-cohort model. *Cancer Management and Research*, **11**: 8145-55.
2. Lin L, Yan L, Liu Y, Yuan F, Li H, Ni J (2019) Incidence and death in 29 cancer groups in 2017 and trend analysis from 1990 to 2017

- from the global burden of disease study. *Journal of Hematology & Oncology*, **12**: 96.
3. Hooley RJ, Greenberg KL, Stackhouse RM, Geisel JL, Butler RS, Philpotts LE (2012) Screening US in patients with mammographically dense breasts: initial experience with Connecticut Public Act 09-41. *Radiology*, **265**: 59-69.
 4. Berg WA, Blume JD, Cormack JB, Mendelson EB (2006) Operator dependence of physician-performed whole-breast US: lesion detection and characterization. *Radiology*, **241**: 355-65.
 5. Ko KH, Son EJ, Kim IW (2018) Accuracy of ultrasound for preoperative assessment of tumor size in patients With newly diagnosed breast cancer: Is it affected by the background parenchymal echotexture? *Journal of ultrasound in medicine: Official Journal of the American Institute of Ultrasound in Medicine*, **37**: 2621-30.
 6. Kim JY, Jung EJ, Park T, Jeong SH, Jeong CY, Ju YT, Lee YJ, Hong SC, Ha WS, Choi SK (2015) Prognostic importance of ultrasound BI-RADS classification in breast cancer patients. *Japanese Journal of Clinical Oncology*, **45**: 411-5.
 7. Mercado CL (2014) BI-RADS update. *Radiologic Clinics of North America*, **52**: 481-7.
 8. Burnside ES, Sickles EA, Bassett LW, Rubin DL, Lee CH, Ikeda DM, Mendelson EB, Wilcox PA, Butler PF, D'Orsi CJ (2009) The ACR BI-RADS experience: learning from history. *Journal of the American College of Radiology : JACR*, **6**: 851-60.
 9. D'Orsi CJ, Sickles EA, Mendelson EB, Morris EA (2013) BI-RADS Atlas, Breast Imaging Reporting and Data System. 5th ed. Reston, VA: *American College of Radiology*, 2013.
 10. Fleury EFC, Gianini AC, Marcomini K, Oliveira V (2018) The Feasibility of Classifying Breast Masses Using a Computer-Assisted Diagnosis (CAD) System Based on Ultrasound Elastography and BI-RADS Lexicon. *Technology in Cancer Research & treatment*, **17**: 1533033818763461.
 11. Hao SY, Jiang QC, Zhong WJ, Zhao XB, Yao JY, Li LJ, Luo BM, Ou B, Zhi H (2016) Ultrasound Elastography Combined With BI-RADS-US Classification System: Is It Helpful for the Diagnostic Performance of Conventional Ultrasonography? *Clinical Breast Cancer*, **16**: e33-41.
 12. Spinelli Varella MA, Teixeira da Cruz J, Rauber A, Varella IS, Fleck JF, Moreira LF (2017) Role of BI-RADS ultrasound subcategories 4A to 4C in predicting breast cancer. *Clinical Breast Cancer*, **18**: e507-e11.
 13. Lee JH, Kim SH, Kang BJ, Choi JJ, Jeong SH, Yim HW, Song BJ (2011) Role and clinical usefulness of elastography in small breast masses. *Academic Radiology*, **18**: 74-80.
 14. Kawai M, Kataoka M, Kanao S, Iima M, Onishi N, Ohashi A, Sakaguchi R, Toi M, Togashi K (2018) The Value of Lesion Size as an Adjunct to the BI-RADS-MRI 2013 Descriptors in the Diagnosis of Solitary Breast Masses. *Magnetic resonance in medical sciences. MRMS : An Official Journal of Japan Society of Magnetic Resonance in Medicine*, **17**: 203-10.
 15. Chiorean AR, Szep MB, Feier DS, Duma M, Chiorean MA, Strliciu S (2018) Impact of Strain Elastography on BI-RADS classification in small invasive lobular carcinoma. *Medical Ultrasonography*, **20**: 148-53.
 16. Adler DD, Carson PL, Rubin JM, Quinn-Reid D (1990) Doppler ultrasound color flow imaging in the study of breast cancer: preliminary findings. *Ultrasound in Medicine & Biology*, **16**: 553-9.
 17. Dobruch-Sobczak K, Piotrkowska-Wroblewska H, Roszkowska-Purska K, Nowicki A, Jakubowski W (2017) Usefulness of combined BI-RADS analysis and Nakagami statistics of ultrasound echoes in the diagnosis of breast lesions. *Clinical Radiology*, **72**: 339 e7- e15.
 18. Taskin F, Koseoglu K, Ozbas S, Erkus M, Karaman C (2012) Sonographic features of histopathologically benign solid breast lesions that have been classified as BI-RADS 4 on sonography. *Journal of Clinical Ultrasound : JCU*, **40**: 261-5.
 19. Taylor K, Britton P, O'Keeffe S, Wallis MG (2011) Quantification of the UK 5-point breast imaging classification and mapping to BI-RADS to facilitate comparison with international literature. *The British Journal of Radiology*, **84**: 1005-10.
 20. Guerra I, Algorta J, Diaz de Otazu R, Pelayo A, Farina J (2003) Immunohistochemical prognostic index for breast cancer in young women. *Molecular Pathology*, **56**: 323-7.
 21. Taucher S, Rudas M, Mader RM, Gnant M, Dubsy P, Bachleitner T, Roka S, Fitzal F, Kandioler D, Sporn E, Friedl J, Mittlböck M, Jakesz R (2003) Do we need HER-2/neu testing for all patients with primary breast carcinoma? *Cancer*, **98**: 2547-53.
 22. Bartolotta TV, Orlando A, Cantisani V, Matranga D, Ienzi R, Cirino A, Amato F, Di Vittorio ML, Midiri M, Lagalla R (2018) Focal breast lesion characterization according to the BI-RADS US lexicon: role of a computer-aided decision-making support. *La Radiologia Medica*, **123**: 498-506.
 23. Xiao X, Jiang Q, Wu H, Guan X, Qin W, Luo B (2017) Diagnosis of sub-centimetre breast lesions: combining BI-RADS-US with strain elastography and contrast-enhanced ultrasound-a preliminary study in China. *European Radiology*, **27**: 2443-50.
 24. James JJ, Evans AJ, Pinder SE, Macmillan RD, Wilson AR, Ellis IO (2003) Is the presence of mammographic comedo calcification really a prognostic factor for small screen-detected invasive breast cancers? *Clinical Radiology*, **58**: 54-62.
 25. Evans AJ, Pinder SE, James JJ, Ellis IO, Cornford E (2006) Is mammographic spiculation an independent, good prognostic factor in screening-detected invasive breast cancer? *AJR American Journal of Roentgenology*, **187**: 1377-80.
 26. Zheng K, Tan JX, Li F, Wei YX, Yin XD, Su XL, Li HY, Liu QL, Ma BL, Ou JH, Li H, Yang SS, Jiang AM, Ni Q, Liu JL, Liu JP, Zheng H, Song ZJ, Wang L, He JJ, Zou TN, Jiang J, Ren GS (2017) Relationship between mammographic calcifications and the clinicopathologic characteristics of breast cancer in Western China: a retrospective multicenter study of 7317 female patients. *Breast Cancer Research and Treatment*, **166**: 569-82.
 27. Orguc S, Basara I, Coskun T, Pekindil G (2012) Three-dimensional vascular mapping of the breast by using contrast-enhanced MRI: association of unilateral increased vascularity with ipsilateral breast cancer. *Diagnostic and Interventional Radiology*, **18**: 454-9.
 28. Folkman J (1971) Tumor angiogenesis: therapeutic implications. *The New England Journal of Medicine*, **285**: 1182-6.
 29. Lin Y, Liu F, Fan Y, Qian X, Lang R, Gu F, Gu J, Fu L (2015) Both high expression of pyruvate kinase M2 and vascular endothelial growth factor-C predicts poorer prognosis in human breast cancer. *International Journal of Clinical and Experimental Pathology*, **8**: 8028-37.
 30. Neeman M, Dafni H, Bukhari O, Braun RD, Dewhirst MW (2001) In-vivo BOLD contrast MRI mapping of subcutaneous vascular function and maturation: validation by intravital microscopy. *Magnetic Resonance in Medicine*, **45**: 887-98.