

Toxicity and cosmetic outcome in hypofractionated radiation therapy for ductal carcinoma in situ after breast-conserving surgery: a preliminary report

J. Soonthornrak¹, N. Amornwichet², K. Shotelersuk², K. Saksornchai^{2*}

¹Division of Therapeutic Radiology and Oncology, Department of Radiology, King Chulalongkorn Memorial Hospital, Thai Red Cross Society, Bangkok, Thailand

²Division of Therapeutic Radiology and Oncology, Faculty of Medicine, Chulalongkorn University, Bangkok, Thailand

► Original article

*Corresponding author:

Dr. Kitwadee, Saksornchai,

E-mail:

kathryn_oil@hotmail.com

Received: February 2021

Final revised: September 2021

Accepted: October 2021

Int. J. Radiat. Res., April 2022;
20(2): 383-387

DOI: 10.52547/ijrr.20.2.19

Keywords: DCIS, cosmesis, hypofractionation.

ABSTRACT

Background: Hypofractionation radiotherapy (HFX) following breast-conserving surgery (BCS) in ductal carcinoma in situ (DCIS) has been shown to be safe in many retrospective studies. In this paper, we report our data and assess those outcomes to support the use of HFX in DCIS. **Material and Methods:** All patients with DCIS after BCS were treated with 4250cGy in 16 fractions to whole breast with tumor bed boost 1000cGy in 4 fractions. The toxicity was evaluated using CTCAE v.5.0. On the last day of radiation (day 0) then 1 and 6 months post radiation. The cosmesis was evaluated at 6 months. **Results:** Between July 2018 and December 2019 at our center, 33 patients were analyzed with a median follow up of 7.3 months. No toxicity of more than grade2 occurred. At day 0 and 1 month after radiation, 89% and 85% of patients had grade1 dermatitis and hyperpigmentation, respectively. For induration, 33% had grade1 at day 0, 29% at 1 month, and 44.8% at 6 months. Only 3% had grade2 induration at 1 month. In addition, 67% of the subjects had grade1 pruritus and 37% had grade1 pain at day0. Radiation oncologists assessed good-to-excellent cosmesis in 93% of these patients, while the 96.6% of patients self-evaluated as good to excellent without impact on their self-confidence. **Conclusion:** This prospective trial showed that HFX can be safely used in DCIS with no more than grade2 skin toxicity and good to excellent cosmesis.

INTRODUCTION

Ductal carcinoma in situ (DCIS) is considered a pre-invasive ductal carcinoma. Currently, standard treatment for DCIS is lumpectomy followed by whole breast radiation. Radiotherapy, according to the Early Breast Cancer Trialists' Collaborative Group (EBCTCG), lowered the absolute 10-year chance of any ipsilateral breast incident by 15.2 %⁽¹⁾. The data from trials in the meta-analysis mainly used conventional fraction 5000cGy over 25 fractions to the whole breast. Recently, the use of alternative schedule using a lower total dose delivered in fewer, larger fractions (hypofractionation, HFX) has been demonstrated to have comparable local control rates and cosmetic outcomes to standard fractionation in early-stage invasive breast cancer⁽²⁻⁵⁾. However, there are only few retrospectives studies available on DCIS. A large cohort study from Canada found that, with a median follow-up of 9.2 years, when compared to conventional radiation therapy, HFX was not associated with an increased risk of local recurrence. However, this study did not report data about toxicity and cosmesis⁽⁶⁾. In a separate study, the 5 year

ipsilateral local recurrence rate was reported as 4.1% for HFX regimen, where using two consecutive clinical trials (4200Gy and 4050Gy, respectively) over 15 fractions resulted in 86% of the initial studied patients reported 91% good-to-excellent and 9% fair-to-poor cosmesis at least 2 years after treatment⁽⁷⁾. Oar *et al.* consistently reported ipsilateral recurrence rate in patients received 4220–4260 cGy in 16 fractions 7.1% and 3.6% for conventional and HFX treatment, respectively, but these were not significant different to each other. (p=0.48). Furthermore, there were no significant changes in cosmetic outcomes between conventional and HFX treatment. (p= 0.06)⁽⁸⁾.

A study from Berlin *et al.* included 107 breasts with DCIS and evaluated acute skin toxicity. The treatment in this study was HFX with concomitant boost and patients were well tolerated to this treatment⁽⁹⁾.

Our study is to assess the toxicity parameters which are of concern for patients receiving breast conserving surgery (BCS). The primary outcome was to evaluate cosmesis at 6 months after HFX treatment, while the secondary outcomes were to assess the

acute and late toxicity during the follow-up visit at the last day of treatment, 1 and 6 months after treatment.

MATERIALS AND METHODS

Patients

From July 2018 to December 2019, 33 patients in Department of Radiation Oncology at King Chulalongkorn Memorial Hospital, Bangkok, Thailand who had undergone BCS with pathological confirmed of DCIS were entered in the protocol with consent. Patients with a history of invasive or DCIS in the ipsilateral breast were excluded. The following variables were recorded: tumor size, tumor grade, surgical margin, estrogen/progesterone receptor status, menstruation status and the use of hormone therapy. The duration of follow-up was determined by the date of the final day of radiation treatment and the date of the follow-up appointment. The trial was approved by the Ethics committee (IRB number 491/61) and registered with ClinicalTrials.gov, number TCTR20191223001.

Simulation and treatment planning

Computed tomography (CT) simulation (Philips Brilliance Big Bore, Phillips Medical Systems, Cleveland, OH, USA) was done 3-4 weeks after surgery with 3-3.5 mm slice thickness in supine position. The patient laid on breast-board immobilization with both arms up. The borders of the radiation field were as follows: the superior edge was at the inferior margin of the head of clavicle. The inferior edge was 2 cm below infra-mammary fold. The medial edge was at midline of the sternum. The lateral edge was at mid-axillary line. The tumor bed was boosted by 0.5 cm expansion using the marker on the surgical scar or post-lumpectomy seroma on the CT imaging. The images were sent to the planning system for contouring (Varian Eclipse, version 15.6, Varian Medical Systems, Palo Alto, CA).

Radiation was delivered to the patient by opposed tangential photon beams on whole breast radiation (42.5 Gy in 16 fractions, 265 cGy per fraction). Patients were treated 5 fractions per week. The tumor bed boost was prescribed using 10 Gy in 4 fractions, 250 cGy per fraction. The satisfied treatment plan was selected following criteria from an American Society for Radiation Oncology (ASTRO) evidence-based guideline by minimizing the volume of tissue receiving greater than 105 % of the prescription dose⁽⁹⁾. Forward intensity- modulated radiotherapy (IMRT) using an electronic compensator was applied in all treatment plans. After whole breast irradiation, an electron beam boost was used to boost the tumor bed.

All patients were treated by different machines of The VARIAN Linear Accelerators (The Varian 21EX,

23EX, RapidArc, Clinac iX or TRUEBEAM accelerators).

Adjuvant hormonal treatment was prescribed by the medical oncologist depending on the hormonal receptor status.

All patients were followed at 1, 3 and 6 months after the treatment course, then yearly until reached 5 years.

Toxicity evaluation

All patients underwent a clinical assessment the day before irradiation and were followed weekly during the treatment and for one, three, and six months thereafter. Acute and late side effects were evaluated at day 0, 1 and 6 months after completion of the radiation treatment. The treating physician assessed toxic effects using the National Cancer Institute Common Terminology Criteria for Adverse Events (CTCAE) v5.0⁽¹⁰⁾.

Evaluation of the cosmetic outcome

Photographs were taken to assess the changes in the breast based on the size, shrinkage, and shape. The score was recorded by using the Global Breast Cosmesis score developed by the European Organization for Research and Treatment of Cancer (EORTC), as detailed by Aaronson and colleagues.⁽¹¹⁾ The overall cosmetic result was graded on a four-point scale, with 0 indicating an excellent result (treatment changes are difficult to discern), 1 indicating a good result (minimal treatment modifications only), 2 indicating a fair result (moderate treatment changes), and 3 indicating a poor result (severe treatment changes). Three radiation oncologists independently rated changes in the breast appearance (photographic), with the final accepted score reached by consensus. At the baseline, photographs were taken (post- surgery and pre-radiotherapy), on the last day of treatment and then 1 and 6 months after radiation. All of the photos were taken by a researcher in two positions: arms up above head and arms at waist. The camera was held in front of the standing patient at the level of patient's chest wall. We evaluated cosmetic outcome at 6 months.

Cosmesis self-evaluation was done by patients using 2-point scale. Score 1 was a good result and not associated with self-confidence, score 2 was a poor result that adversely affected the patient's self-confidence.

Statistical analysis

This was a phase II, prospective descriptive study in a single institution. The study protocol was approved by the Research Ethics Committee of King Chulalongkorn Memorial Hospital.

The duration of follow-up was estimated from the date of diagnosis to the date of the most recent radiation oncology department visit. Proportions are

used for categorical data, while means, medians, and ranges are used for continuous variables. We calculated sample size from giving $\alpha = 0.05$, population proportion (p) = 0.9 from prior trials showing good cosmesis and the acceptable error (d) = 0.1 to provide adequate power for the test, with 33 patients to be recruited.

$$n = \frac{z_{1-\frac{\alpha}{2}}^2 p(1-p)}{d^2}$$

RESULTS

This study enrolled a total of 33 patients who met the inclusion criteria. The median duration of follow-up was 7.3 months. The median age of the patients was 56 years (range 36-74) with 61% of the patient age ≥ 50 years old. In total, 61% of patients were postmenopausal, 39% were premenopausal. Half of patients (51%) presented with abnormal mammography. DCIS was low-grade in 36% of patients, intermediate in 64% and there was no high-grade DCIS. Median tumor size was 6 mm (range 2-33mm). Overall, 67% of patients had surgical margin ≥ 2 mm. Estrogen or progesterone receptor positive in 91% of patients with 71% received Tamoxifen. Table 1 summarizes the baseline

Table 1. Patient characteristics.

	Patients(N=33)	%
Age (Median = 56)		
< 50	13	39
≥ 50	20	61
Menopausal status		
Premenopause	13	39
Postmenopause	20	61
Presentation		
Abnormal mammography	18	55
Symptomatic	15	45
Breast volume		
< 1000cc	24	73
≥ 1000 cc	9	27
Tumor size (Mean = 9mm)		
< 2.5 cm	32	97
≥ 2.5 cm	1	3
Histology grading		
G1	12	36
G2	21	64
G3	0	0
Margin		
< 2mm	11	33
≥ 2 mm	22	67
Hormonal status		
ER/PR positive	30	91
ER/PR negative	3	9
Tamoxifen		
Yes	24	73
No	9	27

G = Grade; ER = Estrogen receptor; PR = Progesterone receptor

characteristics of the patients.

We evaluated acute effect at day 0 and 1 month post radiation. There was 80% (N=27) of patients available at one month follow up. No serious effect was noted in this study. At day 0, for dermatitis, 4%, 89% and 7% had grade 0, grade 1 and grade 2 dermatitis, respectively. There was no grade 2 in any other side effect, but grade 1 induration and pruritus was detectable in 33% and 67% of patients, respectively, and needed only topical intervention. Pain was described as grade 1 in 37% of the patients and mostly characterized as dullness in the breast, but did not need medication.

At 1 month after radiation, 85% and 7% of the 27 available patients had grade 1 or grade 2 hyperpigmentation, respectively, while for induration, 68%, 29% and 3% had grade 0, grade 1 and grade 2, respectively. No pruritus nor pain was found at 1month.

At 6 months after radiation, 87% (N=29) of patients were available for evaluation. No grade 2 hyperpigmentation was noted, but 41.37% had grade 1, while 58.6% had grade 0. For induration, 55.1% had grade 0, 44.8% were detected as grade 1. Table 2 demonstrated the acute and late toxicities of the patients.

Cosmetic outcome

Out of the initial 33 patients, 29 patients reached follow-up at 6 months. There were 4 patients lost to follow up. We used the European Organisation for Research and Treatment of Cancer (EORTC) Global Breast Cosmesis score to evaluate our patients by three radiation oncologists. An excellent result was scored for 7(24.1%) of the patients, 20(68.9%) for good result and only 2 patients (6.9%) was given a fair result. Figure 1 and 2 showed examples of patients' cosmetic results.

Table 2. Acute and late toxicities.

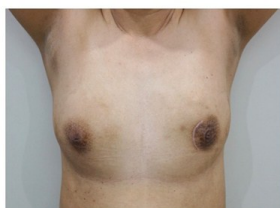
Acute toxicity grade	Grade 0 (%)	Grade 1 (%)	Grade 2 (%)
Day 0 (N= 27)			
Dermatitis	1 (4%)	24 (89%)	2 (7%)
Induration	18 (67%)	9 (33%)	0
Pruritus	9 (33%)	18 (67%)	0
Pain	17 (63%)	10 (37%)	0
At 1 month (N=27)			
Hyperpigmentation	2 (7%)	23 (86%)	2 (7%)
Induration	19 (68%)	8 (29%)	1 (3%)
Late toxicity grade	Grade 0 (%)	Grade 1 (%)	Grade 2 (%)
At 6 months (N= 29)			
Hyperpigmentation	17 (58.6%)	12 (41.37%)	0
Induration	16 (55.1%)	13 (44.8%)	0

Table 3. Retrospective data using hypofractionation in DCIS.

Trial	N	Fractionation	Follow up (yrs)	Ipsilateral breast recurrence (%)	Cosmesis
Ciervide <i>et al.</i> ⁽⁷⁾ 2012	145	42/15 40.5/15 + SIB 7.5/15	5	4.1% (no invasive)	125 patients: 91% good-to-excellent 9% fair-to-poor
Hathout <i>et al.</i> ⁽¹²⁾ 2013	440	42.5/16 + SEQ 10/4	4.4	3% (30% invasive)	x
Williamson <i>et al.</i> 2010 ⁽¹³⁾	266	50/25 42.4/16 40/16 + 12.5 boost	3.76	6% 7% 8% (4yrs)	x
Lalani <i>et al.</i> ⁽⁶⁾ 2014	1609	50/25 42.4/16	9.2	LRFS 86% 89%	x
Oar <i>et al.</i> ⁽⁸⁾ 2016	197	46-50/23-25 (N=141) 42.2-42.6/16 (N=56)	4.4	7.1% 3.6% (NS)	34.5% of patients 92.9% (Hypofraction) vs 76.9% (Conventional fraction) good- excellent EORTC score

DCIS = Ductal carcinoma in situ; SIB = Simultaneous integrated boost; SEQ = Sequential boost; LRFS = Locoregional free survival rate; NS = Not statistically significant; EORTC = European Organisation for Research and Treatment of Cancer.

• Pre-treatment



• 6 month

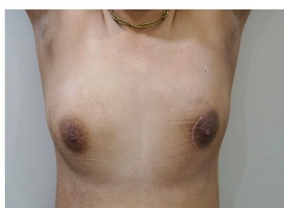
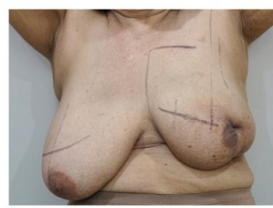


Figure 1. Example of a patient treated to the left breast with good-excellent cosmetic result.

• Pre-treatment



• 6 month

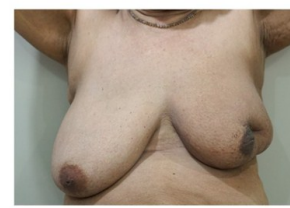


Figure 2. Example of a patient treated to the left breast with a poor cosmetic result: induration and hyperpigmented skin were detected at 6-month follow up.

DISCUSSION

With the established equivalent oncological and cosmetic outcomes between the conventional fractionation and HFx treatment in invasive breast cancer, the same question arises for DCIS of the breast. However, there is a lack of randomized data on hypofractionation in DCIS, with only a few retrospective studies available to date shown in table 3. This study was a single-institutional, prospective, single-arm trial aim to evaluate the cosmetic and toxicity outcomes of the HFx treatment of DCIS patients.

Our study found that 93-100% of patients had grade 0 to 1 acute and late toxicities. These results are

in line with the skin toxicity finding reported in other retrospective studies ^(6-8,12, 13).

In terms of cosmesis, 93% of the patients who reached the 6-month follow-up visit had excellent to good cosmetic outcomes, which is consistent with a previous report of 92.9% ⁽⁸⁾. The two patients (6.9%) who noted only a fair cosmetic result had a breast volume of more than 1,000 cc, although this reflected 33% of all the patients with a large breast volume (> 1,000 cc).

With respect to the correlation between the breast volume and skin toxicity, a previous study comparing treatment with HFx with that using

conventional fraction reported that a large breast size was associated with a lower acute grade 2 toxicity in both treatments ⁽¹³⁾. Likewise, a study from Corbin K.S., found that HFx did not result in an increase in acute skin toxicity in large-breasted women ⁽¹⁵⁾. To avoid any of late skin toxicity and worse cosmesis with HFx, it is advisable to keep the volume of hot spots and not to exceed 105-107% of the prescribed dose ^(9,16). Those two patients in our study, the hot spot was not exceed 107 % of prescribed dose. It is still inconclusive as we cannot find the associated risk factors in those grade 2 toxicity patients.

We administered a tumor bed boost in every cases, since a radiation boost for DCIS following whole breast radiotherapy is associated with a slight but statistically significant reduction in long-term intra breast tumor recurrence ⁽¹⁷⁾. With respect to the tumor bed boost, data from invasive breast cancer suggested that a tumor bed boost was associated with a more moderate to severe fibrosis in the long term follow-up ^(18,19). In 10-year follow up results of START A and B randomized controlled trials, tumor bed boost radiotherapy did not alter the effect to normal tissues ⁽⁴⁾. But the number of patients received boost dose was quite small. The latest BIG 3-07/TROG 07.01 study which is a phase 3 study using a four-armed randomized control trial, has published data on the safety and quality of life of patients treated with conventional or HFx, with or without tumor bed

boost. All patients were follow up at 2 years after the treatment. The study revealed that the cosmetic status was worse in the tumor bed boost arm ⁽²⁰⁾. Although we gave tumor bed boost to every patients, most of them had mild- moderate skin toxicity. To assess the late toxicity, a longer follow-up time is required as the events increase over time.

The limitation of this study is the short follow-up time and the small sample size, where the cosmetic and toxicity outcome would likely be better answered with a longer follow-up and larger sample size.

Currently, the results of the benefit of Hfx with or without tumor bed boost of the BIG 3-07/TROG 07.01 study are awaited ⁽²⁰⁾. Therefore, in the meantime our findings support the use of Hfx treatment for DCIS after BCS.

CONCLUSION

This prospective trial demonstrated that Hfx can be used safely in DCIS with no skin toxicity greater than grade 2 and good to excellent cosmesis.

ACKNOWLEDGMENTS

None.

Ethics considerations: Ethical approval was obtained by the Ethics committee IIRB number 491/61.

Conflict of Interest: All authors declare no conflict of interest.

Funding: none.

Authors' contributions: All authors read and approved the final manuscript.

REFERENCES

- Correa C, McGale P, Taylor C, Wang Y, Clarke M, Davies C, Peto R, Bijker N, Solin L, Darby S (2010) Overview of the randomized trials of radiotherapy in ductal carcinoma in situ of the breast. *Journal of the National Cancer Institute. Monographs*, **41**:162-77.
- Bentzen SM, Agrawal RK, Aird EG, Barrett JM, Barrett-Lee PJ, Bliss JM, Brown J, Dewar JA, Dobbs HJ, Haviland JS, Hoskin PJ (2008) The UK Standardisation of Breast Radiotherapy (START) Trial A of radiotherapy hypofractionation for treatment of early breast cancer: a randomized trial. *The Lancet Oncology*, **9**(4): 331-41.
- Triallists' Group TS (2008) The UK Standardization of Breast Radiotherapy (START) Trial B of radiotherapy hypofractionation for treatment of early breast cancer: a randomized trial. *The Lancet*, **371**(9618): 1098-1107.
- Haviland JS, Owen JR, Dewar JA, Agrawal RK, Barrett J, Barrett-Lee PJ, Dobbs HJ, Hopwood P, Lawton PA, Magee BJ, Mills J (2013) The UK Standardization of Breast Radiotherapy (START) trials of radiotherapy hypofractionation for treatment of early breast cancer: 10-year follow-up results of two randomized controlled trials. *The lancet oncology*, **14**(11): 1086-94.
- Whelan TJ, Pignol JP, Levine MN, Julian JA, MacKenzie R, Parpia S, Shelley W, Grimard L, Bowen J, Lukka H, Perera F (2010) Long-term results of hypofractionated radiation therapy for breast cancer. *New England Journal of Medicine*, **362**(6): 513-20.
- Lalani N, Paszat L, Sutradhar R, Thiruchelvam D, Nofech-Mozes S, Hanna W, Slodkowska E, Done SJ, Miller N, Youngson B, Tuck A (2014) Long-term outcomes of hypofractionation versus conventional radiation therapy after breast-conserving surgery for ductal carcinoma in situ of the breast. *Int J Radiat Oncol Biol Phys*, **90**(5): 1017-24.
- Ciervide R, Dhage S, Guth A, Shapiro RL, Axelrod DM, Roses DF, Formenti SC (2012) Five year outcome of 145 patients with ductal carcinoma in situ (DCIS) after accelerated breast radiotherapy. *International Journal of Radiation Oncology* Biology* Physics*, **83**(2): e159-64.
- Oar AJ, Boxer MM, Papadatos G, Delaney GP, Phan P, Descallar J, Duggan K, Tran K, Yap ML (2016) Hypofractionated versus conventionally fractionated radiotherapy for ductal carcinoma in situ (DCIS) of the breast. *Journal of medical imaging and radiation oncology*, **60**(3): 407-13.
- Smith BD, Bellon JR, Blitzblau R, Freedman G, Haffty B, Hahn C, Halberg F, Hoffman K, Horst K, Moran J, Patton C (2018) Radiation therapy for the whole breast: Executive summary of an American Society for Radiation Oncology (ASTRO) evidence-based guideline. *Practical Radiation Oncology*, **8**(3): 145-52.
- https://ctep.cancer.gov/protocoldevelopment/electronic_applications/docs/CTCAE_v5_Quick_Reference_5x7.pdf
- Aaronsen NK, Bartelink H, Van Dongen JA, Van Dam FS (1988) Evaluation of breast conserving therapy: clinical, methodological and psychosocial perspectives. *European Journal of Surgical Oncology*, **14**(2): 133-40.
- Hathout L, Hijal T, Théberge V, Fortin B, Vulpe H, Hogue JC, Lambert C, Bahig H, Provencher L, Vavassis P, Yassa M (2013) Hypofractionated radiation therapy for breast ductal carcinoma in situ. *Int J Radiat Oncol Biol Phys*, **87**(5): 1058-63.
- Williamson D, Dinniwell R, Fung S, Pintilie M, Done SJ, Fyles AW (2010) Local control with conventional and hypofractionated adjuvant radiotherapy after breast-conserving surgery for ductal carcinoma in-situ. *Radiotherapy and Oncology*, **95**(3): 317-20.
- Butler-Xu YS, Marietta M, Zahra A, TenNapel M, Mitchell M (2019) The effect of breast volume on toxicity using hypofractionated regimens for early stage breast cancer for patients. *Advances in Radiation Oncology*, **4**(2): 261-7.
- Corbin KS, Dorn PL, Jain SK, Al-Hallaq HA, Hasan Y, Chmura SJ (2014) Hypofractionated radiotherapy does not increase acute toxicity in large-breasted women: results from a prospectively collected series. *American Journal of Clinical Oncology*, **37**(4): 322-6.
- Smith BD, Bentzen SM, Correa CR, Hahn CA, Hardenbergh PH, Ibbott GS, McCormick B, McQueen JR, Pierce LJ, Powell SN, Recht A (2011) Fractionation for whole breast irradiation: an American Society for Radiation Oncology (ASTRO) evidence-based guideline. *Int J Radiat Oncol Biol Phys*, **81**(1):59-68.
- Moran MS, Zhao Y, Ma S, Kirova Y, Fourquet A, Chen P, Hoffman K, Hunt K, Wong J, Halasz LM, Freedman G (2017) Association of radiotherapy boost for ductal carcinoma in situ with local control after whole-breast radiotherapy. *JAMA oncology*, **3**(8):1060-8.
- Bartelink H, Maingon P, Poortmans P, Weltens C, Fourquet A, Jager J, Schinagel D, Oei B, Rodenhuis C, Horiot JC, Struikmans H (2015) Whole-breast irradiation with or without a boost for patients treated with breast-conserving surgery for early breast cancer: 20-year follow-up of a randomized phase 3 trial. *The lancet Oncology*, **16**(1):47-56.
- Poortmans PM, Collette L, Bartelink H, Struikmans H, Van den Bogaert WF, Fourquet A, Jager JJ, Hoogenraad W, Müller RP, Dubois JB, Bolla M (2008) The addition of a boost dose on the primary tumor bed after lumpectomy in breast conserving treatment for breast cancer. A summary of the results of EORTC 22881-10882 "boost versus no boost" trial. *Cancer/Radiotherapie*, **12**(6-7): 565-70.
- King MT, Link EK, Whelan TJ, Olivetto IA, Kunkler I, Westenberg AH, Gruber G, Schofield P, Chua BH, Phillips C, Bryant G (2020) Quality of life after breast-conserving therapy and adjuvant radiotherapy for non-low-risk ductal carcinoma in situ (BIG 3-07/TROG 07.01): 2-year results of a randomized, controlled, phase 3 trial. *The Lancet Oncology*, **21**(5): 685-98.

