

Combination of ultrasound with BRAF V600E gene detection for the evaluation of aggressive behavior of papillary thyroid microcarcinoma

W. Liu¹, M. Peng^{1*}, F. Jiang¹, S.Y. Wang², J.J. Liu², K. Tao², J. He²

¹Department of Ultrasound, the Second Hospital of Anhui Medical University, 230601, HeFei, Anhui, China

²Department of Head and Neck, the First Affiliated Hospital of USTC West District, 230000, HeFei, Anhui, China

ABSTRACT

► Original article

*Corresponding author:

Dr. Mei Peng,

E-mail: 714200630@qq.com

Received: March 2021

Final revised: May 2021

Accepted: June 2021

Int. J. Radiat. Res., April 2022;
20(2): 389-395

DOI: 10.52547/ijrr.20.2.20

Keywords: Papillary thyroid microcarcinoma, ultrasound, BRAFV600E, aggressive.

Background: The Japanese clinical guidelines and the 2015 American Thyroid Association Management Guidelines recommend that indolent papillary thyroid microcarcinoma (PTMC) be monitored actively and that patients with aggressive PTMC immediately undergo surgery. This study aimed to establish a stage model and provide a reference for the preoperative identification of aggressive PTMC and indolent PTMC, which might guide the treatment of PTMC. **Materials and Methods:** Risk factors for the aggressive PTMC were identified through multivariate logistic regression analysis. According to the regression coefficient, each risk factor was assigned a risk score; thereafter, a risk score (RS) model and a stage model were established. **Results:** The tumor's largest diameter > 6 mm, BRAFV600E (v-Raf murine sarcoma viral oncogene homolog B1, V600E) mutation, ultrasound-suspected lymph node metastasis, ultrasound-suspected extrathyroidal extension, and microcalcification were identified as risk factors for aggressive PTMC. The stage model was divided into three stages: stage I (RS=0.0; predictive probability for PTMC aggressiveness <10%), stage II (RS=1.0–2.3; predictive probability for PTMC aggressiveness, 10–50%), stage III (RS=3.2–7.6; predictive probability for PTMC aggressiveness, >50%). Based on the abovementioned results, stages I and II were considered to be probably indolent PTMC, and stage III was considered as probably aggressive PTMC. **Conclusion:** We suggest that patients with stages I and II PTMC be recommended for active surveillance, while those with stage III PTMC be recommended for immediate surgery.

INTRODUCTION

Thyroid cancer incidence is increasing rapidly worldwide, with the increase being predominantly of the papillary subtype (PTC [papillary thyroid carcinoma])⁽¹⁾. Nearly 50% of thyroid cancer cases consist of PTC measuring 10 mm or less in size (papillary thyroid microcarcinoma [PTMC])⁽²⁾. It has been reported that although the clinical outcome of patients with PTMC (usually considered to be an indolent tumor) is excellent, there are still a considerable number of cases related to poor prognoses, such as capsule invasion⁽³⁻⁵⁾. Based on the excellent prognosis of patients with PTMC, Kuma Hospital and Cancer Institute Hospital of the Japanese Foundation for Cancer Research first proposed the concept of indolent PTMC (cancer foci without lymph node metastasis, extrathyroidal extension [ETE], or distant metastasis) and aggressive PTMC (cancer foci with lymph node metastasis, ETE, or distant metastasis) and began a study of active surveillance for indolent PTMC instead of surgical treatment⁽⁶⁾. Regardless of active surveillance or surgical

treatment at diagnosis for PTMC, there was no significant difference in the survival rates of the two strategies⁽⁷⁻⁹⁾. Hence, the Japanese clinical guidelines and the 2015 ATA (American Thyroid Association) Management Guidelines advise that indolent PTMC was suitable for active surveillance, whereas aggressive PTMC should be treated with immediate surgery, and that surgery could be considered even after a subclinical PTMC has progressed to clinical disease^(10, 11). However, the sensitivity of conventional ultrasound in detecting cervical lymph node metastasis is low and unstable (37–84%), especially in the central region, which has a sensitivity of only 10.5–61%; this means that approximately half of the patients with metastases were incorrectly diagnosed⁽¹²⁾. Moreover, ultrasound has limited efficiency to identify pathologic ETE⁽¹³⁾. Therefore, we need to find additional reliable genetic alterations to predict the aggressive behavior of PTMC, compensating for the limited ability of ultrasound to identify aggressive PTMC.

Ras gene mutations, rearranged during transfection (RET) gene rearrangement, and the

BRAFV600E mutation are common genetic mutations in PTMC. Among them, the *BRAFV600E* mutation is the most common and has been studied extensively⁽²⁾. Most studies consider it to be an adverse factor contributing to the aggressive behavior of PTMC^(2, 14, 15). Therefore, the *BRAFV600E* was also included in this study to explore its association with the aggressive behavior of PTMC. According to previous studies, features of a preoperative malignant nodule on thyroid ultrasound, such as the tumor's largest diameter (TLD) and microcalcification (MC) were associated with the aggressive behavior of PTMC^(3, 16). In addition, some studies have suggested that an age of <45 years in men was also associated with aggressive PTMC⁽¹⁷⁾. Basic ultrasound features and basic clinical features were compared between the indolent and aggressive PTMC groups to evaluate the underlying relevance.

Previous studies were limited to an association between single ultrasound or single molecular biomarkers and central lymph node metastasis of PTMC to provide a reference to determine whether prophylactic central lymph node dissection should be performed for PTC. In this study, we combined ultrasound with *BRAFV600E* detection and other clinical features to explore the risk factors of aggressive PTMC and established a stage model for its prediction. We aim to provide a reference for preoperative evaluation, which might facilitate the selection of indolent PTMC cases that could be considered for active surveillance.

MATERIALS AND METHODS

Patients

The institutional review board approved this retrospective cross-sectional study; the need for patient approval and informed consent for the review of patient images and records was waived. However, informed consent was obtained from all the patients before each surgical procedure. Between October 2017 and April 2019, 194 pathologically confirmed cases of PTMC in the hospital were identified. The inclusion criteria were as follows: (a) cases with complete preoperative data, ultrasound reports, and *BRAFV600E* detection; and (b) in unifocal PTMC, the maximum diameter of the tumor is 3–10 mm. The exclusion criteria were as follows: (a) history of thyroid surgery; and (b) cases with another type of thyroid cancer, with the exception of PTC.

Neck ultrasound examination

Ultrasound was performed using a GE Healthcare LOGIQ E9 Agile Ultrasound (General Electric Medical Systems (China) Co., Ltd., China) with an ML6-15 linear transducer at a frequency of 6–15 MHz. The ultrasound was performed by the same Professor, a board-certified radiologist with ten years of

experience in thyroid imaging. The examination was performed with the patients in supine position with slight dorsal flexion of the head, and a cross-sectional and longitudinal scan of the thyroid gland, isthmus, and lymph nodes was performed. When suspicious malignant nodules were found, the nodule was assessed for nodular position, taller-than-wide shape, echogenicity, border, color Doppler flow signal (CDFs), TLD, cervical lymph nodes involved, capsular contact, and calcification. The nodular location was divided into four parts: the upper pole, middle part, lower pole, and isthmus. Taller-than-wide shapes were classified into two categories: > 1 and < 1. The echogenicity of the nodule was compared with that of the surrounding parenchyma and classified as marked hypoechogenicity, isoechogenicity, or hyperechogenicity. Marked hypoechogenicity was defined as a lower echogenicity of the PTMC than that of the cervical strap muscle. Isoechogenicity and hyperechogenicity were classified as other echogenicities in our study (table 1). Internal echo homogeneity was classified as heterogeneous and homogeneous. The border of the nodule was classified as either well-defined or ill-defined. The presence of CDFS was classified into two categories: no CDFS and CDFS. TLD refers to the largest diameter of a suspicious malignant nodule on three views of ultrasound. Ultrasound evaluation of cervical lymph nodes included benign cervical lymph nodes (NO ultrasound-suspected lymph node metastasis [US-LNM]) and US-LNM. US-LNM is defined as follows: a round shape structure with the absence of a hilum that presented as a hyperechoic or anechoic zone in the lymph node with peripheral vessels (mainly characterized by short-segment vessels at the periphery of the lymph nodes, which are not derived from hilum vessels or longitudinal nodal vessels). Ultrasound evaluation of capsular contact includes intrathyroidal nodules (NO ultrasound-suspected ETE [US-ETE]), indicating that the tumor is completely enveloped by the thyroid parenchyma, and US-ETE. If the suspicious malignant lesion showed 25% of its perimeter in contact with the thyroid capsule or if the echogenic capsule line in contact with the malignant lesion was lost, the lesion was classified as US-ETE. Because the nodules included in this study were malignant, coarse calcifications, rim calcification, or eggshell calcification were rare, and we considered MC as echogenic foci ≤ 1 mm; further, calcification was classified into two types—no MC and MC.

BRAF mutation analysis

Gene detection was performed using the QIAamp DNA (deoxyribonucleic acid) Formalin-Fixed and Paraffin-Embedded Tissue Kit (Qiagen corporation, German, Cat No. 56404) and the ABI 7500 real-time fluorescence quantitative polymerase chain reaction (PCR) system (Applied Biosystems, USA). PCR

primers were designed using Primer Premier 7.0 software (Premier Company of Canada, Canada) and synthesized by Shanghai Shenggong Bioengineering Co., Ltd, China. The forward primer was 5'-CATCCTAACACATTTCAAGCCCC-3', and the reverse primer was 5'-TCACACCTGCCTTAAATTGCATAC-3'. Primers for the housekeeping gene, *GAPDH* (glyceraldehyde-3-phosphate dehydrogenase), was also synthesized by Shanghai Shenggong Bioengineering Co., Ltd., China. The forward primer was 5'-AGATCCCTCCAAATCAAGTGG-3', and the reverse primer was 5'-GGCAGAGATGATGACCCTTTT-3'.

Briefly, DNA was extracted from paraffin-embedded tissue samples according to the manufacturer's instructions. The detection reagents and positive quality control products in the kit were centrifuged briefly after melting and was then placed on ice. According to the number of DNA samples (n) to be tested, the corresponding number of (n+2) PCR tubes (provided by the user, without DNase, RNase) were taken, and Taq DNA polymerase (1.5µl/tube) was added into the tubes, which were then placed on ice. Thereafter, 13.5 µl of DNA sample to be tested, negative quality control samples (the buffer for dissolving DNA was provided by the user), and positive control samples were added to the PCR tube. They were then blown and mixed thoroughly. Thereafter, the tube cover was closed, and the PCR tube was centrifuged briefly (without using a vortex oscillometer when mixing; subsequent operations were performed immediately after mixing thoroughly). The PCR tube containing the detection reagent was opened. Each DNA sample to be tested, mixed well with the previously added Taq DNA polymerase, negative quality control samples, and positive control samples, was added into different reaction holes of the detection reagent with 3µl/tube (each tube was used to detect four samples).

The PCR tubes were covered tightly and instantaneously centrifuged after the reagents were at the bottom of the tube. The reagent had settled to the bottom of the tube and was immediately placed on a thermal cycler and the assay was run on a real-time fluorescence quantitative PCR instrument. The FAM and VIC fluorescent channels were selected simultaneously. For setting the Ct value, we set the baseline and selected the fluorescence signal when "Automatic Baseline" was set. The principle of the threshold setting was that the threshold line just exceeded the highest point of the normal negative control amplification curve (no regular noise line); that is, the negative control amplification curve showed "undetermined." The test results were interpreted as follows: If a mutation site in the sample (FAM channel) was amplified and the Ct value was ≤35, the sample's mutation result was judged to be positive; if the Ct value was >38 or there was no amplification, the sample's mutation result was

negative; if 35< Ct value ≤38, the experiment was to be repeated; if the Ct value was still in this range, the sample's mutation result was suspected to be positive, which may be caused by the fluctuation of Ct value due to low mutation content.

Table 1. Features of 194 PTMC cases.

Variable	aggressive group	indolent group	χ^2 / t-test	P-value
Age (y)	39.91±9.58	45.00±11.88	-3.223	0.001*
Sex (n, %)				
Male	25(64.1%)	14(35.9%)	6.918	0.009*
Female	63(40.6%)	92(59.4%)		
Nodular location (n, %)				
Upper pole	10(50%)	10(50%)	0.691	0.708
Middle part	61(44.2%)	77(55.8%)		
Lower pole	15(51.7%)	14(48.3%)		
Isthmus part	2(28.6%)	5(71.4%)		
Taller-than-wide shape				
>1	32(45.1%)	39(54.9%)	0.004	0.951
<1	56(45.5%)	67(54.5%)		
Echogenicity				
Markedly hypoechogenicity	1(50%)	1(50%)	0.103	0.748
hypoechogenicity	81(44.8%)	100(55.2%)		
Other echogenicities	6(54.5%)	5(45.5%)		
Internal echo homogeneity				
homogeneous	42(40%)	63(60%)	2.654	0.103
heterogeneous	46(51.7%)	43(48.3%)		
Border (n, %)				
Well-defined	51(38.9%)	80(61.1%)	6.728	0.009*
Ill-defined	37(58.7%)	26(41.3%)		
CDFS (n, %)				
NO	12(30.8%)	27(69.2%)	4.193	0.041*
Yes	76(49.0%)	79(51.0%)		
TLD (n, %)				
>6 mm	58 (58.6%)	41 (41.4%)	14.267	0.000*
≤6 mm	30 (31.6%)	65 (68.4%)		
BRAFV600E (n, %)				
Mutant	76(86.4%)	75(70.8%)	6.790	0.009*
US-LNM				
Yes	41(64.1%)	23(35.9%)	13.478	0.000*
No	47(36.2%)	83(63.8%)		
US-ETE (n, %)				
YES	20 (95.2%)	1 (4.8%)	23.637	0.000*
NO	68 (39.3%)	105 (60.7%)		
MC (n, %)				
No	24 (32.4%)	50 (67.6%)	8.068	0.005*
YES	64 (53.3%)	56 (46.7%)		

*represents P -value<0.05, PTMC: Papillary thyroid microcarcinoma, CDFS: color Doppler flow signal, TLD: tumor's largest diameter, US-LNM: ultrasound-suspected lymph node metastasis, US-ETE: ultrasound-suspected extrathyroidal extension, MC: microcalcification.

Surgical approach

The choice of the surgical approach for thyroid lesions in this study was based on preoperative ultrasound presentations of thyroid nodules and cervical lymph nodes, as well as intraoperative frozen results. Each case of PTMC was a unifocal lesion in this study. All 194 patients included in this study

underwent either thyroidectomy (55/194) or lobectomy, including the isthmus (139/194). All the patients underwent central lymph node dissection. If a suspicious metastasis of the lateral cervical lymph nodes was found intraoperatively, the patients were additionally treated with lateral cervical lymph node dissection (12 cases).

Statistical analysis

Statistical analysis was performed using SPSS software (SPSS for Windows, version 20.0; IBM Corporation, Armonk, NY, USA). Categorical variables are presented as frequencies, and continuous variables are presented as the mean \pm standard deviation. For univariate analysis, if the data met normal distribution and homogeneity of variance, the difference between the two groups of continuous variables was determined using Student's t-test, and the difference between the categorical variables was compared using the chi-square test. Multivariate logistic regression analysis was performed for the statistically significant variables in the univariate analysis. Aggressiveness and indolence of PTMC, according to the pathological results, were considered as the dependent variable. Statistically significant variables in the univariate analysis as covariates and risk factors for the aggressive behavior of PTMC were screened out. Based on the risk factors, a logistic (P) formula was established, and a receiver operating characteristic curve was drawn to evaluate the predictive potential of this formula for aggressive behavior. We then established a stage model to predict the risk of aggressive PTMC. All tests were two-sided, and the threshold for statistical significance was set at $P < 0.05$.

RESULTS

Comparison between the aggressive group and the indolent group

A total of 194 patients with PTMC were enrolled in this study. Of the 194 patients, 39 patients were male, and 155 patients were female. The mean age of the 194 patients was 42.69 ± 11.19 years (range, 20–75 years), the mean TLD was 6.62 ± 1.82 mm (range, 3–10 mm). The 194 cases of PTMC included 88 cases in the aggressive group and 106 cases in the indolent group. Of the 88 cases in the aggressive group of PTMC, 71 had lymph node metastasis, five extended the thyroid capsule, 12 had lymph node metastasis and extended thyroid capsules, and none had distant metastasis.

The mean age of the aggressive group was 39.91 years, and the average age of the indolent group was 45.00 years, with the difference between the two values being statistically significant ($P = 0.001$). This showed that age was a protective factor for the aggressive behavior of PTMC. The proportion of men

in the aggressive group was 64.1%, which was higher than the proportion of women (40.6%), with the difference between the two proportions being statistically significant ($P = 0.009$).

The primary clinical features, BRAFV600E, and conventional ultrasound features of 194 PTMC cases are summarized in table 1. Nodular location, taller-than-wide shape, echogenicity, and internal echo homogeneity did not differ significantly between the aggressive and indolent groups. The aggressive group of PTMC was more prone to demonstrating the following ultrasound features: ill-defined border, CDFS, TLD > 6 mm, US-LNM, US-ETE, and MC. The BRAFV600E mutation rate in the aggressive group was 86.4%, which was higher than that in the indolent group (70.8 %), $P = 0.009$.

Regression analysis

The variables with statistically significant differences in table 1 were entered into a multivariate logistic regression analysis; the results are summarized in table 2. Age, sex, border, and CDFS were not risk factors for aggressive PTMC behavior ($P \geq 0.05$). The risk of aggressive behavior for TLD > 6 mm, BRAFV600E mutant, US-LNM (figure 1), US-ETE, MC of PTMC was higher than that of TLD ≤ 6 mm, BRAFV600E wild type, normal cervical lymph node on neck ultrasound, intrathyroidal nodule on thyroid ultrasound, no MC on thyroid ultrasound of PTMC, with odds ratio (OR) values of 2.805, 3.027, 3.479, 19.768, and 2.360, respectively ($P < 0.05$).

Table 2. Multivariate regression analysis of factors associated with aggressive behavior of PTMC.

Variable	OR (95% CI)	P-value
Age	0.969 (0.938-1.001)	0.061
Sex	2.403 (0.965-5.983)	0.060
Border	1.453 (0.673-3.141)	0.342
CDFS	1.890 (0.729-4.900)	0.190
TLD	2.805 (1.379-5.704)	0.004*
BRAFV600E	3.027 (1.246-7.349)	0.014*
US-LNM	3.479 (1.658-7.300)	0.001*
US-ETE	19.768 (2.185-178.855)	0.008*
MC	2.360 (1.127-4.942)	0.023*

*represents P -value < 0.05, PTMC : Papillary thyroid microcarcinoma, OR: odds ratio, CDFS : color Doppler flow signal, TLD: tumor's largest diameter, US-LNM: ultrasound-suspected lymph node metastasis, US-ETE: ultrasound-suspected extrathyroidal extension, MC: microcalcification.

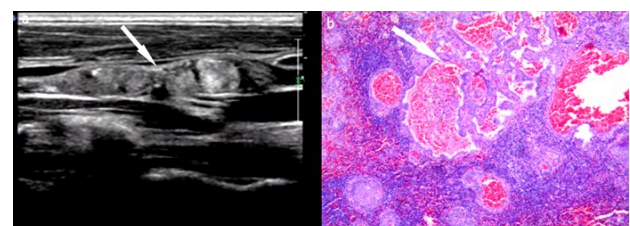


Figure 1. A 48-year-old woman with PTMC. Ultrasound hinted US-LNM: the disappearance of the hilum structure, visible clump hyperechogenicity zone and MC, no CDFS within the nodule. Pathologic report (B) showed that this PTMC nodule presented central lymph node metastasis. The magnification of the pathological picture was 4×10.

Establishment of a risk score model based on the regression analysis

Based on the above five risk factors (as shown in table 3), an RS model was established. The formula for calculating RS is as follows: $RS = 1.1 \times TLD + 1.1 \times BRAFV600E + 1.2 \times US-LNM + 3.2 \times US-ETE + 1.0 \times MC$.

(TLD: the value was defined as 1/0 if TLD >6 mm / ≤6 mm; BRAFV600E: the value was defined as 1/0 if the BRAFV600E was of the mutant/wild type; the value was defined as 1/0 if US-LNM, US-ETE, and MC was YES/NO, respectively).

Table 3. Multivariate regression analysis after adjustment.

Variable	β value	OR	P-value
TLD	1.070	2.915	0.002*
BRAFV600E	1.081	2.947	0.013*
US-LNM	1.224	3.402	0.001*
US-ETE	3.228	25.240	0.003*
MC	0.964	2.622	0.007*

*represents P -value<0.05, OR: odds ratio, TLD: tumor's largest diameter, US-LNM: ultrasound-suspected lymph node metastasis, US-ETE: ultrasound-suspected extrathyroidal extension, MC: microcalcification.

Establishment of the stage model

According to the above formula for calculating RS, the RS of 194 cases of PTMC ranged from 0–7.6 (0, 1.0, 1.1, 1.2, 2.1, 2.2, 2.3, 3.2, 3.3, 3.4, 4.3, 4.4, 5.3, 5.4, 6.4, 6.5, 6.6, 7.6, in detail) points. The stage model was divided into three stages: stage I, RS 0.0 points, with the predictive probability for the aggressiveness of PTMC being less than 10%, six cases; stage II, RS 1.0–2.3 points, with the predictive probability for the aggressiveness of PTMC being 10–50%, 103 cases; stage III, RS 3.2–7.6 points, with the predictive probability for the aggressiveness of PTMC greater than 50%, 85 cases. Based on the above results, stages I and II were considered to be probably indolent PTMCs, and stage III was considered as probably aggressive PTMC. Our retrospective histopathologic results showed 106 cases of indolent PTMC and 88 cases of aggressive PTMC. We found that the stage model in this study had satisfactory predictive accuracy compared with the retrospective pathological results.

DISCUSSION

The mean age of the aggressive group in table 1 was 39.91 ± 9.58 years, which was lower than that of the indolent group (45.00 ± 11.88 years), showing that the aggressive behavior of PTMC was more prone to rejuvenation. However, when age was entered into the multivariate logistic regression analysis, it was not a risk factor for aggressive behavior. The proportion of men in the aggressive group was 64.1%, which was higher than the 40.6% of women in the aggressive group, demonstrating that although men are less common in PTMC cases, the risk of

aggressive behavior was higher in men than in women in the presence of PTMC. However, after incorporating sex into the multivariate logistic regression analysis for the aggressive behavior of PTMC, it was not found to be a risk factor for aggressive PTMC behavior. Many studies (7, 18, 19) have reported that young age and the male sex are risk factors for cervical lymph node metastasis of PTMC. However, this study found that age and sex between the aggressive and indolent groups differed significantly in a univariate analysis, while in a multivariate logistic regression analysis for the aggressive behavior of PTMC, age and sex were not significant risk factors, possibly because there was a false or indirect association between age, sex, and aggressive behavior of PTMC. Univariate analysis of 194 PTMCs showed no significant differences between the aggressive and indolent groups of some ultrasound features, such as the nodular location, taller-than-wide shape, echogenicity, and internal echo homogeneity ($P > 0.05$). The abovementioned ultrasonic features were very similar since all cases of malignant thyroid nodules included in this study were PTMC.

This study implied that nodular borders and CDFs were not risk factors for PTMC's aggressive behavior, which is generally consistent with the results of the study by Jin *et al.* (20). The average TLD for the aggressive group was 7.22 ± 1.70 mm, which was significantly higher than the average TLD for the indolent group (6.13 ± 1.77 mm), showing that a larger TLD was more prone to aggressive behavior. Zhang *et al.* (21) performed a regression analysis on 1066 PTMC patients, and the results showed that $PTMC > 6$ mm was more likely to show cervical lymph node metastasis than $PTMC \leq 6$ mm. Therefore, this study also divided TLD into two groups: >6 mm and ≤6 mm; the proportion of >6 mm in the aggressive group PTMC was 58.6%, which was higher than the ratio of 31.6% in the indolent group PTMC, and the TLD was entered into the multivariate logistic regression analysis for aggressive behavior. The results showed that the risk of aggressive behavior of PTMC with TLD >6 mm was 2.915 times higher than that of PTMC with TLD <6 mm, which is consistent with the findings of Zhang *et al.* (21).

Gene mutations are essential triggers of tumorigenesis. In recent years, studies on the diagnostic value of molecular markers for PTMC and the influence of molecular markers on their prognosis have become relevant. For example, Bastos *et al.* (2) found that the BRAFV600E affects PTMC biological behavior through the mitogen-activated protein kinase pathway; the BRAFV600E mutation was closely related to PTMC's aggressive behavior, which could be used as a molecular marker for poor prognosis of PTMC. However, the mutation rate of the BRAFV600E was high; for instance, according to a meta-analysis report (22), the mutation rate of

BRAFV600E varies from 70.8-71.3%, while others found that the risk of *BRAFV600E*-mutant PTMC progressing to aggressive behavior was not enhanced compared to *BRAFV600E*-wild PTMC. Thus, we also performed a retrospective study to evaluate the association of the *BRAFV600E* mutation with the aggressiveness of PTMC, and found that the *BRAFV600E*-mutant PTMC had a higher risk of aggressive behavior, with an OR value of 2.947, which supported the experimental results by Bastos *et al.* (2).

Conventional ultrasound is regarded as the method of choice to evaluate lymph node disease due to its high resolution, although the sensitivity and specificity of ultrasound-identified cervical lymph node metastasis, especially central lymph node metastasis, was relatively low (23). Ultrasound has certain false negatives for the identification of benign and malignant lymph nodes; approximately 16-63% of neck lymph node metastases cannot be preoperatively spotted through cervical ultrasound (12). However, ultrasound of cervical lymph nodes can provide a reference for the evaluation of aggressive PTMC behavior. For example, US-LNM was a risk factor for PTMC behavior in our study, with an OR value of 3.402. The findings of a study by Yang *et al.* (24) also supported our findings that US-LNM is a risk factor for cervical lymph node metastasis. Moreover, the sensitivity of pathologic ETE identified by preoperative ultrasound was not too high, with some false negatives (13). However, preoperative ultrasound has a certain significance in recognizing the aggressive behavior of PTMC. This study showed that US-ETE was a risk factor, with an OR value of 25.240.

The ultrasound signs of the highly suspected malignant thyroid nodules issued by the 2015 ATA guidelines include solid hypoechoic nodules, ill-defined borders, MC, taller-than-wide shape, etc., and it retrospectively reviewed 657 classic PTCs, and multivariate logistic regression analysis showed that highly suspicious malignant ultrasound features were risk factors for PTC lymph node metastasis (16). Here, we also considered that MC within nodules on ultrasound was more prone to aggressive behavior, with an OR value of 2.622. MC on ultrasound, especially cluster MC, is the psammoma body mainly in the pathological image (19, 25), although the relationship between MC and prognosis of PTMC is unclear, one previous study suggested that psammoma bodies might signify poor prognosis such as ETE or cervical lymph node (LN) metastasis (26).

This study had some limitations. This study did not analyze the relationship between other molecular markers and poor prognosis in patients with PTMC. Therefore, in future studies, the relationship between other molecular markers and the aggressive behavior of PTMC should be analyzed, and better molecular markers evaluating the aggressiveness of PTMC should be selected. Besides, the prediction of the aggressive behavior of PTMC requires further

investigation using a large-sample, multi-center, prospective design.

CONCLUSIONS

TLD >6 mm, MC within a suspicious malignant nodule, US-LNM, US-ETE, and *BRAFV600E* mutations are risk factors for aggressive PTMC. Stages I and II were considered to be probably indolent PTMC, and stage III was considered as probably aggressive PTMC. We suggest that patients at stages I and II might be recommended for active surveillance, while those in stage III are recommended for immediate surgery. Therefore, the established stage model has a potential for clinical application.

ACKNOWLEDGMENTS

This work was supported by the Key Research and Development Plan projects in Anhui Province [grant number 201904a07020068]. We thank Professor Zhihua Zhang for his support in statistical analyses in this study.

Funding: This work was supported by the Key Research and Development Plan projects in Anhui Province [grant number 201904a07020068].

Declaration of Conflicting Interests: The authors declare that there is no conflict of interest.

Ethical considerations: The institutional review board approved this retrospective cross-sectional study; the need for patient approval and informed consent for the review of patient images and records was waived. However, informed consent was obtained from all the patients before each surgical procedure.

Author contributions: M. Peng established the design and conception of the paper. W. Liu provided the first draft of the manuscript, which was discussed and revised critically for intellectual content by M. Peng, F. Jiang, S.Y. Wang, J.J. Liu, K. Tao, J. He. All authors discussed the MATERIALS AND METHODS and CONCLUSIONS and approved the final version to be published.

REFERENCES

1. Tam AA, Ozdemir D, Ogmen BE, Faki S, Dumlu EG, Yazgan AK, *et al.* (2017) Should Multifocal Papillary Thyroid Carcinomas Classified as T1a with a Tumor Diameter Sum of 1 to 2 Centimeters Be Reclassified as T1b. *Endocrine practice : official journal of the American College of Endocrinology and the American Association of Clinical Endocrinologists*, **23**(5): 526-35.
2. Bastos AU, Oler G, Nozima BHN, Moysés RA, Cerutti JM (2015) *BRAF V600E* and decreased NIS and TPO expression are associated with aggressiveness of a subgroup of papillary thyroid microcarcinoma. *European Journal of Endocrinology*, **173**(4): 525-40.
3. Hong YR, Yan CX, Mo GQ, Luo ZY, Zhang Y, Wang Y, *et al.* (2015) Conventional US, elastography, and contrast enhanced US features

- of papillary thyroid microcarcinoma predict central compartment lymph node metastases. *Scientific Reports*, **5**: 7748.
4. Kim KJ, Kim SG, Tan J, Shen X, Viola D, Elisei R, et al. (2020) BRAF V600E status may facilitate decision-making on active surveillance of low-risk papillary thyroid microcarcinoma. *European journal of cancer : official journal for European Organization for Research and Treatment of Cancer (EORTC) [and] European Association for Cancer Research (EACR)*, **124**: 161-9.
 5. Bayadsi H, Bergman M, Sund M, Hennings J (2020) Invasiveness and Metastatic Aggressiveness in Small Differentiated Thyroid Cancers: Demography of Small Papillary Thyroid Carcinomas in the Swedish Population. *World Journal of Surgery*, **44**(2): 461-8.
 6. Sugitani I, Ito Y, Miyauchi A, Imai T, Suzuki S (2019) Active Surveillance Versus Immediate Surgery: Questionnaire Survey on the Current Treatment Strategy for Adult Patients with Low-Risk Papillary Thyroid Microcarcinoma in Japan. *Thyroid: official journal of the American Thyroid Association*, **29**(11): 1563-71.
 7. Ito Y, Miyauchi A, Kihara M, Higashiyama T, Kobayashi K, Miya A (2014) Patient age is significantly related to the progression of papillary microcarcinoma of the thyroid under observation. *Thyroid: Official Journal of the American Thyroid Association*, **24**(1): 27-34.
 8. Ito Y and Miyauchi A (2015) Nonoperative management of low-risk differentiated thyroid carcinoma. *Current Opinion in Oncology*, **27**(1): 15-20.
 9. Takami H, Ito Y, Okamoto T, Onoda N, Noguchi H, Yoshida A (2014) Revisiting the guidelines issued by the Japanese Society of Thyroid Surgeons and Japan Association of Endocrine Surgeons: a gradual move towards consensus between Japanese and western practice in the management of thyroid carcinoma. *World Journal of Surgery*, **38**(8): 2002-10.
 10. Takami H, Ito Y, Noguchi H, Yoshida A, Okamoto T (2012) Treatment of thyroid tumor: Japanese clinical guidelines 2012. Springer Science & Business Media.
 11. Haugen BR, Alexander EK, Bible KC, Doherty GM, Mandel SJ, Nikiforov YE, et al. (2016) 2015 American Thyroid Association Management Guidelines for Adult Patients with Thyroid Nodules and Differentiated Thyroid Cancer: The American Thyroid Association Guidelines Task Force on Thyroid Nodules and Differentiated Thyroid Cancer. *Thyroid: official journal of the American Thyroid Association*, **26**(1): 1-133.
 12. Park AY, Kim JA, Son EJ, Youk JH (2016) Shear-wave elastography for papillary thyroid carcinoma can improve prediction of cervical lymph node metastasis. *Annals of surgical oncology*, **23**(5): 722-9.
 13. Kwak JY, Kim EK, Youk JH, Kim MJ, Son EJ, Choi SH, et al. (2008) Extrathyroid extension of well-differentiated papillary thyroid microcarcinoma on US. *Thyroid: Official Journal of the American Thyroid Association*, **18**(6): 609-14.
 14. Lin K, Wang O, Zhang X, Dai X, Hu X, Qu J (2010) The BRAF Mutation Is Predictive of Aggressive Clinicopathological Characteristics in Papillary Thyroid Microcarcinoma. *Annals of Surgical Oncology*, **17**(12): 3294-300.
 15. Fakhruddin N, Jabbour M, Novy M, Tamim H, Bahmad H, Farhat F, et al. (2017) BRAF and NRAS Mutations in Papillary Thyroid Carcinoma and Concordance in BRAF Mutations Between Primary and Corresponding Lymph Node Metastases. *Scientific Reports*, **7**(1): 4666.
 16. Cho E, Kim EK, Moon HJ, Yoon JH, Park VY, Kwak JY (2018) High suspicion US pattern on the ATA guidelines, not cytologic diagnosis, may be a predicting marker of lymph node metastasis in patients with classical papillary thyroid carcinoma. *American Journal of Surgery*, **216**(3): 562-6.
 17. Back K, Kim JS, Kim JH, Choe JH (2019) Superior Located Papillary Thyroid Microcarcinoma is a Risk Factor for Lateral Lymph Node Metastasis. *Annals of Surgical Oncology*, **26**(12): 3992-4001.
 18. Zheng X, Peng C, Gao M, Zhi J, Hou X, Zhao J, et al. (2019) Risk factors for cervical lymph node metastasis in papillary thyroid microcarcinoma: a study of 1,587 patients. *Cancer Biology & Medicine*, **16**(1): 121-30.
 19. Jeon MJ, Chung MS, Kwon H, Kim M, Park S, Baek JH, et al. (2017) Features of papillary thyroid microcarcinoma associated with lateral cervical lymph node metastasis. *Clinical Endocrinology*, **86**(6): 845-51.
 20. Shin HJ, Kim EK, Moon HJ, Yoon JH, Han KH, Kwak JY (2014) Can increased tumoral vascularity be a quantitative predicting factor of lymph node metastasis in papillary thyroid microcarcinoma. *Endocrine*, **47**(1): 273-82.
 21. Zhang L, Wei WJ, Ji QH, Zhu YX, Wang ZY, Wang Y, et al. (2012) Risk factors for neck nodal metastasis in papillary thyroid microcarcinoma: a study of 1066 patients. *The Journal of Clinical Endocrinology and Metabolism*, **97**(4): 1250-7.
 22. Ma YJ, Deng XL, Li HQ (2015) BRAF (V(6)(0)(0)E) mutation and its association with clinicopathological features of papillary thyroid microcarcinoma: A meta-analysis. *Journal of Huazhong University of Science and Technology. Medical sciences = Hua zhong ke ji da xue xue bao. Yi xue Ying De wen ban = Huazhong keji daxue xuebao. Yixue Yingdewen Ban*, **35**(4): 591-9.
 23. Cui XW, Hocke M, Jenssen C, Ignee A, Klein S, Schreiber-Dietrich D, et al. (2014) Conventional ultrasound for lymph node evaluation, update 2013. *Zeitschrift für Gastroenterologie*, **52**(2): 212-21.
 24. Yang Y, Xia S, Ni X, Ni Z, Zhang L, Wang W, et al. (2017) MiR-324-5p assists ultrasonography in predicting lymph node metastasis of unifocal papillary thyroid microcarcinoma without extracapsular spread. *Oncotarget*, **8**(48): 83802-16.
 25. Pyo JS, Kang G, Kim DH, Park C, Kim JH, Sohn JH (2013) The prognostic relevance of psammoma bodies and ultrasonographic intratumoral calcifications in papillary thyroid carcinoma. *World Journal of Surgery*, **37**(10): 2330-5.
 26. Taki S, Terahata S, Yamashita R, Kinuya K, Nobata K, Kakuda K, et al. (2004) Thyroid calcifications. *Clinical Imaging*, **28**(5): 368-71.

