

Is it possible to diagnose COVID-19 by performing only thorax CT and clinical findings?

A. Mert* and A. Kaptanoglu

Private Yunus Emre Hospital, Istanbul, Turkey

► Original article

*Corresponding author:

Alpaslan Mert, MD.

E-mail:

alpaslanmrt@gmail.com

Received: November 2020

Final revised: July 2021

Accepted: August 2021

Int. J. Radiat. Res., April 2022;
20(2): 431-438

DOI: 10.52547/ijrr.20.2.26

Keywords: Thorax, computed tomography, COVID-19, Pneumonia, SARS-CoV-2.

ABSTRACT

Background: Coronavirus disease 2019 (COVID-19) is a pandemic and increasing rapidly as a global health emergency which is caused by SARS-CoV-2 virus. The real-time reverse transcription polymerase chain reaction test (RT-PCR test) is considered as a gold standard method for diagnosing (COVID-19). However, the test has some limitations as it is not universally available, turnaround times can be lengthy, and reported sensitivities vary. The aim of the study was to describe the imaging features of thorax computed tomography (CT) in diagnosing COVID-19. **Materials and Methods:** In this retrospective study, 36 patients were recruited from the emergency room and outpatient settings at a tertiary-care hospital, Istanbul, Turkey. Thorax CT was done and correlated with clinical findings to diagnose COVID-19. **Results:** A total of 36 of 41 patients were screened for thorax CT and were confirmed as COVID-19. There was no significant difference ($p>0.05$) between the age-distribution and gender for clinical and radiological findings. **Conclusions:** Thorax CT with clinical findings should be preferred as early diagnosis of COVID-19 and follow-up period.

INTRODUCTION

Globally, there is an increase in the number of cases of coronavirus disease-19 (COVID-19) after the World Health Organization (WHO) confirmed an intense pneumonia case of unknown cause in Wuhan, China ⁽¹⁾. This outbreak of novel severe acute respiratory syndrome coronavirus 2 (SARS-CoV-2) virus has become a pandemic and has caused health emergencies worldwide ⁽²⁾. Although SARS-CoV-2 resembles previous outbreaks such as Severe Acute Respiratory Syndrome (SARS) and Middle East Respiratory Syndrome (MERS) the genome is typically different from those viruses resulting in different clinical symptoms ^(3, 4).

Transmission of SARS-CoV-2 can occur through direct, indirect, or close contact with infected people through infected secretions such as saliva and respiratory secretions or their respiratory droplets, which are expelled when an infected person coughs, sneezes, talks or sings. ⁽⁵⁾ Elderly people, pregnant women, immunocompromised people, and people with other diseases particularly type 2 diabetes, respiratory diseases and cardiovascular diseases are at higher risk of getting COVID-19 and associated mortality ^(4, 6).

As the COVID-19 patients show symptoms similar to influenza there is a great need to detect COVID-19 early, but it remains a challenging issue for the

clinicians and the researchers to diagnose COVID-19 early ⁽⁷⁾. Imaging findings like ground glass opacity; chest X-ray (CXR) can be insufficient for the diagnosis of Covid-19 as the sensitivity is low (30-60%) and normal radiography would not exclude the disease ⁽⁸⁾. Currently, reverse transcription polymerase chain reaction (RT-PCR) technique is considered as the standard reference for diagnosing Covid-19 ⁽⁹⁾. Although the RT-PCR test for SARS-CoV-2 is very specific, its diagnostics sensitivity may vary (65-95%) Moreover, it is a time-consuming technique and turnaround can be lengthy ⁽¹⁰⁾. Since an overwhelming number of COVID-19 patients or suspected cases are referred to the hospitals, adequate testing capacity for COVID-19 is lacking worldwide ⁽¹¹⁾. Moreover, RT-PCR detection kits for SARS-CoV-2 are not only expensive but are also in short supply in many countries. In addition, it may end with false-negative readings at early stages of COVID-19 ⁽⁵⁾.

With the unfolding of coronavirus disease 2019 pandemic, radiologists all over the world thought using imaging techniques as a tool for screening or accelerating the speed of diagnosis, especially with shortage and limitation of RT-PCR tests. Initial studies showed that thorax/chest CT images confirm the diagnosis of COVID-19 in RT PCR negative samples ^(7, 12).

However, there is a lack of studies on the use of

thorax CT as a screening tool to diagnose COVID-19. Hence, this study aims to describe the use of thorax CT findings in symptomatic people for diagnosing COVID-19 in absence of immediate availability of RT-PCR test.

MATERIALS AND METHODS

Study subjects

In this retrospective study, a total of 189 subjects with COVID-19 symptoms who attended the emergency rooms or outpatient clinics, were screened using thorax CT between March 12, 2020 and May 14, 2020 at a Private Yunus Emre Hospital, Istanbul, Turkey. All the suspected cases who fulfilled the criteria of the European Centre for Disease Prevention and Control (ECDC), were recruited in this study. The inclusion criteria of ECDC for COVID-19 are as follows; if a suspected case has any one of the following symptoms: cough, fever, shortness of breath, sudden onset of anosmia, and ageusia or dysgeusia, diagnostic imaging shows radiological evidence compatible to COVID-19, detection of SARS-CoV-2 nucleic acid or antigen in a clinical specimen. In addition, close contact with a confirmed COVID-19 case or being a resident or a staff member, in a residential institution for vulnerable people where ongoing COVID-19 transmission has been confirmed 14 days prior to the onset of symptoms. A confirmed case has been defined as, if the patient meets the laboratory criteria using molecular detection for SARS-CoV-2. Patients with normal and non-infectious lung parenchyma, bacterial origin findings, were excluded from the study.

Data collection

Clinical and socio-demographic characteristics of all the study subjects were recorded from the private and national hospital information system (NHIS). Although RT-PCR test is necessary to confirm the diagnosis of COVID-19, in this study, clinical criteria were considered, as most of the private hospitals lacked RT-PCR instruments and kits. However, later the information about RT-PCR results was collected from the National Hospital Information system.

The peripheral, central and ateral ground glass opacity, crazy paving pattern, consolidation were recorded. Out of 189 cases, 148 cases were excluded as they were not diagnosed COVID 19. Hemogram, C-reactive protein (CRP), blood pressure, pulse and respiratory rate and oxygen saturation were recorded for all the 41 patients who were suspected to have COVID 19 radiologically.

Among 41 patients, 24 of them were referred to pandemic hospitals as they were considered as confirmed cases. However, out of 24 patients, 20 patients had positive results and four had negative

results of RT-PCR test for COVID-19 (figure 1). Since, the therapy (antibiotics, hydroxychloroquine, oseltamivir, favipiravir anti-viral, corticosteroids, and low-molecular-weight heparin) for COVID-19 was carried out in the pandemic hospital for the four patients, they were considered as positive for COVID-19.

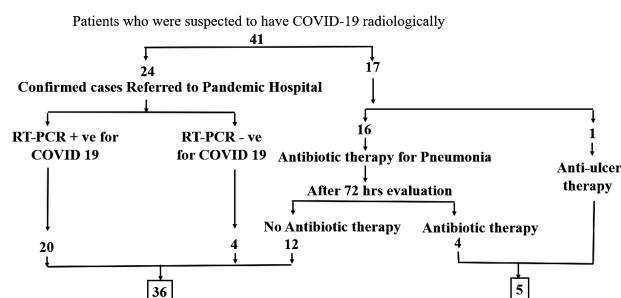


Figure 1. Flow sheet diagram of pateints recruited for the study.

Out of the remaining 17 patients of 41, 16 patients were under antibiotic therapy for Pneumonia, whereas only one patient had symptoms of cough, chest pain, low oxygen saturation, and radiological findings showed unilateral ground glass opacities and the patient was under anti-ulcer therapy.

After 72 hours under observation and treatment, clinical evaluation was conducted again on 17 patients; five patients (four had antibiotic therapy and one had anti-ulcer therapy) were excluded with pre-diagnoses of COVID-19. The rest of the 12 patients were directly referred to pandemic hospitals, as they were not treated with antibiotic therapy along with the remaining 24 patients. Hence, overall, out of 41 patients, 36 (24+12) patients were confirmed as positive for COVID-19 based on thorax CT and clinical findings, and five (2 patients were negatives and no test was conducted for 3 patients) of them were excluded based on the therapy given and the findings were compared with the 36 COVID-19 positive patients.

Statistical analysis

Statistical Package for Social Sciences (SPSS) version 22 was used to analyze the data. The categorical variables were represented as frequency and percentage and continuous variables were represented as mean \pm SD. Kolmogorov Smirnov test was applied to check the normality distribution of data. Hemogram parameters were compared for age-range (19-65 years old and above 65 years old) and gender (male and female) using independent t-tests (normally distributed data); else, the Mann-Whitney U test was used. Chi-square test was used for categorical variables when compared for gender and age-range categories, however, Fisher exact test was used when the data were limited. A two-tailed p ($p < 0.05$) value was considered statistically significant.

RESULTS

All the 189 subjects underwent thorax CT scan, 41 of them were suspected to have COVID-19 radiologically and the remaining 148 patients were excluded as they were diagnosed as COVID-19 negative. Out of 41, 36 (87.8%) patients were confirmed for COVID-19 positive, whereas five (12.2%) patients were excluded based on the therapy given for COVID-19.

Out of 189 thorax CT scans, the majority of the scans were done by family medicine specialists (46%), or chest disease specialists (37.6%) or by others (16.34%) in table 1. Among 36 COVID-19 patients, 21 were male, 15 were female, and 16 patients (44.4%) were treated by family medicine specialists. The mean age of the patients was 55.78 ± 17.88 years shown in table 2. Majority of males (76.2%) and females (93.3%) history of smoking. In addition; 61.1%, 22 patients were not in direct contact with the COVID-19 patients and 66.7% were not under any antibiotic therapy. Among the comorbidities, hypertension was common among males (52.4%) compared to females (46.7%). Overall, there were no signs of any underlying disorders among 41.7% of COVID-19 patients. The oxygen saturation, blood pressure and pulse rate were under normal among all the subjects. Lassitude and fatigue (27.8%) were the second most common symptom among all the subjects next to cough (77.8%) and none were asymptomatic. All the clinical characteristics did not differ significantly between male and female participants.

The patients were grouped into the age-band of 19-65 years comprising 24 (66.67%) patients and the second age-band of >65 years included 12 (33.33%) patients. Table 3 shows the hemogram parameters among the age-range and gender-wise categorized

subjects. The WBC, neutrophil, lymphocyte, platelet counts and C-reactive protein levels were not statistically different among the patients based on age and gender. The mean hemoglobin level was significantly ($P=0.037$) high in males compared to that in females and there was no significant difference among the age distribution.

The thorax CT findings in our study were bilateral ground glass (58.3%), unilateral ground glass (41.7%), crazy paving/reticular pattern (36.1%), consolidation (5.6%), bronchiectasis (5.6%), diffuse infiltration (2.8%), air bronchogram (2.8%), and emphysema (2.8%). The most frequent radiological distribution was seen in the right lower lobe (75%) compared to the other lobes (table 4). There was no significant difference in the frequency of radiological findings based on age and gender ($p>0.05$). When the thorax CT findings were compared between the positive and negative subjects (table 5), we observed no significant differences among all the parameters except for the radiological finding in the left lower lobe. Among the COVID-19 positive patients, there were 22 (61.1%) patients who showed left lower lobe on CT scan and none of the COVID-19 negative patients showed this radiological finding. Figure 2 shows the CT images of the patients showing the lesion distribution among a confirmed COVID-19 patient.

Table 1. Orders of 189 Thorax CT scanning were distributed as the following according to medical branches.

Specialists	n (%)
Family medicine specialists (two family physicians)	87 (46)
Chest disease specialist	71 (37.6)
Other specialists	15 (7.94)
Internal disease specialist	8 (4.2)
Emergency physicians	8 (4.2)
Total	189

Data are reported as the number of subjects with percent in parentheses.

Table 2. General characteristics of patients based on gender.

Variables		Males (n=21)	Females (n=15)	Total (n=36)	χ2/t	P value	
First examination (Branch)	Family Medicine specialist	10 (47.6)	6 (40.0)	16 (44.4)	2.983	0.394 ^b	
	Internal disease specialist	5 (23.8)	3 (20.0)	8 (22.2)			
	Chest disease specialist	6 (28.6)	4 (26.7)	10 (27.8)			
	Emergency physician	0 (0)	2 (13.3)	2 (5.6)			
Age (in years)		56.19±19.03	55.20±16.76	55.78±17.88	0.162	0.873 ^c	
Smoking habits	Active	3 (14.3)	0 (0)	3 (8.3)	2.537	0.281 ^b	
	Quitted	2 (9.5)	1 (6.7)	3 (8.3)			
	Never Smoked	16 (76.2)	14 (93.3)	30 (83.3)			
Contact history	Yes	7 (33.3)	7 (46.7)	14 (38.9)	0.655	0.418 ^b	
	No	14 (66.7)	8 (53.3)	22 (61.1)			
Response to anti-biotic	No	9 (42.9)	3 (20.0)	12 (33.3)			
	Never used	12 (57.1)	12 (80.0)	24 (66.7)			
Directly Referring to Hospitals		12 (57.1)	12 (80.0)	24 (66.7)	2.057	0.282	
Positive RT-PCR		21 (100.0)	15 (100.0)	36 (100.0)	-	-	
Comorbidities	HT	11 (52.4)	7 (46.7)	18 (50)	0.114	0.735 ^b	
	DM	5 (23.8)	6 (40.0)	11 (30.6)	1.081	0.298 ^b	
	Asthma	3 (14.3)	3 (20.0)	6 (16.7)	0.206	0.677	
	COPD	1 (4.8)	0	1 (2.8)	0.735	1.000	
	Others (CAD/Cancer/CRD/TB)	0	0	-	-	-	
	No comorbidities	9 (42.9)	6 (40.0)	15 (41.7)	0.029	0.864 ^b	
	Respiratory Distress	3 (14.3)	2 (13.3)	5 (13.9)	0.007	1.000	
Oxygen saturation	Normal	20 (95.2)	14 (93.3)	34 (94.4)	0.061	1.000	
	Low	1 (4.8)	1 (6.7)	2 (5.6)			
Blood pressure	Normal	17 (81.0)	15 (100.00)	32 (88.9)	3.24	0.125	
	High	4 (19.0)	0 (0)	4 (11.1)			
Pulse rate	Normal	20 (95.2)	14 (93.3)	34 (94.4)	0.061	1.000	
	High	1 (4.8)	1 (6.7)	2 (5.6)			
Symptoms	Cough	16 (76.2)	12 (80.0)	28 (77.8)	0.073	1.000	
	Fever	2 (9.5)	3 (20.0)	5 (13.9)	0.803	0.630	
	Lassitude and fatigue	5 (23.8)	5 (33.3)	10 (27.8)	0.396	0.529 ^b	
	Shortness of breath	3 (14.3)	2 (13.3)	5 (13.9)	0.007	1.000	
	Chill	2 (9.5)	2 (13.3)	4 (11.1)	0.129	1.000	
	Tremble	0 (0)	1 (6.7)	1 (2.8)	1.440	0.417	
	Perspiring	2 (9.5)	2 (13.3)	4 (11.1)	0.129	1.000	
	Phlegm	2 (9.5)	1 (6.7)	3 (8.3)	0.094	1.000	
	Hemoptysis	3 (14.3)	0 (0)	3 (8.3)	2.338	0.250	
	Post nasal drip	1 (4.8)	0 (0)	1 (2.8)	0.735	1.000	
	Headache	2 (9.5)	3 (20.0)	5 (13.9)	0.803	0.630	
	Chest pain	0 (0)	1 (6.7)	1 (2.8)	1.440	0.417	
	Abdominal pain	0 (0)	1 (6.7)	1 (2.8)	1.440	0.417	
	Back pain	1 (4.8)	0 (0)	1 (2.8)	0.735	1.000	
	Sore throat	1 (4.8)	2 (13.3)	3 (8.3)	0.842	0.559	
	Astroglia	3 (14.3)	2 (13.3)	5 (13.9)	0.007	1.000	
	Nausea	0 (0)	2 (13.3)	2 (5.6)	2.965	0.167	
	Vomiting	0 (0)	1 (6.7)	1 (2.8)	1.440	0.417	
		Appetite loss	1 (4.8)	3 (20.0)	4 (11.1)	2.057	0.287
		Diarrhea	1 (4.8)	1 (6.7)	2 (5.6)	0.061	1.000
Weight loss		0 (0)	1 (6.7)	1 (2.8)	1.440	0.417	
Anosmia Hiposmia		1 (4.8)	1 (6.7)	2 (5.6)	0.061	1.000	
Asymptomatic		0 (0)	0 (0)	0 (0)	-	-	

Data are reported as the number of subjects with percent in parentheses, Age is represented with Mean ± Standard Deviation. ^a Fisher exact test, ^b Chi-square test, ^c Independent t-test. HT- Hypertension, DM- Diabetes Mellitus, COPD- Chronic Obstructive Pulmonary Disease, CAD- Coronary Artery Disease, CRD, Chronic Respiratory Disease, TB- Tuberculosis.

Table 3. Hemogram characteristics of patients based on age and gender.

Hemogram	Age Groups (years)				Gender				
	19-65 (n=24)	>65 (n=12)	χ^2/t	P Value ^a	Male (n=21)	Female (n = 15)	Total	χ^2/t	P Value ^a
WBC (X10 ³ /mm ³)	6.84±2.42	7.03 ± 2.18	-0.236	0.815	6.99±2.13	6.78±2.62	6.90±2.31	0.256	0.799
Neutrophil (X10 ³ /mm ³)	4.44±1.91	4.48 ± 1.99	-0.060	0.953	4.37±1.76	4.57±2.16	4.45± 1.91	-0.298	0.768
Lymphocyte (X10 ³ /mm ³)	2.30±2.51	1.73 ± 0.91	0.767	0.524 ^b	2.46 ± 2.69	1.63±0.66	2.11± 2.12	1.161	0.328 ^b
Platelet (X10 ³ /mm ³)	213.96± 54.03	225.1±55.89	-0.576	0.568	211.81±60.25	225.57±44.86	217.67±54.12	-0.764	0.450
Hemoglobin (g/dl)	14.01 ± 1.01	13.28±1.36	1.802	0.080	14.11 ± 1.16	13.29± 1.04	13.77± 1.17	2.168	0.037*
CRP (µg/ml)	19.39 ± 21.37	29.82± 44.41	-0.960	0.750 ^b	17.49 ± 19.47	30.38 ± 41.43	22.87±30.74	-1.250	0.700 ^b

Table 4. Frequency distribution of radiological findings of the patients categorized into age and gender.

Variables		Age (in years)				Gender				
		19-65 (n = 24)	> 65(n = 12)	χ^2/t	P Value ^a	Male (n=21)	Female(n=15)	Total	χ^2/t	P Value ^a
Thorax CT Findings	Bilateral ground glass	13 (54.67)	8 (66.67)	0.514	0.721	14 (66.67)	7 (46.67)	21 (58.3)	1.440	0.230 ^b
	Unilateral ground glass	11(45.83)	4 (33.33)	0.514	0.721	7 (33.33)	8 (53.33)	15 (41.7)	1.440	0.230 ^b
	Crazy paving	9 (37.5)	4 (33.33)	0.060	1.000	10 (47.62)	3 (20)	13 (36.1)	2.893	0.159
	Consolidation	2 (8.33)	0	1.059	0.543	2 (9.52)	0	2 (5.6)	1.513	0.500
	Diffuse infiltration	1 (4.17)	0	0.514	1.000	1 (4.76)	0	1 (2.8)	0.735	1.000
	Air bronchogram	1 (4.17)	0	0.514	1.000	1 (4.76)	0	1 (2.8)	0.735	1.000
	Emphysema	0 (0)	1 (8.33)	2.057	0.333	1 (4.76)	0	1 (2.8)	0.735	1.000
	Bronchiectasis	1 (4.17)	1 (8.33)	0.265	1.000	2 (9.52)	0	2 (5.6)	1.513	0.500
	Others (Nodule presence, Vascular expansion, Pleural effusion, Reverse halo, Lymphadenopathy, Atelectasis, Cavitation, Pneumomediastinum, Mass, Interstitial involvement)	0	0	-	-	0	0	0	0	0
Location in Lobe of Lung	Peripheral location	17 (70.83)	8 (66.67)	0.065	1.000	15 (71.43)	10 (66.67)	25 (69.4)	0.094	0.760 ^b
	Central location	3 (12.5)	1 (8.33)	0.141	1.000	2 (9.52)	2 (13.33)	4 (11.1)	0.129	1.000
	Diffuse distribution	4 (16.67)	3 (25)	0.355	0.664	4 (19.05)	3 (20)	7 (19.4)	0.005	1.000
Radiological Distribution	Right lower lobe	18 (75)	9 (75)	0.000	1.000	17 (80.95)	10 (66.67)	27 (75)	0.952	0.443
	Right upper lobe	14 (58.33)	6 (50)	0.225	0.635 ^b	10 (47.6)	10 (66.67)	20 (55.6)	1.286	0.257 ^b
	Right middle lobe	13 (54.17)	6 (50)	0.056	0.813 ^b	12 (57.14)	7 (46.67)	19 (52.8)	0.385	0.535 ^b
	Left lower lobe	13 (54.17)	9 (75)	1.461	0.292	14 (66.67)	8 (53.33)	22 (61.1)	0.655	0.418 ^b
	Lingula	13 (54.17)	4 (33.33)	1.393	0.302	9 (42.86)	8 (53.33)	17 (47.2)	0.385	0.535 ^b
	Left upper lobe	11 (4.17)	4 (33.33)	0.514	0.721	8 (38.09)	7 (46.67)	15 (41.7)	0.264	0.607 ^b

Data are reported as the number of subjects with percent in parentheses, ^a Fisher's exact test, ^b Chi-square test, CT- computerized tomography.

Table 5. Clinical characteristics of the subjects compared with positive vs negative samples for Thorax CT findings.

Variables		Positive (n=36)	Negative (n=5) ‡	χ^2/t	p-value ^a
Thorax CT Findings	Bilateral ground glass	21 (58.3)	1 (20)	2.594	0.164
	Unilateral ground glass	15(41.7)	4(80)	2.594	0.164
	Crazy paving	13(36.1)	1(20)	0.567	0.645
	Consolidation	2(5.6)	1(20)	1.351	0.330
	Diffuse infiltration	1(2.8)	0(0)	0.142	1.000
	Air bronchogram	1(2.8)	1(20)	2.806	0.232
	Emphysema	1(2.8)	1(20)	0.142	1.000
	Bronchiectasis	2(5.6)	0(0)	0.292	1.000
	Others (Nodule presence, Vascular expansion, Pleural effusion, Reverse halo, Lymphadenopathy, Atelectasis, Cavitation, Pneumomediastinum, Mass, Interstitial involvement)	0(0)	0(0)	-	-
Location in Lobe of Lung	Peripheral location	25(69.4)	3(60)	0.181	0.645
	Central location	4(11.1)	1(20)	0.324	0.497
	Diffuse distribution	7(19.4)	1(20)	0.001	1.000
Radiological distribution	Right lower lobe	27(75)	4(80)	0.060	1.000
	Right middle lobe	19(52.8)	2(40)	0.287	0.663
	Right upper lobe	20(55.6)	3(60)	0.035	1.000
	Left upper lobe	15(41.7)	1(20)	0.866	0.632
	Left lower lobe	22(61.1)	0(0)	6.594	0.016*
	Lingula	17(47.2)	0(0)	4.034	0.065

Data are reported as the number of subjects with percent in parentheses. ^a Fisher's Exact test, ‡(Negatives-2, no test done-3) *p<0.05, significant.

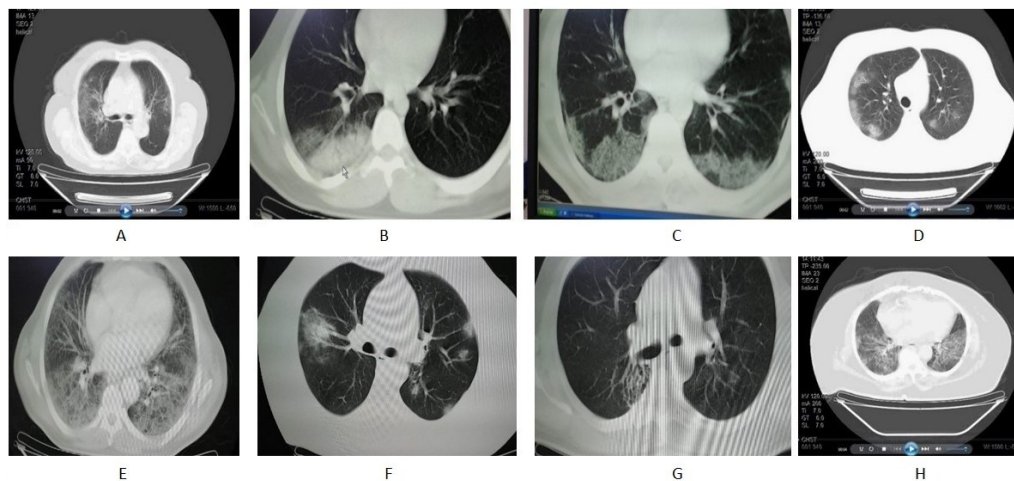


Figure 2. CT images of a COVID-19 patient. **A)** Bilateral multi lobar, subpleural, diffuse ground glass opacities in both lungs. **B)** Lesion, which was compatible with pneumonia, in the superior segment of lower lobe in the right lung. **C)** Ground glass opacities with multilobar, peripheral location in lower lobes of both lungs. **D)** Ground glass opacities with multilobar, peripheral location in both lungs. **E)** Bilateral, interstitial pattern and ground glass opacities with diffuse distribution in all segments of all lobes in both lungs. **F)** Reticular pattern and ground glass opacities with multilobar, subpleural location in both lungs. **G)** Focal ground glass opacities with multilobar, peripheral location in both lungs. “Honeycomb view” in the superior segment of the lower lobe of the right lung. **H)** Diffuse, multifocal, ground glass opacities and reticular pattern in both lungs.

DISCUSSION

Globally, as of June 09, 2020, there were 7,279,933 patients infected with COVID-19 and 412,052 were reported to have died and day by day the infection and mortality rate is increasing. The Turkish Ministry of Health established an Advisory Board on Coronavirus Research and as per its “2019-nCoV Guide”, the public hospitals, University hospitals and Private hospitals, were declared as pandemic hospitals for COVID-19 patients.

According to WHO a confirmed case is defined as a patient with RT-PCR test-proven COVID-19, irrespective of clinical signs and symptoms. Unfortunately, the sensitivity of RT-PCR tests is imperfect. Factors that can lead to a false-negative result, include poor quality of the specimen mainly due—errors while extracting the nuclide acids; collecting the specimen too early (eg, between exposure to SARS-CoV-2 and symptom onset), or late in the course of infection; and inappropriate handling/shipping of the specimen. Moreover, the RT-PCR test is that it takes some time before results are available with estimated testing times ranging from 24-48 hours.

As described above RT-PCR is the standard diagnostic method of testing for COVID-19 it has a lower sensitivity of 65-95% suggesting the probability of false negative results with RT-PCR testing. RT-PCR test is time consuming may takes around 1-2 days to give the results. Moreover, the shortage of supply test kits in many countries may not meet the needs of an ever-growing infected population.

A study has highlighted the positive rate of COVID-19 detection using RT-PCR technique in respiratory

samples to be about 30-90% (13).

The use of medical imaging tools is the second approach of COVID-19 diagnosis. Among medical imaging tools, thorax CT could be used as an alternative method, and is shown to be more sensitive in detecting COVID-19 when used in conjunction with the clinical findings (7). Thorax CT is affordable widely available, and can resolve the false-negative reports obtained from RT-PCR for the patients in early-stage (14). However, few studies reported that thorax CT imaging in COVID-19 is not specific and may overlap with other infections; organized pneumonia, influenza, drug toxicity, and connective tissue diseases show similar findings (8, 15).

The Centers for Disease Control (CDC) does not currently recommend CXR (Chest radiographs) or CT to diagnose COVID-19 and viral molecular testing remains the only specific method of diagnosis diagnosing COVID-19. Confirmation with the viral test is required, even if radiologic findings are suggestive of COVID-19. For the initial diagnostic testing for suspected COVID-19 infection, the CDC recommends testing specimens from the upper respiratory tract (nasopharyngeal and oropharyngeal swabs) or from the lower respiratory tract. Radiologists suggest thorax CT have high specificity but moderate sensitivity in differentiating COVID-19 from viral pneumonia (10).

A study reported that thorax CT had higher sensitivity (88%) for diagnosis of COVID-19 as compared with the initial RT-PCR test (59%) and this observation is compatible with our study results (87.8%) (16). In contrast, another study reported that thorax CT has low specificity in differentiating pneumonia-related lung changes due to significant overlap and found no significant differences in most

of the thorax CT image findings between COVID-19 and non-COVID-19 groups ⁽¹⁾. However, our study suggested that thorax CT could be used to screen or be used as a first-line test to diagnose COVID-19 as the findings of thorax CT with clinical findings were adequate to diagnose COVID-19 in most patients.

In the present study, we observed that the family medicine specialists and chest disease specialist were the first point of examination (83.6%) for the patients with COVID-19. However, reports COVID-19 patients being examined first by physicians in hospitals is lacking.

The treatment of most of the COVID-19 patients with mild-to-moderate symptoms was managed in an outpatient setting and only serious patients were admitted in the COVID-19 hospitals ⁽¹⁷⁾. In this study, all the patients were treated in outpatient settings.

In the present study, out of 41 patients, 36 were diagnosed as positive for COVID-19 and among the rest of the five, two were negative for COVID-19 and no RT-PCR test was conducted for the remaining 3 patients. Furthermore, out of 36 patients selected for this study, four were negative for COVID-19 twice by RT-PCR test in a pandemic hospital. However, all the four patients were acknowledged as positive for COVID-19 as they responded to anti-COVID-19 therapy in pandemic hospitals and recovered. Moreover, the radiological findings of thorax CT and clinical symptoms of these four cases had previously indicated the diagnosis of COVID-19 in outpatient settings. Hence, the findings of 36 COVID-19 patients are discussed in this study.

In our study, the mean age of the patients was 55.78±17.88 years and the two-third of them of them were under 65 years. Male patients were more (58.3%) as compared to female patients (41.7%). The present study suggests male gender can be a risk factor for COVID-19 infection. The results are in accordance with another study among Turkish population which shows that male patients were higher than female patients ^(18, 19). However, further larger studies should be conducted to confirm gender bias infection rate.

There were no significant differences in clinical presentation between male and female patients. Similarly, except for the mean hemoglobin levels which were significantly low females, hemogram profiles were normal and did not differ with respect to age and gender.

In our study, most of the patients had normal oxygen saturation levels, blood pressure and pulse rate.

Cough (77.8%), was the most common symptom among COVID-19 patients followed by lassitude and fatigue, fever, headache, arthralgia, and shortness of breath. Most of the studies had reported that cough, followed by fever and sputum is the common clinical manifestations of COVID-19 patients ^(4, 19, 20). In contrast, a study has reported that headache (70.3%),

was the most common symptom followed by loss of smell (70.2%), nasal obstruction (67.8%), cough (63.2%) and fever (45.5%) ⁽²¹⁾.

Hypertension (50%), diabetes mellitus (30.6%), asthma (16.7%) were the three leading comorbidities in the COVID 19 patients of this study and nonetheless 41.7 % did not have any comorbidity. The finding of this study is in accordance with many studies ⁽²²⁾. However, it is uncertain, whether hypertension has a causal relationship or is confounded by age along with the other comorbidities in developing COVID-19 ⁽²³⁾. Moreover, patients with both hypertension and diabetes, are more prone to develop severe diseases due to compromised immunity. Hypertension, diabetes, cardiovascular or respiratory diseases are considered as the risk factors to develop COVID-19 and are consistent with the analytical results of this study.

In order to rule out inflammation in body due to invasion of virus and possibility of systemic immune impairment, we assessed and C-reactive protein levels and hemogram in all the COVID 19 patients. All the individual components of hemogram were normal and expectedly the mean C-reactive protein level was grossly elevated. At the early stage of the disease WBC level would be usually normal or reduced ⁽⁴⁾.

Among the patients, 69.4% showed the abnormal radiological findings in the peripheral lobe of the lung. About 71.43% peripheral lobe abnormal findings were in males and 70.83% peripheral lobe findings were seen in patients aged less than 65 years. These findings were largely compatible with other studies ^(6, 10, 15). According to thorax CT imaging, the most common changes in lesion density were bilateral ground glass (58.3%) followed by Unilateral ground glass (41.7%) and crazy paving (36.7%). In CT findings, ground glass opacification was seen alone and later consolidated in the 2nd week of infection. It gradually decreased and resolved completely without any sequelae at the end of the 4th week of infection among COVID-19 patients ⁽²⁴⁾. The radiological findings of this study are mostly compatible with several studies ^(1, 10, 15).

The capture rate of health personnel including physicians and nurses was 6.8% in the hospitals throughout Turkey ⁽¹⁹⁾. Among all the 30 physicians in the hospital where this study was conducted, only one physician was found to be infected with COVID-19. The reason for such a low rate in the studied hospital is that it is not considered as a pandemic hospital for COVID-19 patients.

Apart from 36 patients, we have reported five cases (two were negative in RT-PCR and no RT-PCR test was conducted for the three subjects) with similar symptoms of COVID-19. The radiological findings of CT images show the appearance of ground glass opacity for those five patients as seen in

COVID-19 patients, and four of them were treated by antibiotic therapy and the remaining patient had gastroesophageal reflux disease and was treated with antiulcer therapy.

Study limitations

This study has certain limitations. Firstly, out of 36 COVID-19 patients, four patients were negative for RT-PCR test and since compatible with thorax CT findings, clinical symptoms for COVID-19 and recovered upon administration of COVID-19 therapy in pandemic hospitals; they were included as COVID-19 patients. The sample size of this study is small and therefore it is strongly recommended to increase the sample size to find the significant differences among the risk factors and prognostic parameters. Thirdly, all the RT-PCR test findings of COVID-19 patients were recorded from NHIS alone. The clinical symptoms for the COVID-19 patients were not traced from the beginning as a result we were unable to record the median incubation period and thus failed to classify the patients into early, moderate, or severe stages of COVID-19 based on the thorax CT findings and the clinical manifestations which would have further improved the quality of this study.

CONCLUSION

We foresee that findings of our study will encourage specialists in primary healthcare to diagnose COVID-19 using both thorax CT findings and RT-PCR tests. Moreover, thorax CT may serve as a superior screening tool to RT-PCR, particularly in the setting of resource limitation. As COVID-19 is a pandemic and the vaccine is yet to be widely available, early diagnosis of COVID-19 together isolation of patients and social distancing in the general population are the best available remedies to control the spread of COVID-19.

ACKNOWLEDGEMENTS

We would like to thank Dr. Ercan Arabaci, Dr. Zeynep Ozturk, and Dr. Ali Zaimoglu for their contribution to this work and all the participants involved in this study.

Ethical approval: The Ethical approval was obtained from the Ethics Committee of Private Yunus Emre Hospital (Ethics Committee No: 05/15/2020-35), Istanbul, Turkey. Written informed consent was obtained from all the study subjects.

Conflict of interests: The author declares that there are no conflicts of interests.

Funding: No funds received.

Authors' contributions: (AM) and (AYK) conceived this study and interpreted the results. Both authors

drafted and revised the manuscript. All the authors read and accepted the final draft.

REFERENCES

1. Zhu N, Zhang D, Wang W, Li X, Yang B, et al. (2020) A novel coronavirus from patients with pneumonia in China, 2019. *N Eng J Med*, **382**(8): 727-733.
2. Lai CC, Wang CY, Wang YH, Shun-Chung H, Wen-Chien K, Po-Ren H (2020) Global epidemiology of coronavirus disease 2019: disease incidence, daily cumulative index, mortality, and their association with country healthcare resources and economic status. *Int J Antimicrob Agents*, **55**: 105946.
3. Khailany RA, Safdar M, Ozaslan M (2020) Genomic characterization of a novel SARS-CoV-2. *Gene Reports*, **19**: 100682.
4. Huang C, Wang Y, Li X, Ren L, Zhao J, Hu Y, et al. (2020) Clinical features of patients infected with 2019 novel coronavirus in Wuhan, China. *Lancet*, **395**(10223): 497-506.
5. Chan JFW, Yuan S, Kok KH, To KK, Chu H, Yang J, et al. (2020) A familial cluster of pneumonia associated with the 2019 novel coronavirus indicating person-to-person transmission: a study of a family cluster. *Lancet*, **395**(10223): 514-523.
6. Zhou F, Yu T, Du R, Fan G, Liu Y, Liu Z, et al. (2020) Clinical course and risk factors for mortality of adult inpatients with COVID-19 in Wuhan, China: a retrospective cohort study. *Lancet*, **395**(10229): 1054-1062.
7. Xie X, Zhong Z, Zhao W, Zheng C, Wang F, Liu J (2020) Chest CT for typical 2019-nCoV pneumonia: relationship to negative RT-PCR testing. *Radiology*, **200343**.
8. Gezer NS (2020) How to Deal with COVID-19 Pandemic: A Radiologic Approach. *Turk Thorax J*, **21**(3): 219-220.
9. Corman VM, Landt O, Kaiser M, Molenkamp R, Meijer A, Chu DK, et al. (2020) Detection of 2019 novel coronavirus (2019-nCoV) by real-time RT-PCR. *Eurosurveillance*, **25**(3): 2000045.
10. Bai HX, Hsieh B, Xiong Z, Halsey K, Choi JW, Tran TM, et al. (2020) Performance of radiologists in differentiating COVID-19 from viral pneumonia on chest CT. *Radiology*, **200823**.
11. Rothan HA and Byrareddy SN (2020) The epidemiology and pathogenesis of coronavirus disease (COVID-19) outbreak. *J Autoimmunity*, **109**: 102433.
12. Lei J, Li J, Li X, Qi X (2020) CT imaging of the 2019 novel coronavirus (2019-nCoV) pneumonia. *Radiology*, **295**(1): 18.
13. Yang Y, Yang M, Shen C, Wang F, Wang Z, Li J, et al. (2020) Laboratory diagnosis and monitoring the viral shedding of 2019-nCoV infections. *MedRxiv*.
14. Young D, Tatarian L, Mujtaba G (2020) Chest CT versus RT-PCR for Diagnostic Accuracy of COVID-19 Detection: A Meta-Analysis. *J Vasc Med Surg*, **8**: 3.
15. Sun Z, Zhang N, Li Y, Xu X (2020) A systematic review of chest imaging findings in COVID-19. *Quant Imag Med Surg*, **10**(5): 1058-1079.
16. Ai T, Yang Z, Hou H, Zhan C, Chen C, Lv W, et al. (2020) Correlation of chest CT and RT-PCR testing in coronavirus disease 2019 (COVID-19) in China: a report of 1014 cases. *Radiology*, **296**(2): E32-E40.
17. Lapostolle F, Schneider E, Vianu I, Dollet G, Roche B, Berdah J, et al. (2020) Clinical features of 1487 COVID-19 patients with outpatient management in the Greater Paris: the COVID-call study. *Int Emerg Med*, **15**(5): 813-817.
18. Myers LC, Parodi SM, Escobar GJ, Liu VX (2020) Characteristics of hospitalized adults with COVID-19 in an integrated health care system in California. *JAMA*, **323**(21): 2195-2198.
19. Goyal P, Choi JJ, Pinheiro LC, Schenck EJ, Chen R, Jabri A, et al. (2020) Clinical characteristics of Covid-19 in New York city. *N Eng J Med*, **382**(24): 2372-2374.
20. Ozalp M, Demir O, Akbas H, Kaya E, Celik C, Osmanagaoglu MA (2020) Effect of COVID-19 pandemic process on prenatal diagnostic procedures. *J Maternal-Fetal Neonatal Med*, **34**(23): 3952-3957.
21. Lechien JR, Chiesa-Estomba CM, Place S, Van Laethem Y, Cabaraux P, Mat Q, et al. (2020) Clinical and epidemiological characteristics of 1420 European patients with mild-to-moderate coronavirus. *J Int Med*, **288**(3): 335-344.
22. Guan WJ, Ni ZY, Hu Y, Liang WH, Ou CQ, He JX, et al. (2020) Clinical characteristics of coronavirus disease 2019 in China. *N Eng J Med*, **382**(18): 1708-1720.
23. Schiffrin EL, Flack JM, Ito S, Muntner P, Webb RC (2020) Hypertension and COVID-19. *Am J Hypertension*, **33**(5): 373-374.
24. Gündüz Y, Öztürk MH, Tomak Y (2020) The usual course of thorax CT findings of COVID-19 infection and when to perform control thorax CT scan. *Turk J Med Sci*, **50**(4): 684-686.