

Computed tomography and clinical features of Ewing's sarcoma/primary neuroectodermal tumors of the kidney: A case report and literature review

X. Hu^{1,2#}, C. Peng^{1,2#}, C. Yang¹, J. Zheng¹, P. Wang^{1*}, J. Cai^{1*}

¹Department of Nuclear Medicine, Affiliated hospital of Zunyi Medical University, Zunyi 563003, Guizhou Province, China

²Zunyi medical university, Zunyi 563003, Guizhou Province, China

► Case report

*Corresponding authors:

Jiong Cai, Ph.D.,
Pan Wang, Ms.C.,

E-mail:

jjongcai@sina.com,
1298178828@qq.com

Received: October 2020

Final revised: July 2021

Accepted: August 2021

Int. J. Radiat. Res., April 2022;
20(2): 511-515

DOI: 10.52547/ijrr.20.2.37

#These authors contributed equally to this work.

Keywords: Kidney, Ewing's sarcoma, Primary neuroectodermal neoplasm, Case report, CT (computed tomography).

INTRODUCTION

Both Ewing's sarcoma and primary neuroectodermal tumors (EWs and PNETs) share the same genetic and histological characteristics, and are currently referred to collectively as EWs/PNETs⁽¹⁾. EWs/PNET is a small round cell malignant tumor originating from neural crest cells, which has the potential of multidirectional differentiation to neurons, glia and interstitial tissues, and is likely to lead to local recurrence and distant metastasis. EWs/PNET is most commonly found in bone and soft tissue, while primary renal EWs/PNET is rare, accounting for <1% of all renal tumors⁽²⁾. Renal EWs/PNET is typically solitary and usually originates from the renal medulla or renal pelvis. EWs/PNET is more common in young people, the median age of onset is about 30 years, and the incidence of EWs/PNET is higher in males than in females⁽³⁾. Given the highly invasive nature, EWs/PNET is susceptible to cystic degeneration, necrosis, and intratumoral bleeding. To

ABSTRACT

Background: Ewing's sarcoma/primary neuroectodermal tumors (EWs/PNETs) originating in the kidney have been rarely reported. To date, EWs/PNETs have not been demonstrated to have specific clinical characteristics and imaging findings. **Case Presentation:** A 13-year-old boy was admitted to the hospital with abdominal pain following minor trauma. The patient underwent CT examination on the doctor's recommendation, which revealed contusion of the left kidney and the possibility of a space-occupying lesion in the lower pole of the left kidney. Hence, laparotomy was performed at our hospital, followed by excision of the left kidney, tumor detection and removal of hematoma. The pathological diagnosis was left kidney EWs/PNET with hemorrhagic infarction. Postoperatively, the patient did not receive radiotherapy or chemotherapy. After three months, the patient returned to the hospital for Positron Emission Topography (PET)/CT examination, and no obvious signs of tumor recurrence and metastasis were found all over the body. To date, the patient has been followed-up for 15 months, and remains alive and healthy. **Conclusion:** EWs/PNETs are highly invasive tumors, with frequent distant metastasis at diagnosis. Hence, early diagnosis and surgical removal of tumor tissue is critical for the prognosis of patients. CT can be used as the primary auxiliary examination of primary renal EWs/PNET. Cystic necrosis is found in the tumor tissue on the CT image. Moreover, cystic necrosis located around the tumor and septal enhancement are observed on the CT enhanced scan, which is helpful for the diagnosis of primary renal EWs/PNET.

date, fewer than 160 cases of renal EWs/PNET have been reported in the literature⁽⁴⁾, and even fewer cases have complete CT data. Herein, we reported a case and conducted a systematic review of published literature, in order to summarize the clinical features and CT manifestations of renal EWs/PNET.

Case presentation

Patient information: The patient, a 13-year-old male, had abdominal pain due to minor trauma and was treated with intravenous fluids after being diagnosed as a renal contusion at a local hospital. After about a week of treatment, the patient's symptoms did not improve significantly, and then the patient was transferred to the department of urology at our hospital. The family denied any history of serious illness. **Physical examination:** The patient was conscious and responsive, without abdominal pain, abdominal distention, wheezing, shortness of breath or cyanosis, and without any positive signs of fever, convulsions, etc. He had regular breathing, no skin

bleeding points, and no superficial lymph nodes.

Auxiliary examination: The patient underwent non-enhanced CT (GE, USA, 16 slice spiral CT) scan and enhanced scan of the abdomen (figure 1), indicating left kidney contusion and laceration, and the possibility of tumor in the lower end of the left kidney could not be excluded. The blood routine examination indicated that the blood sodium and creatine kinase values decreased.

The process of diagnosis and treatment: The patient was admitted to the urological department with renal contusion and treated with anti-inflammatory, antiemetic, cimetidine gastric nursing, hemostasis and fluid rehydration. After one week of treatment, the patient became increasingly mentally worse, pale, and developed vomiting and intense left abdominal pain. The clinician suspected left kidney blastoma with left kidney contusion and rebleeding. Therefore, surgical treatment was planned. Subsequently, the blood vessels of the left renal pedicle were excised under general anesthesia, the left kidney and tumor tissue were removed, and hemostasis was performed. A large amount of gelatin sponge was filled in the left renal fossa, and a retroperitoneal negative pressure drainage tube was placed to seal the retroperitoneal lateral surface. The frozen tumor tissue was sent to the pathology department during the operation, and the pathological results indicated that the tumor was malignant. Radical nephrectomy was performed immediately to remove the left renal pedicle vessel, the left kidney and the tumor tissue.

Histopathological examination: Figure 2 postoperative Hematoxylin-Eosin staining revealed a fish-like mass of grayish-brown, crushed tissue. Immunohistochemistry (Immunohistochemical reagents include Vimentin, CD56, CD99, Bcl-2, CD57, CgA, CK, CK7, Desmin, EMA, LCA, NSE, S100, SMA, STAT6, Syn, WT-1, CD34 antibodies. All reagents were purchased from Fuzhou MXB Biotechnology Co., Ltd., China.), showed that the tumor cells were positive for Vimentin, CD56, CD99, Bcl-2, CD57, CgA, CK, CK7, Desmin, EMA, LCA, NSE, S100, etc. Based on the above microscopic features and immunohistochemical results of the pathological tissue, the patient was diagnosed as left renal extraosseous EWs/PNET (III period). No tumor involvement was found in the broken end of the ureter, perirenal fat and blood vessels, and renal rupture hemorrhage was associated with infarction. To further understand whether the patient had other distant metastases and develop a treatment plan, the patient underwent a whole-body 18F-fluorodeoxyglucose (18F-FDG) PET/CT (Siemens, Biography MCT, Germany) imaging, which indicated no obvious signs of tumor metastasis. Fifteen days after surgery, the patient received vincristine + daunorubicin+clodensine phosphate (VDC) and deoxy daunorubicin + etoposide (IE) regimen chemotherapy for three

months.

Follow-up and outcomes: To date, the patient has been followed-up for 15 months, with regular CT or PET/CT review and no recurrence or metastasis was observed. The patient's written informed consent was obtained for the publication of this case report and related pictures.

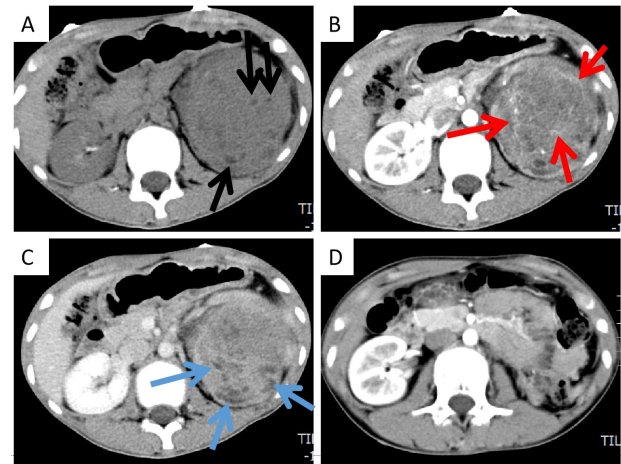


Figure 1. A. CT scan revealed a large soft tissue mass with uneven density in the left renal region, and nodules and patchy low-density shadows (black arrows). B. In the cortical stage of enhanced scanning, the lesion was slightly inhomogeneous in enhancement, and the septom-like enhancement shadow was visible in it (red arrow). C. Contrast enhanced CT in the medullary phase of the lesion continued to non-uniform enhancement, the tumor surrounding a number of small nodular cystic lesions with no enhancement. (black arrow). D. After nephrectomy, the left renal fossa was occupied by intestinal tissue.

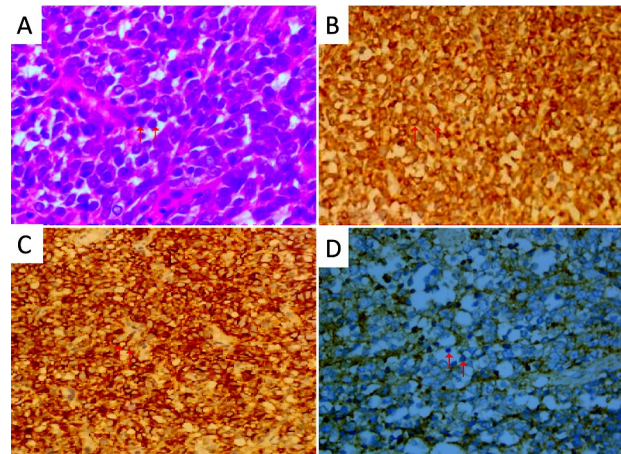


Figure 2. A. Hematoxylin and eosin staining, 200x magnification, the tumor is mainly composed of primitive small round cells with dense nuclei and relatively uniform morphology (red arrows). B. Immunohistochemical staining of tumor cells Bcl-2 was positive (red arrows). C. Immunohistochemical staining of CD56 was positive (red arrows). D. Vimentin immunohistochemical staining was positive (red arrows).

The PubMed, Embase, and Cochrane Library databases were searched for English-language case reports and case series on renal EWs/PNET

published between 1 January 2000 and 1 July 2020. The following keywords (kidney OR renal) AND (Ewing sarcoma OR Ewing's sarcoma OR primordial neuroectodermal tumor) were used for retrieval. A total of 23 patients with renal EWs/PNET in 22 full-text literatures with CT examination data were

included for analysis. The first author and references were recorded for each case, as well as the patient's age, gender, tumor size, weight, affected side, symptoms, CT image characteristics, follow-up results and treatment, as detailed in table 1.

Table 1. Clinical features of renal EWs/PNET from the literature (Including the one we reported on).

	First author	Sex/Age	MD (cm)/Side	UN-CT	CE-CT	clinical symptoms	Follow-up (month)	Treatment
				D/Ca/N/PH	ED/SE/VI			
1	Zhang ⁽⁴⁾	M/18	9.0/L	In/N/Y/Y	EE/Y/Y	Hematuria	12 (0)	S+ R+C
2	Yoshihara ⁽²⁾	F/14	10.0/R	In/N/Y/Y	-/-/Y	abdominal pain	70(0)	S+C
3	Tripathy ⁽⁵⁾	M/28	-/L	In/Y/Y/N	MoE/Y/Y	abdominal pain	-	S
4	Suzuki ⁽⁶⁾	F/45	12.0/R	Ho/N/Y/N	MiE/N/N	Abdominal pain	12(0)	S
5	Saxena ⁽⁷⁾	F/26	18/R	In/N/Y/Y	-/-/N	abdominal discomfort	5(1)	C
6	Sadiq ⁽⁸⁾	F/14	8.8/R	In/N/Y/Y	MoE/N/Y	abdominal pain	90(1)	S+ R+C
7	Richey ⁽⁹⁾	M/50	15.9/R	In/N/Y/Y	EE/Y/N	bdominal pain	96(0)	C
8	Ozturk ⁽¹⁰⁾	F/38	6.0/L	In/Y/Y/N	EE/Y/N	serendipity	72(0)	S+C
9	Kenji ⁽¹¹⁾	M/21	-/R	In/N/Y/Y	MoE/N/Y	Abdominal pain	27 (0)	S+C
10	Moustafellos ⁽¹²⁾	M/32	4.3/R	In/N/Y/Y	-/-/-	bdominal pain	30(0)	S+C
11	Manescu ⁽¹³⁾	F/40	7.0/L	In/N/Y/Y	-/-/-	Abdominal pain	27(0)	S+C
12	Maeda ⁽¹⁴⁾	F/6	5.0/R	In/N/Y/Y	-/-/N	Abdominal pain	90(0)	S+C
13	Li ⁽¹⁵⁾	M/19	12.0/R	In/N/Y/Y	EE/Y/Y	bdominal pain	-	-
14	Li ⁽¹⁵⁾	M/43	12.0/L	In/N/Y/N	MoE/Y/Y	pain+ mass	-	-
15	Kumar ⁽¹⁶⁾	F/35	11.2/R	In/Y/Y/N	EE/N/Y	hematuria	2(1)	C
16	Kang ⁽¹⁷⁾	M/34	17.5/L	In/N/Y/N	-/-/N	bdominal pain	10(1)	C+R
17	Hakky ⁽¹⁸⁾	M/33	5.8/L	In/N/Y/N	-/-/N	bdominal pain	12(0)	S
18	Funahashi ⁽²⁹⁾	F/42	7.2/R	In/N/Y/N	-/-/-	abdominal pain	19(1)	S+C
19	Fergany ⁽²⁰⁾	M/31	12.0/R	In/N/Y/N	MoE/Y/N	hematuria	24(0)	S+C
20	Ding ⁽²¹⁾	F/21	15.0/L	In/N/Y/N	MoE/Y/Y	pain+ mass	15(1)	S+C
21	Bontoux ⁽²²⁾	M/45	13.0/R	In/N/Y/Y	-/-/N	Pain+hematuria	6(0)	S+C
22	Alghamdi ⁽²³⁾	F/15	25.0/L	In/N/Y/N	MoE/Y/N	pain+ mass	18(0)	S+C
23	Alasmari ⁽²⁴⁾	F/15	16.0/L	In/N/Y/N	EE/Y/N	abdominal pain	-	S+ R+C
24	present case	M/13	12.8/	In/N/Y/Y	EE/Y/N	hematuria	25(0)	S+C

Notes. M: male; F:female; Y:yes; N: not; L: left; R:right; MD: maximum diameter; UN-CT:Unenhanced computed tomography; CE-CT: Contrast-enhanced computed tomography; D: Density; Ca: calcification; N: Necrosis; PH: Perirenal hematoma; ED: Enhance degree; SE: Septa-like enhancement; VI: Veins invaded; In: Inhomogeneous; Ho: Homogenous; EE: Evident enhancement; MoE: Moderate enhancement; MiE: Mild enhancement; S: Surgery; R: radiotherapy; C: Chemotherapy.

The literature showed that EWs/PNET occurs most commonly in bone but less frequently in kidney. The scatter plots of gender, diseased side and age of the 24 renal EWs/PNET patients (including our case) are shown in figure 3. The cases included 12 males and 12 females, with the age range of 6-50 years, and the median age was about 28 years, which was consistent with literature reports^(4,18,25). There was no significant difference between the prevalence in left and right kidneys. Most of the patients visited the hospital with abdominal pain, but a few patients presented with hematuria or abdominal mass, which can occur concomitantly, however, any of these clinical symptoms indicate that the disease has entered a progressive stage. Some reports^(4,6) suggested that the pathogenesis of EWs/PNET may be related to the chromosomal translocation of EWSR1, which has not yet been confirmed.

Imaging examination plays an important role in the detection of renal space-occupying lesions, especially CT, which can clearly show the origin, tumor morphology, and size and invasion scope of lesions. The CT data of our included cases showed that the CT signs of renal EWs share some common

features: it usually presented as a single, large, fuzzy boundary and irregular soft tissue mass in the kidney. The mean value of the maximum tumor diameter was 11.6 cm (the minimum was 4.3 cm, the maximum was 25.0 cm). EWs/PNET is susceptible to necrosis, cystic change, bleeding, and often uneven density. Among the 24 patients, only one patient had relatively uniform lesion density and cystic appearance, and a few solid components were found in the cyst wall. In the remaining cases, the density was uneven due to cystic degeneration and/or necrosis within the tumor. The density of the solid portion of the mass was equal to or slightly less than that of the renal parenchyma, and the density of necrotic and cystic components was low. Calcification occurred in tumor tissues of a small proportion of renal EWs/PNET patients (3 of 24 patients), and tumor rupture and hemorrhage occurred in 50% (12/24) of the lesions. Because of the highly aggressive nature of the tumor, one-third of the patients (8 out of 24) were diagnosed with inferior vena cava or renal vein thrombosis. The enhancement degree of the substantive part of EWs/PNET in dynamic enhanced scanning was varied, most of which presented moderate to progressive

enhancement. Some researchers ⁽²⁶⁾ believed that multiple irregular septum-like enhancement and delayed enhancement in lesions are characteristic manifestations of EWs/PNET and can be used to differentiate from other renal tumors. Contrast-enhanced CT scan was performed in 15 of the 24 patients enrolled, and septal enhancement was found in 70% of the lesions, which was consistent with the above literature reports. In younger patients, EWs/PNET needs to be distinguished from nephroblastoma, the most common tumor in children. The CT image of the latter also shows a large mass with equal or slightly lower density, necrosis, cystic change and hemorrhage. In older patients, renal clear cell carcinoma (RCC) should also be considered as one of the differential diagnoses of EWs/PNET, which can also present the above CT signs, but with a higher frequency of calcification. Most RCCs were significantly enhanced at the cortical phase of contrast-enhanced CT, while the medullary stage and delayed scanning of the lesion rapidly reduce the enhancement degree, presenting a typical "fast in and out". However, the enhancement degree of renal EWs/PNET in cortical and medullary stages was much lower than that of RCC.

At present, the diagnosis of EWs/PNET is mainly based on pathology and immunohistochemistry. Microscopy indicates that the tumor is mainly composed of primitive small round cells, with dense staining, relatively consistent morphology, and frequent mitosis. Immunohistochemistry showed that tumor cells consistently and diffusely expressed CD99, and expressed Vimentin, Syn and NSE to varying degrees, while CgA and s-100 were often negative ^(7, 22). The pathological and immunohistochemical results of this patient were consistent with those reported in the literature.

There is no unified treatment guideline for renal EWs/PNET, and the treatment principles of other renal malignancies are mainly referred to at present. Surgical resection of tumor tissue is the main therapeutic measure for renal EWs/PNET, and adjuvant therapy such as radiotherapy and chemotherapy can be chosen after surgery according to the patient's condition ^(8,9,11). Among the enrolled patients, 82% (n=22) underwent surgery, and only four patients had to undergo chemotherapy and/or radiotherapy due to multiple distant metastases. The commonly used chemotherapy drugs of EWs/PNET include vincristine, cyclophosphamide and doxorubicin, etc., which can be changed according to the patient's tolerance ^(2,7,11,18). The prognosis of renal EWs/PNET reported in the literature is varied, which may be related to the number of cases included in each study ^(3,4,8,9,18). The survival curve of patients in this group is shown in figure 4. The average survival rate of patients is 90 months, and the 5-year survival rate is 80%. The mean survival rate of patients treated with surgery and those treated with

radiotherapy and chemotherapy alone showed statistical significance, and the survival time of patients was significantly improved after surgical treatment. There was no evident correlation between the average survival rate and gender.

In summary, primary renal EWs/PNET is rare and its clinical characteristics are non-specific. Renal EWs/PNET should be considered as one of the differential diagnoses of common renal tumors such as RCC and nephroblastoma. CT examination plays an important role in the diagnosis and differential diagnosis of primary renal EWs/PNET, and multiple irregular septum-like enhancement and delayed enhancement in lesions in CE-CT scan are helpful for diagnosis. Final diagnosis of primary renal EWs/PNET is dependent on histopathological examination. Complete resection of tumor tissue is the key to the favorable prognosis of renal EWs/PNET.

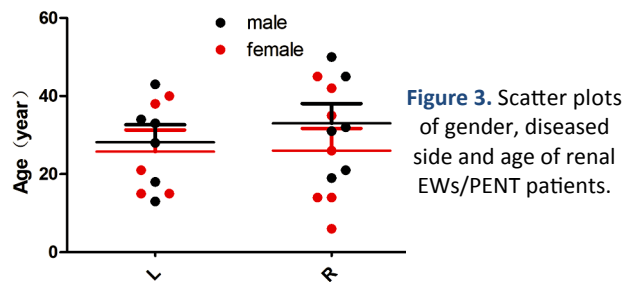


Figure 3. Scatter plots of gender, diseased side and age of renal EWs/PNET patients.

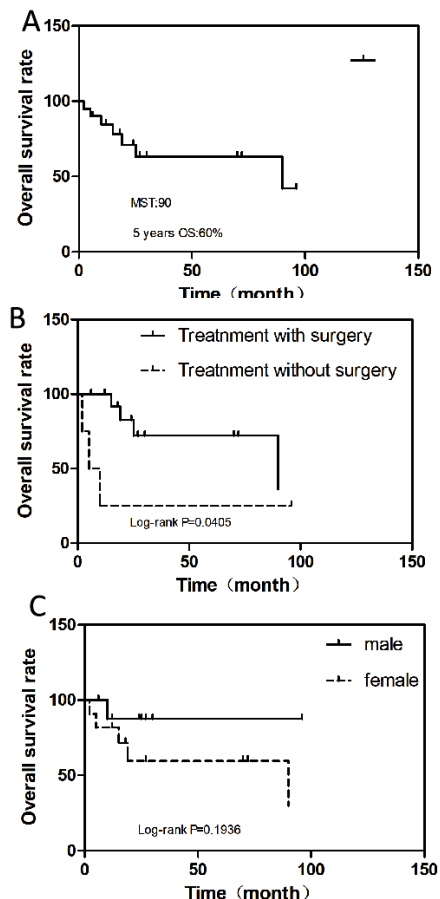


Figure 4. Kaplan-Meier OS. (A) OS in all cases. (B) OS according to patients treated with or without surgery. (C) OS by gender. OS, overall survival; MST, median survival time.

ACKNOWLEDGEMENTS

Thanks to all the medical staff of the Affiliated Hospital of Zunyi Medical University who provided the patient's clinical data, imaging and pathological pictures, and we thank the patient and his family for participating in this study.

Declarations

Ethics approval and consent to participate: This study was conducted under the standards of the Ethics Committee of the Affiliated Hospital of Zunyi Medical University, with the approval number ZYFY201801 and the release date on December 01, 2018. Written informed consent was obtained from the patient and his families.

Consent for Publication: The patient's oral and written informed consent was obtained for this case report and related pictures.

Availability of data and material: The datasets used and materials during the current study are available from the corresponding author on reasonable request.

Competing interests: The authors state that there are no conflicts of interest.

Funding: This study was funded by the National Natural Science Foundation of the People's Republic of China, NSFC (grant numbers: 81571712), Zunyi Medical College Research Start Fund 2018ZYFY03.

Authors' contributions: Hu X and Wang P conceived the case statement and drafted the manuscript; Zheng J and Peng C collected the patient's data and performed the follow-up; Cai J and Hu X wrote the manuscript; Yang C wrote the commentaries below pathological pictures; Cai J revised the manuscript.

REFERENCES

- Moustafellos P, Gourgiotis S, Athanasopoulos G, Karagianni E, Hadjiyannakis E (2007) A spontaneously ruptured primitive neuroectodermal tumor/extraosseous Ewing's sarcoma of the kidney with renal vein tumor thrombus. *Int Urol Nephrol*, **39**(2): 393-5.
- Yoshihara H, Kamiya T, Hosoya Y, Hasegawa D, Ogawa C, Asanuma H, et al. (2016) Ewing sarcoma/primitive neuroectodermal tumor of the kidney treated with chemotherapy including ifosfamide. *Pediatr Int*, **58**(8): 766-9.
- Mohsin R, Hashmi A, Mubarak M, Sultan G, Shehzad A, Qayum A, et al. (2011) Primitive neuroectodermal tumor/Ewing's sarcoma in adult uro-oncology: A case series from a developing country. *Urol Ann*, **3**(2): 103-7.
- Zhang S, Li Y, Wang R, Song B (2019) Ewing's sarcoma/primitive neuroectodermal tumor of the kidney: a case report and literature review. *Transl Androl Urol*, **8**(5): 562-566.
- Tripathy S, Shamim SA, Chellapuram S, Barwad A, Rastogi S (2020) Primary Ewing Sarcoma/Primitive Neuroectodermal Tumor of Kidney With Inferior Vena Cava Thrombus: Findings on 18F-FDG PET/CT. *Clin Nucl Med*, **45**(2): e103-e105.
- Suzuki I, Kubota M, Murata S, Makita N, Tohi Y, Kawakita M. A case of Ewing sarcoma family tumor of the kidney treated with robotic-assisted partial nephrectomy. *Urol Case Rep*, **25**:100900.
- Saxena R, Sait S, Mhawech-Fauceglia P (2006) Ewing sarcoma/primitive neuroectodermal tumor of the kidney: a case report. Diagnosed by immunohistochemistry and molecular analysis. *Ann Diagn Pathol*, **10**(6): 363-366.
- Sadiq M, Ahmad I, Shuja J, Ahmad K (2017) Primary Ewing sarcoma of the kidney: a case report and treatment review. *CEN Case Rep*, **6**(2): 132-135.
- Richey SL, Rao P, Wood CG, Patel S, Tannir NM (2012) Metastatic extraosseous Ewing's sarcoma (EES)/primitive neuroectodermal tumor (PNET) of the kidney: 8-year durable response after induction and maintenance chemotherapy. *Clin Genitourin Cancer*, **10**(3): 210-2.
- Ozturk H (2015) Peripheral neuroectodermal tumour of the kidney (Ewing's sarcoma): Restaging with (18) F-fluorodeoxyglucose (FDG) -PET/CT. *Can Urol Assoc J*, **9**(1-2): E39-44.
- Ohgaki K, Horiuchi K, Mizutani S, Sato M, Kondo Y (2010) Primary Ewing's sarcoma/primitive neuroectodermal tumor of the kidney that responded to low-dose chemotherapy with ifosfamide, etoposide, and doxorubicin. *Int J Clin Oncol*, **15**(2): 210-214.
- Moustafellos P, Gourgiotis S, Athanasopoulos G, Karagianni E, Hadjiyannakis E (2007) A spontaneously ruptured primitive neuroectodermal tumor/extraosseous Ewing's sarcoma of the kidney with renal vein tumor thrombus. *Int Urol Nephrol*, **39**(2): 393-395.
- Manescu MR, Sahyoun A, Froment N, Crisan N, Girot V (2015) Ewing's Sarcoma of the Kidney Complicated by a Wunderlich Syndrome. *Case Reports in Urology*, **2015**: 601038.
- Maeda M, Tsuda A, Yamanishi S, Uchikoba Y, Fukunaga Y, Okita H, et al. (2008) Ewing sarcoma/primitive neuroectodermal tumor of the kidney in a child. *Pediatr Blood Cancer*, **50**(1): 180-183.
- Zhang DF, Li ZH, Gao DP, Yang GJ, Ding YY, Wang GS, et al. (2016) The CT and US features of Ewing's sarcoma/primary neuroectodermal tumor of the kidney: two case reports and review of literature. *Oncotargets and Therapy*, **9**: 1599-603.
- Kumar R, Gautam U, Srinivasan R, Lal A, Sharma U, Nijhawan R, et al. (2012) Primary Ewing's sarcoma/primitive neuroectodermal tumor of the kidney: Report of a case diagnosed by fine needle aspiration cytology and confirmed by immunocytochemistry and RT-PCR along with review of literature. *Diagn Cytopathol*, **40**(2): E156-161.
- Kang SH, Perle MA, Nonaka D, Zhu H, Chan W, Yang GC (2007) Primary Ewing sarcoma/PNET of the kidney: fine-needle aspiration, histology, and dual color break apart FISH Assay. *Diagn Cytopathol*, **35**(6): 353-357.
- Hakky TS, Gonzalvo AA, Lockhart JL, Rodriguez AR (2013) Primary sarcoma of the kidney: a symptomatic presentation and review of the literature. *Ther Adv Urol*, **5**(3): 153-159.
- Funahashi Y, Hattori R, Yamamoto T, Mizutani K, Yoshino Y, Matsukawa Y, et al. (2009) Ewing's sarcoma / primitive neuroectodermal tumor of the kidney. *Aktuelle Urol*, **40**(4): 247-249.
- Fergany AF, Dhar N, Budd GT, Skacel M, Garcia JA (2009) Primary extraosseous Ewing sarcoma of the kidney with level III inferior vena cava thrombus. *Clinical Genitourinary Cancer*, **7**(3): E95-E97.
- Ding Y, Huang Z, Ding Y, Jia Z, Gu C, Xue R, et al. (2016) Primary Ewing's Sarcoma/Primitive Neuroectodermal Tumor of Kidney with Caval Involvement in a Pregnant Woman. *Urol Int*, **97**(3): 365-368.
- Bontoux C, Khaddour S, Pérot G, Vaessen C, Boostandoost H, Augustin J, et al. (2018) Case report of an ewing's sarcoma/primitive neuroectodermal tumor of the kidney. *Int Urol Nephrol*, **50**(8): 1449-1451.
- Alghamdi MHA, Alawad SA, Alharbi MG, Alabdulsalam AK, Almodhen F, Alasker A (2020) A rare case of Ewing's sarcoma of the kidney. *Urology Case Reports*, **29**: 101094.
- Alasmari F, Albadawe H, Alkhateeb S, Alsufiani F, Ghandurah S (2017) Primary Ewing's sarcoma of the kidney: A case report. *Int J Surg Case Rep*, **41**: 65-67.
- Teegavarapu PS, Rao P, Matrana MR, Cauley DH, Wood CG, Patel S, et al. (2017) Outcomes of adults with Ewing sarcoma family of tumors (ESFT) of the kidney: A single-institution experience. *Am J Clin Oncol*, **40**(2): 189-193.
- Lee H, Cho JY, Kim SH, Jung DC, Kim JK, Choi HJ (2009) Imaging findings of primitive neuroectodermal tumors of the kidney. *J Comput Assist Tomogr*, **33**(6): 882-886.

